



This is a digital copy of a book that was preserved for generations on library shelves before it was carefully scanned by Google as part of a project to make the world's books discoverable online.

It has survived long enough for the copyright to expire and the book to enter the public domain. A public domain book is one that was never subject to copyright or whose legal copyright term has expired. Whether a book is in the public domain may vary country to country. Public domain books are our gateways to the past, representing a wealth of history, culture and knowledge that's often difficult to discover.

Marks, notations and other marginalia present in the original volume will appear in this file - a reminder of this book's long journey from the publisher to a library and finally to you.

Usage guidelines

Google is proud to partner with libraries to digitize public domain materials and make them widely accessible. Public domain books belong to the public and we are merely their custodians. Nevertheless, this work is expensive, so in order to keep providing this resource, we have taken steps to prevent abuse by commercial parties, including placing technical restrictions on automated querying.

We also ask that you:

- + *Make non-commercial use of the files* We designed Google Book Search for use by individuals, and we request that you use these files for personal, non-commercial purposes.
- + *Refrain from automated querying* Do not send automated queries of any sort to Google's system: If you are conducting research on machine translation, optical character recognition or other areas where access to a large amount of text is helpful, please contact us. We encourage the use of public domain materials for these purposes and may be able to help.
- + *Maintain attribution* The Google "watermark" you see on each file is essential for informing people about this project and helping them find additional materials through Google Book Search. Please do not remove it.
- + *Keep it legal* Whatever your use, remember that you are responsible for ensuring that what you are doing is legal. Do not assume that just because we believe a book is in the public domain for users in the United States, that the work is also in the public domain for users in other countries. Whether a book is still in copyright varies from country to country, and we can't offer guidance on whether any specific use of any specific book is allowed. Please do not assume that a book's appearance in Google Book Search means it can be used in any manner anywhere in the world. Copyright infringement liability can be quite severe.

About Google Book Search

Google's mission is to organize the world's information and to make it universally accessible and useful. Google Book Search helps readers discover the world's books while helping authors and publishers reach new audiences. You can search through the full text of this book on the web at <http://books.google.com/>

S. SCHREUDER,
PRESCRIPTION DRUGGIST
CHICAGO, ILL.

Robert L. Schreuder



GIFT
Dr. L. A. Emge

Rush Medical College,

~~Robert Sammonsheim.~~

~~Rush Medical College~~

FEB 9

FEB 9

S. SCHREUDER,
RESCRIPTION DRUGGIST
CHICAGO, ILL.

Robert L. Schreuder



GIFT
Dr. L. A. Emge

Rush Medical College,

~~Robert Sonnenschein~~

~~Rush Medical College~~

FEB 9

FEB 9







.

.

..



.



THE
DISSECTION OF THE HUMAN BODY.

HOLDEN.

HOLDEN'S ANATOMY.

Press Notices of Previous Editions.

From THE AMERICAN JOURNAL OF MEDICAL SCIENCES.

"Within a few years many manuals of dissecting have been published, which are gems compared with the companions of a former generation of students. The work before us is a brilliant example of the new order of text-books. How imperfect and plain the old volumes appear! What daubs of printer's ink the wood-cuts are when placed by the side of such illustrations as are now commonly seen! Perhaps no one has had more to do with the introduction of demonstrative illustrations in anatomical books than Mr. Holden. * * * *

"We would call special attention to the character of the illustrations, with which the volume is bountifully furnished. In many books of this kind the cuts are too elaborate, and thus obscure facts and befog the mind of the beginner. Here there are introduced many plans and diagrams, which simplify the subject, and enable the student to fix the important points indelibly in his memory. Diagrammatic drawings, such as a lecturer makes on a blackboard before the very eyes of his class, are far better for instruction than the most artistic paintings of the experienced anatomical artist. This principle has been recognized by the editors, who have given many plans of arterial branches and anastomoses, and of nerve distributions."

From THE BOSTON MEDICAL AND SURGICAL JOURNAL.

"Mr. Holden is the happy possessor of the faculty of writing interesting works on anatomy. A part of the charm consists in the frequent references to practical points, and in the explanation of the advantages and objects of details of structure."

From THE BRITISH MEDICAL JOURNAL.

"The new edition of this favorite students' manual is in every respect worthy of its predecessors.

"In all capacities, whether as demonstrator, lecturer, or examiner, Mr. Holden has endeavored to make anatomical teaching easy, and to provide for the requirements of the student. * * * * Both author and editor are also accomplished surgeons. It is not surprising, therefore, that the fifth edition of the 'Manual of Dissection' is a work thoroughly suited to the requirements of the student, as understood by examiners of the present day. The work contains some excellent new wood cuts."

From THE CINCINNATI MEDICAL NEWS.

"This work is not designed merely for the study of anatomy, but it is for the use of those who are employed in the dissecting room in dissecting, and wish to study the parts as they are disclosed by the dissecting knife in regular dissecting.

"We have met with many dissecting manuals and dissectors, but the book before us is much superior to any work brought to our attention. The most approved methods are given for dissecting; the several regions of the body being treated in the order considered most suitable for their examination; and the muscles, vessels, nerves, etc., are described as they are successively exposed to view in the process of dissection."


W. H. Langton
HOLDEN'S MANUAL

OF THE

DISSECTION OF THE HUMAN BODY

EDITED BY

JOHN LANGTON,

SURGEON TO, AND LECTURER ON ANATOMY AT, ST. BARTHOLOMEW'S HOSPITAL; MEMBER OF THE BOARD OF EXAMINERS, ROYAL COLLEGE OF SURGEONS OF ENGLAND; SURGEON TO THE CITY OF LONDON TRUSS SOCIETY; CONSULTING SURGEON TO THE CITY OF LONDON LYING-IN HOSPITAL AND TO THE MEMORIAL HOSPITAL AT MILDWAY PARK.

SIXTH EDITION.

REVISED BY

A. HEWSON, M. D.,

DEMONSTRATOR OF ANATOMY, JEFFERSON MEDICAL COLLEGE, PHILADELPHIA; CHIEF OF SURGICAL CLINIC, JEFFERSON HOSPITAL; MEMBER ASSOCIATION OF AMERICAN ANATOMISTS; FELLOW OF THE COLLEGE OF PHYSICIANS, ETC.

311 ILLUSTRATIONS.

PHILADELPHIA:
P. BLAKISTON, SON & CO.,
1012 WALNUT STREET.

1894.

VP




COPYRIGHT, 1893, BY P. BLAKISTON, SON & CO., PHILADELPHIA.

Printed by Wm. F. Fell & Co.
1230-24 Market St.,
PHILADELPHIA.

.....
.....
.....
.....
.....
.....

.....
.....
.....
.....
.....



34
726
894

TO
THE STUDENTS
OF
ST. BARTHOLOMEW'S HOSPITAL,

IN THE HOPE THAT IT MAY ASSIST THEM IN THEIR
ANATOMICAL STUDIES,

This Manual is Dedicated

BY THEIR FAITHFUL FRIEND AND WELL-WISHER,

THE AUTHOR.

59431





PREFACE TO THE SIXTH EDITION.

The chief feature of Holden's Anatomy that must have become apparent to all who have hitherto used it, is not only that the text has been made so concise, but that the subject is presented in as clear and practical a light as is compatible with the faithful handling of its natural difficulties. It gives to the beginner a proper method of procedure, together with such details as are essential to the thorough understanding of the matter in hand. In making this revision the Editor has worked in accord with the editors of the previous editions, and has made such additions and alterations as seemed necessary to bring the book in line with present knowledge and methods, and has added the Metric Measurements side by side with the English. The entire work has been gone over line for line ; specially emphasized points have been added in foot-notes to which the editor has signed his initials (A. H.). There are, however, many additions and alterations in the text that were impossible to thus specify.

It has seemed well, in order to reduce the size of the book and still retain its salient features, to put the more minute and intricate points in a smaller type. This will be found an aid to the student and has allowed of the addition of a large number of new illustrations.

The total number of illustrations has been increased from 208 to 311. This, however, does not show the exact number of new pictures as many of those that appeared in the old editions have been struck out and replaced by more modern ones, taken chiefly from the works of Sappey, Wilson, and Landois. A. H.

1508 Pine Street, Philadelphia.





PREFACE TO THE FIFTH EDITION.

In this Edition the Editor has most carefully revised the entire work. The order of dissection has been here and there altered, and further illustrations and additional matter introduced, especially concerning the Anatomy of the Nervous System and the Organs of Special Sense.

The object throughout has been to be as concise as possible, and to put the subject in as clear and practical a light as is compatible with the faithful handling of its natural difficulties.

It is hoped that the work, in its present form, is adapted, not only for students, but for members of the profession who wish to refresh their anatomical knowledge.

The best thanks of the Editor are due to the Demonstrators and Assistant Demonstrators of Anatomy at St. Bartholomew's Hospital for valuable suggestions.

2 Harley Street, Cavendish Square.

PREFACE TO THE FIRST EDITION.

If any apology be needed for the appearance of the present Manual, it may be stated, without any wish to disparage the labours of others, that the works of this kind hitherto published seem to the Author open to one or the other of two objections;—either as being too systematic, and therefore not adapted for the dissecting-room, or as obscuring the more important features of Anatomy by a multiplicity of minute and variable details.

In endeavouring to supply a presumed deficiency, the Author has made it his special aim to direct the attention of the student to the prominent facts of Anatomy, and to teach him the groundwork of the science; to trace the connection, and to point out the relative situation of parts, without perplexing him with minute descriptions.

A concise and accurate account is given of all the parts of the human body—the bones excepted, of which a competent knowledge is presupposed—and directions are laid down for the best method of dissecting it.

The several regions of the body are treated of in the order considered most suitable for their examination; and the muscles, vessels, nerves, etc., are described as they are successively exposed to view in the process of dissection.

The Author has written the work entirely from actual observations: at the same time no available sources of information have been neglected, the highest authorities, both English and Foreign, having been carefully consulted. His acknowledgments are especially due to F. C. SKEY, Esq., F.R.S., Lecturer on Anatomy at St. Bartholomew's Hospital, for many valuable suggestions. He is also much indebted to his young friend, Mr. W. CLUBBE, for able assistance in dissections.

September, 1851.

CONTENTS.

	PAGE
DISSECTION OF THE SCALP,	25
DISSECTION OF THE FACE,	45
DISSECTION OF THE ORBIT,	68
DISSECTION OF THE NECK,	81
COURSE AND RELATIONS OF THE SUBCLAVIAN ARTERIES,	128
THE MUSCLES OF MASTICATION. TEMPORAL AND PTERYGO-MAXILLARY REGIONS,	141
BRANCHES OF THE INTERNAL MAXILLARY ARTERY IN THE THREE STAGES OF ITS COURSE,	148
BRANCHES OF THE INFERIOR MAXILLARY NERVE,	151
DISSECTION OF THE THORAX,	167
Dissection of the Heart,	203
Fœtal Circulation,	216
Structure of the Lungs,	218
Dissection of the Pharynx,	225
Dissection of the Larynx,	239
Dissection of the Tongue,	253
Dissection of the Superior Maxillary Nerve,	256
Dissection of the Ninth, Tenth, and Eleventh Cranial Nerves at the Base of the Skull,	261
Dissection of the Nose,	265
Dissection of the Muscles of the Back,	271
Ligaments of the Spine,	284
DISSECTION OF THE UPPER EXTREMITY,	293
Dissection of the Axilla,	298
Dissection of the Upper Arm,	310
Dissection of the Front of the Forearm,	325
Dissection of the Palm of the Hand,	338
Muscles of the Back connected with the Arm,	349
Dissection of the Muscles of the Shoulder,	359
Dissection of the Back of the Forearm,	367
Dissection of the Ligaments,	380
DISSECTION OF THE ABDOMEN,	395
Dissection of the Parts concerned in Inguinal Hernia,	414
Dissection of the Pelvic Viscera,	461

	PAGE
DISSECTION OF THE ABDOMEN (<i>Continued</i>),	
Dissection of the Male Perineum,	467
Dissection of the Female Perineum,	479
Anatomy of the Side View of the Pelvic Viscera,	483
Structure of the Bladder, Prostate, Urethra, and Penis,	500
Dissection of the Female Pelvic Viscera,	512
Dissection of the Abdominal Viscera,	524
DISSECTION OF THE LOWER EXTREMITY,	557
Anatomy of the Parts concerned in Femoral Hernia,	565
Dissection of the Front of the Leg,	588
Dissection of the Gluteal Region,	598
Dissection of the Back of the Thigh,	611
Dissection of the Back of the Leg,	617
Dissection of the Sole of the Foot,	626
Dissection of the Ligaments,	635
DISSECTION OF THE BRAIN,	655
Dissection of the Spinal Cord,	708
DISSECTION OF THE EYE,	719
DISSECTION OF THE ORGAN OF HEARING,	740
DISSECTION OF THE MAMMARY GLAND,	757
DISSECTION OF THE SCROTUM AND TESTIS,	759
INDEX,	771

ERRATA.

- The description under Fig. 54, page 146, should read, Pterygoid Muscles and Internal Maxillary Artery.
- The description under Fig. 55, page 149, should read, Plan of Internal Maxillary Artery.
- The description of Fig. 119, page 312, should read, at the Bend of the left Elbow, instead of at the End of the Left Elbow.
- The description of Fig. 129, page 341, should read, Deep Palmar Arches, instead of Palmar Arches.
- The description of Fig. 267, page 673, should read, Base of the Cerebrum, instead of Base of the Cerebellum.

LIST OF ILLUSTRATIONS.

FIG.	PAGE
1. Muscular and Aponeurotic Stratum of the Scalp,	26
2. Sensory Nerves of the Scalp and Face,	28
3. Branches of the Facial Nerve,	29
4. Section of Cranium, showing Falx Cerebri,	32
5. Diagram to show the Formation of a Sinus,	34
6. The Cranial Sinuses,	34
7. The Venous Sinuses at the Base of the Skull,	37
8. The Exit of the Cranial Nerves,	40
9. The Nerves in the Foramen Jugulare,	42
10. Relation of Structures in the Cavernous Sinus,	42
11. Relations of the Nerves in the Sphenoidal Fissure,	43
12. Relations of the Nerves and Muscles in the Orbit,	43
13. The Genuiculate Ganglion of the Facial Nerve,	44
14. The Muscles of the Face,	47
15. Tendon of the Orbicularis Palpebrarum,	49
16. Muscles of the Eye,	52
17. The Lachrymal Apparatus,	53
18. Tensor Tarsi,	54
19. Superficial Muscles of Face and Neck,	55
20. The Muscles of the Pharynx,	58
21. The Branches of the External Carotid Artery,	60
22. Dissection of Face, showing Glands,	62
23. Nerves of the Face,	65
24. The Sensory Nerves of the Scalp and Face,	67
25. The Nerves of the Orbit,	69
26. View of the Orbit from above,	71
27. Lachrymal Gland,	72
28. Muscles of the Eye,	73
29. View of the Optic and Lower Nerves of the Orbit,	75
30. Diagram of the Nerves of the Orbit,	78
31. Insertion of the Recti Muscles,	79
32. The Superficial Nerves and Veins of the Neck,	83
33. Cutaneous Nerves of the Neck,	85

FIG.	PAGE
34. Sterno-cleido-mastoid Muscle and Muscles above and below the Hyoid Bone,	89
35. The Triangles of the Neck,	90
36. Central Line of the Neck,	96
37. Muscles of the Hyoid and Infra-hyoid Regions,	97
38. Relations of the Carotid Arteries,	99
39. Central Line of Neck.—Course and Relations of Common Carotid Artery,	102
40. Lymphatic Vessels Coming from the Glands of the Neck and Axilla, .	106
41. Digastric Triangle and Contents,	109
42. Central Line of Neck, Course and Relations of Common Carotid Artery, .	113
43. The Branches of the External Carotid Artery and their Branches, . .	114
44. Gasserian Ganglion and Branches,	116
45. Muscles, Vessels, and Nerves of the Tongue,	118
46. Scalene Muscles,	127
47. The Heart and Large Vessels,	129
48. Lymphatic Vessels Coming from the Glands of the Neck and Axilla, .	132
49. Branches of the Subclavian Artery,	134
50. The Inosculations of the Subclavian Artery,	137
51. The Formation of the Brachial Plexus and its Branches,	139
52. Dissection of Face, Showing Glands,	142
53. Temporal Muscle,	144
54. Pterygoid Muscles and the Internal Maxillary Artery,	146
55. Plan of the Internal Maxillary Artery,	149
56. External Carotid Artery and its Branches,	150
57. Gasserian Ganglion and Branches,	152
58. Muscles of Tongue and Glottis,	156
59. Origin and Distribution of the Glosso-Pharyngeal, Pneumogastric, and Spinal Accessory Nerves,	161
60. The Communications of the Facial, Glosso-pharyngeal, Pneumogastric, Spinal Accessory, Hypoglossal, Sympathetic, and the two Upper Cervical Nerves,	165
61. Form and Position of the Lungs,	168
62. The Reflections of the Pleural Sacs,	172
63. Showing Interpleural Space,	174
64. Form and Position of the Lungs,	175
65. Relative Position of the Heart and its Valves with regard to the Walls of the Chest,	178
66. Relation of the Pericardium,	180
67. Superior Vena Cava and its Tributaries,	183
68. Course and Relations of the Arch and the Aorta,	185
69. The Course of the Vena Azygos and the Thoracic Duct,	191

FIG.	PAGE
70. The Thoracic Portion of the Sympathetic Nerve,	196
71. Diagram of a Spinal Nerve,	199
72. The Constituents of the Root of each Lung and their relative position,	202
73. The Interior of the Right Auricle,	206
74. Anatomy of the Heart—Right Side,	209
75. Anatomy of the Heart—Left Side,	210
76. The Relative Position of the Valves of the Heart seen from above,	214
77. Scheme of the Fœtal Circulation,	217
78. Ultimate Air-cells of the Lung,	223
79. Side View of the Muscles of the Pharynx,	227
80. View of the Constrictor Muscles from behind,	229
81. View of the Pharynx laid open from behind,	231
82. Pharynx opened Posteriorly,	234
83. Vertical Section of the Nasal Fossæ and Mouth,	236
84. Anterior View of Os Hyoides,	240
85. Larynx, Front View, with the Ligaments and Insertion of Muscles,	242
86. Posterior View of the Larynx, with the Muscles Removed,	242
87. Shape of the Glottis when at rest,	246
88. Posterior View of the Larynx, with its Muscles,	247
89. Diagram showing the Action of the Crico-thyroid Muscle,	248
90. Glottis dilated : Muscles dilating it,	248
91. Side view of the Muscles of the Larynx,	249
92. Glottis closed : Muscles closing it,	250
93. Nerves of the Larynx,	251
94. Upper Surface of the Tongue, with the Fauces and Tonsils,	254
95. Diagram of the Superior Maxillary Nerve,	257
96. Deep view of the Spheno-palatine Ganglion,	258
97. Communications of the Facial, Glosso-pharyngeal, Pneumogastric, Spinal Accessory, Hypoglossal, Sympathetic, and the two Upper Cervical Nerves,	260
98. The Geniculate Ganglion of the Facial Nerve and its Connections,	263
99. Cartilages of the Nose,	266
100. Vertical Section of the Nasal Fossæ and Mouth,	268
101. Transverse Section of the Nasal Fossæ,	269
102. Transverse Section through the Abdomen to show the attachment of the Lumbar Fascia,	272
103. The Superficial Muscles of the Back,	273
104. The Suboccipital Triangle,	279
105. The Cutaneous Nerves of the Back,	281
106. The Prevertebral Muscles,	283
107. The Odontoid and Transverse Ligaments,	288
108. Costo-vertebral Ligaments,	289

FIG.	PAGE
109. The Ligaments connecting the Rib with the Vertebra,	290
110. Transverse Section to show the Ligaments and the Fibro-Cartilage of the Lower Jaw,	291
111. Thoracic and Brachial Lymphatic Vessels emptying into the Axillary Lymphatic Glands,	300
112. Muscles of the Anterior Part of the Thorax,	301
113. The Axilla,	303
114. Plan of the Branches of the Axillary Artery,	304
115. The Origins of the Triceps,	304
116. The Brachial Plexus of Nerves,	306
117. Muscles of the Back (Superficial),	309
118. Distribution of the Cutaneous Nerves to the front of the Shoulder and Arm,	311
119. Superficial Veins and Nerves at the Bend of the Left Elbow,	312
120. Anterior Muscles of the Arm,	315
121. Plan of the Chief Branches of the Brachial Artery,	319
122. Brachial Portion of Musculo-Cutaneous Median and Ulnar Nerves,	322
123. Terminal Portion of the Median and Ulnar Nerves,	322
124. Triceps Muscle,	323
125. Superficial Muscles on the Anterior Surface of the Left Forearm,	328
126. Flexor Muscles of the Fingers,	330
127. Terminal Branches of the Radial Nerve,	333
128. Deep Flexor of the Fingers,	337
129. Diagram of the Superficial and Deep Palmar Arches,	341
130. Cutaneous Nerves of the Back,	351
131. The Superficial Muscles of the Back,	353
132. Cutaneous Nerves of the Left Shoulder and Arm (posterior view),	359
133. Analysis of the Deltoid,	360
134. Triceps Muscle,	362
135. Anterior Muscles of the Arm,	362
136. The Arteries of the Scapula,	365
137. Superficial Extensors of the Forearm,	370
138. Deep Extensors of the Forearm,	375
139. The Anastomoses of the Arteries at the back of the Elbow and Wrist Joints,	376
140. The Dorsal Interossei,	379
141. The Palmar Interossei, and the Adductor Pollicis,	379
142. The Sterno-clavicular Ligaments,	381
143. Anterior view of the Scapulo-clavicular Ligaments, and of the Shoulder- joint,	383
144. Ligaments of the Elbow joint,	386
145. The Ligaments and Synovial Membranes of the Wrist-joint,	389

FIG.	PAGE
146. The Abdominal Regions,	396
147. Superficial Vessels and Glands of the Groin,	398
148. Lymphatic Vessels and Glands of the Groin,	399
149. Muscles of the Anterior Part of the Trunk,	401
150. Poupart's Ligament, and the External Abdominal Ring,	402
151. The Lower Fibres of the Internal Oblique and Transversalis, with the Cremaster Muscle,	404
152. Deep Muscles of the Abdominal Wall,	405
153. Transverse Section to show the Formation of the Sheaths of the Rectus, the Quadratus Lumborum, and the Erector Spinæ,	407
154. The Fascia Transversalis seen from the front,	411
155. Varieties of Congenital Inguinal Herniæ,	418
156. Section to show the Ileo-cæcal Valve and Appendix Vermiformis,	424
157. Relative Position of the Kidneys and the Large Intestine, seen from behind,	425
158. The Peritoneum,	430
159. A Transverse Section through the Upper Part of the Abdominal Cavity,	432
160. A Transverse Section through the Lower Part of the Abdominal Cavity,	432
161. Branches of the Abdominal Aorta,	435
162. The Branches of the Cœliac Axis,	437
163. The Vena Portæ,	439
164. Plan of the Mesenteric Arteries, and their Communications,	440
165. The Diaphragm,	446
166. The Diaphragm from its Upper Surface,	447
167. The Course and Relations of the Abdominal Aorta and Vena Cava Inferior,	450
168. Psoas, Iliacus, and Quadratus Lumborum Muscles,	454
169. Plan of the Lumbar Plexus and Branches,	460
170. The Relative Position of the Pelvic Viscera,	464
171. Vertical Section through the Female Pelvic Viscera,	466
172. Framework of the Perineum,	467
173. Muscles, with Superficial Vessels and Nerves, of the Perineum,	471
174. The Accelerator Urinæ in Profile,	472
175. The Triangular Ligament of the Urethra,	473
176. The Parts Behind the Anterior Layer of the Triangular Ligament,	474
177. The Relations of the Compressor Urethræ,	477
178. Bulb of the Vagina,	482
179. Vertical Section through the Perineum and Pelvic Viscera,	484
180. Transverse Section to show the Reflections of the Pelvic Fascia,	485
181. Side View of the Pelvic Viscera,	487
182. Posterior View of the Bladder,	489
183. Plan of the Branches of the Internal Iliac Artery,	495
184. View of the Abnormalities of the Obturator Artery,	496
185. Plan of the Sacral Plexus and Branches,	499

FIG.	PAGE
186. Bladder and Urethra exposed from the Upper Surface,	501
187. Lower Part of the Human Bladder laid open,	505
188. Side View of the Pelvic Viscera,	507
189. Transverse Sections of the Urethra,	508
190. Transverse Section through the Penis,	511
191. Virgin Uterus,	518
192. The Uterus, the Ovaries, and Fallopian Tubes,	520
193. Section of an Ovary,	523
194. The Under Surface of the Liver,	525
195. Transverse Sections of Lobules of the Liver,	527
196. Longitudinal Sections of Lobules of the Liver,	528
197. Diagram of a Liver Lobule and Isolated Liver Cells,	529
198. Diagram of a Transverse Section through the Lower Part of the Abdominal Cavity,	531
199. Pancreas and Duodenum seen from behind,	532
200. Section of the Kidney,	538
201. The Course and Arrangement of the Uriniferous Tubules,	540
202. Blood-vessels and Uriniferous Tubules of the Kidney (Semi-diagram- matic)	541
203. Bowman's Capsule and Glomerulus,	542
204. Vertical Section of the Wall of the Human Stomach,	546
205. Vertical Section of the Gastric Mucous Membrane,	547
206. Vertical Section of the Duodenum,	550
207. Injected Blood-vessels of a Villus,	551
208. Section of a Solitary Follicle of the Small Intestine,	552
209. Section to show the Ileo-cæcal Valve,	553
210. Longitudinal Section of the Large Intestine	554
211. Lymphatic Vessels and Glands of the Groin,	559
212. Saphenous Opening with the Cribriform Fascia,	561
213. Fascia on the Outside of the Thigh,	563
214. The Femoral Ring and the Saphenous Opening,	564
215. Position of Parts under the Crural Arch,	567
216. The Sheath of the Femoral Vessels,	568
217. View of the Abnormalities of the Obturator Artery,	571
218. Scarpa's Triangle,	573
219. Internal Muscles of the Thigh,	574
220. Pectineus and Adductors,	574
221. Adductor Magnus and Brevis,	578
222. Anterior Muscles of the Thigh,	578
223. Section through Hunter's Canal,	582
224. Plan of the Inosculations of the Circumflex Arteries,	585
225. Nerves on the Anterior Part of the Thigh,	586
226. Anterior Muscles of the Leg,	591

LIST OF ILLUSTRATIONS.

xix

FIG.	PAGE
227. Extensor Tendons of the Toes,	594
228. Muscles of the Fibular Region,	596
229. Peroneal or External Popliteal Nerve,	596
230. Gluteus Maximus Muscle,	601
231. Muscle beneath the Gluteus Maximus,	601
232. The Great Sciatic Nerve,	603
233. Plan of the Sacral Plexus and Branches,	605
234. Deep Muscles of the Gluteal Region,	606
235. The Arteries of the Gluteal Region,	607
236. Left Popliteal Space,	610
237. Hamstring Muscles,	613
238. Short Head of the Biceps and Semimembranosus Muscles,	614
239. Diagram showing Action of the Hamstring Muscles,	616
240. Muscles of the Calf,	618
241. Diagram showing Action of the Gastrocnemius,	621
242. Popliteal and Posterior Tibial Arteries,	622
243. Deep Muscles on the Back of the Leg,	623
244. Superficial Muscles of the Sole of the Foot,	628
245. Muscles, Vessels, and Nerves of the Sole of the Right Foot,	629
246. Plantar Arteries,	631
247. View of the Third Layer of the Muscles of the Foot,	633
248. Ligaments of the Pelvis and Hip-joint,	637
249. Ligaments of the Hip-joint (lateral view),	637
250. Vertical Section through the Hip,	640
251. The Semilunar Cartilages and Lateral Ligaments of the Knee,	643
252. Posterior View of the Ligaments of the Knee-joint,	644
253. Internal Ligaments of the Knee-joint,	644
254. Crucial Ligaments of the Knee,	647
255. Ligaments of Ankle-joint,	649
256. The External Lateral Ligament,	649
257. Calcaneo-scapoid Ligament,	651
258. Ligaments of the Sole of the Foot,	651
259. Interosseous Ligaments of the Wedge Bones,	653
260. The Articulations of the Tarsus and the Tarso-metatarsus,	654
261. The Base of the Brain,	658
262. The Front Surface of the Medulla Oblongata,	661
263. The Fourth Ventricle and the Restiform Bodies,	663
264. The Course of the Fibres through the Medulla Oblongata,	665
265. Convolution and Fissures of the External Surface of the Brain,	670
266. Convolution of the Upper Surface of the Brain,	671
267. Convolution of the Base of the Cerebrum,	673
268. Convolution and Fissures of the Median and Tentorial Surfaces of Right Hemisphere,	675

FIG.	PAGE
269. The Base of the Brain,	677
270. Diagram of the Course of the Fibres through the Medulla and Pons . . .	680
271. The Origins of the Olfactory and Optic Nerves,	681
272. The Floor of the Fourth Ventricle,	684
273. Upper Surface of the Corpus Callosum,	686
274. Diagram of the Lamina Cinerea,	686
275. Vertical Section through the Corpus Callosum, and parts below, . . .	687
276. The Lateral Ventricles,	689
277. Transverse Vertical Section through the Brain,	690
278. The Fornix,	691
279. The Lateral Ventricles and the Velum Interpositum,	694
280. The Third Ventricle,	697
281. The Interior of the Third Ventricle (from above),	698
282. Floor of the Fourth Ventricle,	701
283. Superior Surface of the Cerebellum,	704
284. Inferior Surface of the Cerebellum,	705
285. The Spinal Veins (vertical section),	709
286. The Spinal Veins (transverse section),	709
287. Membranes of the Cord and Nerves given off,	710
288. The Ligamentum Denticulatum,	713
289. A Transverse Section through the Spinal Cord and its Membranes, . .	714
290. Transverse Sections of the Spinal Cord in Different Regions,	716
291. Insertion of the Recti Muscles,	722
292. A Vertical Section of the Eye,	723
293. Antero-posterior Section at the Junction of the Cornea with the Sclerotic,	724
294. The Choroid, the Ciliary Muscle, and Nerves,	727
295. Horizontal Section of Eye showing the Blood-vessels,	730
296. The Various Layers of the Retina,	733
297. Section of the Fovea Centralis,	735
298. Arteries of the Retina,	737
299. Vertical Section of Ear,	741
300. Tensor Tympani Muscle,	743
301. Tympanic Membrane and Auditory Ossicles (left),	745
302. Auditory Ossicles (right),	745
303. Right Stapedius Muscle,	747
304. Osseous Labyrinth of the Right Side (opened),	748
305. The Osseous Cochlea,	749
306. Section of the Cochlea,	750
307. Vertical Section of the First Turn of the Cochlea,	753
308. Distribution of the Vestibular Branch in the Membranous Labyrinth, .	755
309. The Two Branches of the Auditory Nerve,	755
310. A Vertical Section through the Testicle,	760
311. Transverse Section through the Left Testicle,	762

A MANUAL

OF THE

DISSECTION OF THE HUMAN BODY.

DISSECTION OF THE SCALP.

An incision should be made from the root of the nose (*nasion*) along the mesial line of the vertex to the external protuberance of the occipital bone (*inion*); another horizontally round each half of the head, to join at right angles the two ends of the first incision. These incisions must not divide more than the skin, so that the subcutaneous vessels and nerves be not injured. It is well to dissect on one side of the head the muscles only, reserving the other side for the dissection of the vessels and nerves.

Dissection.

Strata Composing the Scalp.

The several strata of tissues covering the skull-cap are—1, the *skin*; 2, a thin layer of *connective tissue* and *fat* which contains the cutaneous vessels and nerves and the bulbs of the hair; and by which the skin is very closely connected to, 3, the *broad thin aponeurosis* of the occipito-frontalis muscle (aponeurosis of the scalp); 4, an abundance of loose *connective tissue*, which permits the free motion of the scalp upon, 5, the *pericranium*, or periosteum of the skull cap.

Immediately beneath the skin, then, we expose the thin stratum of connective and adipose tissue which firmly connects it with the aponeurosis of the scalp. This layer is continuous behind with the superficial fascia covering the muscles at the back of the neck, and laterally it passes over the temporal fascia. It forms a bed for the bulbs of the hair and for the ramifications of the cutaneous arteries. The toughness of this tissue, in which the arteries ramify, does not permit them to retract when divided; hence the hæmorrhage which follows incised wounds of the scalp; hence also the difficulty of drawing them out with the forceps.

**Occipito-frontalis
Muscle and Epi-
cranial Aponeuro-
sis.**

This cutaneous muscle is closely connected to the scalp. It consists of two fleshy portions, one on the occiput, the other on the forehead, connected by a broad aponeurosis. The *occipital portion* of the muscle is thin, and takes origin from the outer two-thirds of the upper curved line of the occipital bone, and the adjoining part of the mastoid process of the temporal bone. The fibres ascend over the back

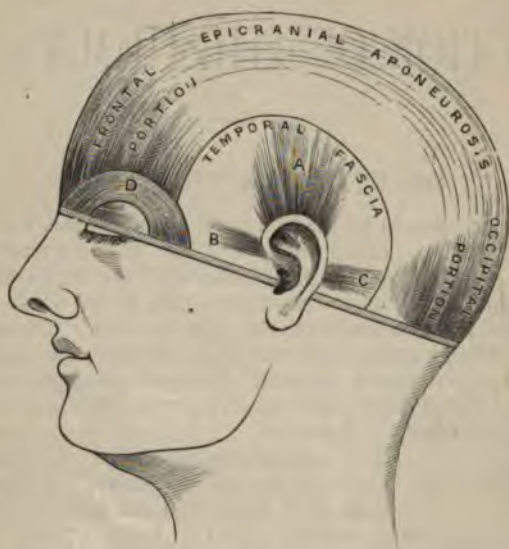

FIG. 1.—DIAGRAM SHOWING THE MUSCULAR AND APONEUROTIC STRATUM OF THE SCALP. A, Attollens aurem. B, Attrahens aurem. C, Retrahens aurem. D, Orbicularis palpebrarum.

of the head for about two inches, and then terminate in the epicranial aponeurosis. The *frontal portion*, commencing in an arched form from the epicranial aponeurosis below the coronal suture, descends over the forehead, and terminates partly in the skin of the brow, partly in the orbicularis oculi and corrugator and supercillii, while some of the inner fibres are continuous in front of the nose with the pyramidalis nasi muscle. The aponeurosis of the scalp covers the vertex of the skull, the two being continuous across the middle line. It is continued over the temples and side of the head, gradually changing from tendinous into connective tissue. This muscle enables us to move the scalp backwards and

forwards. But its chief action is as a muscle of expression. It elevates the brows, and occasions the transverse wrinkles in the expression of surprise.

The occipital portion is supplied by the posterior auricular branch of the facial; the frontal portion by the temporal branch of the same nerve.

Muscles of the Ear. There are several small muscles to move the cartilage of the ear. In man they are thin and pale, and require care to dissect them out satisfactorily. In animals, who possess a more delicate sense of hearing, they are much more developed, for the purpose of quickly directing the cartilage of the ear towards the direction of the sound.

Attollens Aurem. To indicate the position of this muscle the student should draw down the upper part of the pinna of the ear, when it will be found immediately under the ridge of skin so produced. It is a thin, fan-shaped muscle and *arises* from the epicranial aponeurosis, and is *inserted* into the cranial aspect of the upper part of the concha.

Attrahens Aurem. This muscle is the smallest of these muscles, and its situation is indicated by the prominence of skin produced by drawing backwards the front part of the helix, or outer rim of the cartilage of the ear. It *arises* from the aponeurosis of the occipito-frontalis, and is *inserted* into the front of the helix.

Retrahens Aurem. This muscle is exposed by reflecting the skin from the ridge produced by drawing the pinna forwards. Consisting of two or three fasciculi, it *arises* from the base of the mastoid process and is *inserted* into the lower part of the concha, or expanded portion of the cartilaginous auditory canal.

The retrahens and the attollens aurem are supplied by the posterior auricular branch of the facial nerve; the attrahens, by an offset from the temporal branch of the same nerve.

Arteries of Scalp. The *arteries* of the scalp are derived, in front, from the *supra-orbital* and *frontal* arteries, branches of the ophthalmic artery, which is a branch of the internal carotid; on the sides, from the *temporal*; behind, from the *occipital* and *posterior auricular*, all branches of the external carotid.

The *frontal* emerges from the orbit at its inner angle; it runs upwards for a short distance on the forehead and inosculates with the following artery.

The *supra-orbital* passes through the supra-orbital notch and then divides into a superficial and a deep branch. It distributes branches, some of which ascend toward the top of the head and communicate with the temporal and frontal arteries.

The *temporal*, about two inches above the zygoma, divides into two branches—an anterior and a posterior. The anterior runs forwards in a tortuous course and

anastomoses with the supra-orbital and frontal arteries; the *posterior* (usually the larger) arches backwards over the temporal fascia, and its branches communicate with the corresponding branch of the opposite side and with the occipital and posterior auricular arteries.

The *posterior auricular* is a small vessel seen in the cleft between the ear and the mastoid process. It ascends, and divides into two branches: one, the mastoid or occipital, which passes backwards and inosculates with the occipital; the other, the auricular, which runs forwards above the ear and communicates with the posterior branch of the temporal artery.

The *occipital* may be noticed piercing the trapezius near to the external occipital protuberance; ascending over the back of the head, it divides into numerous branches which inosculate with the preceding arteries.

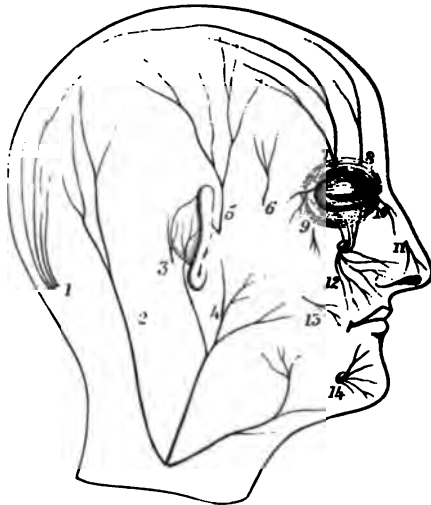

FIG. 2.—DIAGRAM OF THE SENSORY NERVES OF THE SCALP AND FACE.

1. Great occipital. 2. Small occipital. 3. Auricular br. of the pneumogastric. 4. Great auricular. 5. Auriculo temporal. 6. Temporal br. of superior maxillary nerve. 7. Supra-orbital. 8. Supra-trochlear. 9. Malar br. of superior maxillary nerve. 10. Infra-trochlear. 11. Naso-lobular. 12. Infra-orbital. 13. Buccal br. of inferior maxillary nerve. 14. Mental.

The frontal vein passes downwards with its corresponding artery, and joins the supra-orbital vein, to form the angular vein. The other veins of the scalp accompany their respective arteries.

Nerves of the Scalp. The sensory nerves of the scalp are derived from each of the three divisions of the fifth cranial nerve—namely, the ophthalmic, the superior and inferior maxillary; also from the second cervical nerve. The nerves to the muscles of the scalp and ear come from the facial seventh cranial nerve.

In front will be found the supra-trochlear and supra-orbital nerves; in the temporal region, there are the temporal filament from the orbital branch of the superior maxillary, the auriculo-temporal, and the temporal branches of the facial nerve; and behind will be seen the posterior auricular branch of the facial, the small and great occipital nerves, and occasionally a small filament from the posterior division of the sub-occipital nerve.

The *supra-trochlear nerve* is derived from the frontal branch of the ophthalmic division of the fifth. It appears at the inner angle of the orbit, and ascending beneath the orbicularis palpebrarum and occipito-frontalis, it finally supplies the skin of the forehead and the upper eyelid.

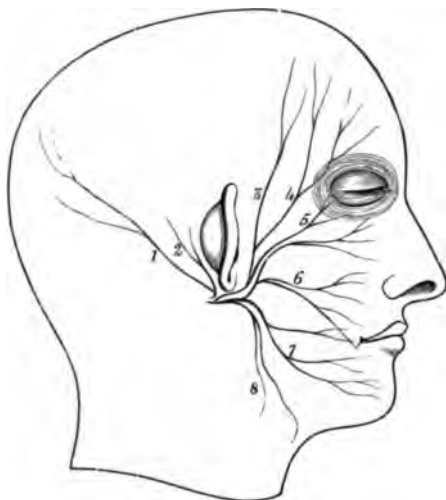

FIG. 3.—DIAGRAM OF THE BRANCHES OF THE FACIAL NERVE.

1. Branch to occipito-frontalis. 2. Posterior auricular. 3. Temporal brs. 4. Malar brs. 5. Infra-orbital. 6. Buccal. 7. Supra-maxillary. 8. Infra-maxillary.

The *supra-orbital nerve* is a continuation of the frontal branch of the fifth. It emerges from the orbit through the notch in the frontal bone, and subdivides into branches, which are covered at first by the fibres of the orbicularis and occipito-frontalis; but they presently become subcutaneous, and terminate in two branches—an *inner*, which ascends, to supply the structures as high as the parietal bone; and an *outer* and larger, which may be traced over the vertex as far as the occipital bone.

The *temporal branch* of the *orbital branch* of the superior maxillary nerve pierces the temporal fascia about an inch above the zygoma and is distributed to the skin of the temple, communicating with the facial nerve and occasionally with the following.

The *auriculo-temporal nerve*, a branch of the inferior maxillary nerve, after

sending a small filament to the upper part of the pinna, divides into two branches which accompany the divisions of the superficial temporal artery; of these, the posterior is the smaller. The anterior communicates with the facial nerve, and with the orbital branch of the superior maxillary.

The *temporal branches* of the facial nerve lie superficial to the temporal fascia, and supply the *atrahens* and *attollens aurem*, the *orbicularis palpebrarum*, the *corrugator supercillii*, and the *occipito-frontalis*. These branches communicate with the temporal branch of the superior maxillary, the *auriculo-temporal* nerve, and with the *lacrymal* and *supra-orbital* branches of the *ophthalmic*.

The *posterior auricular nerve* is a branch of the facial, and divides like its accompanying artery behind the pinna of the ear into a *posterior* or *occipital* branch which supplies the posterior belly of the *occipito-frontalis*, and into an *anterior* or *auricular* branch which ends in the auricle, the *retrahens*, and *attollens aurem*. It communicates with the *great auricular* and *small occipital* nerves, and with the *auricular branch* (Arnold's) of the *pneumogastric*.

The *auricular branch of the pneumogastric* (Arnold's) emerges from the *auricular fissure* immediately behind the pinna, and supplies the skin of the pinna and the neighbourhood.

The *great occipital nerve* is the internal branch of the posterior division of the second cervical nerve. After piercing the *complexus* it appears on the occiput with the *occipital artery*, and divides into wide-spreading branches which supply the skin. It communicates with the *posterior auricular*, the *small occipital*, and the *third cervical* nerves.

The *small occipital nerve*, a branch of the anterior division of the second cervical nerve, runs along the posterior border of the *sterno-mastoid* and supplies the scalp behind the ear. It communicates with the *great auricular*, and with the two preceding nerves.

Occasionally, though rarely, a cutaneous branch of the *suboccipital nerve* is distributed to the back of the head.

Points of Surgical Interest.

Raise the aponeurosis of the scalp, and observe the quantity of loose connective tissue which intervenes between it and the pericranium.

This tissue never contains fat. There are some points of surgical interest concerning it: 1. Its looseness accounts for the extensive effusions of blood which one often sees after injuries of the head. 2. It admits of large flaps of the scalp being detached from the skull-cap; but these flaps rarely slough, unless severely damaged, because they carry their blood-vessels with them. 3. In *phlegmonous erysipelas* of the scalp, the connective tissue becomes infiltrated with pus and sloughs; hence the necessity of making incisions: for the scalp will not lose its vitality and liberate the sloughs, like the skin of other parts under similar conditions, because its vessels run above the diseased tissue, and therefore its supply of blood is not cut off.

Lymphatics of the Scalp.

The lymphatics of the scalp run for the most part backwards towards the occiput to join the *occipital* and *posterior auricular* glands; a few run towards the root of the *zygoma*, where they enter the *parotid lymphatic* glands. It is in these situations, therefore, that one finds glandular enlargements when the scalp is diseased.

If the skin has been removed from the face in dissecting its nerves, the student is advised to continue the facial dissection, as in well-injected subjects the brain will keep well in the skull.

Dissection.

To examine the brain and its membranes, the skull-cap must be removed about half an inch above the supra-orbital ridges in front, and on a level with the occipital protuberance behind. The student should remember that the bone in the temporal region is very thin, and that here especial care is needed that the brain be not injured by the saw. It is better to saw only through the outer table of the skull, and to break through the inner with a chisel. In this way the dura mater and the brain are less likely to be injured. On removing the skull-cap, which is more or less intimately attached to the subjacent membrane, we expose a tough fibrous layer, *the dura mater*, which forms the most external of the membranes of the brain.

The meningeal arteries ramify between the skull and the dura mater. We cannot, however, with the brain *in situ*, trace their course, at present, throughout; so their consideration must be deferred until the brain has been removed.

Dura Mater.

This membrane is a dense white fibrous membrane, rough on its outer aspect, where it is more or less adherent to the inner surface of the skull, forming its internal periosteum. On its inner surface it is smooth and shining, being lined by a layer of endothelial cells, which anatomists now describe as constituting a part of the dura mater. In consequence, the term "*subdural space*" is now substituted for the old one—"the cavity of the arachnoid." The dura mater differs in its adhesion to the subjacent bones: its adhesion is firmest at the sutures, the petrous portion of the temporal bone, the basilar process, the body of the sphenoid, the cribriform plate of the ethmoid bone, the depressions for the Pacchionian bodies, and at the margin of the foramen magnum. In front it sends downwards a prolongation into the foramen cæcum; also numerous small tubular sheaths through the foramina in the cribriform plate. It further sends a prolongation through the optic foramen, and another through the sphenoidal fissure into the orbit.

The dura mater is supplied with *nerves* by the recurrent branch of the fourth nerve, and by the fifth cranial nerve. Filaments have likewise been traced into it from the sympathetic and from the Gasserian ganglion.

Its remarkably tough and fibrous structure adapts it exceedingly well to the four purposes which it serves: 1. It forms the internal periosteum of the skull. 2. It forms, for the support of the lobes of the brain, three partitions—namely, the falx cerebri,

the falx cerebelli, and the tentorium cerebelli. 3. It forms the sinuses or venous canals which return the blood from the brain. 4. It forms sheaths for the nerves as they leave the skull.

Of the partitions formed by the dura mater for the support of the lobes of the brain, two are vertical, and separate, respectively, the two hemispheres of the cerebrum and those of the cerebellum ;

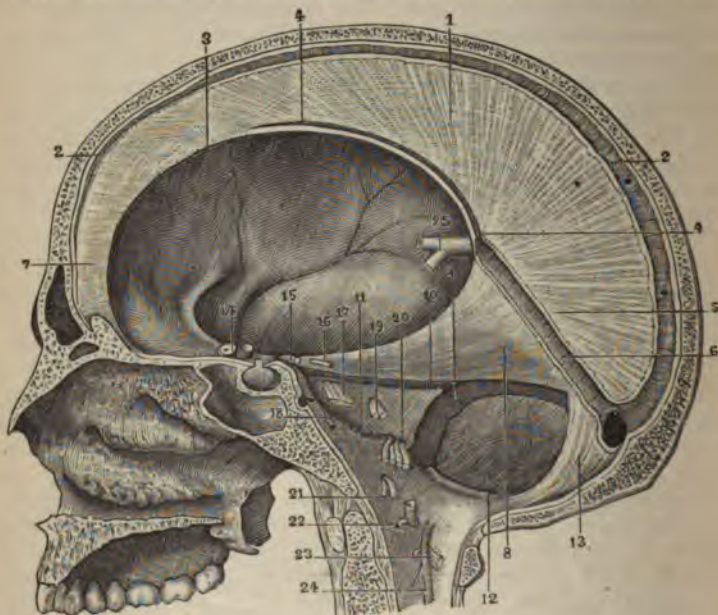


FIG. 4.

1. Falx cerebri. 2, 2. Its convex border enclosing the superior longitudinal sinus. 3. Its concave border. 4, 4. Inferior longitudinal sinus. 5. Base of the falx cerebri. 6. Straight sinus. 7. Apex of the falx attached to the crista galli. 8. Right half of the tentorium cerebelli from the interior surface. 9. Right lateral sinus. 10. Superior petrosal sinus. 11. Inferior petrosal sinus. 12. Occipital sinus. 13. Falx cerebelli. 14. Optic or second nerve. 15. Third nerve. 16. Fourth nerve. 17. Fifth nerve. 18. Sixth nerve. 19. Seventh and eighth nerves. 20. Ninth, tenth, and eleventh nerves. 21. Twelfth nerve. 22. First pair of cervical nerves. 23. Second pair of cervical nerves. 24. Superior end of linamentum denticulatum. 25. Venæ Galeni.

the third arches backwards, and supports the posterior lobes of the cerebrum.

Falx Cerebri.

This partition is named, from its resemblance to the blade of a sickle, *falx cerebri*. It is received into the longitudinal fissure, and separates the two cerebral hemispheres. It begins in a point attached to the *crista galli*, and gradually becomes broader as it extends backwards. Its

upper edge is convex, and attached to the median groove on the inner aspect of the vertex of the skull; its lower margin is concave and free, and runs along the upper aspect of the corpus callosum. From its base or broadest part proceeds the sloping arched partition named *tentorium cerebelli*. This forms an arch for the support of

Tentorium Cerebelli. the posterior lobes of the cerebrum, so that they may not press upon the cerebellum beneath. The tentorium is attached to the transverse ridge of the occipital bone, to the superior border of the petrous portion of the temporal bone, and to the posterior and anterior clinoid processes of the sphenoid. In front there is a large oval opening to allow of the passage of the crura cerebri. The small median partition

Falx Cerebelli. which separates the lobes of the cerebellum is called the *falx cerebelli*. It is placed vertically in the same plane with the falx cerebri, and its point is downwards towards the foramen magnum. As it approaches the foramen it usually divides into two small folds.

Glandulæ Pacchioni. In the neighbourhood of the superior longitudinal sinus, we meet with small white elevated granulations, sometimes arranged singly, sometimes in clusters, which are received into the depressions on the inner aspect of the skull-cap. They are termed *glandulæ Pacchioni*, and are found in four situations: 1. On the outside of the dura mater, close to the superior longitudinal sinus, and so large as to occasion depressions in the bones. 2. Along the margin of the fissure of Sylvius. 3. On the surface of the pia mater. 4. In the interior of the superior longitudinal sinus, covered by its lining membrane. 5. On the posterior and antero-inferior parts of the posterior lobe of the cerebrum.

They are due to an increased growth of the villi, which are normally found in the arachnoid membrane, and make their way, through the dura mater or the pia mater, to the different situations in which they are found. The greatest growth takes place from the visceral layer, as may be seen in the dissection of the brain. These bodies are not found at birth, but usually commence their growth about the third year, and are always found at the seventh year, after which they gradually increase as life advances.

Sinuses of the Dura Mater. It is one of the peculiarities of the cerebral circulation, that the blood is returned through canals or *sinuses* formed by the dura mater.

These canals are produced by a splitting of the dura mater into two layers as shown in Fig. 5, where 1 represents a vertical section through the superior longitudinal sinus. They are lined by the same smooth membrane continuous with that of the venous system. Since their walls consist of unyielding structure, and are always on

the stretch, it is obvious that they are admirably adapted to resist the pressure of the brain. There are fifteen of these sinuses, and they are classified into two groups—a *supero-posterior* and an *infero-anterior*. The supero-posterior group comprises the superior longitudinal, the inferior longitudinal, the straight, the lateral, and the occipital sinuses; while the infero-anterior group includes the cavernous, the circular, the superior and inferior petrosal, and the straight sinuses.

Of these fifteen sinuses, five are pairs and five are single, as follows:—

The five pairs of sinuses are—

- The lateral.
- The superior petrosal.
- The inferior petrosal.
- The cavernous.
- The occipital.

The five single sinuses are—

- The superior longitudinal.
- The inferior longitudinal.
- The circular.
- The transverse.
- The straight.

The blood from all these sinuses is eventually discharged into the internal jugular veins.

Superior Longitudinal Sinus.

This runs along the upper attached border of the falx cerebri (Fig. 6). It begins very small at the foramen cæcum, gradually increases in size in its course backwards, and opposite the internal protuberance

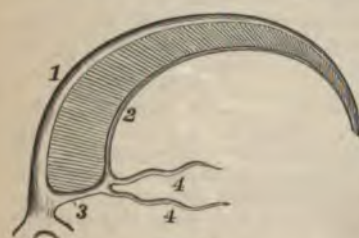


FIG. 6.

1. Superior longitudinal sinus. 2. Inferior longitudinal sinus. 3. Straight sinus. 4, 4. Veins Galeni.

of the occipital bone opens into a triangular dilatation, the *torcular Herophili*, or the *confluence of the sinuses*. It then divides into the right and left lateral sinuses, the right being generally the larger. Besides numerous veins from the cancellous texture of the skull-cap, the superior longitudinal sinus receives large veins from the upper part of each hemisphere of the cerebrum, and an emissary vein through the parietal foramen. It is interesting to observe that these veins run (as a rule) from behind forward, contrary to the current of blood in the sinus, and that they pass through the wall of the sinus very obliquely, like the ureter into the bladder. The probable object of this oblique entrance is to prevent regurgitation of blood from the sinus into the veins of the brain.

Cut open the superior longitudinal sinus: observe that it is triangular with its base upwards, and that its cavity is intersected in many places by slender fibrous cords, termed *chordæ Willisii*. Their precise use is not understood.

The brain should now be removed, and preserved in alcohol, 91 p., for future examination. Its anatomy, with that of its remaining membranes, will be described in a subsequent part of this work.

Dissection.

The brain is to be removed in the following manner: The dura mater should be cut through with a pair of scissors on a level corresponding with the sawn calvarium, care being taken to cut completely through the falx cerebri in the front part of the longitudinal fissure. Now lift up gently, with the fingers of the left hand, the frontal lobes from the anterior fossæ, taking care to raise with the brain the soft olfactory lobes from the cribriform plate of the ethmoid. Two white flat nerves—the optic—come into view prior to their leaving the skull through the optic foramina; these must be divided with a sharp knife together with the ophthalmic arteries which lie beneath the corresponding nerves. In the middle line, fixed firmly in the sella turcica, lies the pituitary body, attached to the brain by a process—the infundibulum. It is not easy to remove this body from the fossa in which it rests, owing to its being retained in its position by dura mater. When this is removed, two round white nerves—the third—are observed, one on each side, lying on the inner free border of the tentorium cerebelli, immediately behind the anterior clinoid process of the sphenoid. Divide these and then proceed to cut through the tentorium cerebelli close to its attachment to the posterior clinoid process and the upper border of the petrous portion of the temporal bone, as far back as the lateral sinus. If this be done with care, the nerves lying beneath the tentorium will not have been injured. Immediately external to the third nerves are the slender fourth nerves; and still further outside are the soft, flattened fifth nerves. Cut these through, still gently raising the brain from the skull base, when the seventh pair come into view as they pass backwards and outwards towards the internal auditory foramina. When these have been cut, we notice the two sixth nerves running directly forwards to pierce the dura mater covering the basilar process of the occiput. Divide these as they pierce the dura mater, when the ninth, tenth, and eleventh nerves are brought well into view, lying behind and internal to the seventh and eighth; the anterior one is the glosso-pharyngeal or ninth; the middle one is the pneumogastric, tenth, and the hindermost one is the spinal accessory, eleventh, whose spinal portion can be traced coming up from the foramen magnum. These all emerge through the jugular foramina. Below and internal to these

are the hypoglossal, twelfth, nerves, which usually pass through the dura mater in two fasciculi. Cut these, and then pass down the knife as far into the spinal canal as possible, and cut through the spinal cord, the two vertebral arteries, and the spinal portions of the spinal accessory nerves. Now lay the knife aside, when by gentle traction the brain can be easily removed from the skull.

The other sinuses should now be examined.

Lateral Sinuses.

These are the two great sinuses through which all the blood from the brain is returned to the jugular veins. Their course is well marked in the dry skull. The right is usually the larger. Each commences at the internal occipital protuberance, and proceeds at first horizontally outwards, enclosed between the layers of the tentorium, along a groove in the occipital bone and the posterior inferior angle of the parietal; it then descends along the mastoid portion of the temporal bone, and again indenting the occipital bone, turns forwards to the foramen lacerum posterius, and terminates in the bulb of the internal jugular vein,* where it is joined by the inferior petrosal sinus. It receives blood also from the inferior cerebral and cerebellar veins, from the diploë, and the superior petrosal sinus. It communicates with the veins of the scalp through emissary veins, which pass through the mastoid and posterior condylar foramina.

Inferior Longitudinal Sinus.

This is of small size. It runs in the inferior free border of the falx cerebri, and terminates in the straight sinus at the anterior margin of the tentorium (Fig. 6).

Straight Sinus.

This may be considered as the continuation of the preceding. It runs along the line of junction of the falx cerebri with the tentorium cerebelli, and terminates in the torcular Herophili at the divergence of the two lateral sinuses. It receives the inferior cerebral and the superior cerebellar veins, and also the two *venæ Galeni* (Fig. 6), which return the blood from the lateral and third ventricles of the brain.

Cavernous Sinus.

This is so called because its interior is intersected by numerous cords. It extends along the side of the body of the sphenoid bone, outside the internal carotid artery. It receives the ophthalmic vein which leaves the orbit through the sphenoidal fissure and the anterior inferior cerebral veins; it communicates with the circular sinus which surrounds the pituitary body (Fig. 7). At the apex of the petrous portion of the temporal bone it divides into the superior and inferior petrosal sinuses.

* It has, in some subjects, another outlet, through the foramen mastoideum, or else through the posterior condylar foramen.

Circular Sinus. This surrounds the pituitary body (P in Fig. 7) and communicates on each side with the cavernous sinus. The posterior branch is sometimes absent.

Petrosal Sinuses. These lead from the cavernous to the lateral sinuses. There are two on each side. The *superior* runs along the upper portion of the pars petrosa, in the attached border of the tentorium cerebelli; the *inferior*, the larger

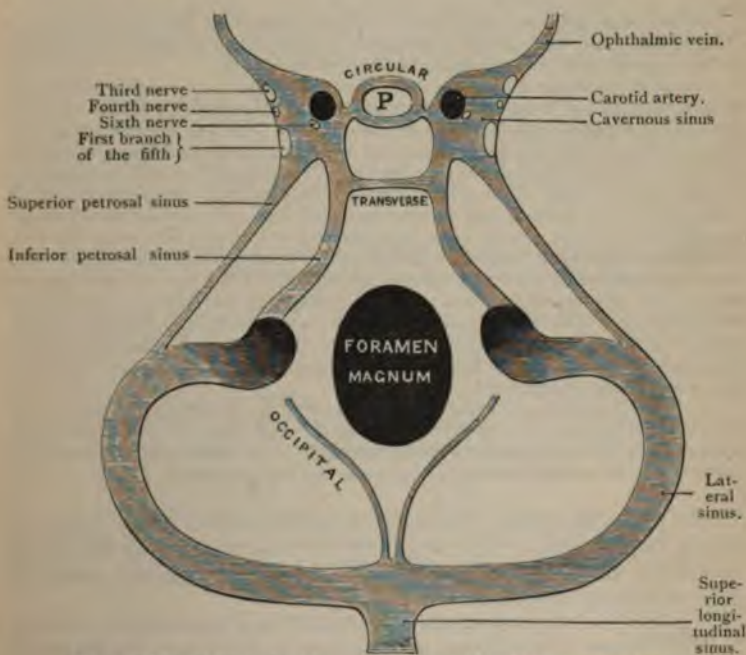


FIG. 7.—DIAGRAM OF THE VENOUS SINUSES AT THE BASE OF THE SKULL.

of the two, runs along the suture between the pars petrosa and the occipital bone, and ends in the lateral sinus just before this terminates in the internal jugular vein. The superior sinus receives the inferior cerebral, the superior cerebellar veins, and a small branch from the tympanum; the inferior sinus is joined by the inferior cerebellar and auditory veins.

Transverse Sinus. This extends from one inferior petrosal to the other, across the basilar process of the occipital bone. It communicates below with the anterior spinal veins.

Occipital Sinuses. These are very small. They commence around the margin of the foramen magnum, run in the falx cerebelli, and uniting to form a single sinus, open into the torcular Herophili. They join inferiorly with the posterior spinal veins.

Meningeal Arteries. These arteries ramify between the skull and the dura mater. Their course may be traced by the grooves which they make in the bones. They are termed *anterior*, *middle*, and *posterior*, from the fossæ in which they ramify.

The *anterior meningeal* are derived from the ethmoidal branches of the ophthalmic artery and the cavernous portions of the internal carotid. They supply the dura mater in the neighbourhood of the ethmoid bone.

The *middle meningeal* are three in number; the most important is the *arteria meningea media*, a branch of the internal maxillary artery. It enters the skull through the foramen spinosum, and divides into two principal branches: one, the anterior, runs in a groove near the anterior border of the parietal bone; the other, the posterior, curves backwards over the temporal bone, and subsequently ramifies on the parietal bone. The artery gives off a small branch—the *petrosal*—which enters the hiatus Fallopii and anastomoses with the stylo-mastoid artery in the aquæductus Fallopii; one or more anastomosing branches which enter the orbit through the sphenoidal fissure to communicate with the ophthalmic artery; and some temporal branches which pierce the sphenoid bone to enter the temporal fossa. It is accompanied by two veins which empty themselves into the internal maxillary vein. The *arteria meningea parva*, which enters the skull through the foramen ovale, and a *meningeal branch* from the ascending pharyngeal artery, which comes up through the foramen lacerum medium, also supply the dura mater and bones of the middle fossa.

The *posterior meningeal* come from the occipital, the ascending pharyngeal, and the vertebral arteries; the two former enter the skull through the foramen jugulare, and the latter through the foramen magnum. The meningeal veins, with the exception of the middle meningeal, open into the various sinuses.

The position of the meningeal arteries renders them liable to injury in fractures of the skull; hence extravasation of blood between the skull and dura mater is one of the common causes of compression of the brain.

Dissection. The student should now examine the cranial nerves as they pass out through the foramina in the base of the skull, and then dissect the cavernous sinus.

Exit of the Cranial Nerves. The cranial nerves proceed in pairs through the foramina at the base of the skull; they are named first, second, third, fourth, &c., pairs, according to the order of succession from before backwards. As they pass through the foramina, each receives a process from the three membranes of the brain, the dura mater, the pia mater, and the arachnoid; the two first are gradually lost upon the nerve, while the arachnoid is reflected back.

The *first* is the *olfactory nerve*. This cannot be seen, because the olfactory bulb has been removed with the brain. From the under

aspect of the bulb proceed about twenty branches, which pass through the foramina in the cribriform plate of the ethmoid bone, and are arranged in three groups—inner, middle, and outer. The *inner* (larger) pass to the septum nasi; the *middle* to the roof of the nose; and the *outer* to the outer wall of the nose as low as the middle turbinated bone.

The *second* (*optic nerve*) passes through the foramen opticum into the orbit accompanied by the ophthalmic artery.

In order to see the next three pairs of nerves, the dura mater must be carefully removed from the side of the body of the sphenoid, and the nerves traced as they pass through the tentorium cerebelli.

The *third* (*motor oculi*) passes through the dura mater, close behind the anterior clinoid process, traverses the outer wall of the cavernous sinus, and enters the orbit through the sphenoidal fissure, where it receives some filaments from the cavernous plexus of the sympathetic.

Before passing through the fissure, it divides into two branches, an upper and a lower, which enter the orbit between the two heads of the external rectus.

The *fourth* (*trochlearis*), a small nerve, passes through the dura mater a little behind the posterior clinoid process. It passes through the outer wall of the cavernous sinus, lying below the preceding nerve and above the first division of the fifth, and then runs forwards through the sphenoidal fissure. Here it lies above the third nerve, and is finally distributed to the superior oblique muscle, on its orbital surface.

In passing through the cavernous sinus it receives some branches from the sympathetic plexus. It also communicates here with the ophthalmic nerve, and sends back a recurrent branch to supply the tentorium cerebelli as far back as the internal occipital protuberance.

The *fifth* (*trifacial*) nerve passes through an aperture in the dura mater beneath a tentorium attached to the elevated margins of the concave surface on the anterior part of the pars petrosa at its apex. It consists of two parts—a larger or sensory root, and a smaller or motor. Upon its larger or sensory root is developed a large ganglion, the *Gasserian ganglion*; while the motor root lies below and unconnected with it. From this ganglion proceed the three primary divisions of the nerve—the *ophthalmic*, which passes through the outer wall of the cavernous sinus below the fourth nerve, and subsequently enters the orbit through the sphenoidal fissure;

While in the cavernous sinus this nerve receives filaments of communication from the cavernous plexus, and also sends back a recurrent branch to supply the tentorium cerebelli (Arnold); the ophthalmic nerve is frequently intimately connected

with a branch of the fourth nerve; it is also connected by a small branch with the sixth nerve;

The *superior maxillary*, which gives off a small recurrent branch

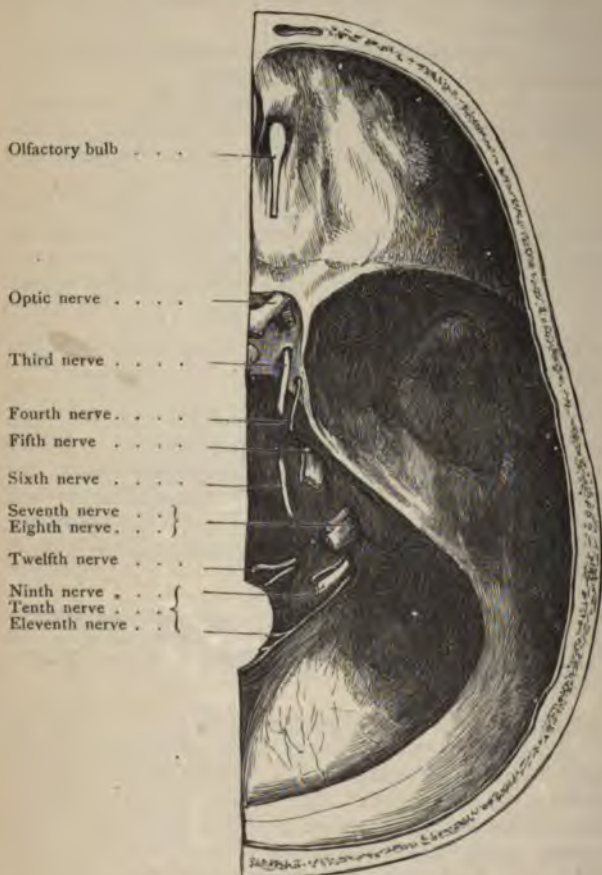


FIG. 8.—DIAGRAM OF THE EXIT OF THE CRANIAL NERVES.

to the dura mater and middle meningeal artery, and then leaves the skull through the foramen rotundum; and the *inferior maxillary*, which passes through the foramen ovale. The smaller or motor root of the fifth lies beneath the ganglion, with which it has

no communication, and then joins the inferior maxillary division to supply the muscles of mastication with motor power.

The *sixth (abducens)* nerve pierces the dura mater behind the body of the sphenoid bone, which it grooves. It then passes along the inner wall of the cavernous sinus, external to the internal carotid artery, and enters the orbit through the sphenoidal fissure to supply the external rectus, between the two heads of which it passes. It is connected, as it passes along the inner wall of the cavernous sinus, with the cavernous plexus, the ophthalmic nerve, and in the orbit with Meckel's ganglion.

The *seventh or facial nerve* passes through the meatus auditorius internus together with the auditory nerve and artery. As it passes along the meatus it is separated from the auditory nerve, upon which it lies, by the portio intermedia. At the bottom of the auditory meatus, the facial nerve leaves the auditory to traverse a tortuous bony canal, the "aquæductus Fallopii." In the meatus auditorius, the facial and the auditory nerves are connected by small filaments.

The *eighth or auditory nerve* passes outwards through the internal auditory meatus in company with the preceding nerve. It is the larger of the two nerves, and lies below the facial, which lies in a groove on this nerve. In the meatus the auditory divides into two branches, cochlear and vestibular.

The *ninth or glosso-pharyngeal nerve* passes through the jugular foramen in front of the pneumogastric and spinal accessory nerves. This nerve has a separate tube of dura mater and arachnoid, and lies in a groove in the lower border of the pars petrosa of the temporal bone together with the two succeeding nerves (Fig. 9).

The *tenth or pneumogastric nerve* emerges through the jugular foramen behind and rather internal to the glosso-pharyngeal. It is enclosed in a common sheath of dura mater with the spinal accessory, but is separated from it by a thin septum of arachnoid membrane.

The *eleventh or spinal accessory* also passes through the foramen jugulare, lying behind the preceding nerve.

The *twelfth or hypoglossal nerve* passes through the anterior condylar foramen, piercing the dura mater by two fasciculi which unite external to the skull.

Dissection.

We must now examine the cavernous sinus, and the nerves which course along its walls to the orbit—namely, the third, the fourth, the ophthalmic division of the fifth and the sixth nerves.

Cavernous Sinus.

This sinus (Fig. 7) lies by the side of the body of the sphenoid bone. In front it receives the ophthalmic vein, which passes backwards through the sphenoid

noidal fissure; while posteriorly it divides into the superior and inferior petrosal sinuses, which have been already described; on the inner side it communicates with the circular sinus, which surrounds the pituitary body (P in Fig. 7). The interior of the

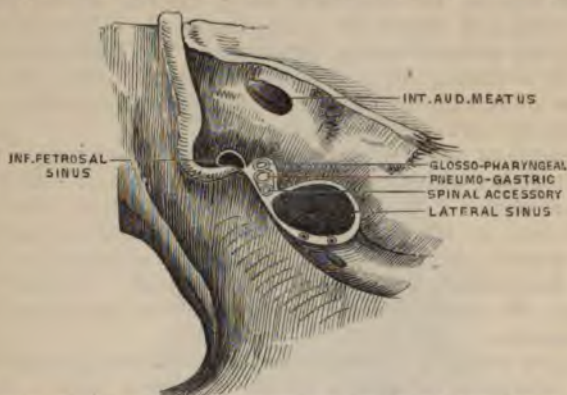


FIG. 9.—DIAGRAM SHOWING THE RELATIONS OF THE VESSELS AND NERVES PASSING THROUGH THE FORAMEN JUGULARE.

sinus is remarkable for the numerous fine bands of reticular tissue which interlace in all directions.

In the outer wall of the cavernous sinus we trace, from above downwards, the third nerve, the fourth, and the ophthalmic division of the fifth, in their course to the orbit. On its inner wall are situated the internal carotid artery with the sixth nerve below and

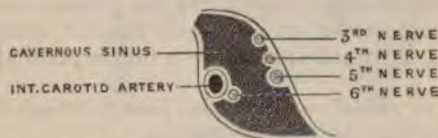


FIG. 10.—RELATION OF THE VARIOUS STRUCTURES PASSING THROUGH THE CAVERNOUS SINUS.

to its outer side. These structures are not actually within the sinus so as to be bathed by the blood, for they are separated from it by the lining membrane of the sinus (Fig. 10).

Relative Positions of Nerves in Sphenoidal Fissure.

These nerves should be traced from the cavernous sinus, forwards, so as to see how they alter their relative positions before entering the sphenoidal fissure, and, again, in their passage through it.

Just before entering the sphenoidal fissure, the fourth nerve (on its way to the orbital surface of the superior oblique) gets above the third, which here divides into an upper and a lower branch (both proceeding to the ocular surface of the muscles they supply); lower still, we have the frontal, lachrymal, and nasal divisions of the

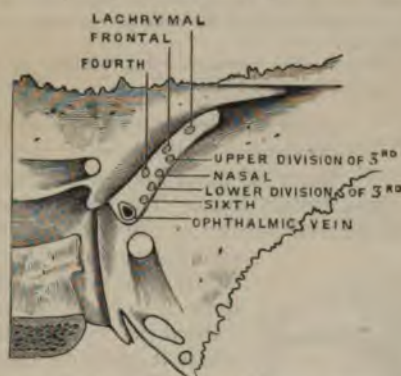


FIG. 11.—DIAGRAM OF THE RELATIONS OF THE NERVES AS THEY PASS THROUGH THE SPHENOIDAL FISSURE.

ophthalmic; lowest of all is the sixth nerve on its way to the external rectus.

In their passage through the sphenoidal fissure, we find that the fourth nerve, the frontal, and lachrymal branches of the ophthalmic,

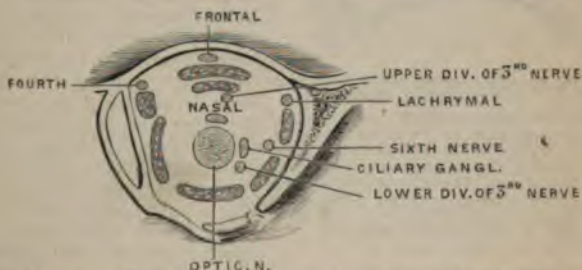


FIG. 12.—RELATIONS OF THE NERVES AND MUSCLES AT THE BACK OF THE ORBIT.

lie at the top, on nearly the same level, and they enter the orbit above the muscles in this order from within outwards. Lower, and in the following order from above downwards, come the upper division of the third, the nasal branch of the ophthalmic, the lower division of the third, and the sixth; all of which (with the ophthal-

mic vein) enter the orbit between the two origins of the rectus externus (Fig. 11).

At the back of the orbit the relation of these nerves is further altered. The fourth, frontal, and lachrymal are still on the same level: the upper division of the third is below the superior rectus, and above the optic nerve is the nasal nerve; the sixth is on the inner side of the external rectus, while the lower division of the third is below and to the outer side of the optic nerve, close to which is the lenticular ganglion (Fig. 12).

The dissector will better remember the varying relations of these nerves when he has learnt their respective destinations.

Curves of the Carotid Artery.

After the removal of the cavernous sinus, a good view is obtained of the curves, like the letter S, made by the internal carotid artery on the side of the pituitary fossa. The vessel enters the cranium at the apex of the petrous portion of the temporal bone, makes its

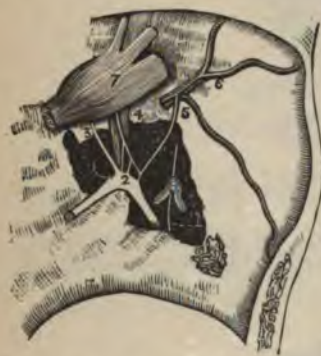

FIG. 13.—THE GENICULATE GANGLION OF THE FACIAL NERVE.

1. The chorda tympani. 2. The geniculate ganglion of the facial nerve. 3. The great petrosal nerve. 4. The lesser petrosal nerve lying over the tensor tympani. 5. The external petrosal nerve communicating with the sympathetic plexus on the arteria meningea media (6).
7. The Gasserian ganglion.

sigmoid curves within the cavernous sinus, and then passes through the dura mater, between the anterior clinoid process and the optic nerve, where it gives off the ophthalmic artery. Within the cavernous sinus, small branches, *arteriæ receptaculi*, arise from the carotid and supply the pituitary body and the walls of the sinus.

A careful dissection would show a plexus of sympathetic nerves on the outer side of the internal carotid artery, as it lies by the side of the body of the sphenoid. This is the CAROTID PLEXUS. It is connected by numerous filaments with the sixth nerve and the Gasserian ganglion. It further furnishes the large deep petrosal nerve which unites with the large superficial petrosal nerve of the facial to form the Vidian; and also the small deep petrosal nerve which joins probably the tympanic plexus. Those filaments of the sympathetic seen on the inner side of the artery in the upper part of the cavernous sinus constitute the CAVERNOUS PLEXUS,

which is in communication with the third, the fourth, and the ophthalmic division of the fifth nerves, and gives a branch to the lenticular ganglion in the orbit.

On removing the Gasserian ganglion, three small nerves are seen lying on the anterior surface of the petrous portion of the temporal bone. One, the *large superficial petrosal nerve*, enters the hiatus Fallopii to join the facial; the second, immediately external to the preceding, is the *small superficial petrosal*, which passes from

the facial to join the otic ganglion; the third, the *external superficial petrosal nerve* (not always present), passes from the facial to communicate with the sympathetic on the middle meningeal artery.

DISSECTION OF THE FACE.

Much practice is required to make a good dissection of the face, and it is well, therefore, to dissect this part before the skin and subjacent structures get dry and discoloured.

The muscles of expression are numerous and complicated; they are interwoven with the subcutaneous tissue and closely united to the skin; their fibres are often pale and indistinct. The face is largely supplied with motor and sensory nerves, of which the ramifications extend far and wide. Therefore you must not be discouraged if, in a first attempt, you fail to make a satisfactory display of the parts.

The cheeks and nostrils should be distended with horse-hair, and the lips sewn together.

Make an incision down the mesial line of the face; another from the chin along the base of the lower jaw to the angle; then prolong it, in front of the ear, to the zygoma. Reflect the skin from below upwards. Each muscle, to be properly cleaned, should be put on the stretch by hooks.

The student is recommended to make out the muscles and arteries on the one side, leaving the other side for the display of the nerves.

The motor nerve which supplies all the muscles of expression in the face is the '*portio dura*,' or facial nerve. It emerges from the stylo-mastoid foramen, and divides into branches, which pass through the parotid gland, forming a plexus termed the '*plexus anserinus*.'

The sensory nerves of the face are chiefly derived from the three divisions of the fifth cranial nerve; namely, the supra-orbital, the supra-trochlear, the lachrymal, the infra-trochlear, and naso-lobular, which latter supply the ala and the tip of the nose; the three sets of branches from the infra-orbital; and the mental. The other nerves which confer sensation upon the face are the great auricular branch of the cervical plexus, which supplies the skin covering the parotid gland and part of the cheek.

It is convenient to arrange the muscles of the face under three groups; appertaining, respectively, to the mouth, the nose, the eyebrows, and lids. Begin with those of the mouth.

The muscles of the mouth are arranged thus: there is an orbicular or sphincter muscle surrounding the lips; from this, as from a common centre, muscles diverge and are fixed into the surround-

ing bones. They are named elevators, depressors, sphincters, etc., according to their respective action.

Musculus Risorius
(Santorini).

This muscle is usually considered as a part of the *platysma myoides*, the large subcutaneous muscle of the neck. It arises by thin fasciculi from the fascia over the masseter muscle, and passes horizontally forwards to be inserted into the angle of the mouth, where it intermingles with the *orbicularis oris* and *depressor anguli oris*. It produces the smile, not of good-humour, but of derision.

Orbicularis Oris.

This muscle, nearly an inch in breadth, surrounds the mouth, forming a kind of sphincter. Its size and thickness in different individuals produce the variety in the prominence of the lips. Observe that its fibres, except the most internal, do not surround the mouth in one unbroken series, but that those of the upper and lower lip decussate at the angles of the mouth, and intermingle with the fibres of the *buccinator* and other muscles which converge from different parts of the face.

The *orbicularis* consists of two parts, an inner or *labial* part, and an outer or *facial*; the difference in appearance of the fibres being very marked. The *labial* part consists of pale, thin fibres, forming more or less of the inner part of the *orbicularis*, and has no attachment to bone; the *facial* part is thinner but broader, and besides being connected with other muscles, is attached to bone thus: in the upper lip by two fasciculi on each side, one to the *septum nasi*, the other to the alveolar border opposite the incisor teeth; in the lower lip by a single fasciculus to the lower jaw on each side opposite the canine tooth. The cutaneous surface of the muscle is intimately connected with the lips and the surrounding skin; the deep surface is separated from the mucous membrane by the labial glands and the coronary vessels.

The *orbicularis* is the antagonist of all the muscles which move the lips. Upon a nice balance of their opposite actions depends the play and infinitely varied expression of the mouth.*

Depressor Anguli
Oris.

This muscle *arises* broadly from the oblique line of the lower jaw behind the *foramen mentale*, and is *inserted* narrowly into the angle of the mouth, intermingling with the *zygomatici*, the *risorius*, and *orbicularis oris*. It is an important muscle in the expression of sorrowful emotions. We see its action when children cry.

* In strong muscular lips the upper part of the *orbicularis* sends a small subcutaneous slip of muscle from each side along the *septum nasi* nearly to the apex. The interval between the two slips corresponds to the furrow which leads from the nose to the lip. This is the *naso-labialis* or *depressor septi narium* of Haller and Albinus.

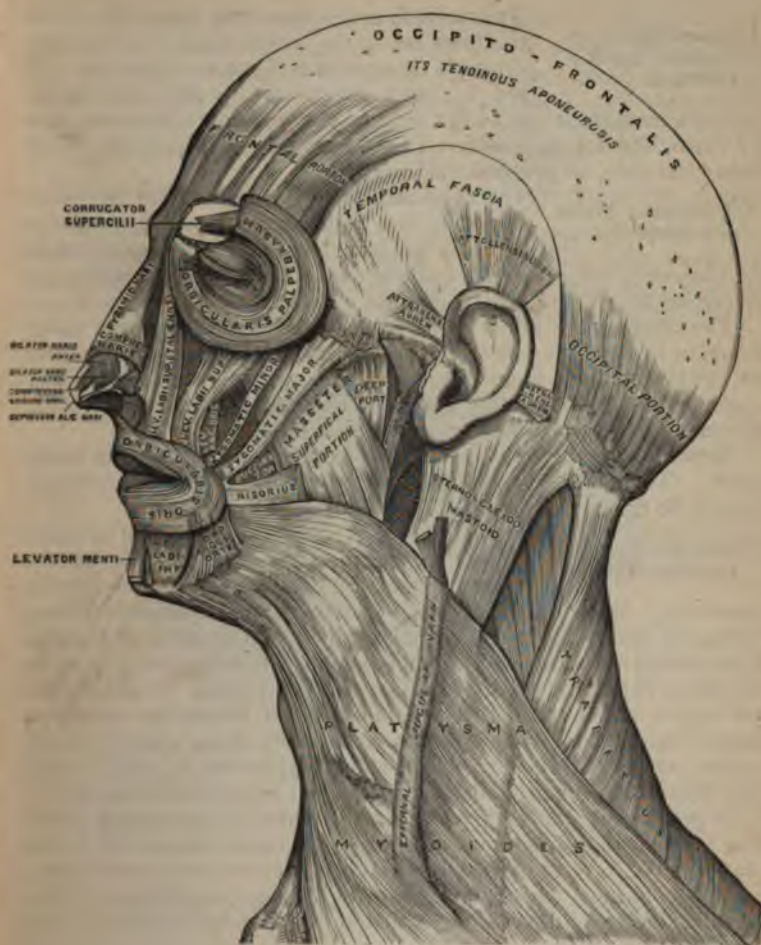


FIG. 14.

Depressor Labii Inferioris, or Quadratus Mentis.

This muscle *arises* from the oblique line of the lower jaw below the foramen mentale, and is *inserted* into the lower lip, its fibres intermingling with those of its fellow of the opposite side and the orbicularis. It covers the vessels and nerves which emerge from the foramen.

**Levator Mentis, or
Levator Labii
Inferioris.**

This muscle *arises* from the lower jaw, from the fossa below the incisor teeth, and, passing down, is *inserted* into the skin of the chin. To see it, evert the lower lip and remove the mucous membrane on either side of the frænum. There are two of them, one for each side. Their action is well seen when we shave the chin, or protude the lower lip.

**Zygomaticus Major
and Minor.**

The zygomaticus major *arises* from the outer surface of the malar bone close to its suture with the zygoma, passes obliquely downwards and inwards, and is *inserted* into the angle of the mouth, joining the depressor anguli and orbicularis oris.

The zygomaticus minor *arises* from the outer surface of the malar bone, in front of the preceding, and is *inserted* into the outer border of the levator labii superioris near the corner of the mouth. The zygomaticus minor is often absent. The zygomaticus major is the muscle of laughing: the minor expresses sadness.

Before examining the orbicularis palpebrarum, notice the tendo oculi. To make the tendon more apparent, the tarsal cartilages should be drawn outward.

**Tendo Oculi or
Palpebrarum.**

This tendon is a thin cord about 4 mm. ($\frac{1}{8}$ in.) in length, and is readily felt at the inner angle of the eye by drawing the eyelids outwards. It is fixed to the nasal process of the superior maxillary bone, in front of the lachrymal groove, is U-shaped, and passes horizontally outwards; one limb is attached to the upper, the other to the lower tarsal cartilage. The tendon crosses the lachrymal sac a little above the centre, and furnishes a tendinous expansion which covers the sac and is attached to the margin of the bony groove which contains it. To see this expansion we must reflect that portion of the orbicularis palpebrarum which covers the sac.

In puncturing the lachrymal sac the knife is introduced below the tendon, in a direction downwards, outwards, and a little backwards. We have to divide the skin, a few fibres of the orbicularis, and the fibrous expansion from the tendo palpebrarum. The angular artery and vein are situated on the inner side of the incision.

**Orbicularis Palpe-
brarum.**

This thin, broad muscle surrounds the margin of the orbit and the eyelids, forming a sphincter. It is attached on the inner side to the tendo palpebrarum, to the nasal process of the superior maxillary bone, to the internal angular process of the frontal bone, and to the lower margin of the orbit. From this attachment the fibres form a series of oval curves, taking a wide sweep, and pass uninterruptedly round the eyelids and orbit.

The fibres which belong to the eyelids (*orbicularis palpebrarum*) are thin and pale, and form, over each eyelid, a series of elliptical curves which meet at the external canthus of the lids, and are loosely attached to the external tarsal ligament. The degree of their curvature becomes less as they approach the margin of the lids, so that some fibres proceed close to the lashes.

This was first pointed out by Riolanus,* and described as the *musculus ciliaris*.†

The fibres which spread over the orbital margins (*orbital portion*) are thicker and redder, and mingle, on the forehead, with the occipito-frontalis and corrugator supercillii, on the cheek, with the elevators of the upper lip and nose and the zygomaticus minor.

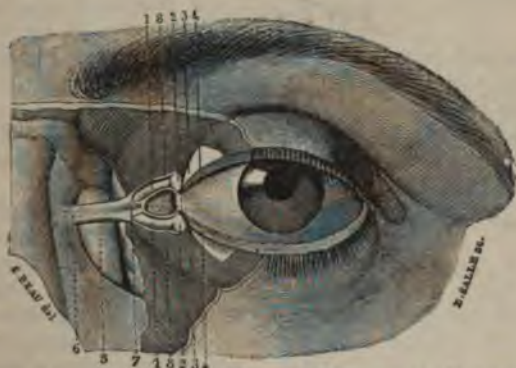


FIG. 15.—TENDON OF THE ORBICULARIS PALPEBRARUM, SHOWING THE UNION OF THIS TENDON WITH THE LACHRYMAL SAC AND THE LACHRYMAL CANALS. (Sappey.)

1. Lachrymal canals. 2, 2. Commencement of these canals in the lids. 3, 3. Internal extremity of the tarsal cartilages. 4, 4. Free border of the lids. 5. Lachrymal sac. 6. Attachment of the tendo oculi to the nasal process of the superior maxillary. 7. The division of the tendo oculi into its two branches. 8, 8. The two branches ensheathing the two lachrymal canals and attached to the internal extremity of the tarsal cartilages.

No fat is found on the eyelids; nothing intervenes between the skin and the muscles but loose connective tissue, that there may be no impediment to the free play of the lids.

The orbicular muscle not only closes the eyelids but protects the eye. When the eye is threatened, the muscle suddenly contracts, presses the eye back into the orbit, and contracts the skin of the

* *Anthropologia*, lib. v., cap. 10.

† Strictly speaking, the *musculus ciliaris* arises from the two little divisions of the tendo oculi, and is inserted at the external canthus, into the fibrous tissue which unites the two tarsal cartilages.

brow and cheek so as to form a soft cushion in front of it. The cushion itself may be severely bruised, as is seen in a "black eye;" but the globe itself is rarely injured. When the eye is closed, as in winking, the palpebral portion of the muscle contracts. Observe this movement, and notice that the lids are drawn slightly inwards as well as closed. The object of this inward motion is to direct the tears towards the inner angle of the eyelids, where they are absorbed by the *puncta lachrymalia*.

The *tensor tarsi* muscle is described in the dissection of the orbit.

Since the orbicular muscle is supplied by the facial nerve, it is affected in facial palsy, and the patient cannot close the lids.

Corrugator Supercilii.

This *arises* from the inner end of the superciliary ridge of the frontal bone, and is *inserted* into the under surface of the orbicularis palpebrarum and occipito-frontalis. It lies concealed beneath these two muscles, and is the proper muscle of frowning. Its nerve is derived from the facial.

The present being a good opportunity to examine the appendages (*tutamina oculi*) of the eyes, postpone for the present the dissection of the remaining muscles of the face.

The Eyelids.

The *eyelids* are two moveable elliptical folds consisting of strata of different tissues. The *upper lid* is large and more moveable than the *lower*, so that when the eye is closed, it is mainly by this fold. The interval between the two lids is called the *fissura palpebrarum*, which terminates on the inner and outer sides in two angles, the *canthi*. The lids are thickest at their borders, are somewhat curved, and near the inner canthus each presents a slight elevation, the *papilla lachrymalis*, at the top of which is a small opening, the *punctum lachrymale*; this is the commencement of a small canal, *canaliculus*, which receives the tears and conveys them to the lachrymal sac, and thence through the nasal duct to the nose. At the inner canthus the two lids are separated by an oval space, the *lacus lachrymalis*, where the mucous membrane is raised into a rounded eminence, the *caruncula*.

Caruncula

Lachrymalis.

The *caruncula lachrymalis* is the red rounded eminence situated at the inner canthus and formed by the conjunctiva. It is composed of an aggregation of sebaceous and sweat glands covered by mucous membrane; on the surface of it are minute hairs.

Resting upon the eyeball external to the caruncle is a slight vertical triangular fold of conjunctiva, *plica semilunaris*, which is the rudimentary *membrana nictitans* (the third eyelid found in birds). Both in the caruncle and *plica semilunaris* unstriped muscular tissue has been demonstrated.

The *conjunctiva* is the mucous membrane which covers the inner surface of the lids and the front of the eyeball. The portion lining the lids is termed the *palpebral*; that portion covering the front of the eye, the *ocular*. The angle of its reflection from the lids to eyeball is called the *fornix conjunctivæ*, where are situated a number of racemose glands; there is also some lymphoid tissue found in other parts of the conjunctiva. The palpebral conjunctiva is more vascular than the ocular, and it presents a number of minute papillæ, which, when enlarged and aggregated by inflammation, give rise to the disease called "granular lids." The conjunctiva will be more fully described with the anatomy of the eye.

The *eyelashes* (cilia) are placed in two or more rows along the edges of the tarsal cartilages. The eyelashes of the upper lid are longer and more numerous than in the lower; and their convexity is directed downwards, while those of the lower lid present an opposite curve. The bulbs of the lashes are situated between the tarsal cartilage and the fibres of the orbicularis palpebrarum. They are supplied with blood by the palpebral branches of the ophthalmic artery, which run parallel and close to the free borders of the lids beneath the orbicular muscle.

Structure of the Eyelids.

The *eyelids* are composed of different tissues, arranged in successive strata one beneath the other. They are—1. The *skin*; 2. The *orbicularis palpebrarum*; 3. The *palpebral ligament*, which extends from the margin of the orbit to the cartilage; 4. The expanded *tendon of the levator palpebræ* (in the upper lid only); 5. The *tarsal cartilage*; 6. A thin *layer of fascia*, in which are seen the blood-vessels; 7. The *Meibomian glands*, which lie embedded in the tarsal cartilage; 8. *Conjunctiva*. These structures are severally connected by areolar tissue, which never contains fat.

Such, in outline, is the structure of the eyelids. Their use is best described by Socrates, who, in answer to the question whether animals were made by chance or design, replies: "Think you not that it looks like the work of *forethought*, because the sight is delicate, to guard it with eyelids as with shutters, which open when we want to see, and shut during sleep; and, that even winds may not hurt them, to make eyelashes in the lids for a sieve; and to furnish the parts over the eyes with eyebrows, as with eaves, so that even the sweat from off the head may do them no mischief?"*

The *skin* of the eyelids is remarkably smooth and delicate, and destitute of fat. It is abundantly supplied with sensory nerves by branches of the fifth pair—namely, by the supra-orbital, supra-trochlear, infra-trochlear, lachrymal, and infra-orbital nerves.

* Xenophon's *Memorabilia*, b. 1, c. vi., § 6.

The *orbicularis palpebrarum* has been already described (p. 48). It is supplied by the facial nerve.

The *levator palpebræ* arises from the lesser wing of the sphenoid above the optic foramen, gradually becomes broader, and terminates in a thin aponeurosis, which unites with the broad tarsal ligament, and is lost on the upper surface of the superior tarsal cartilage.

**Tarsal Cartilages
and Ligaments.**

These are plates of dense connective tissue, which support and give shape to the eyelids. There is one for each lid, and they are connected at the angles (*commissures* or *canthi*) of the lids through the medium of fibrous tissue. They can best be examined by everting

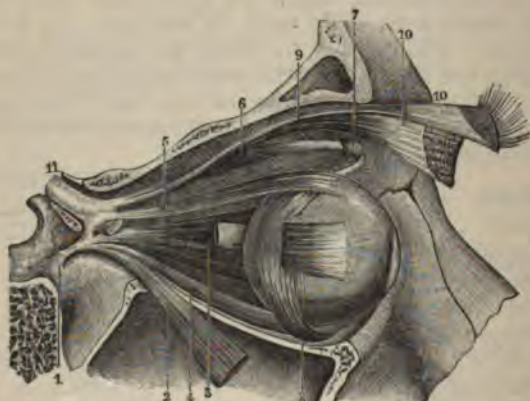


FIG. 16.—MUSCLES OF THE EYE. LIGAMENT OF ZINN.

1. Attachment of the ligament of Zinn—showing the three tongue-like projections, from its annular parts surrounding the optic nerve, to the internal, external, and inferior recti muscles. 2. External rectus, incised and deflected downwards to show the internal rectus. 3. Internal rectus. 4. Inferior rectus. 5. Superior rectus. 6. Superior oblique. 7. Pulley for the superior oblique muscle. 8. Inferior oblique. 9. Levator palpebræ. 10. Portion of the orbicularis palpebrarum. 11. Optic nerve.

the lids. Each cartilage resembles its lid in form. The upper is the larger, is broad in the middle, and gradually becomes narrower at either end. The lower is nearly of uniform breadth throughout. Both are thicker on the nasal than on the temporal side. They are connected to the margin of the orbit, and maintained in position by the *broad tarsal* or *palpebræ ligament*; this is a continuation from the periosteum of the orbit to the tarsal cartilage, and is denser at the outer part of the orbit. There are two of them—upper and lower—and they pass to each cartilage respectively.

When an abscess forms in the connective tissue of the lids, these ligaments prevent the matter from making its way into the orbit.

Each tarsal cartilage is attached on its outer side to the malar bone by the external tarsal ligament, and on its side to the nasal process of the superior maxillary by the tendo palpebrarum or the internal tarsal ligament.

The free or ciliary margin is straight, and is the thickest part of the tarsal cartilages. It is generally stated that the inner edge of each is sloped or bevelled off; and that, when the lids are closed, there is formed, with the globe of the eye, a triangular channel. This channel is said to conduct the tears to the puncta lachrymalia. According to our observation, this channel does not exist; for when the lids are closed, their margins are in such accurate apposition, that not the slightest interspace can be discovered between them.

Puncta Lachrymalia. The *puncta lachrymalia* are two pin-hole apertures, easily discovered on the margin of the lids, close to the inner angle. They are the orifices of the canals, called *canaliculi*, which pass inwards and convey the tears into the lachrymal sac.

Observe that their orifices are directed backwards. The upper canaliculus, the longer and narrower of the two, ascends for a short distance nearly vertically, and then dilating into a small pouch makes a sharp bend inwards for about a quarter of an inch to join the lachrymal sac; the lower canal descends perpendicularly, and, like the upper, makes a sharp bend, after which it pursues a direction upwards and inwards to the sac.

The two canals open separately into the sac (sometimes by a common orifice). In facial palsy, the tensor tarsi being affected, the puncta lose their proper direction, and the tears flow over the cheek.

In the introduction of probes for the purpose of opening the contracted puncta, or of slitting up the lachrymal ducts, it is necessary to know the exact direction of these canals. (Fig. 17.) When from any cause the tears are secreted in greater quantity than usual, they overflow and trickle down the cheek.

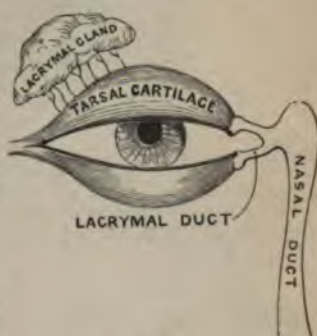

FIG. 17.

Meibomian Glands. These long compound sebaceous glands, so called after the anatomist* who first described them, are situated on the under surface of each of the tarsal cartilages. In the upper lid there are between twenty and thirty; not quite so many in the lower. On everting the lid, they are seen running in longitudinal parallel rows in grooves in

* H. Meibom.

the cartilage. Under the microscope, each is seen to consist of a straight central tube, round the sides of which are a number of openings leading to short cæcal dilatations. The orifices of these glands are situated on the free margin of the lids behind the lashes. They are lined with flattened epithelial cells which, in the cæcal dilatations and ducts, become cubical and filled with fat. Their function is to secrete a sebaceous material, which prevents the lids from sticking together.

Tensor Tarsi.

This muscle is only a deeper part of the orbicularis palpebrarum, and lies just behind the tendo palpebrarum. To expose it, cut perpendicularly through the middle of the upper and lower lids, and turn the inner halves towards the nose. After removing the mucous membrane, the muscle will be seen *arising* from the ridge of the

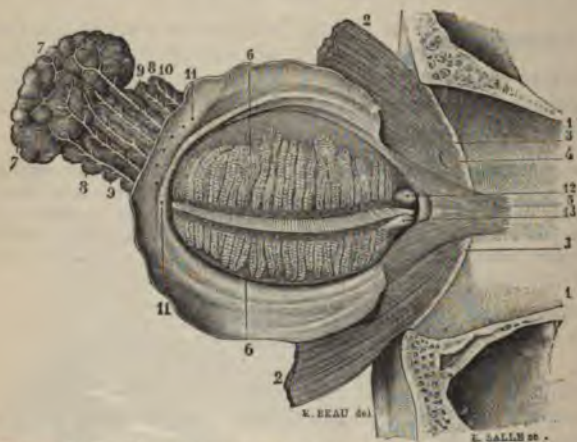


FIG. 18.—TENSOR TARSI—ATTACHMENT OF THE ORBICULARIS PALPEBRARUM TO THE INNER PART OF THE BASE OF THE ORBIT. (*Sappey*.)

- 1, 1. Inner wall of the orbit. 2, 2. Internal part of the orbicularis palpebrarum. 3, 3. Attachment of this muscle to the circumference of the base of the orbit. 4. Opening for the nasal artery. 5. Tensor Tarsi. 6, 6. Posterior view of the lids. 7, 7. Orbital portion of the lachrymal gland. 8, 9, 10. Palpebral portion of this gland. 11, 11. Mouths of its excretory ducts.

lachrymal bone. It passes nearly horizontally outwards for about 6.5 mm., or $\frac{1}{4}$ inch, and then divides into two portions, which are *inserted* into the upper and lower tarsal cartilages, close to the orifices of the lachrymal ducts. It is probable that the tensor tarsi draws backwards the open mouths of the ducts, so that they may receive the tears at the inner angle of the eye. It is supplied by a small branch from the facial nerve.

Let us now examine the muscles in connection with the nose : namely—the pyramidalis nasi, the compressor naris, the depressor

alæ nasi, and the smaller intrinsic muscles of the nose. All are supplied by the facial nerve.

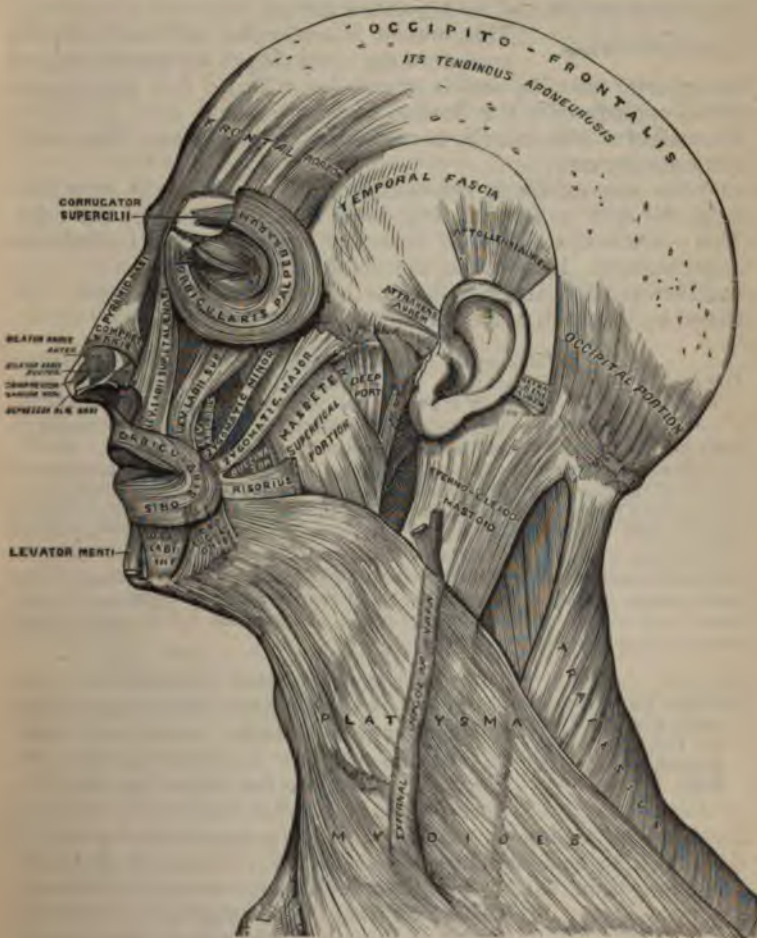


FIG. 19.

Pyramidalis Nasi.

This is situated on the bridge of the nose, one on each side of the mesial line, and is usually regarded as a continuation of the inner part of the occipito-

frontalis. The two muscles diverge as they descend, and their fibres blend with those of the compressor naris. Their action produces transverse wrinkles of the skin at the root of the nose, as in the expression of an aggressive feeling.

Compressor Naris.

This muscle is triangular, and *arises* by its apex from the inner side of the canine fossa of the superior maxilla, and is *attached* to a broad thin aponeurosis which spreads over the dorsum of the nose, and joins its fellow. The origin of this muscle is concealed by the levator labii superioris alæque nasi.

When this muscle is reflected from its junction with its fellow, a small nerve is seen running down towards the tip of the nose. This nerve is the *superficial branch* of the nasal nerve (called also *naso-lobular*). It becomes subcutaneous between the nasal bone and the cartilage, and supplies the tip and lobule of the nose. It is joined by a branch of the facial nerve at its termination.

**Depressor Alæ
Nasi.**

This *arises* from the superior maxilla, above the second incisor tooth, and is *inserted* into the septum and ala of the nose. It is situated between the mucous membrane and the muscular structure of the upper lip; so that, to expose it, the upper lip must be everted, and the mucous membrane removed.

Besides the muscles above described, we find in connection with the cartilages of the alæ of the nose, pale muscular fibres which have no very definite arrangement and require a lens for their detection. The *dilatator naris posterior* arises from the nasal process of the superior maxilla and the sesamoid cartilages, and is inserted into the skin of the margin of the nostril; the *dilatator naris anterior* descends vertically from the cartilage of the aperture to its free margin. The action of these small muscles is to raise and evert the ala of the nose, and to counteract its tendency to be closed by atmospheric pressure. In dyspnoea, and in certain mental emotions, they contract with great energy.

Levator Labii Superioris Alæque Nasi, or Levator Labii Superioris et Alæ Nasi.

This *arises* from the nasal process of the superior maxillary bone near its orbital margin, and passing downwards divides into two portions: an inner *inserted* into the side of the ala of the nose; an outer, into the upper lip, where its fibres blend with the orbicularis oris and levator labii superioris. It acts chiefly in expressing the smile of derision. Its habitual use occasions the deep furrow which, in most faces, runs from the ala of the nose towards the corner of the mouth.

Levator Labii Superioris Proprius.

This *arises* from the lower margin of the orbit, *i.e.*, from the superior maxilla and malar bone, above the infra-orbital foramen, and is *inserted* into the upper lip, where its fibres blend with the orbicularis oris. It is nearly an inch in breadth at its origin, which covers the infra-orbital vessels and nerves, and is itself overlapped by the orbicularis palpebrarum.

Levator Anguli Oris. This muscle, which is covered by the levator labii superioris, *arises* from the canine fossa of the superior maxilla, below the infra-orbital foramen, and is *inserted* into the angle of the mouth, superficial to the buccinator, its fibres blending with those of the orbicularis oris, the zygomatici, and the depressor anguli oris.

Buccinator. The buccinator *arises* from the outer surface of the alveolar borders of the upper and lower jaws corresponding to the molar teeth, and behind from the pterygo-maxillary ligament. The fibres pass forwards and converge, to be inserted into the angle of the mouth and the muscular structure of the lips; the central fibres decussate, while the upper fibres pass to the upper lip, and the lower fibres pass to the lower lip. The muscle is covered on its inner aspect by the mucous membrane of the cheek, and on its outer by a thin fascia which passes backwards, and is continuous with that covering the pharynx.

The buccinator is the principal muscle of the cheek. It forms with the superior constrictor of the pharynx a continuous muscular wall for the side of the mouth and pharynx. The bond of connection between the buccinator and the superior constrictor is a tendinous band, the *pterygo-maxillary ligament*. This ligament (Fig. 20) extends from the hamular process vertically to the posterior extremity of the mylo-hyoid ridge of the lower jaw near the last molar tooth. It is simply a fibrous intersection between the two muscles.

The duct of the parotid gland pierces the buccinator obliquely, and opens into the mouth opposite the second molar tooth of the upper jaw.

The chief use of the buccinator is to keep the food between the teeth during mastication. It can also widen the mouth. Its power of expelling air from the mouth, as in whistling or playing on a wind instrument, has given rise to its peculiar name. It is supplied by the facial nerve, and is, therefore, affected in facial paralysis.

The buccinator is in relation, externally and behind, with a large amount of buccal fat, with the masseter and temporal muscles; in front with the risorius, the levator anguli oris, depressor anguli oris, the zygomatici, the duct of the parotid gland, the facial artery and vein, and the facial and buccal nerves; internally with the mucous membrane of the mouth and buccal glands; and posteriorly with the pterygo-maxillary ligament.

Buccal Fascia. The buccinator muscle is covered by a thin layer of fascia, which adheres closely to its surface, and is attached to the alveolar border of the upper and lower jaws. This structure is thin over the anterior part of the muscle, but more dense behind, where it is continuous with the aponeurosis of the pharynx. It is called the

bucco-pharyngeal fascia, since it supports and strengthens the muscular walls of these cavities. In consequence of the density of this fascia, abscesses do not readily burst into the mouth or the pharynx.

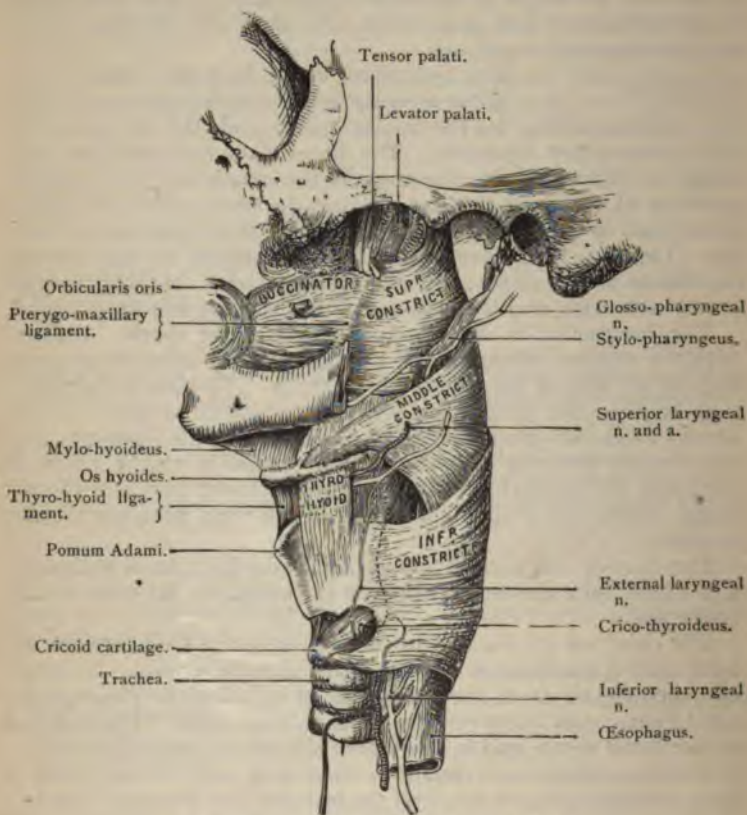


FIG. 20.—MUSCLES OF THE PHARYNX.

Buccal and Molar Glands.

The *buccal* glands, in structure compound racemose like the salivary, are situated between the buccinator and the mucous membrane. They resemble the labial glands found beneath the mucous membrane of the lips, though somewhat smaller. Three or four other glands, about the size of a little split pea, should be made out, as they lie between the masseter and buccinator; these are the *molar* glands. Their secretion, said to be mucous, is conveyed to the mouth by separate ducts near the last molar teeth.

Between the buccinator and the masseter, there is, in almost all subjects, an accumulation of fat. It is found, beneath the zygoma especially, in large round masses, and may be turned out with the handle of the scalpel. It helps to fill up the zygomatic fossa, and being soft and elastic, presents no obstacle to the free movements of the jaw. Its absorption in emaciated individuals occasions the sinking of the cheek.

Facial Artery. The *facial* (external maxillary) artery is the third branch of the external carotid. It ascends tortuously beneath the posterior belly of the digastricus and the stylo-hyoideus, next *through* or under the substance of the submaxillary gland; it then rests upon the mylo-hyoideus, and subsequently mounts over the base of the jaw at the *anterior edge of the masseter* muscle. This part of the course of the facial will be fully examined further on in the dissection of the neck. It now ascends tortuously near the corner of the mouth and the ala of the nose, towards the inner angle of the eye, where, much diminished in size, it inosculates with the terminal branch of the ophthalmic, a branch of the internal carotid. In the first part of its course on the face, the artery is covered by the platysma and the deep fascia; above the corner of the mouth it is crossed by a few fibres of the risorius and the zygomatici; still higher it is covered by some of the fibres of the elevator of the upper lip.* It lies successively upon the buccinator, levator anguli oris, and levator labii superioris alæque nasi muscles. In its course along the face it gives off the following branches:—

a. The inferior labial artery passes inwards under the depressor anguli oris and inosculates with the mental branch of the inferior dental, the inferior coronary, and the submental arteries.

b. The inferior coronary artery comes off near the angle of the mouth, either directly from the facial, or in common with the superior coronary. It runs tortuously along the lower lip, beneath the depressor anguli oris; it then pierces the orbicularis, running between this muscle and the mucous membrane of the lip. It inosculates largely with its fellow, the inferior labial and the mental arteries.

c. The superior coronary, larger than the preceding, is given off beneath the zygomatici. It proceeds along the upper lip close to the mucous membrane, and inosculates with its fellow; thus is formed round the mouth a complete arterial circle, which can be felt pulsating on the inner side of the lip, near the free border. From this circle numerous branches pass off to the papillæ of the lips and the labial glands. The superior coronary gives off a branch, *the artery of the septum*, which ascends along the septum to the apex of the nose; also a small one to the ala nasi.

d. The lateral artery of the nose, a branch of considerable size, arises opposite the ala nasi, ramifies upon the external surface of the nose, and inosculates with the nasal branch of the ophthalmic artery, the infra orbital, and the artery of the septum.

* Not infrequently the artery lies superficial to this muscle.

ε. The **angular artery**, which may be regarded as the termination of the facial, inosculates on the inner side of the tendo-palpebrarum with the nasal branch of the ophthalmic artery.

The facial artery supplies numerous branches to the muscles of the face, and inosculates with the transversalis faciei, infra-orbital,

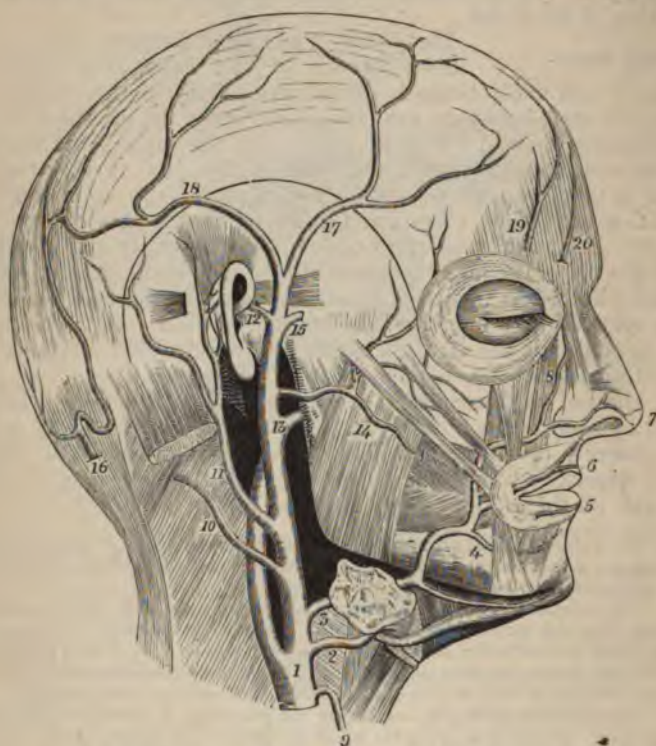


FIG. 21.—BRANCHES OF THE EXTERNAL CAROTID ARTERY.

1. External carotid. 2. Lingual. 3. Facial. 4. Inferior labial. 5. Inferior coronary. 6. Superior coronary. 7. Lateral nasal. 8. Angular. 9. Superior thyroid. 10 and 16. Occipital. 11. Posterior auricular. 12. Anterior auricular. 13. Internal maxillary. 14. Transverse facial. 15. Middle temporal. 17. Anterior temporal. 18. Posterior temporal. 19. Supra-orbital. 20. Frontal.

the mental, the sublingual branch of the lingual, the nasal branches of the internal maxillary and the ophthalmic, the ascending pharyngeal and descending palatine arteries.

The facial artery and its branches are surrounded by a minute plexus of nerves (*nervi molles*) invisible to the naked eye. They

are derived from the superior cervical ganglion of the sympathetic, and exert a powerful influence over the contraction and dilatation of the capillary vessels, and thus occasion those sudden changes in the countenance indicative of certain mental emotions, *e. g.*, blushing or sudden paleness.

The **facial vein** does not run with the artery, but takes a straight course from the inner angle of the eye to the anterior border of the masseter. In this course it descends upon the levator labii superioris, then passes beneath the zygomatic muscles, over the termination of the parotid duct, and at the anterior border of the masseter passes over the jaw, behind the facial artery, and joins the internal jugular.

The facial vein is a continuation of the frontal, which descends over the forehead, and, after receiving the supra-orbital, takes the name of *angular* at the corner of the eye. It communicates with the ophthalmic vein, receives the veins of the eyelids, the external part of the nose, the coronary veins, and others from the muscles of the face. Near the angle of the mouth it is increased in size by a communicating branch from the infra-orbital vein, and by a large vein which comes from the temporo-maxillary vein. The other veins which empty themselves into the facial correspond with the branches given off from the facial artery.

**Arteria Transversalis
Faciei.**

This artery arises from the temporal, or occasionally from the external carotid in the substance of the parotid gland. It runs forwards across the masseter between the parotid duct and the zygoma, and is distributed to the glandula socia parotidis, and the masseter. It anastomoses with the infra-orbital, buccal, and facial. It is seldom of large size, except when it supplies those parts which usually receive blood from the facial. We have seen it as large as a goose-quill, furnishing the coronary and the nasal arteries, the facial itself not being larger than a sewing-thread.

The parotid gland is now to be examined. Its boundaries, its deep relations, the course of its duct, and the objects contained within the gland, must be carefully observed.

Parotid Gland.

The parotid, the largest of the salivary glands, occupies the space between the ramus of the jaw and the mastoid process, and weighs between five and eight drachms (20 to 32 gm.). It is bounded above by the zygoma; below, by the sterno-mastoid and digastric muscles; behind, by the meatus auditorius externus and the mastoid process; in front, it lies over the ascending ramus of the jaw, and is prolonged for some distance over the masseter. It is separated from the submaxillary gland by the stylo-maxillary ligament; sometimes the two glands are directly contiguous.

The superficial surface of the gland is flat, and covered by a

strong layer of fascia, a continuation of the cervical, and has one or two lymphatic glands lying on it.

It not only surrounds the gland, but sends down numerous partitions which form a framework for its lobes. The density of this sheath explains the pain caused by inflammation of the gland, the tardiness with which abscesses within it make their way to the surface, and the propriety of an early opening.

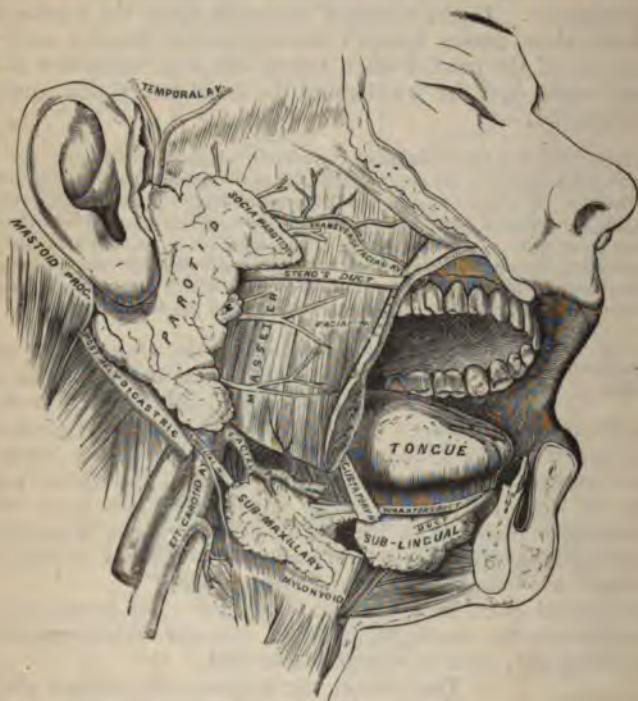


FIG. 22.

The deep surface of the gland is irregular, and moulded upon the subjacent parts.

Thus it sends a prolongation which passes inwards between the neck of the jaw and the internal lateral ligament; another process which passes in front of the styloid process, and extends upwards and occupies the posterior part of the glenoid cavity; a third process passes behind the styloid process, below the mastoid process and behind the sterno-mastoid muscle, and sometimes penetrates deep enough to be in contact with the internal jugular vein.

The internal carotid artery and internal jugular vein are in contact with the gland behind.

On carefully removing the substance of the parotid gland, the following structures are seen in its interior, proceeding in the order of their depth from the surface:—

1. Two or more small lymphatic glands.
2. The pes anserinus, or primary branches of the facial nerve, which emerge at its anterior border.
3. Branches from the great auricular and auriculo-temporal nerves which communicate in its substance with the facial nerve.
4. The external jugular vein formed by the junction of the internal maxillary and temporal veins.
5. The external carotid artery, which, after distributing many branches to the gland, divides, opposite the neck of the jaw, into the internal maxillary and temporal, the latter giving off in the gland the posterior auricular and transverse facial arteries.

That portion of the gland which lies on the masseter muscle is called *glandula socia parotidis*. It varies in size in different subjects; and is situated chiefly above the parotid duct, into which it pours its secretion by one or two smaller ducts.

The *duct* of the parotid gland (ductus Stenonis*), about two inches and a half (6.5 c. m.) long, 3 mm. in diameter, is very thick and strong. In this respect it differs from the duct of the submaxillary gland, which is less exposed to injury. The volume of the parotid is 26 c. cm., its weight is 6.75 drachms (27 gm.). It runs transversely forwards over the masseter, about an inch (2.5 c. m.) below the zygoma, through the fat of the cheek, then perforates the buccinator obliquely, and opens into the mouth opposite the second molar tooth of the upper jaw. Near its termination it is crossed by the zygomaticus major and the facial vein. After perforating the buccinator, the duct passes for a short distance between the muscle and the mucous membrane. Its orifice is small and contracted compared with the diameter of the rest of the duct, which will admit a crow-quill; it is not easily found in the mouth, being concealed by a fold of mucous membrane.

The direction of the parotid duct corresponds with a line drawn from the middle of the lobule of the ear to a point midway between the nose and the mouth.

The blood supply of the parotid is derived from the external carotid and its branches, which are accompanied by their respective veins. Its nerves are supplied from the sympathetic plexus around the external carotid, the auriculo-temporal, the great auricular, and the facial nerves.

* Nic. Steno, *De Glandulis Oris, etc.* Bat. 1661.

The *lymphatic* glands about the parotid deserve notice, since they are liable to become enlarged, and simulate disease of the parotid itself. A lymphatic gland lies close to the root of the zygoma, in front of the cartilage of the ear; this gland is sometimes affected in disease of the external tunics of the eye; *e. g.*, in purulent ophthalmia; also in affections of the scalp.

To display the plexus of nerves (*pes anserinus*), formed by the branches of the facial, cut into the parotid gland by a vertical incision until the main trunk of the nerve is reached.

Portio dura, or Facial Nerve. This is the seventh cranial nerve, and is the motor nerve of the face. It supplies all the muscles of expression, the platysma, and the buccinator. Through some of its branches it supplies other muscles, the description of which will be deferred till the facial nerve is dissected in the temporal bone.

It arises immediately below the pons Varolii, from the lateral tract of the medulla oblongata, between the olivary and restiform bodies. The nerve enters the meatus auditorius internus, lying upon the auditory nerve, traverses a tortuous bony canal (*aqueductus Fallopii*) in the petrous portion of the temporal bone, and leaves the skull at the stylo-mastoid foramen. Its course and connections in the temporal bone will be studied hereafter: at present we must trace the facial part of the nerve.

Having emerged from the stylo-mastoid foramen, the nerve enters the parotid gland, and divides behind the ramus of the jaw into two primary branches, named, from their distribution, *temporo-facial* and *cervico-facial*. These primary branches cross over the external carotid artery and the external jugular vein, and form, by their communications within the substance of the parotid, the plexus called *pes anserinus*, from its fancied resemblance to the skeleton of a goose's foot. (Fig. 23.)

Close to the stylo-mastoid foramen, the facial nerve gives off its **posterior auricular** branch (Fig. 23), which ascends behind the ear and divides into two, an *auricular* and an *occipital*.

The former supplies the *retrahens* and *attollens aures*, the latter the posterior belly of the *occipito-frontalis*. This branch communicates with the deep branch of the great auricular n., with the small occipital, and with the auricular branch of the pneumogastric. Its two next *branches* supply the stylo-hyoideus and the posterior belly of the digastricus. The digastric nerve enters the muscle by many filaments; the nerve to the stylo-hyoid is long, and enters the muscle about the middle. The stylo-hyoid branch communicates with the sympathetic on the external carotid a.; the digastric branch with the glosso-pharyngeal near the base of the skull. These two muscular nerves are frequently given off from a common branch.

The **temporo-facial** division, the larger of the two, in passing through the parotid gland, crosses the external carotid and the neck of the jaw, receives two or more communications from the auriculo-temporal (branch of the fifth), and subdivides into *temporal*, *malar*, and *infra-orbital* branches.

The *temporal* branches ascend over the zygoma, supply the frontalis, the *atrahens aurem*, the orbicularis palpebrarum, the corrugator supercilii, and tensor tarsi, and communicate with filaments of the supra-orbital nerve, with the tem-

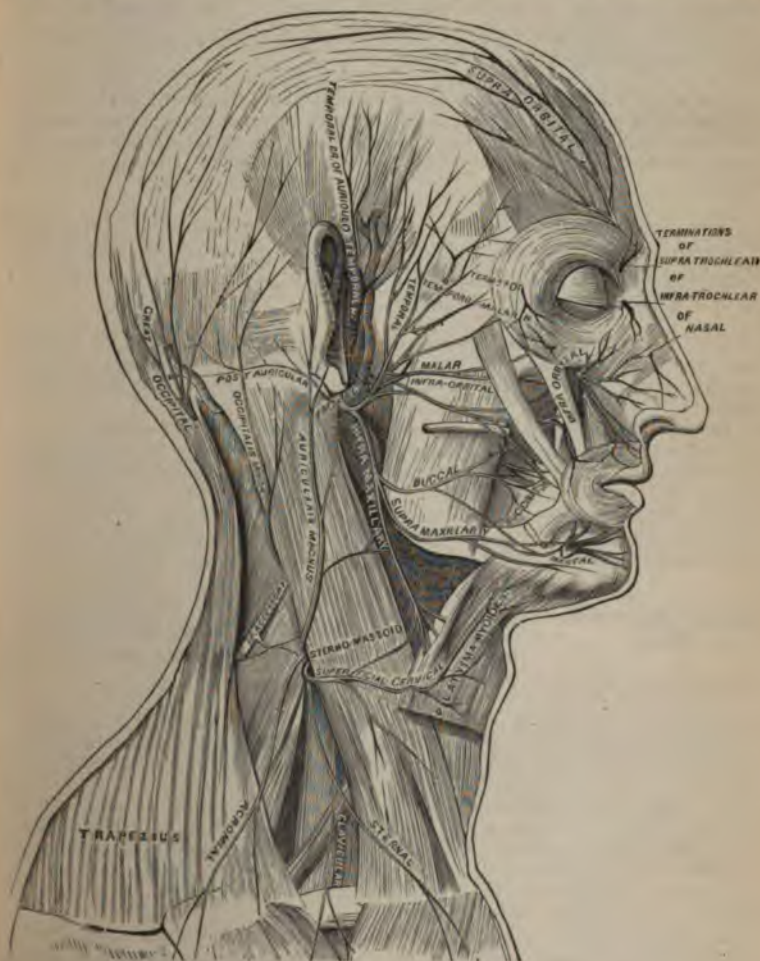


FIG. 23.

poral branch of the superior maxillary n., with the auriculo-temporal n., and with the lachrymal n.

The *malar* branches cross the malar bone, supply the orbicular muscle, and

communicate with filaments of the lachrymal, the supra-orbital, the superior maxillary, and the malar branch of the superior maxillary.

The **infra-orbital** branches are the largest, and proceed transversely forwards over the masseter beneath the zygomatici, to supply the orbicularis oris, the elevators of the upper lip, and the muscles of the nose.

The superficial branches join with the nasal and infra-trochlear branches of the ophthalmic along the side of the nose; the deep branches communicate beneath the levator labii superioris with the infra-orbital branches of the superior maxillary nerve forming the *infra-orbital plexus*, and also with the buccal branches of the facial.

The **cervico-facial** division, joined in the parotid gland by filaments from the great auricular (branch of the cervical plexus), descends towards the angle of the jaw, and subdivides into buccal, supra and infra-maxillary branches.

The *buccal* branches pass forwards over the masseter parallel with the parotid duct, and supply the buccinator; they communicate with the buccal branch of the inferior maxillary nerve (third division of the fifth), and with the infra-orbital nerve.

The *supra-maxillary* branches advance over the masseter and facial artery, and run under the platysma and the depressor muscles of the lower lip, all of which they supply. Some of the filaments communicate with the mental branch of the inferior dental nerve.

The *infra-maxillary* or cervical branches, one or more in number, arch forwards below the jaw covered by the platysma, as low as the hyoid bone, and communicate with the superficial cervical (branch of the cervical plexus).

Sensory Nerves of the Face.

These are the supra-orbital, the supra- and infra-trochlear, the naso-lobular, the temporo-malar, the infra-orbital, and the mental, all branches of the fifth pair.

The *supra-orbital nerve* is the continuation of the frontal, which is a branch of the first division of the fifth pair. It leaves the orbit through the supra-orbital notch and ascends upon the forehead, at first covered by the orbicularis and occipito-frontalis. It presently divides into two sets of branches—an *outer*, the larger, which passes backwards as far as the occipital bone, and an *inner*, which ascends as far as the parietal bone. It distributes sensory muscular branches also to the orbicularis palpebrarum, corrugator supercilii, the occipito-frontalis, to the pericranium and branches which supply the skin of the forehead, upper eyelid, and scalp. It communicates with the facial nerve on the forehead. The supra-orbital artery is a branch of the ophthalmic.

The *supra-trochlear n.*, or internal frontal, appears at the inner angle of the orbit between the supra-orbital foramen and the pulley of the superior oblique, and sends down in front of the pulley a loop to communicate with the infra-trochlear branch of the nasal. The main trunk of the nerve ascends to the forehead. Its further course has been described (p. 29).

The *infra-trochlear n.* issues from the orbit below the pulley, and supplies branches to the eyelids, the conjunctiva, lachrymal sac, and the side of the nose.

The *infra-orbital nerve* is the terminal branch of the superior maxillary or second division of the fifth nerve. It emerges with its artery from the infra-orbital foramen, covered by the levator labii superioris.

The nerve immediately divides into several branches, *palpebral*, *nasal*, and *labial*; the palpebral, ascending beneath the orbicularis, supply the lower eyelid, and communicate with the facial and the malar branch of the orbital nerve; the nasal pass inwards to supply the nose, and join the nasal branch (naso-lobular) of the ophthalmic; the labial, by far the most numerous, descend into the upper lip,

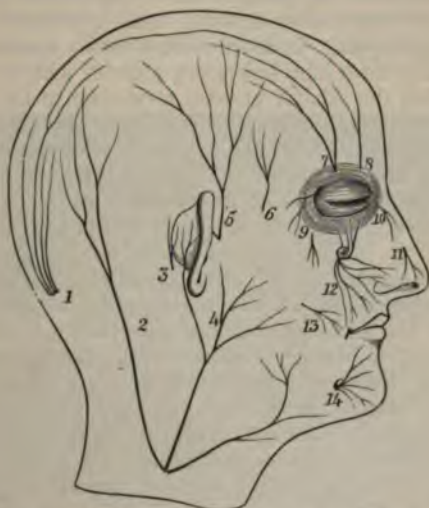

FIG. 24.—DIAGRAM OF THE SENSORY NERVES OF THE SCALP AND FACE.

1. Great occipital. 2. Small occipital. 3. Auricular br. of the pneumogastric. 4. Great auricular. 5. Auriculo-temporal. 6. Temporal br. of superior maxillary nerve. 7. Supra-orbital. 8. Supra-trochlear. 9. Malar br. of superior maxillary nerve. 10. Infra-trochlear. 11. Naso-lobular. 12. Infra-orbital. 13. Buccal br. of inferior maxillary nerve. 14. Mental.

beneath the levator labii superioris, and eventually terminate in lashes of filaments, which endow the papillæ of the lip and the mucous membrane of the mouth with exquisite sensibility. Close to the infra-orbital foramen is the infra-orbital plexus, before alluded to (p. 66).

The *infra-orbital artery* is the terminal branch of the internal maxillary; it supplies the muscles, the skin, and the front teeth of the upper jaw, and inosculates with the transverse facial, buccal, facial, and coronary arteries.

The *naso-lobular nerve* is the external branch of the nasal nerve and is distributed to the tip and lobule of the nose, and is joined by filaments from the facial nerve.

The *temporal branch of the orbital nerve* (branch of the superior maxillary nerve, running along the outer wall of the orbit, and which divides into a temporal and a malar branch) issues through the temporal fascia about a finger's breadth above the zygoma, and supplies the skin of the temple. It communicates with the facial and the auriculo-temporal nerves.

The *malar nerve*, a branch also of the orbital nerve, issues through a foramen in the malar bone, and, after piercing the orbicularis palpebrarum, supplies the skin of the cheek over the malar bone. It communicates with the facial and the palpebral branches of the infra-orbital nerve.

The *mental nerve* is a branch of the inferior maxillary or third division of the fifth. It emerges from the mental foramen in the lower jaw, in a direction upwards and backwards, beneath the depressor anguli oris. It soon divides into a number of branches beneath the depressor labii inferioris, some of which supply the skin of the chin, but the greater number terminate in the papillæ of the lower lip. It communicates with the facial nerve.

The *mental artery* is a branch of the inferior dental. It supplies the gums and the chin, and inosculates with the sub-mental, the inferior labial, and inferior coronary arteries.

Dissection. To expose the contents of the orbit, remove that portion of the orbital plate which forms the roof of the orbit as far back as the optic foramen, making one section with a saw on the outer side, and the other on the inner side of the roof, so that the two sections converge at the optic foramen. In doing this, be careful not to injure the little pulley on the inner side for the superior oblique. If the bone be sufficiently sawn through, a gentle tap with the saw on the front of the orbital plate will fracture its thin wall transversely. The anterior fourth of the roof should be turned forwards and downwards and kept in this position by hooks; the remainder is to be removed by bone forceps nearly as far as the optic foramen, so as to leave a ring of bone from which most of the ocular muscles have their origin. The eyeball should be made tense by blowing air through a blowpipe passed well into the globe through the cranial end of the optic nerve.

Periosteum of the Orbit. The roof being removed, we expose the fibrous membrane which lines the walls of the orbit.

It is a continuation of the dura mater through the sphenoidal fissure. Traced forwards, we find that it is loosely connected to the walls of the orbit, and that at the margin of the orbit it divides into two layers, one of which is continuous with the periosteum of the forehead, the other forms the broad tarsal ligament which fixes the tarsal cartilage.

The periosteum is now to be removed, and the fascia of the orbit made out. The following objects should then be carefully traced: in the middle are seen the *frontal artery and nerve*, lying

on the levator palpebræ; on the outer side, the *lacrimal nerve and artery* pass forwards on the external rectus to the lacrimal gland, which lies under cover of the external angular process; on the inner side is the *fourth nerve*, lying on and supplying the superior oblique.

Fascia of the Orbit and Capsule of Tenon.

The fascia of the orbit provides the lacrimal gland and each of the muscles with a loose sheath, thin and delicate at the back of the orbit, but stronger near the eyeball. It is pierced behind by the optic nerve and by the arteries and nerves of the orbit, while in front it is connected with the ocular conjunctiva close to the cornea. The sheaths are firmly adherent to the mus-

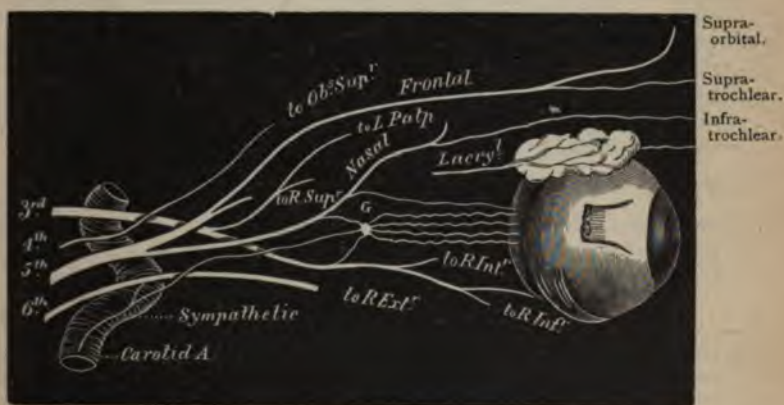

FIG. 25.—DIAGRAM OF THE NERVES OF THE ORBIT.

cles, and their tendinous insertions into the globe are connected by the fascia. From the insertions of the muscles it is reflected as a double layer backwards over the globe, so that it resembles a serous membranous sac—a tunica vaginalis—one layer being loosely connected with the globe, the other lining the fat in which the globe is set. These layers are lined with epithelium, and are separated by an external lymph space. This reflection of the orbital fascia is called the *capsule of Tenon*, its use being to allow free movement of the globe.

The orbit contains a large quantity of granular fat, which forms a soft bed for the eye, and prevents its being retracted too far by its muscles. Upon the amount of this fat depends, in some measure,

the prominence of the eyes. Its absorption in disease or old age occasions the sinking of the eyeballs.

Contents of the Orbit.

In the middle of the orbit is the eyeball, surrounded by more or less fat, and attached to it are six muscles which move it: four, running forwards in a straight direction, are called the *recti*, and are arranged one above, one below, and one on each side of the globe; the remaining two are called, from their direction, *obliqui*, one superior, the other inferior. There is also a muscle to raise the upper eyelid, termed *levator palpebræ*. The *nerves* are: the optic, which passes through the optic foramen; the third, the fourth, the first division of the fifth, the sixth, and some filaments of the sympathetic, all of which pass through the sphenoidal fissure. The third supplies all the muscles with motor power, except the superior oblique, which is supplied by the fourth, and the external rectus, which is supplied by the sixth. The first or ophthalmic division of the fifth divides into a frontal, lachrymal, and nasal branch. The ophthalmic artery, a branch of the internal carotid, passes into the orbit through the optic foramen; its vein passes backwards through the sphenoidal fissure to join the cavernous sinus.

Frontal Nerve.

The *ophthalmic*, or first division of the fifth—a sensory nerve—after giving off from its inner and lower side, whilst within the cavernous sinus, the nasal nerve, divides into the frontal and lachrymal nerves, of which the former is the larger.

It is the smallest division of the fifth, and runs forwards for the distance of about an inch (2.5 c. m.); in its course it is connected with the cavernous plexus of the sympathetic, with the third, fourth, and sixth nerves, and close to its origin from the Gasserian ganglion it sends off a small recurrent branch to the tentorium cerebelli.

One of its divisions, the frontal nerve, runs forwards upon the upper surface of the levator palpebræ, on which, about midway in the orbit, it divides into two branches—the supra-trochlear and the supra-orbital.

a. The *supra-trochlear*, the smaller of the two (Fig. 26) runs obliquely inwards above the pulley of the superior oblique to the inner angle of the orbit. Here it gives off a small communication downwards to the infra-trochlear branch of the nasal, and then divides, after passing between the bone and the orbicularis palpebrarum, into filaments which supply the skin of the upper eyelid, forehead, and nose. One or two small filaments may be traced through the bone to the mucous membrane of the frontal sinuses.

b. The *supra-orbital* is the continuation of the frontal nerve, and runs forwards on the levator palpebræ to the supra-orbital notch, through which it ascends to supply the skin of the upper eyelid, forehead, pericranium, and scalp. Its cutaneous branches, an inner

and an outer, which run upwards beneath the occipito-frontalis, have been described in the dissection of the scalp (p. 27). It supplies with common sensation the orbicularis palpebrarum, the occipito-frontalis, and the corrugator supercilii, where it joins the facial nerve.

Lachrymal Nerve. This is the smallest of the three branches of the ophthalmic nerve. It runs along the upper border of the external rectus on the outer side of the orbit with the lachrymal artery, through the lachrymal gland, which it supplies as well as the upper eyelid. Its branches within the orbit are: 1, a branch which passes down behind the lachrymal gland to communicate with the orbital branch of the superior maxillary nerve;

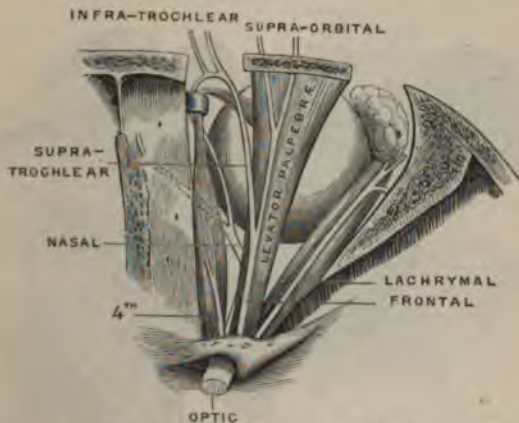


FIG. 26.—VIEW OF ORBIT FROM ABOVE.

2, filaments to the lachrymal gland. It then pierces the palpebral ligament to supply the skin of the upper eyelid.

Fourth Cranial Nerve.

This nerve enters the orbit through the sphenoidal fissure above the other nerves. It runs along the inner side of the frontal nerve, and enters the upper or orbital surface of the superior oblique, to which it is solely distributed. This nerve is joined in the outer wall of the cavernous sinus by filaments from the sympathetic. It communicates occasionally with the lachrymal, and the ophthalmic division of the fifth. Here also it sends backwards two or more filaments to supply the tentorium cerebelli.

Lachrymal Gland.

This gland is situated below the external angular process of the frontal bone. It consists of an orbital and palpebral portion—the former placed beneath

the external angular process of the frontal bone in a depression for its reception, the latter extending to the margin of the upper lid. The orbital portion is oval, flattened, and curved, is held in place by a suspensory ligament attached to the bone, and extends one-fifth of the distance into the orbital cavity from this base. It is $\frac{3}{4}$ of an inch (19 mm.) from before backwards, $\frac{1}{2}$ inch (13 mm.) wide, $\frac{1}{6}$ of an inch (3 mm.) thick, and weighs .8 of a gm., and has a volume of about 0.66 cm. It is limited externally by the external palpebral ligament, internally by the edge of the superior rectus. The palpebral portion is quadrilateral, smaller, thinner, and is in contact with the palpebral conjunctiva. It is $\frac{1}{3}$

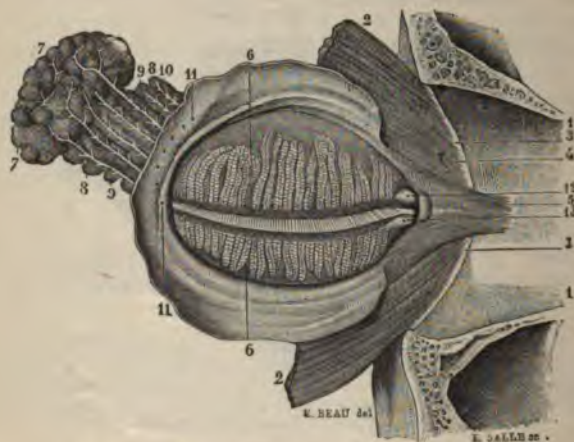


FIG. 27.—LACHRYMAL GLAND.

7, 7. Orbital portion of the lachrymal gland. 8, 9, 10. Palpebral portion of this gland.
11, 11. Mouths of its excretory ducts.

of an inch (9 mm.) long, nearly as wide, and $\frac{1}{3}$ of an inch (2 mm.) thick. The lachrymal gland empties by ten to fifteen excretory ducts which run parallel and perforate the conjunctiva in a row on the upper lid $\frac{1}{4}$ of an inch (6.5 mm.) above the tarsal cartilage near the external canthus. They are not easily discovered in the human eye; in that of the horse or bullock they are large enough to admit a small probe. The secretion of the gland keeps the surface of the cornea constantly moist and polished; but if dust, or any foreign substance, irritate the eye, the tears flow in abundance and wash it off.

All the muscles of the orbit, with the exception of the inferior

oblique, arise from the margin of the foramen opticum, and pass forwards, like ribands, to their insertions.

Levator Palpebræ. This muscle *arises* from the roof of the orbit, above and in front of the optic foramen. It gradually increases in breadth, and terminates in a broad, thin aponeurosis, which is *inserted* into the upper surface of the tarsal cartilage beneath the palpebral ligament. It is constantly in action when the eyes are open, in order to counteract the tendency of the lids to fall. As sleep approaches, the muscle relaxes, the eyes feel heavy, and the lids close. Its nerve comes from the superior

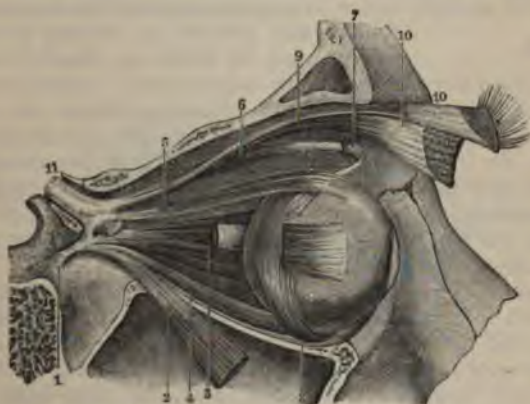


FIG. 28.—MUSCLES OF THE EYE. LIGAMENT OF ZINN.

1. Attachment of the ligament of Zinn—showing the three tongue-like projections, from its annular parts surrounding the optic nerve, to the internal, external, and inferior recti muscles. 2. External rectus, incised and deflected downwards to show the internal rectus. 3. Internal rectus. 4. Inferior rectus. 5. Superior rectus. 6. Superior oblique. 7. Pulley for the superior oblique muscle. 8. Inferior oblique. 9. Levator palpebræ. 10. Portion of the orbicularis palpebrarum. 11. Optic nerve.

division of the third nerve, and enters it on its under or ocular aspect.

Obliquus Superior. This muscle *arises* from the inner side of the optic foramen. It runs forwards along the inner and upper side of the orbit, and terminates in a round tendon, which passes through a fibro-cartilaginous pulley—*trochlea*—attached to the trochlear fossa in the frontal bone. From the pulley the tendon is reflected outwards and backwards, beneath the superior rectus, and is *inserted* by an expanded tendon into the outer part of the sclerotic coat, midway between the cornea and the entrance of the optic nerve. The pulley is lined by a synovial membrane, which is continued over the tendon. The *action* of

this muscle will be considered with that of the inferior oblique. It is supplied by the fourth nerve, which enters the back part of its upper surface.

The frontal nerve and levator palpebræ are now to be cut through the middle and reflected, the front part forwards and the hind part backwards. On its under aspect is seen the twig from the upper division of the third nerve entering it. On reflecting this muscle the superior rectus is exposed.

The *superior rectus* arises by a tendinous origin from the upper margin of the optic foramen and from the sheath of the optic nerve, and is *inserted* by a broad, thin tendon into the sclerotic coat, about a quarter of an inch (6 mm.) from the margin of the cornea (p. 79).

Dissection. Reflect this muscle by cutting through the middle, and, in doing so, observe a filament from the third nerve entering its under aspect. After the removal of a quantity of granular fat, the following objects are exposed: beneath the muscle are the optic nerve, the ophthalmic artery and vein, the nasal nerve and its ciliary branches crossing over the optic nerve, and further forwards is the reflected tendon of the superior oblique; on the outer side of the optic nerve, and close to the ophthalmic artery, is the lenticular ganglion, with numerous ciliary filaments passing forwards from it to enter the sclerotic. The student should now trace backwards the two roots which enter the upper and lower angle respectively of the ganglion, the upper being its sensory branch from the nasal, the lower its motor root from the lower division of the third nerve. Further back should be traced the third, the nasal branch of the ophthalmic, and the sixth nerves passing between the two heads of the external rectus to their respective destinations. The ophthalmic artery and its branches may also at this stage be exposed and cleaned.

Nasal Nerve.

This is one of the three divisions of the ophthalmic branch of the fifth, and is usually the first branch given off (Fig. 25, p. 69). It enters the orbit through the sphenoidal fissure between the two origins of the external rectus, and between the two divisions of the third n. It then crosses obliquely over the optic nerve, beneath the levator palpebræ and the superior rectus, towards the inner wall of the orbit. After giving off the *infra-trochlear* branch, the nerve passes out of the orbit between the superior oblique and the internal rectus, through the anterior ethmoidal foramen, into the cranium, where it lies beneath the dura mater, upon the cribriform plate of the ethmoid bone. It soon leaves the cranium through the nasal slit near the crista galli, and enters the nose. Here it divides into two branches—an *inner* or *septal*, which supplies the mucous mem-

brane of the front of the septum ; and an *outer*, the main continuation of the nerve—which runs in a groove on the under surface of the nasal bone, and distributes branches to the pituitary membrane of the outer part of the nose and the two lower turbinated bones ; it also gives off a superficial branch, which emerges between the nasal bone and the cartilage, under the name of the *naso-lobular*, and is distributed to the skin of the tip and ala of the nose (p. 67).

The nasal nerve gives off the following branches in the orbit :—

a. One slender filament to the *lenticular ganglion* (forming its upper or long root) is given off from the nasal nerve as it passes between the heads of the external rectus close to the optic nerve. It is about half an inch long, and enters the posterior-superior angle of the ganglion.

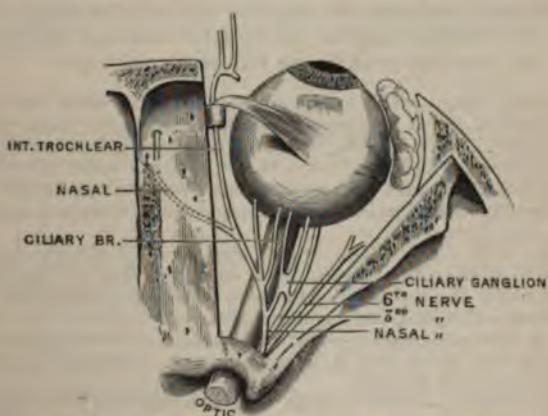


FIG. 29.—VIEW OF OPTIC AND LOWER NERVES OF ORBIT.

b. Two or three *long ciliary nerves*. They run along the inner side of the optic nerve to the back of the globe of the eye. They are joined by filaments from the lenticular ganglion, and pass through the sclerotic coat to supply the iris (Fig. 29).

c. *Infra-trochlear nerve*.—This runs forwards along the inner side of the orbit, below the pulley of the superior oblique, where it communicates with the supra-trochlear branch of the frontal nerve. It passes to the inner angle of the orbit, and divides into filaments, which supply the skin of the eyelids, the caruncle, the lacrimal sac, and the sides of the nose.

Optic Nerve.

This nerve, having passed through the optic foramen, proceeds forwards and a little outwards for about an inch to the globe of the eye, which it enters on the nasal side of its axis. It pierces the sclerotic and choroid coats, and then expands to form the retina. The nerve is invested by a

dense fibrous coat derived from the dura mater, and by a thin one from the arachnoid, both of which pass forward as far as the sclerotic. At the optic foramen it is surrounded by the tendinous origins of the recti; in the rest of its course, by loose fat and by the ciliary nerves and arteries. It is pierced in its course through the orbit by the *arteria centralis retinae*, which runs along with its vein in the middle of the nerve to the eyeball.*

Ophthalmic Artery. This artery arises from the internal carotid, close by the anterior clinoid process. It enters the orbit through the optic foramen, outside and below the optic nerve; occasionally through the sphenoidal fissure. Its course in the orbit is remarkably tortuous. Situated at first on the outer side of the optic nerve, it soon crosses over it, and runs along the inner side of the orbit between the superior and internal recti, to inosculate with the internal angular artery (the terminal branch of the facial). Its branches arise in the following order:—

a. Lachrymal Artery.—This branch proceeds along the outer wall of the orbit above the external rectus, in company with the nerve of the same name, to the lachrymal gland. After supplying the gland, it terminates in the conjunctiva and eyelids. In the orbit it gives off some *malar* branches which pierce the malar bone to get to the temporal fossa, and anastomose with the deep temporal arteries. It also sends a branch backwards through the sphenoidal fissure to anastomose with the *arteria meningea media*.

b. Supra-orbital Artery.—This branch runs forwards with the frontal nerve under the roof of the orbit and upon the levator palpebrae. It emerges on the forehead through the supra-orbital foramen, where it communicates with the superficial temporal, frontal, and angular arteries.

c. Arteria Centralis Retinae.—This small branch enters the optic nerve obliquely on the outer aspect close to the optic foramen. It runs in the centre of this nerve to the interior of the eye.

d. Ciliary Arteries.—These branches may be arranged in three groups. The *short ciliary*, twelve to fifteen in number, proceed tortuously forward with the optic nerve, and pierce the sclerotic coat at the back of the eye to supply the choroid coat and the iris. The *long ciliary*, two in number, run on each side of the optic nerve, enter the sclerotic, and pass horizontally forward, one on each side of the globe, between the sclerotic and the choroid, nearly as far as the iris, where each divides into an upper and a lower branch. These branches of the two long ciliary arteries anastomose with the anterior ciliary and form two vascular circles, an outer at the circumference of the iris, the *circulus major*, and an inner at the free margin of the iris, the *circulus minor*. The *anterior ciliary* are branches of the muscular and lachrymal arteries and proceed with the tendons of the recti, and enter the front part of the sclerotic coat. In inflammation of the iris the vascular zone round the cornea arises from enlargement and congestion of the anterior ciliary arteries.

e. Ethmoidal Arteries.—Of these arteries, two in number, the *anterior* and larger passes through the anterior ethmoidal foramen with the nasal nerve; the *posterior* enters the posterior ethmoidal foramen with the sphenothmoidal nerve.

* A small branch from Meckel's ganglion, ascending through the sphenomaxillary fissure, is described by Arnold as joining the optic nerve.

The anterior gives off branches to the frontal and anterior ethmoidal cells, and a nasal branch to the nose; it likewise gives off an anterior meningeal branch to the dura mater in the anterior fossa. The posterior is distributed to the posterior ethmoidal cells and upper part of the nose.

f. Muscular Branches.—There is an upper and a lower branch supplying respectively the upper and lower muscles: besides these, there are irregular branches from the lachrymal and supra-orbital arteries.

g. Palpebral Arteries.—These branches, a *superior* and an *inferior*, proceed from the ophthalmic artery near the front of the orbit. They are distributed to their respective eyelids, forming arches near the margins of the lids between the tarsal cartilages and the orbicularis palpebrarum, with branches from the lachrymal and the infra orbital arteries.

h. Nasal Artery.—This branch may be considered one of the terminal divisions of the ophthalmic. It leaves the orbit on the nasal side of the eye above the tendon of the orbicularis, and inosculates with the angular and nasal arteries of the facial. It supplies the side of the nose and the lachrymal sac.

i. Frontal Artery.—This is the other terminal branch of the ophthalmic. It emerges at the inner angle of the eye, ascends, and inosculates with the supra-orbital artery.

Ophthalmic Veins. There are two ophthalmic veins. The *superior* commences at the inner angle of the eye by a communication with the frontal and angular veins. It runs backwards above the optic nerve in a straighter course than the artery, receives the veins corresponding to the arteries of the upper and inner part of the orbit, and finally passes between the two heads of the external rectus, through the inner part of the sphenoidal fissure, to terminate in the cavernous sinus. The *inferior ophthalmic vein* is formed by the union of branches from the lower and outer part of the orbit, and proceeding backwards along the floor of the orbit, opens into the superior vein, or directly into the cavernous sinus. In front it sends a communicating vein through the speno-maxillary fissure to join the pterygoid plexus.

Ophthalmic or Lenticular Ganglion. This small ganglion,* of reddish colour and about the size of a pin's head, is situated at the back of the orbit, between the optic nerve and the external rectus, on the outer side of, and usually closely adherent to, the ophthalmic artery. It is somewhat quadrilateral in shape, and receives its *sensory or long root* from the nasal nerve, which joins its posterior superior angle; its *motor or short root*, from the branch of the third nerve, going to the inferior oblique, which enters its posterior inferior angle; and its *sympathetic root* from the cavernous plexus which joins it at its posterior border, or in conjunction with its sensory root. The ganglion, thus furnished with motor, sensory, and sympathetic roots, gives off the *short ciliary nerves*. These, from eight to twelve in number, issue from the anterior upper and lower angles of the ganglion, usually four or five from the upper, the remainder from the lower. They run very tortuously with the optic nerve, pass through the back of the sclerotic coat, where they are joined by the long

* W. Marshall regards this ganglion, from its mode of development and from its relations in some of the lower vertebrates, to be connected more with the third nerve than the ophthalmic.

ciliary (from the nasal), and are distributed to the iris and the ciliary muscle. Since the ciliary nerves derive their motor influence from the third nerve, the iris must lose its power of contraction when this nerve is paralyzed.

Third Nerve, Motor Oculi.

The third nerve passes forwards in the outer wall of the cavernous sinus, and here receives one or two filaments from the cavernous plexus of the sympathetic. Just before it enters the inner end of the sphenoidal fissure it divides into two branches, both of which pass between the two heads of origin of the external rectus, separated from each other by the nasal nerve. The *upper* and smaller division has been already traced into the superior rectus and levator palpebræ. The *lower* division after a short course divides into

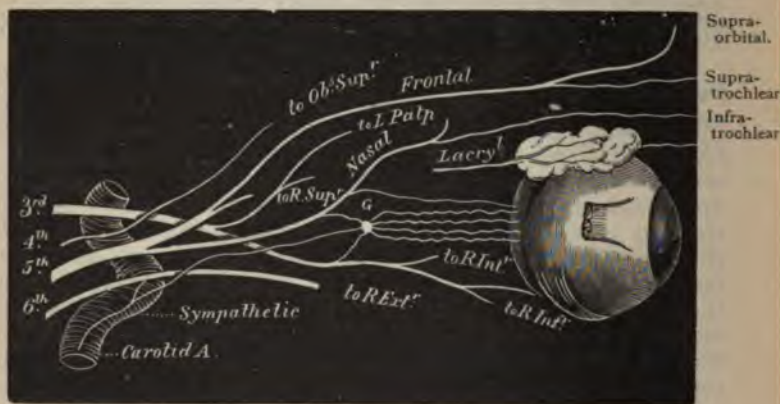


FIG. 30.—DIAGRAM OF THE NERVES OF THE ORBIT.

three branches, one passing inwards under the optic nerve to supply the internal rectus, another passes to the inferior rectus, and a third runs along the floor of the orbit to the inferior oblique. This last-named branch sends a small twig upwards to the lenticular ganglion, mentioned in the description of this ganglion, and another to the inferior rectus.

What is the result of paralysis of the third nerve? Falling of the upper eyelid (ptosis), external squint, dilatation and immobility of the pupil.

Sixth Nerve, Abducens.

This nerve lies in the inner wall of the cavernous sinus external to the internal carotid artery, passes through the sphenoidal fissure, and enters the orbit between the two heads of the external

rectus. Here it lies below the lower division of the third and above the ophthalmic vein. The nerve terminates in fine filaments, which are distributed to the ocular surface of the external rectus. In the cavernous sinus it is joined by filaments from the carotid plexus, and in the orbit by a branch from Meckel's ganglion and from the ophthalmic nerve.

Respecting the motor nerves in the orbit, observe that they all enter the ocular surface of the muscles, with the exception of the fourth, which enters the orbital surface of the superior oblique.

Recti Muscles. The *internal* and *inferior recti* arise from a fibrous band—the *ligament of Zinn*—attached to the inner and lower borders of the optic foramen. The *external rectus* arises by two heads, the lower from the ligament of Zinn and the lower border of the sphenoidal fissure, the upper from the margin of the foramen opticum; between these heads pass in the following order, from above downward—the upper division of the third, the nasal, the lower division of the third, the sixth nerves, and the ophthalmic vein.

The four recti diverge from each other, one above, one below, and one on each side of the optic nerve. Their broad, thin tendons are inserted into the sclerotic coat of the eye, about a quarter of an inch from the margin of the cornea (Fig. 31).

The recti muscles enable us to direct the eye towards different points. It is obvious that by the single action of one, or the combined action of two, the eye can be turned towards any direction.

The *rectus superior* is supplied by the upper division of the third nerve; the *rectus internus*, the *rectus inferior*, and *obliquus inferior*, by the lower division. The *rectus externus* is supplied by the sixth.

Follow the recti to the eye, in order to see the tendons by which they are inserted. Notice also the anterior ciliary arteries, which run to the eye along the tendons. The congestion of these little vessels occasions the red zone round the cornea in iritis. It has been already mentioned that the tendons are invested by a fascia, which passes from one to the other, forming a loose tunic—*capsule of Tenon*—over the back of the eye. This tunic consists of two layers with an intermediate space, lined with flat cells, thus allowing

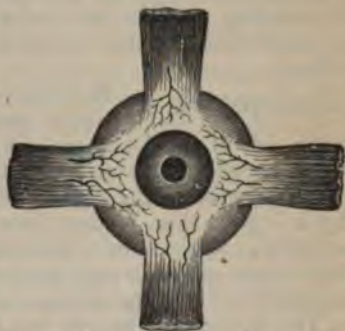

FIG. 31.—INSERTION OF THE RECTI MUSCLES WITH THE ANTERIOR CILIARY ARTERIES.

free mobility of the globe. It is this fascia which resists the passage of the hook in the operation for the cure of squinting. Even after the complete division of the tendon the eye may still be held in its faulty position if this tissue, instead of possessing its proper softness and pliancy, happen to have become contracted and unyielding. Under such circumstances it is necessary to divide it freely with the scissors.

By removing the conjunctival coat of the eye, the tendons of the recti are soon exposed. The breadth and the precise situation of their insertion deserve attention in reference to the operation for strabismus. The breadth of their insertion is about three-eighths of an inch (*1 c. m.*), but the line of this insertion is not, at all points, equidistant from the cornea. The centre of the insertion is nearer to the cornea by about one-twelfth of an inch (*2 mm.*) than either end. Taking the internal rectus, which has most frequently to be divided in strabismus, we find that the centre of its tendon is, upon an average, one-fourth of an inch (*6 mm.*) only from the cornea, the lower part nearly one-half of an inch (*10 mm.*), and the upper one-third of an inch (*8 mm.*). It is, therefore, very possible that the lower part may be left undivided in the operation, being more in the background than the rest. The tendon of the internal rectus is nearer to the cornea than either of the others.

Inferior Oblique. This muscle *arises* by a flat tendon from the orbital plate of the superior maxilla on the outer side of the lachrymal groove. It runs outwards and backwards between the orbit and the inferior rectus, then curves upwards between the globe and the external rectus, and is *inserted* by a broad, thin tendon into the outer and back part of the sclerotic, close to the tendon of the superior oblique. It rotates the cornea outwards and upwards and slightly abducting it. It is supplied by the lower division of the third nerve.

The tensor tarsi muscle has been described in the dissection of the face (p. 54).

Orbital Branch of the Superior Maxillary Nerve. This is always very small, and is sometimes absent. It comes from the trunk of the superior maxillary in the speno-maxillary fossa, enters the orbit through the speno-maxillary fissure, and divides into two branches.

Of these, one, the *temporal*, lies in a groove in the outer wall of the orbit, and after sending a small branch to the lachrymal nerve in the orbit, passes through a foramen in the malar bone to the temporal fossa. It then pierces the temporal aponeurosis an inch (*2.5 c. m.*) above the zygoma, and supplies the skin of the temple communicating with the facial, and joining frequently with the auriculo-temporal branch of the inferior maxillary. The other branch, the *malar*, passes along the outer part of the floor of the orbit, imbedded in fat, and makes its exit through a foramen in the malar bone, to supply the skin of the cheek over the malar bone (p. 68).

DISSECTION OF THE NECK.

Surface Marking. Before the student reflects the skin of the neck he should examine the skin surface, which in some places is raised, in others depressed, indicating thereby unevenness of the subjacent structures. The neck is bounded above by a well-marked transverse ridge, indicating the lower border of the inferior maxilla, and at its lower part the neck is bounded by another ridge which corresponds with the clavicle. Crossing obliquely from the centre of the neck below to the mastoid process above is the rounded prominence caused by the sterno-mastoid, and crossing this muscle diagonally from its anterior to its posterior border is the external jugular vein, which varies in size in different subjects. In front and behind the sterno-mastoid are two triangular depressions; the posterior one, it will be seen, has its base at the clavicle, the anterior one at the lower jaw. The posterior triangle has the trapezius as its outer boundary, but this border is only well defined inferiorly, where the hollow becomes most marked, and takes the name of the supra-clavicular or Mohrenheim's fossa. In this is placed deeply the subclavian artery, the posterior belly of the omo-hyoid, and the brachial plexus. In front of the sterno-mastoid is another triangular hollow space with its base upwards; this is called the carotid triangle, for in it lies the carotid artery immediately beneath the anterior border of the sterno-mastoid. The body of the hyoid bone can always be felt in the middle line below the symphysis of the lower jaw. About a finger's breadth below the hyoid is the prominent pomum Adami of the thyroid cartilage, and a short distance below this cartilage is the cricoid, separated from the cartilage above by the crico-thyroid membrane. The cricoid cartilage corresponds with the fifth cervical vertebra, and from it the trachea passes down, gradually receding from the surface, so that there is, especially in emaciated subjects, a deep hollow—*fonticulus gutturis*—immediately above the sternum. In front of the second, third, and fourth rings of the trachea is the isthmus of the thyroid gland, and there are usually another four rings below these above the sternum, covered more or less by the depressor muscles of the os hyoides.

Dissection. The head must be slightly raised, and the face turned from the side on which the dissection is to be made. Then make a vertical incision through the skin, down the middle of the neck from the symphysis of the lower jaw to the sternum; a second along the clavicle to the acromion; a third along the base of the jaw as far as the mastoid process. Reflect the skin and subcutaneous fat, and expose the cutaneous muscle, called the *platysma myoides*. Between the *platysma* and the

skin is a layer of adipose tissue, called the *superficial fascia*. It varies in thickness in different subjects, but is generally more abundant at the upper part of the neck, especially in corpulent individuals, in whom it occasions a double chin.

Platysma Myoides. The *platysma myoides* is the thin cutaneous muscle covering the front and side of the neck. It arises from the subcutaneous tissue over the pectoralis major, trapezius, and deltoid muscles; thence proceeding obliquely over the clavicle and the side of the neck, its fibres become more closely aggregated, and terminate thus: The anterior cross those of the opposite platysma, immediately below the symphysis of the jaw, and are lost in the skin of the chin; the middle are attached along the base of the jaw; the posterior cross the masseter muscle, and terminate, partly in the subcutaneous tissue of the cheek, partly in the muscles at the corner of the mouth blending with the depressor anguli oris and orbicularis.*

The platysma forms a strong muscular defence for the neck. It is also a muscle of expression.† It is supplied with nerves by the cervical plexus, and by the cervical branch of the facial nerve.

Dissection. Cut through the platysma near the clavicle and turn it upwards. Beneath it lies the general investment of the neck, called the *deep cervical fascia*. Upon this fascia we trace the superficial branches of the cervical plexus of nerves, the external jugular vein, and a smaller vein in front, called the anterior jugular. These superficial veins are so variable in size and course that a general description only is applicable.

External Jugular Vein. The *external jugular vein* is formed within the substance of the parotid gland by the junction of the temporal and internal maxillary veins.

* Some of the uppermost fibres of this part of the platysma take the name of *musculus risorius*: this has been described among the muscles of the face.

† If the entire muscle be permanently contracted it may occasion wry-neck, though distortion from such a cause is an exceedingly rare occurrence. A case in point is related by Mr. Gooch (*Chirurg. Works*), in which a complete cure was effected, after the failure of all ordinary means of relief, by the division of the platysma a little below the jaw.

The platysma myoides belongs to a class of muscles called *cutaneous*, from their office of moving the skin. There are not many in man, except upon the neck and face, and there is a little one (*palmaris brevis*) in the palm of the hand. To understand their use thoroughly we must refer to the lower orders of animals, in whom they fulfil very important functions, by moving not only the skin, but also its appendages. For instance, by muscles of this kind the hedgehog, porcupine, and animals of that family can roll themselves up and erect their quills; we are all familiar with the broad "*panniculus carnosus*" on the sides of herbivorous quadrupeds, which enables them to twitch their skins, and thus rid themselves of insects. In birds, too, these cutaneous muscles are extremely numerous, each feather having appropriate muscles to move it.

After receiving the transverse facial and posterior auricular veins, it appears at the lower border of the gland, crosses obliquely over the sterno-mastoid muscle (Fig. 32), running along its posterior border, nearly as low down as the clavicle, where it pierces the deep cervical fascia and terminates in the subclavian vein. Accompanying the vein in its upper part is the auricularis magnus nerve, and crossing it, about the middle, is the superficial cervical nerve, both being branches of the superficial cervical plexus. It is usually provided with two pairs of valves—the lower, imperfect, close to its termination in the subclavian vein; the upper, placed about an inch and a half (3.8 cm) above the clavicle. A line drawn from

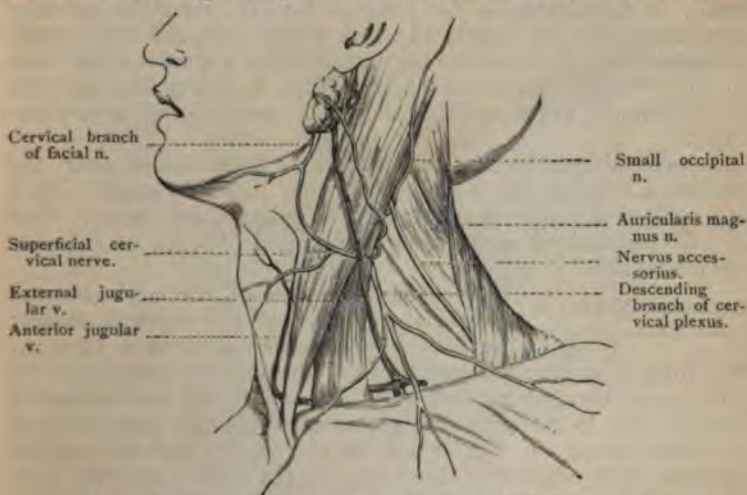


FIG. 32.—DIAGRAM OF THE SUPERFICIAL NERVES AND VEINS OF THE NECK.

the angle of the jaw to the middle of the clavicle would indicate its course. To trace the vein, during life, press upon it just above the clavicle; but do not be surprised if you fail to find it; it is sometimes wanting, and frequently very small.

Near the angle of the jaw the external jugular vein communicates by a large branch with the internal jugular, and about its middle it is joined by a large vein—*posterior external jugular*—from the occipital region.

Before its termination the external jugular vein generally receives the supra-scapular, posterior scapular, and other unnamed veins: a disposition very embarrassing to the surgeon, because there is a *confluence of veins immediately over the subclavian artery* in the place where it is usually tied.

Anterior Jugular Vein.

The *anterior jugular vein* is situated more in the middle of the neck, and is much smaller than the external jugular. It commences by small branches below the chin, and runs down the front of the neck, nearly to the sternum; it then curves outwards, beneath the sterno-mastoid muscle, and opens either into the external jugular or the subclavian vein. We commonly meet with two anterior jugular veins, one on either side; immediately above the sternum they communicate by a transverse branch.

The size of the anterior jugular vein is inversely proportionate to that of the external jugular. When the external jugular is small, or terminates in the internal jugular, then the anterior jugular becomes an important supplemental vein, and attains considerable size. It is not uncommon to find it a quarter of an inch (6 mm.) in diameter, and we have seen it nearly half an inch (12.5 mm.). These varieties should be remembered in tracheotomy.

Superficial lymphatic glands are sometimes found near the cutaneous veins of the neck. From four to six in number, they are small and escape observation unless enlarged by disease. One or two are situated over the sterno-mastoid muscle; others, near the mesial line.

Cutaneous Nerves of the Neck.

The cutaneous nerves of the neck are the superficial branches of the cervical plexus; the plexus itself cannot at present be seen. It is formed by the communications of the anterior divisions of the four upper cervical nerves, and lies under the sterno-mastoid muscle, close to the transverse processes of the four upper cervical vertebræ, resting on the levator anguli scapulæ and the scalenus medius. The superficial branches of the plexus emerge from beneath the posterior border of the sterno-mastoid, and take different directions. They are named thus (Fig. 32):—

Superficial branches of the cervical plexus.	{ Ascending branches . . . Transverse branch . . . Descending branches . . .	{ Great auricular. Small occipital. Superficial cervical. Sternal. Clavicular. Acromial.

The *great auricular n.* comes from the second and third cervical nerves, winds round the posterior border of the sterno-mastoid, and ascends obliquely over that muscle, near the external jugular vein, towards the parotid gland. Near the gland it divides into two principal branches, of which the *anterior* or *facial* branches are distributed to the skin over the parotid gland, where they join branches from the facial nerve, and to the side of the cheek; the *posterior* or *auricular*, after ascending a short distance, give off a branch, which ramifies mainly upon the cranial aspect of the cartilage of the ear; and a smaller branch, the *mastoid*, which

supplies the skin over the mastoid process. Other filaments of this nerve communicate in the substance of the parotid gland with branches of the facial nerve.

The *small occipital n.* comes from the second cervical nerve, and is occasionally

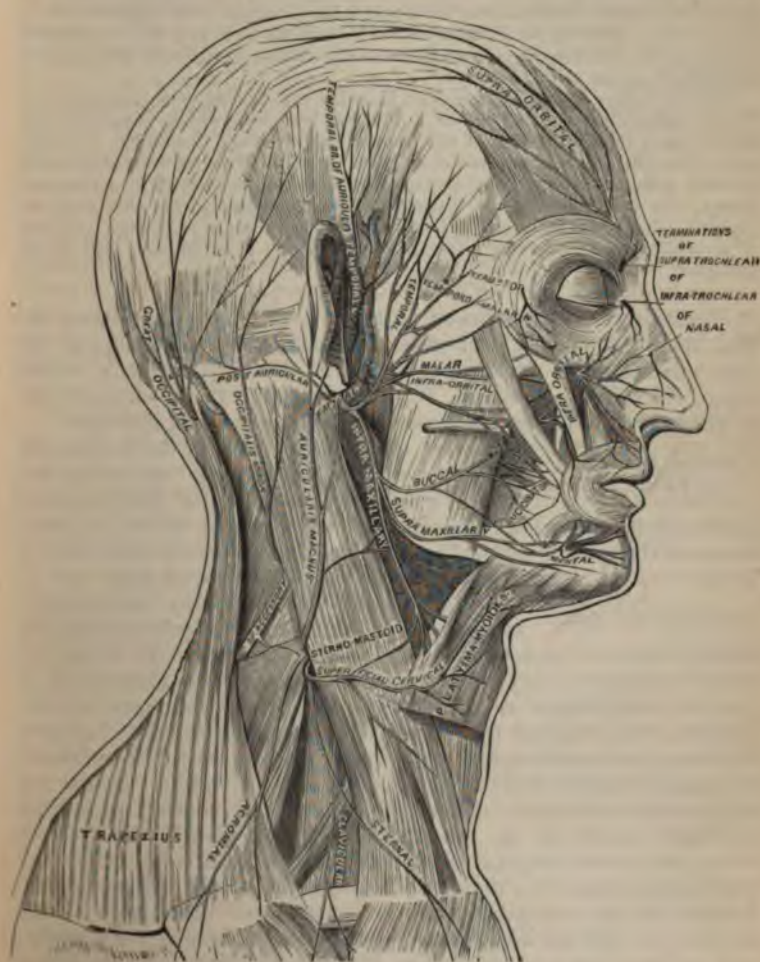


FIG. 33.

double. It ascends along the posterior border of the sterno-mastoid muscle to the occiput, where it supplies the back of the scalp, and communicates with the great occipital, the great auricular, and the posterior auricular nerves. It also sends off

one branch, which is distributed to the skin of the temporal region, and another *auricular* to the pinna of the ear. Beneath the sterno-mastoid this nerve commonly forms a loop, which embraces the *nervus accessorius*, and sends a branch to it.

The *superficial cervical n.* comes from the second and third cervical nerves. It passes transversely forwards over the sterno-mastoid muscle, and supplies the front of the neck. Some of its filaments ascend towards the jaw, and join the cervical branch of the facial nerve; other filaments descend and supply the skin in front of the neck as low as the sternum.

The *descending* or *supra-clavicular* branches are derived from the third and fourth cervical nerves, and divide into three branches, which cross over the clavicle, and supply the skin of the front of the chest and shoulder. Of these, one, called the *internal* or *sternal*, supplies the skin over the inner end of the clavicle and the upper part of the sternum; another, the *middle* or *clavicular*, passes over the middle of the clavicle, and is distributed to the skin over the pectoral muscle, the mammary gland, and the nipple; the third, named *external* or *acromial*, crosses over the trapezius and acromion to supply the skin of the shoulder.

Reviewing these cutaneous branches of the cervical plexus, we find that they have a very wide distribution, for they supply the skin covering the following parts—viz., the ear, the back of the scalp, the side of the cheek, the parotid gland, the front and side of the neck, the upper and front part of the chest and shoulder.

Cervical Branch of the Facial Nerve. Look for this branch beneath the fascia near the angle of the jaw (p. 83). It leaves the parotid gland, and, piercing the deep cervical fascia, divides into filaments which curve forwards below the jaw; some of these, forming arches, join the superficial cervical branch of the cervical plexus; others supply the platysma and skin.

Deep Cervical Fascia. Now turn your attention to the membranous investment called the *deep cervical fascia*, which encloses the several structures of the neck. In some subjects the fascia is very thin; in others, with strong muscles, it is proportionally dense and resisting. It is always stronger in particular situations, for the more effective protection of the parts beneath; for instance, in front of the trachea, in the fossa above the clavicle, and below the angle of the jaw. It not only covers the soft parts of the neck collectively, but, by its inflexions, forms separate sheaths for the muscles, vessels, and glands. It isolates them, and keeps them in their proper relative position. A lengthened description of its numerous layers would be not only extremely tedious, but unintelligible, without considerable knowledge of the anatomy of the neck. We propose, therefore, to give only a general outline of the fascia, and of its principal layers, commencing from behind.

Tracing it from behind, we find that the cervical fascia (sometimes called *deep cervical* or *muscular fascia* of the neck) is attached to the ligamentum nuchæ and to the spinous and transverse pro-

cesses of the cervical vertebræ. From these attachments it passes forwards over the posterior triangle of the neck to the posterior border of the sterno-mastoid, where it splits into two layers, superficial and deep, which invest that muscle and reunite at its anterior border. The superficial layer passes towards the mesial line, where it becomes continuous with the corresponding fascia of the opposite side. The layer which lies in front of the sterno-mastoid is attached above to the base of the inferior maxilla, and passes over the parotid gland to the zygoma, to the mastoid process, and the superior curved line of the occipital bone. Traced downwards, we find it attached to the clavicle and to the upper border of the sternum. In the middle line it is closely connected to the hyoid bone, and below the thyroid body divides into two layers, one being attached to the front of the upper border of the sternum, the other to the back of the upper border of the same bone. Between these layers there is a well-marked interval, containing more or less fat, and one or two small lymphatic glands. This layer forms investing sheaths for the depressor muscles of the os hyoides and larynx.

The deep layer—viz., that which passes beneath the sterno-mastoid—forms the common sheath for the carotid artery, internal jugular vein, and the pneumogastric nerve, which lie behind this muscle; the structures contained in the carotid sheath are separated from each other by delicate septa. The fascia is continued behind the pharynx (constituting the *prævertebral fascia*) to join the fascia of the opposite side, while another prolongation passes in front of the trachea beneath the sterno-thyroid muscle. Below, it is attached to the first rib, to which it binds down the intermediate tendon of the omo-hyoid; and still further down it is continuous in the chest with the pericardium. It may also be traced under the clavicle along the axillary vessels and nerves into the axilla. Above, it is attached to the angle of the lower jaw, from which it extends backwards to the styloid process, and forms the *stylo-maxillary* ligament. Thence it is attached to the base of the skull, the petrous portion of the temporal bone, and the basilar process of the occipital bone.

A correct knowledge of the attachments of the principal layers of the cervical fascia is essential to a right understanding of the course which pus takes when it forms in the neck. For instance, suppose the pus to be formed at the lower part of the neck. If it be seated under the superficial layer (which is attached to the clavicle), it may burrow beneath the clavicle into the axilla. But if it be seated beneath the deep layer (which is attached to the first rib), then it becomes more serious, since the pus may travel through the loose tissue by the side of the pharynx, and make its way into

the chest, where it may burrow down the anterior or the posterior mediastinum, and burst into the trachea or the œsophagus.

Besides forming sheaths for the several structures of the neck, there are other purposes to which the cervical fascia is subservient. The firm attachment of its layers to the sternum, the first rib, and the clavicle, forms a fibrous barrier at the upper opening of the chest, which supports the soft parts, and prevents their yielding to the pressure of the atmosphere during inspiration. Dr. Allan Burns* first pointed out this important function of the cervical fascia, and has recorded a case exemplifying the results of its destruction by disease.

Moreover, the great veins at the root of the neck, namely, the internal jugular, subclavian, and innominate, are so closely united by the cervical fascia to the adjacent bones and muscles, that when divided they gape. They are, as the French express it, "*canalisés*," and are therefore better able to resist the pressure of the atmosphere, which tends to render them flaccid and impervious during inspiration. But this anatomical disposition of the great veins makes them more liable to the entrance of air when wounded. Instances of death have been recorded, resulting from the sudden entrance of air into the veins during operations about the neck, or even the axilla.

**Sterno-cleido-
mastoideus.**

The sterno-cleido-mastoideus is the large muscle which passes obliquely across the neck.

It *arises* by a rounded tendon from the upper part of the sternum, and by fleshy fibres from the sternal third of the clavicle. It is *inserted* by a thick tendon into the external surface of the mastoid process, and by a thin aponeurosis into about the outer half of the superior curved ridge of the occipital bone.

The sternal origin of the muscle is at first separated from the clavicular by a slight interval; subsequently the sternal fibres gradually overlap the clavicular. The muscle is confined by its strong sheath of fascia, in such a manner that it forms a slight curve, with the convexity forwards. Observe especially that its front border overlaps the common carotid artery; along this border we make the incision in the operation of tying the vessel.

**Action of Sterno-
mastoid.**

When both sterno-mastoids act simultaneously they draw the head and neck forwards and downwards, and are therefore especially concerned in raising the head from the recumbent position. When one sterno-mastoid acts singly, it turns the head obliquely towards the opposite shoulder; in this action it co-operates with the splenius

* "Surgical Anatomy of the Head and Neck."

of the other side.* On emergency, the sterno-mastoid acts as a muscle of inspiration, by raising the sternum; its fixed point being, in this case, at the head.

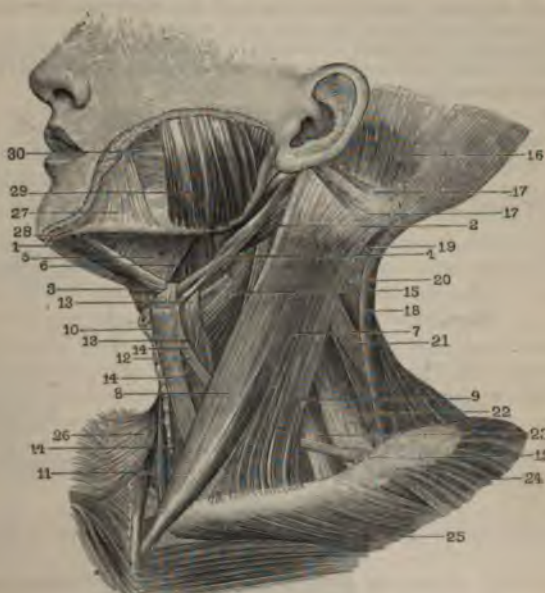

FIG. 34.—STERNO-CLEIDO-MASTOID M. AND MUSCLES ABOVE AND BELOW THE HYOID BONE.

1. Anterior belly of the digastric on the left side. 2. Posterior belly of the digastric. 3. Tendon of the digastric and pulley through which it passes. 4. Stylo-hyoid pierced by the posterior belly of the digastric. 5. Mylo-hyoid m. 6. Hyo-glossus m., the anterior part being covered by the preceding muscle. 7. Sterno-cleido-mastoid m. 8. Sternal portion of the sterno-mastoid m. 9. Clavicular portion of the sterno-mastoid m. 10. Sterno-hyoid m. of the left side. 11. Sterno-hyoid m. of the right side. 12, 12. Anterior and posterior bellies of the omo-hyoid m. 13. Thyro-hyoid m. 14, 14. Sterno-thyroid m. 15. Anterior part of the inferior constrictor m. of the pharynx. 16. Occipito-frontalis m. 17, 17. The two fasciculi of the retrahens aurem. 18. Trapezius m. 19. Capitis portion of the splenius capitis et colli m. 20. Colli portion of the same m. 21. Levator anguli scapulae. 22. Scalenus posticus m. 23. Scalenus anticus m. 24. Superior part of the deltoid m. 25. Clavicular portion of the pectoralis major m. 26. Anterior and inferior part of the platysma-myoid m. 27. Depressor anguli oris m. 28. Transverse portion of the preceding m., blending with, although external to, the depressor labii inferioris m. 29. Masseter m. 30. Buccinator m.

* The single action of the muscle is well seen when it becomes rigid and causes a wry-neck. Other means of relief failing, the division of the muscle near its origin is sometimes beneficial in curing the distortion. In deciding as to the propriety of this operation, we should be careful to examine the condition of the other muscles, lest, after having divided the sterno-mastoid, we should be disappointed in removing the deformity.

The sterno-mastoid is supplied by three nutrient arteries—an upper, a middle, and a lower. The upper sterno-mastoid artery, a branch of the occipital, enters the muscle with the n. accessorius, close to the mastoid process of the temporal bone; the middle mastoid is a branch of the superior thyroid, and enters the under surface of the muscle, crossing over the common carotid on a level with the thyroid cartilage; the lower mastoid is a branch of the supra-scapular, and supplies the clavicular portion of the muscle, close to its origin.

The sterno-mastoid is supplied with nerves by the n. accessorius, and by branches from the deep cervical plexus; these branches come from the second and sometimes the third cervical nerves.

Triangles of the Neck.

Anatomists avail themselves of the oblique direction of the sterno-mastoid muscle to divide the neck on each side into two great triangles, an anterior and a posterior (Fig. 35). The base of the anterior

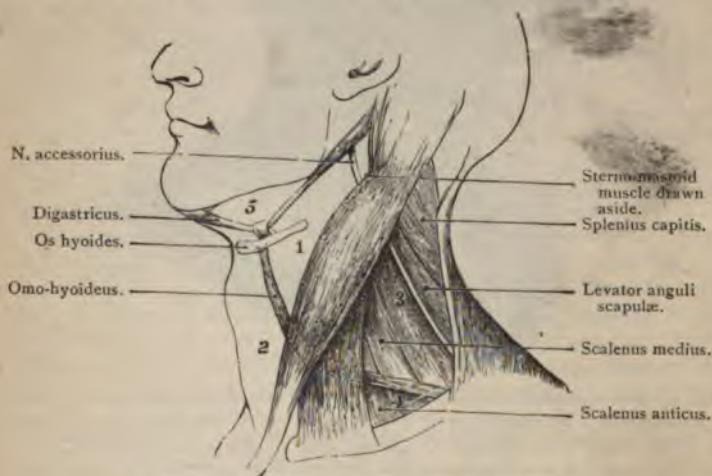

FIG. 35.—DIAGRAM OF TRIANGLES OF THE NECK.

1. Superior carotid triangle. 2. Inferior carotid triangle. 3. Occipital triangle. 4. Supra-clavicular triangle. 5. Submaxillary triangle.

triangle is formed by the jaw, its sides by the mesial line and the front border of the sterno-mastoid. The posterior has the clavicle for the base, while the sides are defined by the hind border of the sterno-mastoid and the front border of the trapezius.

The omo-hyoid muscle, which crosses the neck under the sterno-mastoid, subdivides these primary triangles into four smaller ones (Fig. 35) of unequal size: an anterior superior, an anterior inferior, a posterior superior, and a posterior inferior. The direction of the omo-hyoid muscle renders their boundaries at once obvious.

Contents of Posterior Triangle.

The fat and connective tissue must now be carefully removed from the posterior triangle. The following muscles will be seen forming its floor: viz., beginning from above, the splenius capitis, the levator anguli scapulæ, the scalenus medius and posticus, and a small portion of the serratus magnus. The posterior belly of the omo-hyoid crosses this triangle about an inch (2.5 c. m.) above the clavicle, and subdivides it into two unequal parts—an upper or *occipital*, and a lower or *supra-clavicular*. In the occipital triangle, the larger of the two, besides the muscles just mentioned (with the exception of the serratus magnus), are found the descending branches of the cervical plexus, and passing obliquely downward from beneath the sterno-mastoid is the spinal accessory nerve, which enters the under part of the trapezius. Curving round the posterior border of the sterno-mastoid, and becoming superficial, are the ascending and transverse branches of the superficial cervical plexus. The transversalis colli (posterior scapular) artery and vein, and its branch, the superficialis colli (which chiefly supplies the trapezius), cross transversely outwards the lower part of the space. A chain of lymphatic glands is also found along the posterior border of the sterno-mastoid.

Nervus Accessorius. The upper part of the sterno-mastoid is traversed obliquely by a large nerve called the spinal accessory or n. accessorius. This nerve—the eleventh cranial—consists of two parts: one, the *accessory*, arises from the side of the medulla oblongata below the pneumogastric nerve; the other, the *spinal* part, arises from the cervical portion of the spinal cord by a series of filaments from the lateral tract as low down as the sixth cervical vertebra. The spinal portion ascends between the ligamentum denticulatum and the posterior roots of the spinal nerves, through the foramen magnum into the skull. Within the cranium the two parts unite and form a single nerve, which leaves the skull through the foramen jugulare. Here the *accessory* portion is connected with the ganglion of the root of the pneumogastric by several filaments; and lower down it again joins the pneumogastric at the ganglion of the trunk, below which the two nerves become blended. The accessory and spinal portions communicate in the foramen jugulare. Below the foramen the *spinal* part runs behind the internal jugular vein, the digastric and stylo-hyoid muscles, and then pierces obliquely the upper third of the sterno-mastoid. Emerging beneath its outer border, it crosses the posterior triangle of the neck to the under surface of the trapezius, to which it is distributed. The nervus accessorius supplies also the sterno-mastoid in its passage through it, and here it joins some branches from the third cervical. After leaving the muscle it is joined by branches from the second and third cervical nerves. Beneath the trapezius it forms a plexus with the third and fourth cervical nerves. The upper mastoid artery, a branch of the occipital, enters the sterno-mastoid with the nerve.

Supra-clavicular Triangle.

The *supra-clavicular* or *subclavian triangle* is bounded below by the clavicle, in front by the outer border of the sterno-mastoid, and above by the posterior belly of the omo-hyoid muscle. The area of the

The sterno-mastoid is supplied by three nutrient arteries—an upper, a middle, and a lower. The upper sterno-mastoid artery, a branch of the occipital, enters the muscle with the n. accessorius, close to the mastoid process of the temporal bone; the middle mastoid is a branch of the superior thyroid, and enters the under surface of the muscle, crossing over the common carotid on a level with the thyroid cartilage; the lower mastoid is a branch of the supra-scapular, and supplies the clavicular portion of the muscle, close to its origin.

The sterno-mastoid is supplied with nerves by the n. accessorius, and by branches from the deep cervical plexus; these branches come from the second and sometimes the third cervical nerves.

Triangles of the Neck.

Anatomists avail themselves of the oblique direction of the sterno-mastoid muscle to divide the neck on each side into two great triangles, an anterior and a posterior (Fig. 35). The base of the anterior

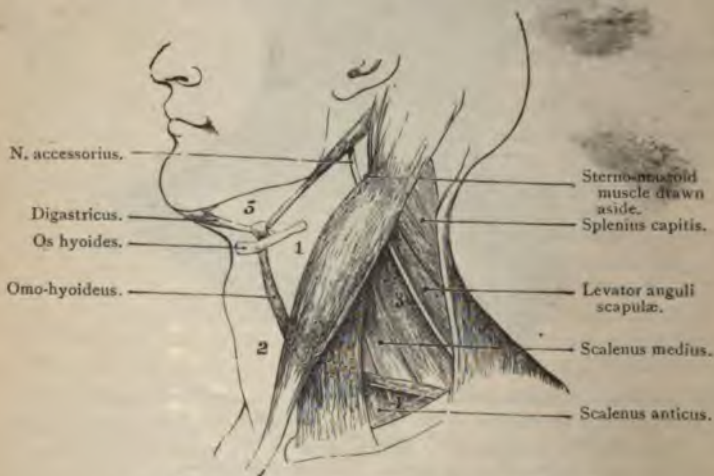

FIG. 35.—DIAGRAM OF TRIANGLES OF THE NECK.

1. Superior carotid triangle. 2. Inferior carotid triangle. 3. Occipital triangle. 4. Supra-clavicular triangle. 5. Submaxillary triangle.

triangle is formed by the jaw, its sides by the mesial line and the front border of the sterno-mastoid. The posterior has the clavicle for the base, while the sides are defined by the hind border of the sterno-mastoid and the front border of the trapezius.

The omo-hyoid muscle, which crosses the neck under the sterno-mastoid, subdivides these primary triangles into four smaller ones (Fig. 35) of unequal size: an anterior superior, an anterior inferior, a posterior superior, and a posterior inferior. The direction of the omo-hyoid muscle renders their boundaries at once obvious.

Contents of Posterior Triangle.

The fat and connective tissue must now be carefully removed from the posterior triangle. The following muscles will be seen forming its floor: viz., beginning from above, the splenius capitis, the levator anguli scapulæ, the scalenus medius and posticus, and a small portion of the serratus magnus. The posterior belly of the omo-hyoid crosses this triangle about an inch (2.5 c. m.) above the clavicle, and subdivides it into two unequal parts—an upper or *occipital*, and a lower or *supra-clavicular*. In the occipital triangle, the larger of the two, besides the muscles just mentioned (with the exception of the serratus magnus), are found the descending branches of the cervical plexus, and passing obliquely downward from beneath the sterno-mastoid is the spinal accessory nerve, which enters the under part of the trapezius. Curving round the posterior border of the sterno-mastoid, and becoming superficial, are the ascending and transverse branches of the superficial cervical plexus. The transversalis colli (posterior scapular) artery and vein, and its branch, the superficialis colli (which chiefly supplies the trapezius), cross transversely outwards the lower part of the space. A chain of lymphatic glands is also found along the posterior border of the sterno-mastoid.

The upper part of the sterno-mastoid is traversed obliquely by a large nerve called the spinal accessory or n. accessorius. This nerve—the eleventh cranial—consists of two parts: one, the *accessory*, arises from the side of the medulla oblongata below the pneumogastric nerve; the other, the *spinal* part, arises from the cervical portion of the spinal cord by a series of filaments from the lateral tract as low down as the sixth cervical vertebra. The spinal portion ascends between the ligamentum denticulatum and the posterior roots of the spinal nerves, through the foramen magnum into the skull. Within the cranium the two parts unite and form a single nerve, which leaves the skull through the foramen jugulare. Here the *accessory* portion is connected with the ganglion of the root of the pneumogastric by several filaments; and lower down it again joins the pneumogastric at the ganglion of the trunk, below which the two nerves become blended. The accessory and spinal portions communicate in the foramen jugulare. Below the foramen the *spinal* part runs behind the internal jugular vein, the digastric and stylo-hyoid muscles, and then pierces obliquely the upper third of the sterno-mastoid. Emerging beneath its outer border, it crosses the posterior triangle of the neck to the under surface of the trapezius, to which it is distributed. The nervus accessorius supplies also the sterno-mastoid in its passage through it, and here it joins some branches from the third cervical. After leaving the muscle it is joined by branches from the second and third cervical nerves. Beneath the trapezius it forms a plexus with the third and fourth cervical nerves. The upper mastoid artery, a branch of the occipital, enters the sterno-mastoid with the nerve.

Supra-clavicular Triangle.

The *supra-clavicular* or *subclavian triangle* is bounded below by the clavicle, in front by the outer border of the sterno-mastoid, and above by the posterior belly of the omo-hyoid muscle. The area of the

triangle thus formed will vary in proportion to the obliquity of the omo-hyoid muscle, and the extent to which the sterno-mastoid and trapezius are attached to the clavicle. The depth of the vessels and nerves contained in this space depends not only upon the degree to which the clavicle arches forwards, but varies with the elevation and depression of the shoulder.

Dissection.

The descending branches of the cervical plexus, together with some fat, should now be cut through and turned aside, when a layer of a fascia which binds down the omō-hyoid muscle to the clavicle will be exposed. Beneath this is a deeper layer of fascia, which covers the subclavian vessels and brachial plexus of nerves, and descends with them under the clavicle into the axilla. Between these two layers we meet with more or less fat and connective tissue and lymphatic glands continuous with those in the axilla. It will be easily understood how a collection of pus in the axilla may ascend in front of the vessels and point above the clavicle, or, *vice versâ*, how matter formed in the neck may travel under the clavicle and point in the axilla.

Near the posterior border of the sterno-mastoid muscle the external jugular vein passes through both layers of the deep fascia and terminates in the subclavian; but before its termination it is commonly joined by the supra-scapular, the posterior scapular, and other unnamed veins proceeding from the surrounding muscles; so that there is in this situation a *confluence of veins*, which, when large or distended, is exceedingly embarrassing.

The fascia and the glands should be removed, and the following objects carefully dissected. Behind and nearly parallel with the clavicle is the supra-scapular (*transversalis humeri*) artery, a branch of the thyroid axis. A little higher is the *transversalis colli*, or posterior scapular (commonly a branch of the thyroid axis), which crosses the lower part of the neck towards the posterior superior angle of the scapula. Both these arteries are very irregular in respect to their origin, *the last particularly* being often given off from the subclavian in the third part of its course. Search for the outer border of the scalenus anticus, which descends from the transverse processes of the cervical vertebræ to the first rib; running down longitudinally upon it may be seen the phrenic nerve. The subclavian vein lies upon the first rib in front of the insertion of the anterior scalene muscle behind the clavicle, so that it is not usually seen in this triangle. The subclavian artery rises up into the neck as high as an inch (*2.5 c. m.*) above the clavicle, and sometimes on the right side as high as an inch and a half (*3.8 c. m.*). It appears higher than the vein, emerging beneath the outer border of the scalenus anticus, and care must be taken to preserve the small branch from the brachial plexus, which crosses the artery and

proceeds to the subclavius muscle. The large nerves constituting the brachial plexus come out between the scalenus anticus and medius, higher than the subclavian artery, and on a plane posterior to that vessel. These different objects will be described in detail hereafter.

Dissection of the
Anterior Triangle.

The *anterior triangle* must now be dissected. In doing so, notice, before the deep cervical fascia is removed, the arching forwards of the anterior border of the sterno-mastoid muscle, which is connected to the lower jaw by the fascia, so that the common carotid artery is concealed from view before the parts are disturbed. The anterior triangle is bounded behind by the anterior border of the sterno-mastoid, in front by the middle line of the neck, and above by the lower border of the inferior maxilla. Covering the triangle are the superficial and deep cervical fasciæ and the platysma; passing across it are the superficial cervical n., the infra-maxillary branch of the facial nerve; and descending in front is the anterior jugular vein. This space is subdivided by the anterior belly of the omo-hyoid into a *superior* and an *inferior carotid triangle*, and above them is a third triangle mapped out by the converging bellies of the digastric muscle and the lower jaw, and is called the *sub-maxillary* or *digastric triangle* (Fig. 35, p. 90.)

The *inferior carotid triangle* is bounded above and below by the omo-hyoid and sterno-mastoid muscles, and in front by the middle line. The muscles forming its floor are the sterno-hyoid and sterno-thyroid muscles, and lying on them is the anterior jugular vein; in the middle line is the thyroid body covering the trachea.*

The *superior carotid triangle* has for its boundaries the sterno-mastoid, the omo-hyoid, and the posterior belly of the digastricus. Its muscular floor is formed by the hyo-glossus, the middle and inferior pharyngeal constrictors, and the thyro-hyoid. In this space are found the bifurcation of the common carotid into its external and internal divisions, and the following branches of the external carotid—the superior thyroid, lingual, facial, the occipital, and the ascending pharyngeal arteries—their accompanying veins and the internal jugular vein. The nerves seen are the hypoglossal, crossing over the external carotid, the infra-maxillary branch of the facial, the spinal accessory, the superior and external laryngeal nerves, and in front of the carotid sheath is the descendens noni.

The *digastric triangle* will be described subsequently (p. 108).

* The vessels and nerves lying within and upon the carotid sheath are not seen, as they are situated beneath the anterior border of the sterno-mastoid.

fascia prevents matter coming to the surface, when suppuration takes place by the side of the pharynx.

Remove the fascia, and clean the various structures beneath the

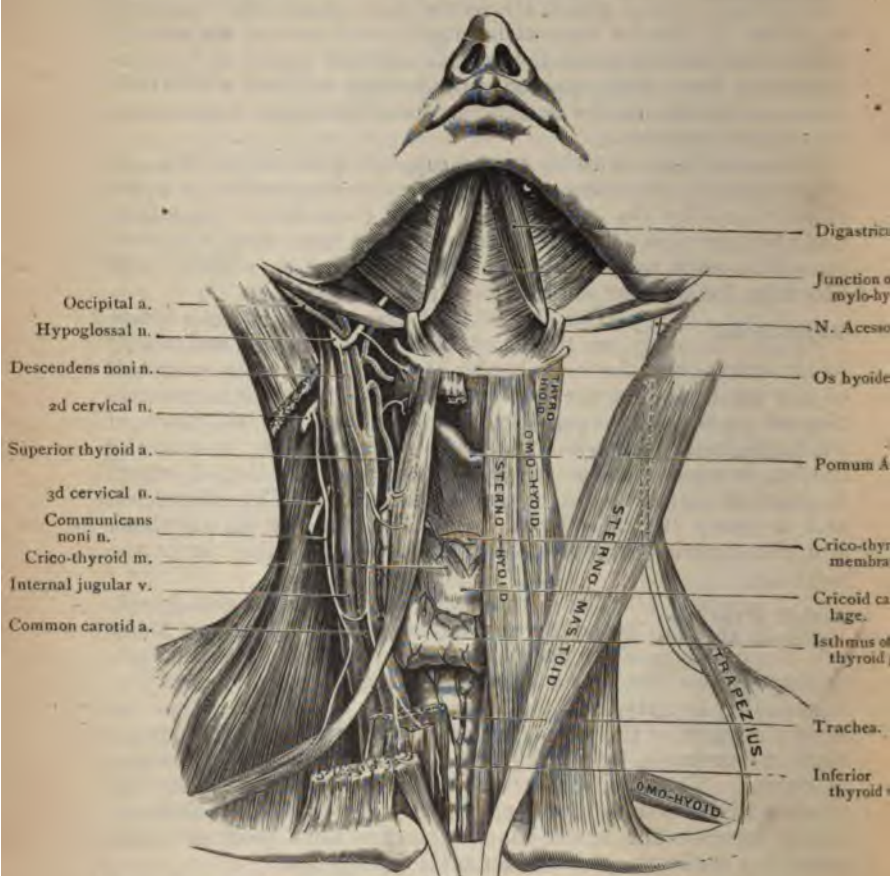


FIG. 36.—CENTRAL LINE OF NECK.—COURSE AND RELATIONS OF COMMON CAROTID ARTERY.

sterno-mastoid, taking care not to cut away the descendens noni and communicantes noni nerves, which lie in front of the sheath of the common carotid. Dissect out the lymphatic glands which lie along the sheath of the large vessels.

The objects exposed to view, when the muscle is reflected, are very numerous. Among these the more important are: the sterno-clavicular articulation, the splenius capitis and colli, the posterior belly of the digastricus, the levator anguli scapulæ, scalenus medius and anticus,

Parts exposed beneath the Sterno-mastoid.

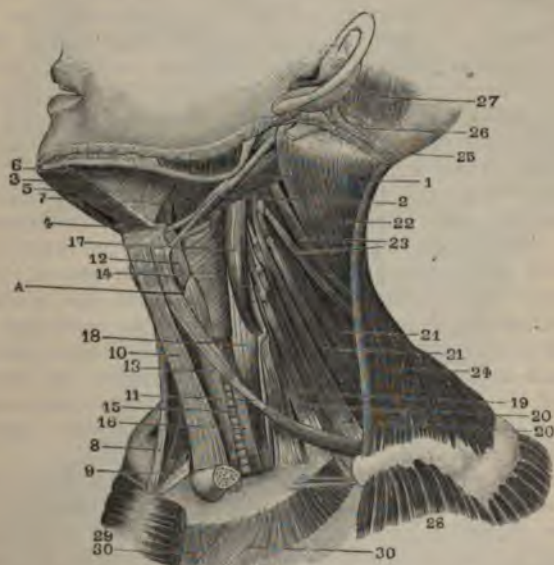


FIG. 37.—MUSCLES OF THE HYOID AND INFRA-HYOID REGIONS.

1. Posterior belly of the digastric m. 2. Stylo-hyoid m. 3. Anterior belly of the digastric m.
4. Tendon and pulley of this muscle. 5. Anterior belly of the right sterno-gastric m. 6. Mylo-hyoid m. 7. Hyo-glossus m. 8. Sternal portion of the right sterno-mastoid m. 9. Sternal portion of the left sterno-mastoid m. 10. Sterno-hyoid m. 11. Tendon of the omo-hyoid m.
12. Thyro-hyoid m. 13. Sterno-thyroid m. A. Oblique line of the thyroid cartilage to which the two preceding muscles are attached. 14. Inferior constrictor m. of the pharynx.
15. Trachea. 16. Oesophagus. 17. Rectus capitis anticus major m. 18. Longus colli m.
19. Scalenus anticus m. 20, 20. Scalenii medius and posticus mm. 21, 21. Fasciculi of the levator anguli scapulæ m. passing to be inserted to the transverse processes of the cervical vertebrae.
22. Splenius capitis m. 23. Splenius colli m. 24. Trapezius m. 25. Attachment of the sterno-mastoid m. 26. Attachment of the two fasciculi of the retrahens aurem m. 27. Occipito-frontalis m. 28. Deltoid m. 29. Attachment (sternal) of the right and left pectoralis major mm. 30. Intercostal muscles.

omo-hyoid, sterno-hyoid, and sterno-thyroid muscles; the occipital artery, the common carotid artery and its division, the internal jugular vein, the subclavian artery and the branches of the first part of its course, the cervical plexus, and the lower cervical nerves which form the brachial plexus; the phrenic, pneumogastric,

hypoglossal, and spinal accessory nerves, the descendens and communicantes noni nerves; the subclavian vein and its tributaries; and lastly, a small part of the parotid gland, and the three sterno-mastoid arteries. On the left side, in addition, we find the thoracic duct; on the right side, the right lymphatic duct.

Course and Relations of the Common Carotid. The *common carotid artery* is now exposed in the whole extent of its course in the neck.

It arises, on the right side from the *arteria innominata*, behind the upper part of the right sterno-clavicular articulation; on the left, from the arch of the aorta. It ascends in front of the bodies of the cervical vertebræ, by the side of the trachea, thyroid gland, and larynx, as high as the upper border of the thyroid cartilage, and then divides into the external and internal carotids. Thus, a line drawn from the sternal end of the clavicle to a point midway between the mastoid process and the angle of the jaw will nearly indicate its course. It is contained in a sheath of the deep cervical fascia, together with the internal jugular vein and the pneumogastric nerve. The vein lies on the outer side of, and parallel with, the artery; the nerve lies behind and between the artery and the vein. The structures contained within this sheath are separated from each other by a thin septum of fascia, so that each has a separate investment. Owing to the increasing breadth of the larynx, the two common carotid arteries, which at their origin lie near together, are separated by a wide interval at their point of division.

At the lower part of the neck the carotid artery is deeply placed, but as it ascends it becomes more superficial, although it has the appearance of being deeply situated owing to the prominence of the thyroid cartilage. *In front* the artery is covered by the skin, superficial fascia, platysma myoides, deep fascia, the sternal portion of the sterno-mastoid, the sterno-hyoid, and thyroid muscles, and, on a level with the cricoid cartilage, it is crossed by the omohyoid. Above this point the artery becomes more superficial, and is covered by the integument, platysma, the cervical fasciæ, the middle sterno-mastoid artery, and only slightly overlapped by the sterno-mastoid. Lying upon the sheath of the artery, we find the descendens noni joined by the communicantes noni nerves. The sheath is crossed by the facial, the superior, and middle thyroid veins, and lower down by the anterior jugular vein, all of which empty themselves into the internal jugular. This is the general rule, and especial attention should be directed to it, because the veins are liable to be overlooked and injured in the operation of tying the carotid. To the *inner side* of the artery we find the trachea, the thyroid body, the recurrent laryngeal nerve, the inferior thyroid artery, the external laryngeal nerve, the inferior

constrictor of the pharynx, and the larynx. On the *outer side* are the pneumogastric nerve and the internal jugular vein.

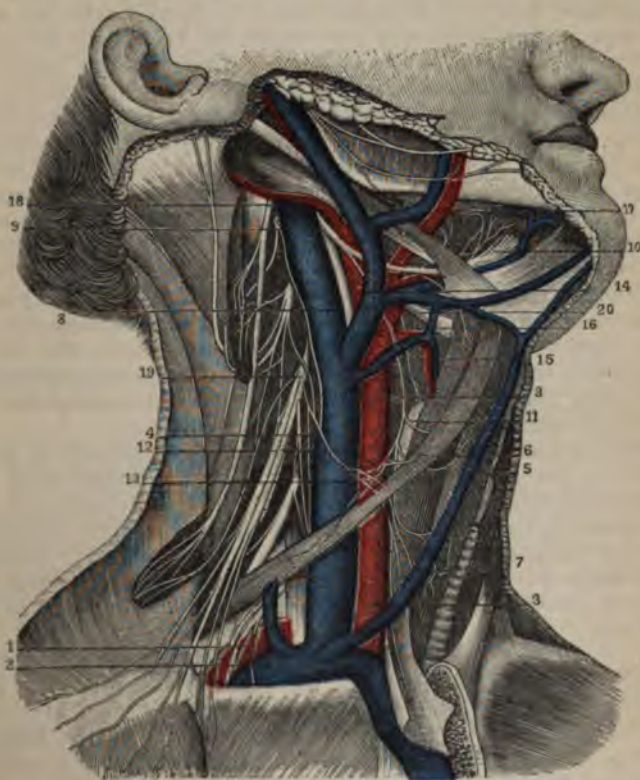


FIG. 38.—RELATIONS OF THE CAROTID ARTERIES.

1. Subclavian artery. 2. Subclavian vein. 3, 3. Common carotid artery. 4. Internal jugular vein. 5. Anterior jugular vein passing in front of the common carotid artery to empty into lower part of the jugular vein. 6. Omo-hyoid muscle. 7. Sterno-hyoid muscle. 8. Trunk of the pneumogastric nerve placed behind the carotid and internal jugular, which it accompanies throughout their course and is seen between them inferiorly. 9. Hypoglossal nerve. 10. Terminal portion of the same. 11. Its descending branch (descendens noni nerve). 12. Descending branch from cervical plexus uniting with the preceding (communicans noni nerve). 13. Plexus formed by the union of the two preceding nerves. 14. Internal carotid artery. 15. Superior thyroid artery and vein. 16. Lingual and facial arteries arising by a common trunk. 17. Facial artery and vein. 18. Occipital artery. 19. Anterior branches of the fourth pair of cervical nerves. 20. Superior laryngeal nerve.

Behind the artery are the sympathetic nerve, the inferior thyroid artery, the recurrent laryngeal nerve; and lastly, the carotid sheath

lies successively upon the longus colli and the rectus capitis anticus major muscles.*

The common carotid may be ligatured either above or below the omo-hyoid. It is most accessible above the point where this muscle crosses; and therefore, if the surgeon has his choice, he would prefer to tie the vessel in this situation. In the higher operation we make an incision, three inches (7.6 cm.) in length, along the inner border of the sterno-mastoid, the centre of the incision being opposite the cricoid cartilage; we cut through the skin, superficial fascia, platysma, deep cervical fascia, when we come to the anterior border of the sterno-mastoid. The overlapping edge of this muscle must be drawn outwards, and the muscle at the same time relaxed by turning the head to the same side. The sheath of the vessel is then exposed, and a small opening is to be made on its inner side large enough to admit the aneurism needle, which should be passed round the artery on its outer side, so as to avoid wounding the internal jugular vein. The vessel is then to be ligatured, care being taken not to separate more of the sheath than is necessary from the artery, and not to include in the ligature the pneumogastric or descendens noni nerves.

After ligation of the artery, the collateral circulation is maintained by the following vessels: between the branches of the external and internal carotid arteries of the opposite side with the corresponding branches of the ligatured side; between the vertebral and the posterior communicating of the same side; between the inferior and superior thyroids of the same side; between the profunda cervicis and the princeps cervicis of the occipital of the same side.

In what respects the
Left Carotid differs
from the Right.

In the first part of its course the left carotid differs from the right in the following particulars:—

1. It arises from the arch of the aorta, is therefore longer and deeper seated than the right, and is covered by the first bone of the sternum.

* It is important that we should be aware that the common carotids vary occasionally in their origin. Thus the right may arise in common with the left carotid, or the right may arise separately from the arch of the aorta, in which case the right subclavian is usually transposed. The left may be given off from the innominate artery of the right side, or it may arise in common with the left subclavian, and thus form a left innominate. In transposition of the aorta there is a left innominate, which is given off first, the right carotid and the right subclavian, arising as separate branches from the arch. The place of division of the common carotid is subject to considerable variation: it may divide higher or lower than usual, the former being the more frequent. Rarely there has been no common carotid artery, the external and internal arising as separate branches from the arch of the aorta.

2. It is crossed by the left brachio-cephalic vein.
3. It is in close relation with the œsophagus and the trachea.
4. It is in close relation with the left recurrent laryngeal nerve.
5. It is in close relation posteriorly with the thoracic duct.
6. It is covered by the thymus gland in early life.

The artery has *in front* the sternum, the sterno-hyoid and sterno-thyroid muscles, the left innominate vein, and the remains of the thymus gland; to the *left side* it has the left subclavian artery and the left pneumogastric nerve; to the *right side* the arteria innominata; and *behind*, the trachea, œsophagus, and thoracic duct.

The common carotid, as a rule, gives off no branch in its course; but, occasionally, the middle sterno-mastoid, the superior thyroid, or, more rarely, the vertebral, arise from it prior to its division. At its bifurcation it usually presents a slight bulbous enlargement, which is sometimes so marked that it might be mistaken for an incipient aneurism. It is necessary to know that the carotid sometimes divides as low as the level of the cricoid cartilage, and that not infrequently the division takes place as high as the hyoid bone.

Internal Jugular Vein.

The internal jugular vein is the continuation of the lateral sinus, and returns the blood from the brain. Leaving the skull through the foramen jugulare, it receives the inferior petrosal sinus, and at the junction it presents a slight enlargement, the *sinus*. The vein descends on the outer side of the internal carotid, and subsequently the common carotid arteries, in the same sheath, and joins the subclavian vein at a right angle to form the brachio-cephalic or innominate vein. - In its course down the neck it receives the pharyngeal, occipital, facial, lingual, superior, and middle thyroid veins.

Previous to their terminations the internal jugular veins incline somewhat to the right side to meet the corresponding subclavian veins; thus, on the right side, there is a triangular interval between the artery and vein in which is seen the pneumogastric nerve and vertebral artery; on the left side the vein slightly overlaps the artery, thus rendering ligature of the left carotid more difficult than of the right. The internal jugular veins, moreover, advance slightly to meet the subclavian veins, so that they lie on a plane a little anterior to their accompanying arteries. A little before their termination the internal jugulars have a double valve.

Descendens Noni and Communicantes Noni Nerves.

The *descendens noni* (p. 99), a branch of the hypoglossal, runs down obliquely over the sheath of the carotid to supply the depressor muscles of the os hyoides. Trace the nerve upwards to see that it leaves the hypoglossal where this nerve curves round the occipital artery. For a short distance the descendens noni lies within the carotid sheath; but, about the level of the os hyoides, it comes through the sheath, and crosses obliquely over the carotid,

from the outer to the inner side. The descendens noni is reinforced by one or more nerves termed *communicantes noni*, derived from the second and third cervical nerves. These communicating branches

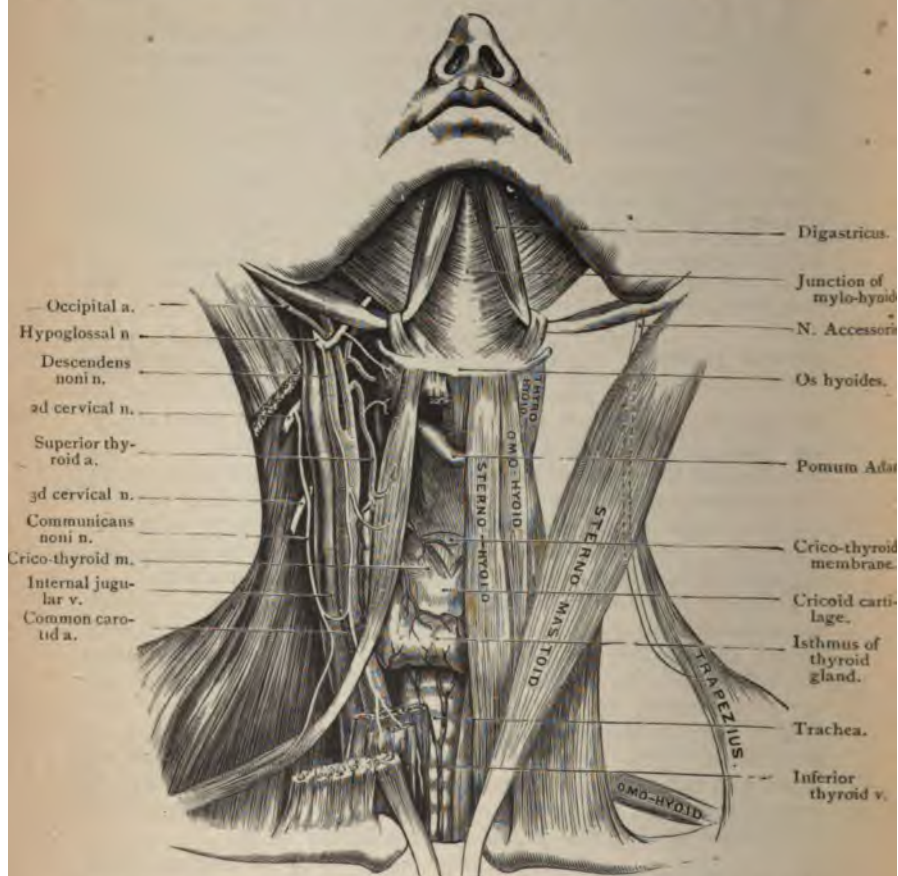


FIG. 39.—CENTRAL LINE OF NECK.—COURSE AND RELATIONS OF COMMON CAROTID ARTERY.

descend on the outer side of the internal jugular vein, and form generally two loops in front of the carotid sheath, constituting a triangular plexus called the "*ansa hypoglossi*." From these loops the nerves proceed to the anterior and posterior bellies of the omo-

hyoid, to the sterno-hyoid and sterno-thyroid muscles. A small branch may sometimes be traced proceeding from the descendens noni into the chest to join the cardiac and phrenic nerves.

In some subjects the descendens noni seems to be wanting, in which case it will probably be concealed *within* the carotid sheath; when this happens the reinforcing loops from the cervical nerves will be found behind the internal jugular vein.*

Dissection. The thyroid body should now be examined. To expose it, reflect the sterno-hyoid and thyroid muscles from their insertions, so that they can be replaced if necessary. Next observe the lymphatic glands of the neck, and lastly survey the objects in the central line of the neck, from the jaw to the sternum.

Thyroid Body. This very vascular gland-like body lies over the front and sides of the upper part of the trachea, and extends upwards on each side of the larynx. It consists of *two lateral lobes*, connected a little below the cricoid cartilage by a transverse portion called the *isthmus*, and weighs from one to two ounces (*28.3 gms. to 56.6 gms.*). Each lobe is conical, about two inches (*5 cm.*) in length, and an inch and a quarter (*3.2 cm.*) in breadth. Its base is opposite the fifth or sixth ring of the trachea, and the apex by the side of the thyroid cartilage. Its anterior surface is convex, and is covered by the sterno-hyoid, sterno-thyroid, and omo-hyoid muscles; its deep surface—concave—embraces the sides of the trachea and larynx, and usually extends so far backwards as to be in contact with the pharynx. Its external border overlaps, in most cases partially, but sometimes completely, the common carotid artery, particularly on the right side; and there are instances in which the lobe is deeply grooved by the vessel.

The isthmus lies over the second and third rings of the trachea. This portion of the organ varies much in its dimensions. In some instances there is no transverse portion. This corresponds with the normal disposition in most of the lower orders of mammalia; but in man, it is a failure in the union of the two halves by which the organ is originally developed.† Generally, the vertical measurement is about half an inch (*13 mm.*). Between its upper border and the cricoid cartilage is a space about one-third of an inch (*8.3*

* By many anatomists the descendens noni is regarded as the combination of filaments from the hypoglossal and pneumogastric nerves; by some it is looked upon as a branch of the pneumogastric; and lastly, which is most probable, it is considered by others to be mainly derived from a branch which is sent to the hypoglossal from the first and second cervical nerves.

† Concerning the development of the lateral halves and central portion of the thyroid body, see a paper by Callender in the *Proceedings of the Royal Society*, 1867.

mm.) in extent, where the trachea is free; this space, therefore, is the more preferable situation for tracheotomy. But the vertical measurement of this isthmus is sometimes of very considerable length, so that it has been seen covering the trachea almost down to the sternum.*

The thyroid body is closely connected, by areolar tissue, to the sides of the trachea, to the cricoid and thyroid cartilages. Hence it rises and falls with the larynx in deglutition.

The thyroid varies in size in different individuals and at different periods of life. It is relatively larger in the child than the adult, in the female than the male. In old age it diminishes in size, becomes firmer, and occasionally contains earthy matter.

By far the most notable considerations in respect to the thyroid body are the number, the large size, and the free inosculation of its *arteries*. The superior thyroid arteries come from the external carotid and enter the front surface of the apex of each lobe; the inferior thyroid come from the subclavian, and enter the under surface of the base. An artery, called the middle thyroid (*thyroidea ima*), is observed in some subjects; it is given off from the *arteria innominata*, or the arch of the aorta, and ascends directly in front of the trachea to the isthmus.

Its *veins* are equally large, and form a plexus upon it. The superior and middle thyroid veins cross the common carotid, and open into the internal jugular. The inferior thyroid veins, two in number, descend over the front of the trachea, communicate freely with each other, and terminate in the left brachio-cephalic vein. When you perform tracheotomy, bear in mind the size of these inferior thyroid veins, and the possible existence of a middle thyroid artery.

Its *nerves* are furnished by the middle and inferior cervical ganglia of the sympathetic. They accompany the arteries.

The *lymphatics* of the thyroid body are both numerous and large. They form a dense network on the surface, and pass into the connective tissue of the gland, and eventually "enclose the primary lobes in complete rings or more or less perfect arches." On the right side they open into the right lymphatic duct, on the left side into the thoracic duct.

* From the upper part of the isthmus, or from the adjacent border of either lobe, most commonly the left, a conical prolongation of the thyroid body, called the *pyramid*, frequently ascends in front of the crico-thyroid membrane, as high as the pomum Adami, and is attached to the body of the os hyoides by fibrous tissue. In some subjects we may observe a few muscular fibres passing from the os hyoides to the pyramid. This constitutes the *levator glandule thyroideae* (see preparation in Museum of St. Barth. Hosp., Patholog. Series, No. 14) of some anatomists. There are instances in which the pyramid is double; and, lastly, we have seen a considerable portion of this thyroid substance lying over the crico-thyroid membrane, completely isolated from the rest of the organ. These varieties deserve notice, because any one portion of this structure may become enlarged independently of the rest, and occasion a bronchocele.

**Structure of the
Thyroid Body.**

The thyroid body belongs to the class of ductless glands, since no excretory duct has been discovered. It is invested by a thin covering of dense areolar tissue, which connects it with the surrounding structures and also penetrates it, imperfectly dividing it into lobes and supporting the vessels as they enter it. It consists of a multitude of closed vesicles, which are imbedded in a delicate reticulum. The function of the gland is probably that of disintegration of the red blood-cells, and of the conveyance into the general lymphatic system of the products of these degenerative changes.

An enlargement of the thyroid body is termed a "bronchocele." If the relation of its lobes to the trachea and œsophagus be properly understood, it is easy to predicate the consequences which may result from their enlargement. The nature and severity of the symptoms will, to a certain extent, be determined by the part of the organ affected. An enlargement of the left lobe is more likely to produce a difficulty in swallowing, on account of the inclination of the œsophagus towards the left side. If the isthmus be enlarged, difficulty in breathing will probably be the prominent symptom, and, in order to remove this danger, the isthmus has been divided, and in part removed.

Small lymphatic glands are observed about the thyroid body, especially in front of the trachea; one is often situated over the crico-thyroid membrane. These glands, if enlarged by disease, might be mistaken for a small bronchocele.

**Deep Cervical Lym-
phatic Glands.**

In the connective tissue which surrounds the great vessels of the neck, we meet with a series of lymphatic glands, called the deep cervical. They form an uninterrupted chain (whence their name *glandulæ concatenate*), from the base of the skull, along the side of the neck, to the clavicle, beneath which they are continuous with the thoracic and the axillary glands. Some of these glands lie anterior to the common carotid artery; others, between it and the spine. This disposition explains the well-known fact, that, when these glands are enlarged, the great vessels and nerves of the neck are liable to become imbedded in their substance.

The glands are particularly numerous near the division of the common carotid, by the side of the pharynx, and the posterior belly of the digastricus. The lymphatics connected with them come from all parts of the head and neck. These vessels unite, to form, on both sides of the neck, one or more absorbent trunks, called the jugular. On the left side this jugular trunk joins the thoracic duct, or opens by a separate orifice into the junction of the left internal jugular and subclavian veins; on the right side it opens into the right lymphatic duct, a short trunk about half an inch in length, which terminates at the angle of the junction of the right internal jugular and subclavian veins. The terminations of the thoracic duct and the right lymphatic duct are guarded by two small semilunar valves, in order to prevent regurgitation of blood back from the veins.

The contiguity of the glands to the great vessels and nerves of the neck explains the symptoms produced by their enlargement. The tumour may be so situated as to be raised and depressed by the pulsation of the carotid, and thus simulate an aneurism. A careful examination, however, will distinguish between an inherent and a communicated pulsation. By grasping the tumour we become sensible that the pulsation does not depend upon any variation of its magnitude, but upon the impulse derived from the artery; consequently, if the tumour be lifted from the vessel, all feeling of pulsation ceases.

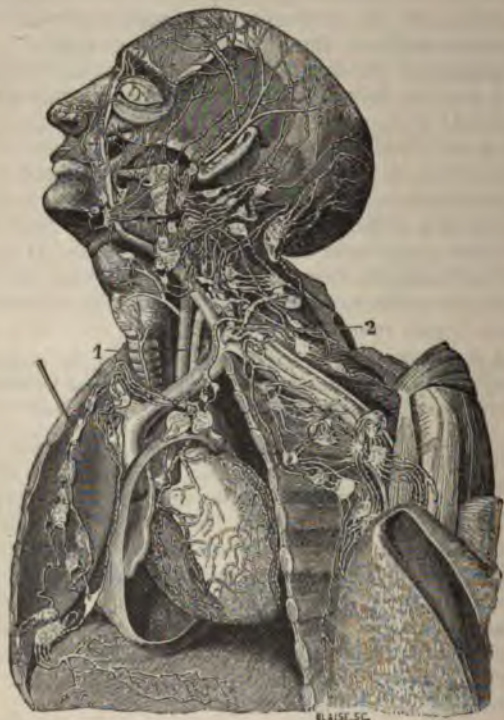


FIG. 40.—LYMPHATIC VESSELS COMING FROM THE GLANDS OF THE NECK AND AXILLA.

1. Superior extremity of the thoracic duct passing behind the internal jugular vein, in an arch.
2. Terminal portion of this arch, which enters in the angle made by the union of the internal jugular and the subclavian veins on the left side.

Survey of the Central Line of the Neck.

The parts in the central line of the neck should now be well studied (Fig. 39, p. 102). Beginning at the chin, we observe the insertions of the digastric muscles. Below these is the junction, or raphé, of the mylo-hyoid muscles. Then comes the os hyoides. Below the

os hyoides is the thyro-hyoid membrane, attached above to the posterior and upper border of the hyoid bone, and below to the thyroid cartilage. Next is the pomum Adami, or projection of the thyroid cartilage, which is apparent between the contiguous borders of the sterno-hyoidei. Below the thyroid cartilage is the cricoid. These two cartilages are connected by the crico-thyroid membrane, across which runs the crico-thyroid artery to join its fellow. Below the cricoid cartilage is the trachea. This is crossed by the isthmus of the thyroid body, and lower down it recedes from the surface, covered by the inferior thyroid veins.

Now the chief surgical interest lies just above, and just below, the-cricoid cartilage. This cartilage can be felt very plainly in the living subject at any age, no matter how fat. In laryngotomy, the crico-thyroid membrane is divided transversely. The membrane should be divided *close* to the edge of the cricoid c., for two reasons: 1. In order to be farther from the vocal cords. 2. To avoid the crico-thyroid artery, which crosses the middle of the membrane. If more room be required, the cricoid cartilage should be divided longitudinally.

In tracheotomy, the trachea may be opened by a perpendicular incision, above the isthmus of the thyroid body, or below it. The operation above the isthmus, if there be space enough for the introduction of the tube, is the easier and safer of the two; for here the trachea is nearer to the surface, and no large blood-vessels are, generally speaking, in the way. The space available measures from a quarter (*6.2 mm.*) to half (*12.5 mm.*) an inch; and the isthmus is not so firmly adherent to the trachea as to prevent its being drawn downwards for a short distance. However, it is right to state that, in one case out of every eight or ten, there is *no* available space.

Tracheotomy below the isthmus is neither an easy nor a safe operation, for many reasons: 1. The trachea recedes from the surface as it descends, so that just above the sternum it is nearly an inch and a half (*3.8 cm.*) from the skin. 2. The large inferior thyroid veins are in the way. 3. A middle thyroid artery may run up in front of the trachea, direct from the arteria innominata. 4. The arteria innominata itself lies sometimes upon the trachea higher than usual, and may, therefore, be in danger. 5. The left brachio-cephalic vein in some cases crosses the trachea above the edge of the sternum instead of below it.

Whoever pays attention to this subject in the dissecting-room will soon be convinced of the fact that not only large veins, but large arteries, occasionally cross the crico-thyroid membrane as well as the trachea, thus showing the necessity of cutting *cautiously* down to, and fairly exposing, the air tube before we venture to

open it. It is preferable, after making the first incision through the skin, to lay aside the sharp knife and to use a blunt one, so that the tissues may be torn rather than cut; by this proceeding the liability to hæmorrhage is materially lessened. Tracheotomy is now safely done with the hypodermic injection of a 5 per cent. solution of hydrochlorate of cocaine with perfect ease to the patient and little or no danger on account of the hæmorrhage carrying off the surplus of the drug. Ether or chloroform is not necessary.

**Dissection of the
Submaxillary Re-
gion or the Digas-
tric Triangle.**

When the platysma and the cervical fascia have been removed from their attachment to the jaw, the most conspicuous object is the submaxillary gland. Observe that the fascia is here very strong, and forms for the gland a complete capsule. Beneath the jaw are several lymphatic glands, from six to ten in number, of which some lie superficial to the salivary gland, others beneath it. These glands receive the lymphatics of the face, the tonsils, and the tongue.

A little dissection will expose a muscle called the digastricus, consisting of two distinct fleshy portions connected by a tendon. They form, with the body of the jaw, a triangle called the *digastric*, of which we propose to examine the contents. The muscles forming its floor are the mylo-hyoideus and hyo-glossus. Under the submaxillary gland is the facial artery, which here runs a tortuous course, and finally turns up over the lower jaw in front of the masseter muscle. Lying on the mylo-hyoideus, under cover of the lower jaw, is the submental artery, accompanied by the mylo-hyoid nerve and artery. Behind the submaxillary gland, and separating it from the parotid, which also is contained within this triangle, is the stylo-maxillary ligament. Ascending and then entering the parotid is the external carotid artery, in front of which is the infra-maxillary branch of the facial nerve. Deep in this space are situated the internal jugular vein, the internal carotid artery, and the pneumogastric nerve; and running obliquely forwards between the internal and external carotid arteries are the stylo-glossus, stylo-pharyngeus, glosso-pharyngeal nerve, and the stylo-hyoid ligament.

Digastricus.

The *digastricus* consists of two muscular bellies united by an intermediate tendon. The posterior belly *arises* from the digastric fossa of the temporal bone, passes obliquely downwards, forwards, and inwards, and then ascends to be *inserted* by its anterior belly close to the symphysis of the lower jaw. Raise the submaxillary gland to see the intermediate tendon of the digastricus piercing the stylo-hyoid muscle, the angle which it forms, and how it is fastened by aponeurosis to the body and the greater cornu of the os hyoides. Observe also that

this aponeurosis—*supra-hyoid aponeurosis*—is connected in the mesial line with its fellow of the opposite side, so that a fibrous expansion occupies the interval between the anterior portions of the digastrici.

The chief action of the digastricus is to depress the lower jaw. But if the lower jaw be fixed, then the muscle raises the os hyoides, as in deglutition.

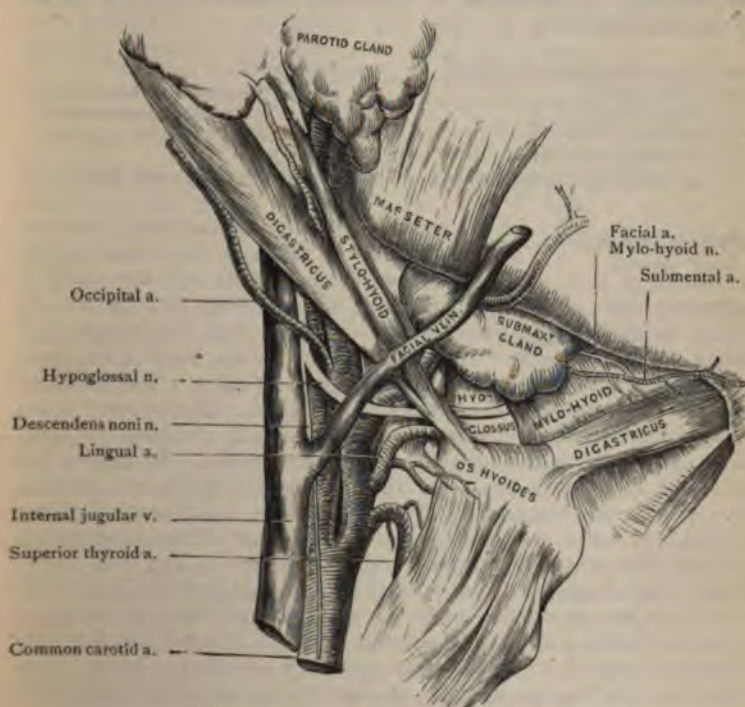


FIG. 41.—DIGASTRIC TRIANGLE AND CONTENTS.

The posterior belly of the digastricus is supplied by a nerve from the facial; the anterior belly by a branch from the mylo-hyoidean nerve (which comes from the third division of the fifth pair).

Stylo-hyoideus. The stylo-hyoideus *arises* from the middle of the styloid process of the temporal bone, and passing downwards and forwards is *inserted* into the body of the os hyoides. This muscle at first runs above the posterior belly of the digastricus, and near its insertion is pierced by the digastric

tendon. Its nerve is derived from the facial close to its exit from the stylo-mastoid foramen, in common with the branch to the posterior belly of the digastricus.* Its action is to raise and draw back the os hyoides.

The digastric triangle is bounded above by the horizontal ramus of the lower jaw, and mastoid process of the temporal bone; behind by the posterior belly of the digastricus; and in front by the anterior belly. The objects to be examined in this triangle are twelve in number, as follow:—

- | | |
|-----------------------------------|---|
| 1. Submaxillary salivary gland. | 7. Stylo-maxillary ligament. |
| 2. Facial vein. | 8. Part of the parotid gland. |
| 3. Facial artery. | 9. Part of the external carotid artery. |
| 4. Submental artery. | 10. Mylo-hyoideus muscle. |
| 5. Mylo-hyoidean nerve. | 11. Hypoglossal nerve. |
| 6. Submaxillary lymphatic glands. | 12. Part of the hyo-glossus muscle. |

Submaxillary Salivary Gland.

In the ordinary position of the head, the submaxillary gland is partially concealed by the jaw, but when the head falls back the gland is more exposed. It is about the size of a chestnut (7 *c.cm.* in volume), weighs about two drachms (8 *gm.*), and is divided into several lobes. Its upper margin is covered by the body of the jaw; its lower margin overlaps the side of the os hyoides. Its cutaneous surface is flat, being covered only by the skin, platysma, and deep cervical fascia; but the lobes on its deep surface are irregular, and often continuous with those of the sublingual gland. By raising the gland we find that it lies upon the mylo-hyoideus, the hyo-glossus, the stylo-glossus, the tendon of the digastricus, and a portion of the hypoglossal nerve, seen above the tendon. Part of the gland passes beneath the posterior border of the mylo-hyoid, and not infrequently becomes continuous with the sublingual gland. The facial artery lies in a groove on its deeper surface, and subsequently upon its upper border; and it is separated from the parotid gland, which is situated behind it, by the stylo-maxillary ligament. Mark these relations well, because they are of importance, as will be presently explained in tying the lingual artery. (See Fig. 22, p. 62.)

The duct of the gland cannot at this stage of the dissection be traced further, for it runs forward, under cover of the mylo-hyoideus, to end in the floor of the mouth, by the side of the frænum linguæ. The description of its course and relations had better, therefore, be deferred till it can be dissected in its whole length with the gustatory nerve in the pterygoid region.

* In many, if not in most subjects, a small filament from the hypoglossal nerve is distributed to this muscle.

Facial Vein.

The facial vein does not accompany the facial artery, but runs nearly a straight course. It leaves the face at the anterior edge of the masseter m., then runs *over* the submaxillary gland, the digastricus and stylo-hyoideus and the carotid artery, to join the internal jugular. This is the rule—but there are frequent exceptions. Before it empties itself into the internal jugular it is joined by a large branch from the external jugular vein. The principal point to remember is, that the vein runs superficial to the gland, and that we must be cautious in opening abscesses under the jaw. (Fig. 38, p. 99.)

Course and Relations of the External Carotid Artery.

The course and relations of the external carotid artery, and its branches in the neck, should now be made out as far as the parotid gland. In preparing a view of them, observe that nearly all the veins lie *in front* of their corresponding arteries. In removing the connective tissue, fat, and lymphatic glands the student must take care of the nerves and other structures which are liable to be injured.

The *external carotid* arises from the common carotid about the level of the upper border of the thyroid cartilage. It ascends to the interval between the ear and the jaw in a slightly curved direction, at first forwards and then backwards. The external and the internal carotids are in the adult nearly of equal size; but the external rapidly diminishes in size, owing to the large branches it gives off within a short distance. At first it *lies beneath* the skin, superficial fascia, platysma myoides, deep cervical fascia, some of the superficial cervical nerves, and the sterno-mastoid muscle. It is next crossed by the hypoglossal nerve, the facial and lingual veins, the posterior belly of the digastricus and stylo-hyoideus; it then enters the parotid gland, where it lies beneath the facial nerve and the external jugular vein, and terminates between the external auditory meatus and the neck of the jaw, by dividing into the temporal and internal maxillary arteries. *Internally* the artery is in relation with the hyoid bone, the pharynx, the parotid gland, and the posterior border of the ascending ramus of the lower jaw.

Behind the external carotid, and separating it from the internal, are the stylo-glossus, the stylo-pharyngeus, the glosso-pharyngeal nerve, and the stylo-hyoid ligament. The superior laryngeal nerve and part of the parotid gland are also placed behind the artery.

Notice the relative position which the external and internal carotids bear to each other. The external lies at first on the same plane with, but nearer to the side of the pharynx than the internal. It soon, however, changes its position, and crosses

obliquely in front of the internal to reach the space between the angle of the jaw and the mastoid process. The internal carotid ascends perpendicularly by the *side of the pharynx* to the base of the skull.

The external carotid gives off the following branches—

- | | |
|--------------------------|------------------------------|
| 1. The superior thyroid. | 5. The posterior auricular. |
| 2. The lingual. | 6. The internal maxillary. |
| 3. The facial. | 7. The temporal. |
| 4. The occipital. | 8. The ascending pharyngeal. |

Superior Thyroid Artery.

The superior thyroid, the first branch of the external carotid, arises just below the great cornu of the os hyoides. It lies in the superior carotid triangle, and, curving downwards and inwards, runs beneath the omo-hyoid, sterno-hyoid, and sterno-thyroid muscles to the upper and front surface of the thyroid body, in which it terminates. Its branches are the four following:—

1. The *hyoid*, a small muscular branch, runs horizontally inwards below the greater cornu of the os hyoides, and anastomoses with its fellow.

2. The *superior laryngeal* branch, accompanied by the superior laryngeal nerve, runs inwards beneath the thyro-hyoid muscle, pierces the thyro-hyoid membrane (sometimes the thyroid cartilage), supplies the muscles and the mucous membrane of the larynx, and anastomoses with its fellow of the opposite side.

3. The *middle sterno-mastoid*, a small branch, variable as to origin, descends over the sheath of the common carotid artery, and enters the under aspect of the sterno-mastoid muscle.

4. The *crico-thyroid*, an artery of great interest in reference to the operation of laryngotomy, crosses the crico-thyroid membrane, and communicates with a corresponding branch on the opposite side. One or two small branches pass through the membrane to the interior of the larynx. It is important to know that the crico-thyroid artery often varies in direction and size. In most cases it is small, and runs across the centre of the membrane; we should therefore be least likely to wound it in laryngotomy, by dividing the membrane close to the cricoid cartilage. But it is by no means infrequent to find this artery of considerable size, taking an oblique or even a perpendicular direction in front of the membrane, and finally distributed to one of the lobes of the thyroid body. We have seen several instances in which the membrane was crossed by the main trunk of the superior thyroid. These facts should establish the practical rule in laryngotomy, not to make an opening into the larynx until it has been fairly exposed.

Among the many arterial inosculation about the thyroid body are two which deserve notice: the one is formed between the two superior thyroid arteries along the upper border of the isthmus; the other takes place along the back part of the lateral lobe between the superior and inferior thyroid arteries of the same side.

The *superior thyroid vein* leaves the upper part of the thyroid body, crosses over the common carotid artery, and joins the internal jugular or the facial vein.

Superior Laryngeal Nerve.

The *superior laryngeal nerve*, mentioned as accompanying the superior laryngeal artery, is given off from the inferior ganglion of the pneumogastric nerve. It descends by the side of the pharynx, behind both carotid arteries, and divides into two

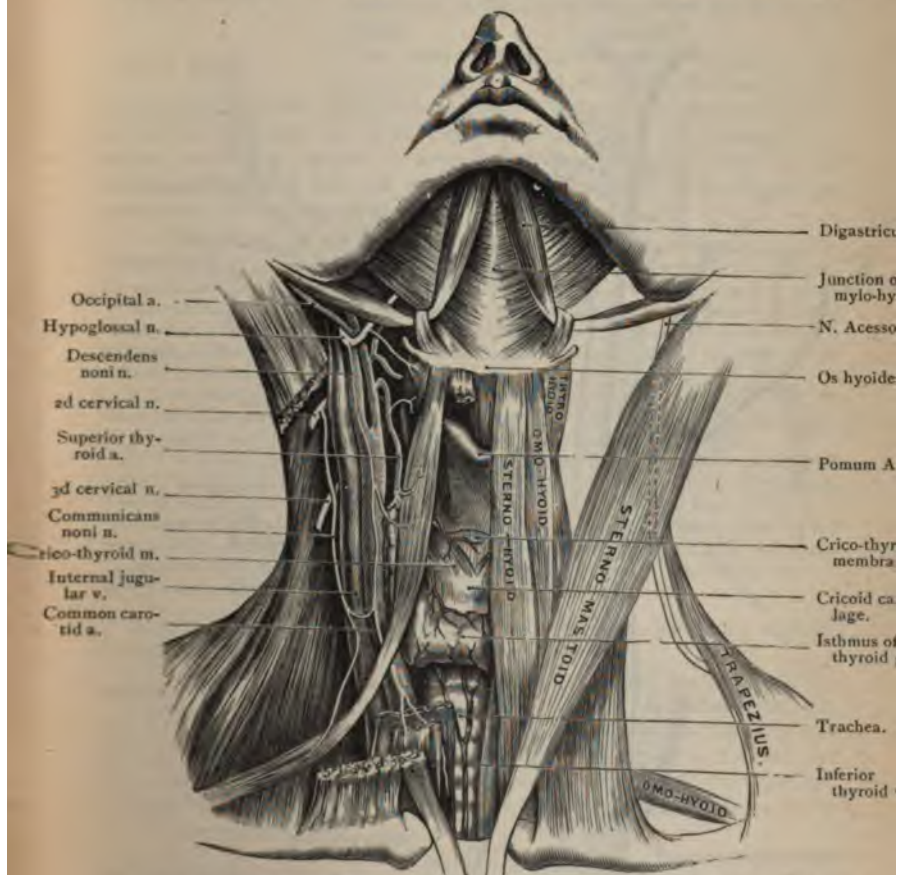


FIG. 42.—CENTRAL LINE OF NECK.—COURSE AND RELATIONS OF COMMON CAROTID ARTERY.

branches—the internal and external laryngeal nerves. The *internal branch* enters the larynx through the thyro-hyoid membrane accompanied by the superior laryngeal artery, and supplies the mucous membrane of the larynx with its exquisite sensibility. Some of its branches may be traced upwards in the ary-epiglottidean fold to supply the epiglottis and the base of the tongue; others descend

to the rima glottidis; a large branch passes down behind the ala of the thyroid cartilage to join the recurrent laryngeal nerve; and a small branch pierces the arytenoideus to supply the mucous membrane beneath it. The *external branch*,

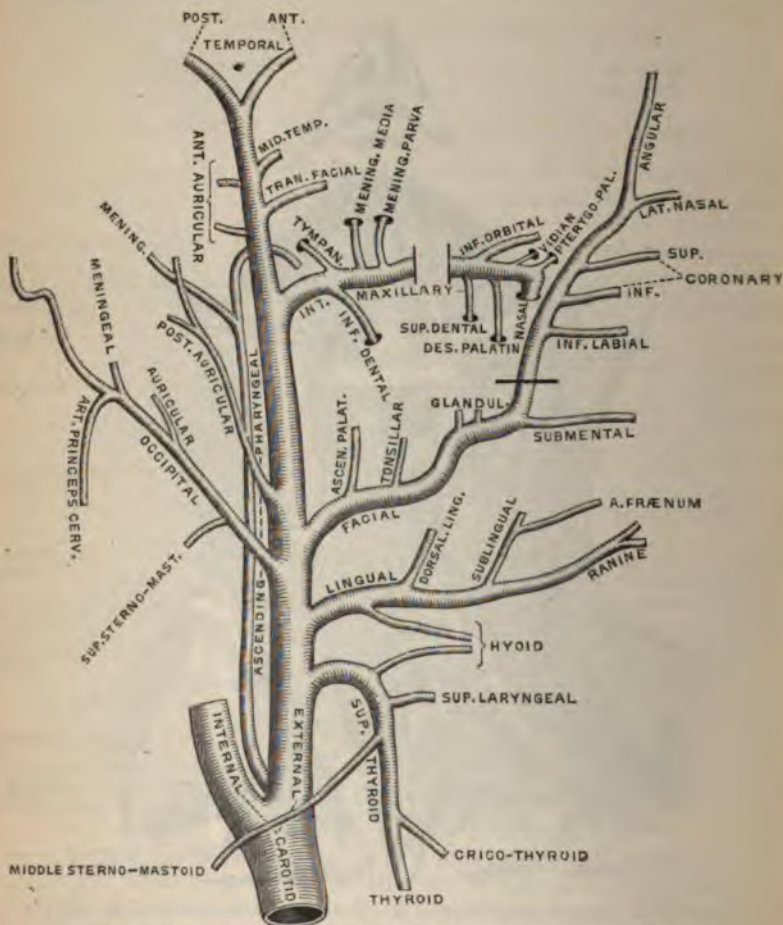


FIG. 43.—DIAGRAM OF THE BRANCHES OF THE EXTERNAL CAROTID ARTERY AND THEIR BRANCHES.

descending beneath the depressors of the larynx, accompanies the crico-thyroid artery, and after distributing filaments to the pharyngeal plexus, supplies the thyroid body, the inferior constrictor, and the crico-thyroid muscles. It receives a

branch from the superior cervical ganglion of the sympathetic, and sends off a cardiac filament to join the superior cardiac branch of the sympathetic behind the common carotid artery.

Lingual Artery. The lingual artery and its branches will be described in the dissection of the submaxillary region.

Facial Artery. The *facial artery* is the third branch of the external carotid. It runs tortuously *under* the hypoglossal nerve, the posterior belly of the digastricus and stylo-hyoideus, and beneath or through the substance of the submaxillary gland to the face, where it appears at the anterior border of the masseter. Below the jaw the facial rests on the mylo-hyoideus, and gives off the four following branches:—

1. The *ascending or inferior palatine artery* runs up between the stylo-glossus and the stylo-pharyngeus m., and behind the internal pterygoid m. to the pharynx, to which and the neighbouring parts it gives branches. Ascending as far as the levator palati, it divides into two branches: one courses along the tensor palati to supply the soft palate; the other enters the tonsil, and anastomoses with the descending palatine of the internal maxillary, and with the tonsillar branches of the ascending pharyngeal.

2. The *tonsillar* runs up between the internal pterygoid and the stylo-glossus m.; then, perforating the superior constrictor, it supplies the tonsil and root of the tongue.

3. *Glandular* branches to the submaxillary gland and side of tongue.

4. The *submental* arises from the facial behind the submaxillary gland, and runs forwards upon the mylo-hyoideus, beneath the inferior maxilla, distributing branches in its course to the gland and the adjacent muscles. It then curves over the bone and divides into two branches: a superficial one, which supplies the skin and lip; and a deep one, which runs between the muscles and the bone, and inosculates with the mental and inferior labial arteries. Beneath the inferior maxilla it usually inosculates with the sublingual artery.

The remaining branches of the external carotid artery will be described later on.

Mylo-hyoidean Nerve. Look for the mylo-hyoidean nerve near the submental artery. The nerve comes from the inferior dental (before its entrance into the dental foramen), and running along a groove on the inner side of the inferior maxilla, advances between the bone and the internal pterygoid m., to supply the mylo-hyoideus and the anterior belly of the digastricus (Fig. 44).

Submaxillary Lymphatic Glands. The submaxillary lymphatic glands receive the lymphatics of the face and the tongue. They are often enlarged in cancerous diseases of the tongue or the lower lip. It should be remembered also that there are lymphatic glands in the mesial line below the chin.

Mylo-hyoideus. The mylo-hyoideus, a triangular muscle, *arises* from the mylo-hyoid ridge of the lower jaw, from the symphysis, as far back as the last molar tooth (Fig. 41).

Its posterior fibres are *inserted* into the body of the os hyoides, the anterior being attached to a median tendinous line, termed the *raphé*. Thus the muscles of opposite sides form a muscular floor for the mouth. Superficially, it is in relation with the anterior belly of the digastricus, the submaxillary gland, the submental artery, and the mylo-hyoidean n. By its deep surface, it is in rela-

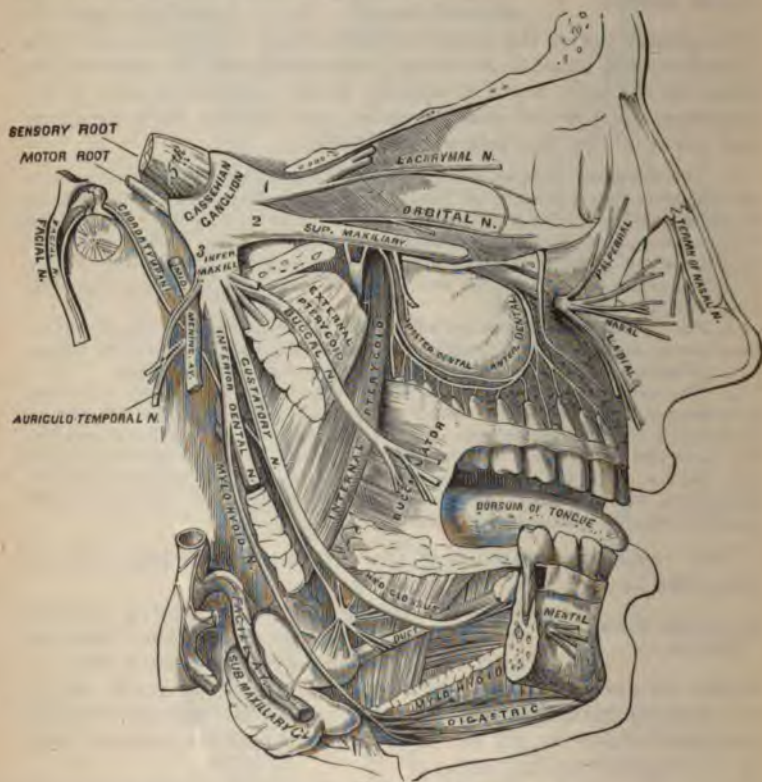


FIG. 44.

tion with part of the hyo-glossus, the stylo-glossus, the genio-hyoideus, Wharton's duct, the gustatory and hypoglossal nerves with their communications, and the sublingual gland. It is supplied with nerves by the mylo-hyoide branch of the inferior dental; with blood by the submental artery. The muscles of opposite sides conjointly elevate the os hyoides and the floor of the mouth—as in deglutition.

**Stylo-maxillary
Ligament.**

This is a layer of the deep cervical fascia, extending from the angle of the jaw to the styloid process. It is a broad sheet of fascia, and separates the submaxillary gland from the parotid. It is continuous with the fascia covering the pharynx; this gives it a surgical interest, because it prevents accumulations of matter formed near the tonsils and upper part of the pharynx from coming to the surface.

The remaining objects seen in the submaxillary triangle—namely, the parotid gland, the hypoglossal nerve, the hyo-glossus muscle—will be described presently when they can be better seen. Your attention should now be directed to a piece of surgical anatomy, which will enable you readily to find and tie the lingual artery. It is this:—

A curved incision, about two inches (5 *cm.*) in length, being made from the lesser cornu along the upper border of the great cornu of the os hyoides, through the skin, the platysma, and the cervical fascia, you will come upon the lower edge of the submaxillary gland. Lift up the gland, which is easily done, and underneath it you will observe that the tendon of the digastricus makes two sides of a triangle, of which the base is formed by the hypoglossal nerve crossing the hyo-glossus muscle. Within this little triangle, cut transversely through the fibres of the hyo-glossus: under them is the lingual artery, lying on the middle constrictor. The first time you perform this operation on the dead subject, you will not unlikely miss the artery and cut through the middle constrictor into the pharynx.

Dissection.

The facial vessels must now be divided immediately below the jaw. Reflect the anterior belly of the digastricus from its insertion; detach the mylo-hyoides from the middle line and the os hyoides, and turn it over the body of the jaw, taking care not to injure the muscles and structures beneath. The lower jaw must now be sawn through, a little to the dissector's side of the symphysis, and the bone drawn upwards by hooks. The tongue should then be drawn out of the mouth, and fastened by hooks. The os hyoides should be drawn down by means of hooks, so as to put the parts on the stretch. All this done, we have to make out, by carefully cleaning away the fat and connective tissue, the following objects represented in Fig. 45:—

- | | |
|-----------------------|---------------------------|
| 1. Genio-hyoideus. | 6. Sublingual gland. |
| 2. Hyo-glossus. | 7. Hypoglossal nerve. |
| 3. Stylo-glossus. | 8. Gustatory nerve. |
| 4. Genio-hyo-glossus. | 9. Submaxillary ganglion. |
| 5. Submaxillary duct. | 10. Lingual artery. |

Genio-hyoideus.

The *genio-hyoideus* arises from the inferior tubercle behind the symphysis of the jaw, and passes downwards and backwards to be inserted into the front of the body of the os hyoides. This round muscle is situated in the mesial line, parallel to its fellow. Its nerve comes from the hypoglossal, and its blood from the lingual artery. Its action is to draw the os hyoides forwards and upwards; and, if the hyoid bone be fixed, it depresses the lower jaw.

Hyo-glossus.

The *hyo-glossus* arises from the body, the greater and lesser cornua of the os hyoides,

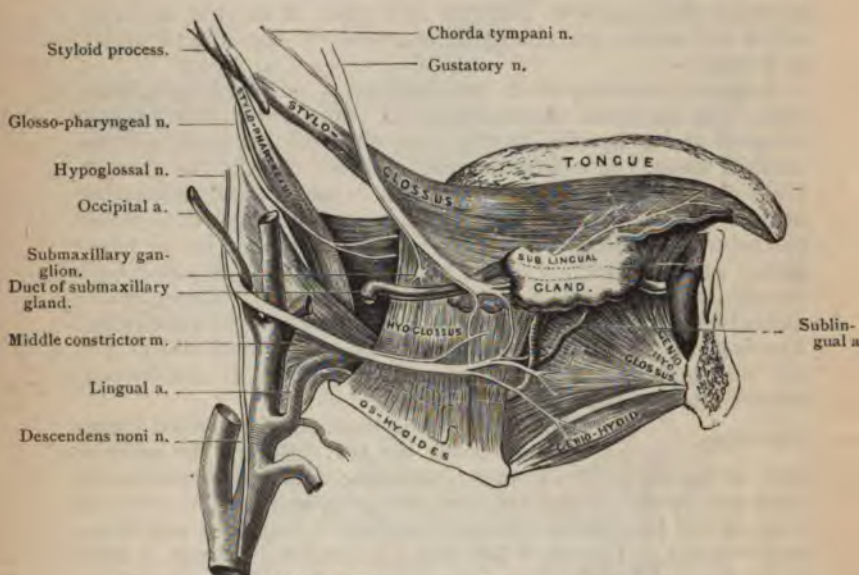


FIG. 45.—MUSCLES, VESSELS, AND NERVES OF THE TONGUE.

and is inserted into the posterior two-thirds of the side of the tongue, its fibres blending with the stylo-glossus and palato-glossus. It is a square and flat muscle, and its fibres ascend nearly perpendicularly from origin to insertion. The fibres arising from the body of the hyoid bone, termed the *basio-glossus*, are directed backwards and upwards, and overlap the fibres which have their origin from the greater cornu and are termed the *kerato-glossus*. Those that arise from the lesser cornu are termed the *chondro-glossus*. The nerve to the *hyo-glossus* comes from the

hypoglossal, and its blood from the lingual. Its action (with that of its fellow) is to depress the tongue. Observe the objects which lie *upon* the hyo-glossus; namely, the hypoglossal and gustatory nerves (which at the anterior border form one or more loops of communication with one another), the chorda tympani nerve, the submaxillary ganglion, the submaxillary gland and its duct, the hyoid branch of lingual artery, the lingual vein, the sublingual gland, the digastricus, stylo-hyoid, stylo-glossus, and mylo-hyoid muscles. *Beneath* the hyo-glossus muscle lie the lingual artery and vein, part of the middle constrictor of the pharynx, part of the genio-hyo-glossus, the lingualis, and the glosso-pharyngeal nerve.

Genio-hyo-glossus. The genio-hyo-glossus *arises* by a tendon from the upper tubercle behind the symphysis of the lower jaw, and is *inserted* as follows: the lower fibres into the body of the os hyoides; the upper fibres into the tongue from the base to the apex. It is the largest and most important of the muscles of the tongue. It is fan-shaped, with the apex attached to the symphysis; thence its fibres radiate into the entire length of the tongue. *Externally*, the muscle is in relation with the stylo-glossus, lingualis, and hyo-glossus, the lingual artery, the sublingual gland, Wharton's duct, the hypoglossal and gustatory nerves; *inferiorly*, by its lower border it is in contact with the genio-hyoid; *above*, by its anterior border, with the mucous membrane of the mouth; and *internally*, it is in contact with its fellow and the fibrous septum of the tongue. It derives its nerves from the hypoglossal, and its blood from the lingual artery. Its action is various. The posterior fibres, by raising the os hyoides and drawing forwards the base of the tongue, protrude the tongue out of the mouth; the anterior draw the tongue back again. When every part of the muscle acts, it draws down the whole tongue, and is therefore one of the chief muscles concerned in suction.

Stylo-glossus. The stylo-glossus, a long and slender muscle, *arises* from the outer side of the styloid process near its apex and from the stylo-maxillary ligament; its fibres pass downwards and forwards, and then nearly horizontal, and are *inserted* along the side of the tongue. It runs outside the hyo-glossus nearly to the tip of the tongue, and blends with the fibres of this muscle, as well as with the palato-glossus. Its nerve comes from the hypoglossal. Its action is to retract the tongue.

Hypoglossal Nerve. The hypoglossal, or twelfth cranial nerve, is the *motor* nerve of the muscles of the tongue. It arises by several filaments, twelve to fifteen, from the front of the medulla oblongata between the anterior pyramid and the olivary body. It pierces the dura mater in two fasciculi which leave the skull through the anterior condylar foramen; these subsequently

blend to form a single nerve trunk. It lies deeply beneath the internal jugular vein and internal carotid artery, where it is intimately connected with the lower ganglion of the pneumogastric nerve; it then comes up between the artery and vein, and, immediately below the posterior belly of the diaphragm, curves forwards over the occipital, the internal and external carotid, and facial arteries. Next it crosses the hyo-glossus muscle, and passing beneath the mylo-hyoid, divides into branches which supply the following muscles; namely, the stylo-glossus, hyo-glossus, genio-glossus, lingualis, and the genio-hyoideus.

As it curves round the occipital artery, the hypoglossal nerve sends the *descendens noni* to the depressors of the os hyoides (p. 118). It also sends a nerve to the thyro-hyoideus, which proceeds from it where it crosses over the external carotid, accompanied by the hyoid branch of the lingual artery. Near the anterior border of the hyo-glossus it communicates by several-loops with the gustatory nerve. (Fig. 45.)

The hypoglossal at its origin is purely a *motor* nerve. But after leaving the skull, it receives communications from the first two cervical nerves. These communications are important physiologically for two reasons: 1. They account for the hypoglossal nerve containing sensory fibres. 2. They contribute the greater part of the filaments of the *descendens noni*. It is also connected by small branches with the pneumogastric nerve and the superior cervical ganglion of the sympathetic at the base of the skull.

Sublingual Gland. The sublingual gland lies immediately beneath the mucous membrane of the floor of the mouth. Its shape is oblong, with the long axis (about an inch and a half, 3.6 cm.) directed from before backwards, and it weighs 45 grains (3 gm.); its volume is 2.5 c.cm. Its relations are as follows: *above*, it is covered with mucous membrane; *below*, it rests upon the upper surface of the mylo-hyoid muscle; *internally*, it is in contact with the hyo-glossus, genio-hyo-glossus, stylo-glossus, the gustatory nerve, and Wharton's duct—its length is 1½ inches (3.8 cm.), breadth ½ of an inch (2 mm.); *posteriorly*, with the submaxillary gland; and in *front*, it rests in a depression behind the symphysis of the lower jaw.

The ducts of the sublingual gland (ducts of Rivinus) vary in number from eight to twenty. They terminate by minute openings behind the orifice of the submaxillary duct, along the ridge felt upon the floor of the mouth. One or more ducts terminate in the submaxillary duct; one of these takes the name of the *duct of Bartholin*. Its length is a little more than ¾ of an inch (20 mm.), breadth ⅓ of an inch (1 mm.).

The duct of the submaxillary gland may now be traced across

the hyo-glossus, and under the gustatory nerve to the floor of the mouth.

Lingual or Gustatory Nerve.

This nerve is a branch of the inferior maxillary or third division of the fifth pair of cranial nerves. Emerging beneath the external pterygoid muscle, in company with, but in front of, the inferior dental nerve, it rests upon the internal pterygoid muscle. It descends between this latter muscle and the ramus of the lower jaw, and curves forwards towards the side of the tongue over the superior constrictor of the pharynx, along the upper part of the hyo-glossus, at the anterior border of which it crosses, superficially, the duct of the submaxillary gland (Fig. 44, p. 116). Having reached the under part of the tongue, the nerve divides into numerous branches which pierce the muscular structure of the tongue, and then break up into filaments which supply the mucous membrane and the fungiform and filiform papillæ on its anterior three-fourths. Beneath the external pterygoid it is joined at an acute angle by the chorda tympani, a branch of the facial nerve; in its course it gives off some communicating branches to the hypoglossal nerve near the anterior border of the hyo-glossus. It supplies also the mucous membrane of the mouth, gums, and the sublingual gland, one or more branches to the submaxillary ganglion, and at the apex of the tongue the terminal branches of this nerve and the hypoglossal are connected.

Submaxillary Ganglion.

At the lower border of the gustatory nerve as it lies upon the hyo-glossus muscle, and before it crosses the submaxillary duct, you will find a small, convex, triangular ganglion, about the size of a pin's head. Like the other ganglia in connection with the branches of the fifth pair, it receives filaments of *communication* of three different kinds—viz., motor, sensory, and sympathetic. Its motor root is the chorda tympani, derived from the facial nerve; its sensory branches proceed from the gustatory; and its connection with the sympathetic system is established by a branch which comes from the *nervi molles* round the facial artery. The ganglion supplies five or six branches of *distribution* to the submaxillary gland, its duct, and the mucous membrane of the floor of the mouth. Meckel describes a small branch of the ganglion which sometimes passes forwards to join a branch of the hypoglossal, on the hyo-glossus m., and ends in the genio-hyo-glossus.

Lingual Artery.

The lingual artery is generally the second branch of the external carotid. Curving slightly upwards and inwards from its origin, the artery soon runs forwards round the great cornu of the hyoid bone, beneath the posterior belly of the digastricus and stylo-hyoideus, and then passes beneath the hyo-glossus m. parallel to the os hyoides. At

the anterior edge of the hyo-glossus it ascends to the under surface of the tongue, and is continued forwards to the apex of the tongue under the name of *ranine*. Before the artery passes beneath the hyo-glossus, it is crossed by the hypoglossal nerve, but it immediately after becomes separated from the nerve by this muscle. Under the hyo-glossus the artery lies upon the middle constrictor of the pharynx, and the genio-hyo-glossus; in the substance of the tongue it lies between the genio-hyo-glossus and the inferior lingualis. The curves made by the artery are for the purpose of allowing the elongation of the tongue. Its branches are (Fig. 43, p. 114):—

1. The *hyoid*, a small artery which runs along the upper border of the hyoid bone, supplying the muscles and anastomosing with its fellow, and with the hyoid branch of the superior thyroid artery. The nerve to the thyro-hyoid muscle, which is derived from the hypoglossal, accompanies this artery.

2. The *dorsales linguae*, two or more, run under the hyo-glossus to the back of the tongue, the mucous membrane, tonsil, and soft palate.

3. The *sublingual*, arising near the anterior border of the hyo-glossus, supplies the sublingual gland, the mylo-hyoideus, and the mucous membrane of the mouth and gums. This artery generally gives off the little artery of the *frænum linguae*, which is sometimes wounded in cutting the *frænum* in children who are tonguetied, especially when we neglect the rule of pointing the scissors downwards and backwards.

4. The *ranine* is the termination of the lingual artery. As it runs forwards to the tip of the tongue along the outer side of the genio-hyo-glossus, along with the gustatory nerve, it distributes branches to the tongue, and at the tip inosculates slightly with its fellow of the opposite side.

The *ranine vein*, commencing at the tip of the tongue, after joining with the venæ comites of the lingual artery and the dorsal veins of the tongue, runs along its under surface *over* the hyo-glossus, and terminates in the internal jugular or facial vein.

The best place for finding and tying the lingual artery has been mentioned (p. 117). The rule laid down is trustworthy only when the artery runs its normal course. We have known an instance in which a good anatomist failed in an attempt to tie the lingual artery, because the vessel arose from the facial behind the submaxillary gland, and then passed through the mylo-hyoideus to reach the tongue.

The occipital artery arises from the posterior part of the external carotid, usually opposite the facial artery, and runs upwards and backwards along the lower border of the digastricus towards the mastoid process. It passes then under the posterior belly of the digastricus, and further on in its course it lies in the interval between the transverse process of the atlas and the mastoid process, close to the rectus capitis lateralis; it now changes its direction, for it runs horizontally backwards in the occipital groove of the temporal bone, under all the muscles

attached to the mastoid process—namely, the sterno-mastoid, the splenius capitis, the trachelo-mastoid, and the digastricus, and it lies on the superior oblique and the complexus. Arrived at the back of the head, the artery pierces the cranial attachment of the trapezius, and ascending, divides into wide-spreading branches for the supply of the scalp.

In the first part of its course, the occipital artery crosses over the internal carotid artery, the internal jugular vein, the pneumogastric and the spinal accessory nerves, and is itself crossed by the hypoglossal nerve. It sends off the seven following branches:—

1. *Muscular* branches to the digastric, stylo-hyoid, splenius, and trachelo-mastoid muscles.

2. The *superior sterno-mastoid*, which enters the muscles with the *nervus accessorius*.

3. The *auricular* ramifies on the cranial aspect of the concha.

4. The *posterior meningeal* ascends with the internal jugular vein, and enters the cranium through the foramen jugulare to supply the dura mater of the posterior fossa.

5. The *princeps cervicis*, which we shall see better hereafter, is a short trunk which runs down the back of the neck, and divides into two branches—a superficial, lying beneath the splenius, and supplying also the trapezius, and a deep branch lying under the complexus, and anastomosing with branches of the vertebral and with the deep cervical branch of the superior intercostal artery between this muscle and the semi-spinalis colli.

6. The *mastoid* enters the foramen in the mastoid process, and supplies the dura mater.

7. The *cranial* branches supply the scalp on its posterior aspect, and anastomose freely with the corresponding artery of the opposite side, the posterior auricular and the superficial temporal arteries.

The *occipital vein* accompanies the artery, and is connected with the lateral sinus through a small vein running through the mastoid foramen. It subsequently terminates in the internal jugular, occasionally in the external jugular vein.

Posterior Auricular Artery.

The posterior auricular artery (Fig. 43, p. 114), the fifth branch, is given off from the posterior part of the external carotid. It arises above the digastricus, lies on the styloid process, and under cover of the parotid gland reaches the furrow between the cartilage of the ear and the mastoid process. Before it reaches the furrow it is crossed by the facial nerve,* and just beneath it is the spinal accessory. Above the mastoid process it divides into two branches, a posterior inosculating with the occipital, and an anterior communicating with the temporal. It supplies the back of the scalp and the cartilage of the ear. It gives off—

1. Small branches to the digastricus, stylo-hyoid, and the parotid gland.

* The posterior auricular artery frequently runs superficial to the facial nerve.

2. The *stylo-mastoid*, a very constant little artery, which runs through the stylo-mastoid foramen to supply the mastoid cells, the vestibule, and the membrana tympani. In young subjects, one of these latter branches forms a vascular circle around the circumference of the membrane with the tympanic branch of the internal maxillary.

3. The *auricular* branch runs along the cranial surface of the auricle, and anastomoses with the superficial temporal and occipital arteries. Some of the branches pierce the cartilage of the ear and ramify on its anterior surface.

4. The *mastoid* branch is distributed to the structures over the mastoid process.

The *posterior auricular* vein is rather large, and running over the mastoid process, terminates in the external jugular vein.

Posterior Auricular Nerve. The posterior auricular nerve lies close to the artery of the same name. It is the first branch of the seventh or facial nerve after its exit from the stylo-mastoid foramen. It runs behind the ear and divides into an *auricular* branch to the retrahens and the attollens aurem, and an *occipital* branch to the posterior belly of the occipito-frontalis, which communicates with the small occipital nerve. The nerve is connected with the great auricular nerve of the cervical plexus, and with the auricular branch of the pneumogastric nerve.

Ascending Pharyngeal Artery. This long and straight branch arises about half an inch above the division of the common carotid (Fig. 43, p. 114). It ascends between the internal carotid and the side of the pharynx to the base of the skull, lying upon the rectus capitis anticus major. It gives off numerous branches; among them are—

1. *Small external branches* which pass outwards to supply the anterior recti muscles, the superior cervical ganglion, the pneumogastric and hypoglossal nerves, and the prevertebral lymphatic glands. They anastomose with the ascending cervical artery.

2. *Pharyngeal branches*, some of which pass to the two lower pharyngeal constrictors and the stylo-pharyngeus; one, the largest of all, enters the pharynx above the superior constrictor, and terminates in the soft palate, the Eustachian tube, and the tonsils.

3. *Meningeal branches*; one passes through the foramen lacerum posticum, with the internal jugular vein, and is distributed to the dura mater of the occipital fossa; another through the foramen lacerum medium, and one through the anterior condylar foramen.

The *pharyngeal vein* receives some meningeal branches, also small veins from the soft palate, Eustachian tube, and, uniting, form the pharyngeal plexus which opens into the internal jugular or common facial vein.

The examination of the two remaining branches of the external carotid, the internal maxillary and temporal, must for the present be postponed. Meanwhile the student should make out the deep cervical plexus and its branches.

Cervical Plexus of Nerves.

This plexus is formed by the anterior branches of the four upper cervical nerves. It consists of a series of loop-like communications, between these nerves, close to the transverse processes of the four upper cervical vertebræ; each nerve dividing into an ascending and a descending branch, with the exception of the first. The plexus rests on the levator anguli scapulæ and scalenus medius, and is situated behind the sterno-mastoid m. and the internal jugular vein.

The plexus gives off *superficial* and *deep* branches, the superficial coming from the second, third, and fourth nerves, the deep from the third and fourth n. The superficial branches have been already described (p. 84).

The deep branches may be divided into an *internal* and an *external* series.

INTERNAL SERIES.—1. The *phrenic* arises from the third, fourth, and fifth cervical nerves, descends obliquely inwards over the scalenus anticus, and then crosses over the first part of the subclavian artery. Near the thorax it is joined by the sympathetic, and frequently by a looped branch from the nerve to the subclavius muscle. Its course through the thorax to its destination in the diaphragm will be described p. 127.

2. The *communicantes noni* come from the second and third cervical nerves, wind round the internal jugular vein, and join the descendens noni in front of the carotid sheath, forming the "ansa hypoglossi." They supply the depressor muscles of the os hyoides and larynx.

3. *Muscular* branches which proceed from the first cervical and the loop between it and the second cervical, to the recti antici, the rectus lateralis, and longus colli muscles.

4. *Branches* which communicate with the pneumogastric, hypoglossal, and sympathetic nerves, and one to join the fifth cervical.

EXTERNAL SERIES.—1. One or more *communicating branches* to the nervus accessorius: firstly in the sterno-mastoid, then in the occipital triangle, and lastly beneath the trapezius.

2. *Muscular branches* to supply the trapezius, levator anguli scapulæ, scalenus medius, and sterno-mastoid. The branches to the trapezius, levator anguli scapulæ, and scalenus medius, come from the third and fourth; the branch to the sterno-mastoid from the second cervical nerve.

Dissection.

The clavicle should now be sawn through the middle, and the sternal half raised with the sterno-mastoid attached, so that the bone can be replaced, to study its relation to the subjacent parts. The scalene muscles and the subclavian artery throughout its whole course must next be care-

fully dissected. While this is being done, the student must be careful not to injure the branches of the subclavian artery, the lymphatic duct on the right, and the thoracic duct on the left side, the nerve to the subclavius m., the phrenic nerve, the cervical and the brachial plexuses of nerves, and their small branches.

Scalene Muscles. The scalene muscles, so called from their resemblance to a scalene triangle, extend from the transverse processes of the cervical vertebræ to the first and second ribs. They may be considered as intercostal muscles, since the transverse processes of the cervical vertebræ are but rudimentary ribs. Anatomists describe them as three separate muscles—an anterior, a middle, and a posterior; the anterior and middle are attached to the first rib, the posterior to the second. In plan and purpose these three muscles are one.

Scalenus Anticus. The scalenus anticus is attached above to the anterior tubercles of the transverse processes of the third, fourth, fifth, and sixth cervical vertebræ, and below by a flat tendon to the tubercle on the *inner* border and upper surface of the first rib in the front of the groove for the subclavian artery.

Scalenus Medius. The scalenus medius is attached above to the posterior tubercles of the transverse processes of all the cervical vertebræ except the first, and below to the first rib behind the scalenus anticus, extending, from the tubercle, forwards for an inch and a half.

Scalenus Posticus. The scalenus posticus is attached above to the posterior tubercles of the transverse processes of the two or three lowest cervical vertebræ, and below to the second rib between its tubercle and angle, anterior to the levator costæ, and behind the serratus magnus.

The scaleni are supplied by branches derived from the lower cervical nerves.

The scalene muscles are important agents in raising the thorax, in a deep inspiration. Take a deep breath, and you can easily feel them contracting. They can bend the cervical portion of the spine, if their lower attachment be the fixed point, as in rising from the recumbent position.

The scalenus anticus is one of those muscles about which we ought to know well all that lies in front of it, and all that lies behind it. In the front of it are: the clavicle, the subclavius, the clavicular origin of the sterno-mastoid, the omo-hyoid, the phrenic nerve, the subclavian vein, the supra-scapular, the posterior scapular, and the ascending cervical arteries. Behind it are the subclavian artery, the five nerves which form the brachial plexus, and the pleura; to its inner side is the internal jugular vein, and the vertebral artery separates it from the longus colli.

Make your finger familiar with the feel of the tubercle on the first rib, to which the scalenus anticus is attached. This tubercle is the guide to the subclavian artery, for it enables you to find the *outer edge* of the scalenus anticus, where you must look for the vessel. Is the scalenus anticus entirely concealed from view by the sterno-mastoid, or not? This will depend upon the breadth of the clavicular attachment of the sterno-mastoid. As a general rule, it may be said that the scalene muscle *is* concealed by the sterno-

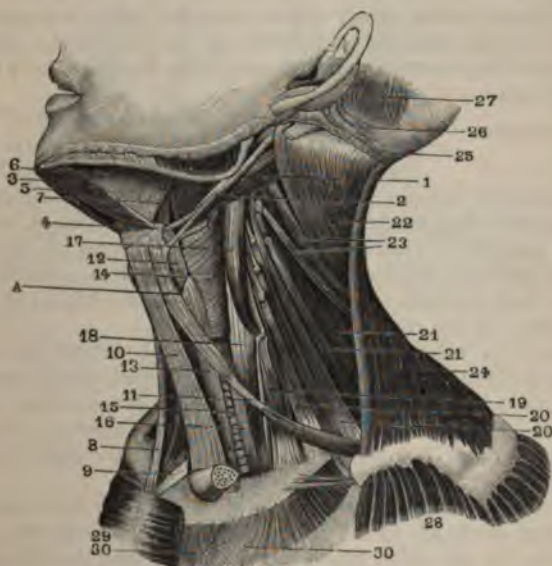


FIG. 46.—SCALENE MUSCLES.

19. Scalenus anticus muscle. 20, 20. Scalenii medius and posticus. 21, 21. Fasciculi of the levator anguli scapulae muscle. 22. Splenius capitis muscle. 23. Splenius colli muscle.

mastoid, and that consequently, in tying the subclavian artery, it may be necessary to divide partially the clavicular origin of the muscle.

Phrenic Nerve.

The phrenic nerve runs down in front of the scalenus anticus, from the outer to the inner border. It arises from the third, fourth, and fifth cervical nerves, but chiefly from the fourth. It enters the chest between the subclavian artery and vein, crosses in front of the internal mammary

artery, and continues its course between the pericardium and pleura, in front of the root of the lung, to the diaphragm, which it supplies.

When the spinal cord is injured above the fourth cervical vertebra, the origin of the phrenic is implicated; therefore, the diaphragm, as well as the other muscles of inspiration, are paralyzed. Death is the immediate result.*

COURSE AND RELATIONS OF THE SUBCLAVIAN ARTERIES.

The left subclavian artery differs from the right, not only in its origin, but in the relations of the first part of its course. The right should, therefore, be examined first, and then the differences between it and the left.

Right Subclavian Artery.

The right subclavian artery is one of the two great branches into which the arteria innominate divides behind the sterno-clavicular joint.

It runs outwards behind the scalenus anticus, then inclines downwards over the first rib, at the outer border of which it takes the name of axillary. The artery describes a curve, of which the greatest convexity is between the scalene muscles. The height to which the arch ascends varies. Generally, it rises higher in women than in men, on the right side than on the left.

To study its relations more precisely, the course of the subclavian is divided into three parts: 1. The part which intervenes between its origin and the inner border of the scalenus anticus. 2. That which lies behind the scalenus. 3. That which intervenes between the outer border of the scalenus and the outer border of the first rib.

The *first* portion of the artery lies deeply in the neck and passes upwards and outwards to the inner border of the scalenus anticus. It is *covered* by the skin, platysma, superficial and deep fasciæ, the sternal end of the clavicle, the sterno-mastoid, sterno-hyoid, and sterno-thyroid muscles, and a layer of deep fascia, continued from the inner border of the scalenus anticus. It is *crossed* by the internal jugular and vertebral veins, by the pneumogastric and

* The phrenic nerve is joined by a filament from the sympathetic, and frequently by a filament from that branch of the brachial plexus which supplies the subclavian muscle. This is sometimes a branch of considerable size, and forms the greater portion of the phrenic itself. We have met with many instances in which this accessory branch was larger than the regular trunk; in all of them it crossed over the subclavian artery in the third part of its course, and would probably have been injured in the operation of tying this vessel. That such an accident has actually happened is reported by Bransby Cooper in his surgical lectures. He speaks of having injured this accessory branch of the phrenic in tying the subclavian artery. The patient had incessant spasm of the diaphragm till he died.

phrenic nerves, and by some cardiac filaments of the sympathetic. *Inferiorly* it rests upon the pleura. *Behind* the artery are the recurrent branch of the pneumogastric, the sympathetic nerve, the longus colli, the transverse process of the seventh cervical vertebra,

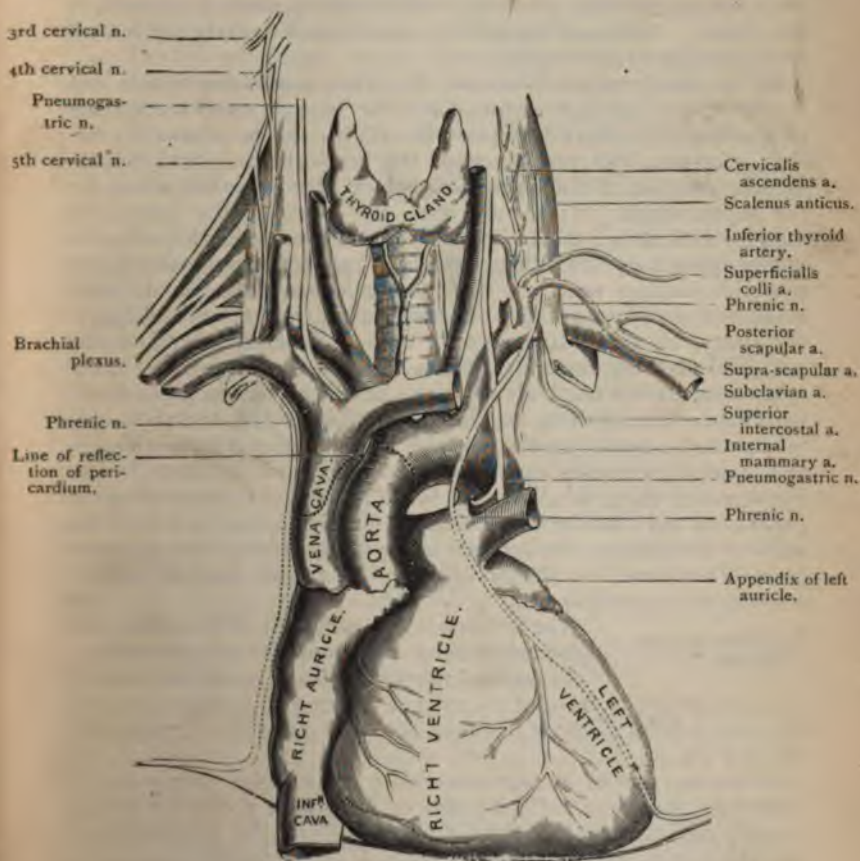


FIG. 47.

and the apex of the lung covered with the pleura. The subclavian vein lies below the artery. Three branches arise from this portion of the subclavian—viz., the vertebral, internal mammary, and thyroid axis.

In the *second* (the highest) part of its course, the artery lies between the scalene muscles. It is *covered* by skin, platysma, and superficial fascia, by the clavicular origin of the sterno-mastoid, the deep cervical fascia, and by the scalenus anticus and phrenic nerve, which separate it from the subclavian vein. *Behind* the artery is the scalenus medius; *above* it, is the brachial plexus; *below* it, is the pleura. Only one branch, the superior intercostal, is given off from this part of the artery.

In the *third* part of its course, the artery passes downwards and outwards, and lies in the supra-clavicular triangle upon the surface of the first rib. Here it is most superficial, and is *covered* by the skin, platysma, the two layers of the cervical fascia, and the clavicular branches of the superficial cervical plexus; subsequently by the suprascapular artery and vein, the clavicle, the subclavius muscle, with its nerve; and, what is of much more consequence, it is here crossed by the external jugular and (often) the supra and posterior scapular veins; so that there is here a confluence of large veins in front of the artery. The subclavian vein is situated below the artery, but on a plane anterior to it. *Below* it, is the first rib, and behind it the scalenus medius. *Above* the artery, and to its outer side, are the trunk nerves of the brachial plexus and the omohyoid m. One of these nerves (the conjoined fifth and sixth cervical) runs so nearly parallel with the artery, and *on a plane anterior* to it, that is quite possible to mistake the nerve for the artery in the operation of tying it. We have heard a hospital surgeon of great experience say that he had seen this mistake committed on three separate occasions. In this part of its course, the artery as a rule gives off no branches; the most frequent exceptions are the posterior scapular and supra-scapular.

**Left Subclavian
Artery.**

The left subclavian is the last of the three great branches which arise from the arch of the aorta. It ascends nearly vertically out of the chest, and then arches in front of the apex of the lung and pleura to reach the inner border of the scalenus anticus, behind which it runs over the first rib.

In the first part of its course the left subclavian lies deeply in the chest near the spine. On its *outer* or left side it is covered by the pleura; on its *inner* or right side are at first the trachea, then the œsophagus and thoracic duct; in *front* are the left lung, covered with its pleura, the pneumogastric and phrenic nerves, and the cardiac branches, all of which lie parallel with the artery, the left common carotid, and the left brachio-cephalic vein; at the level of the upper part of the chest it has in front the sterno-thyroid, sterno-hyoid, the sterno-mastoid muscles, the left internal jugular and vertebral veins, and the sternal end of the clavicle; *behind* it are

the longus colli, the vertebral column, the inferior cervical ganglion of the sympathetic, the œsophagus, and the thoracic duct.

Behind the scalenus anticus, and on the surface of the first rib, the relations of the left subclavian are similar to those of the right (p. 129).

The left subclavian, then, differs from the right only in the first part of its course. Now, what are these differences?

1. The left subclavian comes direct from the arch of the aorta, and is therefore longer, deeper in the chest, and more vertical than the right, which comes from the arteria innominata.

2. The left subclavian is in close relation with the œsophagus and the thoracic duct: the right is not.

3. The left subclavian is crossed by the left brachio-cephalic vein.

4. The left subclavian has the phrenic, pneumogastric and cardiac nerves nearly parallel with it; on the right side, these nerves cross the artery at a nearly right angle.

5. The left subclavian is not embraced by the recurrent laryngeal nerve, like the right subclavian.

The thoracic duct bears an important relation to the left subclavian. It ascends from the chest to the left of the œsophagus and *behind* the artery; then arching behind the internal jugular vein as high as the seventh cervical vertebra, it curves downwards and forwards in front of the scalenus anticus to terminate in the subclavian vein at its junction with the jugular. The duct is so thin and transparent that it easily escapes observation; it is most readily found by raising the subclavian vein near its junction with the jugular, and searching with the handle of the scalpel on the inner side of the scalenus anticus, in front of the vertebral vein (Fig. 48).

Before tracing the branches of the subclavian artery, consider some points relating to the operation of tying it.

To tie the artery in the first part of its course, namely, on the inner edge of the scalenus anticus, is an operation of great difficulty and danger, even with the parts in a normal position. The great depth at which the artery is placed, the size and close proximity of its numerous branches, the large veins by which it is covered, its connection with the pneumogastric, recurrent laryngeal, phrenic, and sympathetic nerves, and, above all, its close contiguity with the pleura, form a combination of circumstances so formidable that one cannot be surprised the operation has never been performed with a favourable result. On the left side the operation is more difficult to perform than on the right, owing to the difference in the anatomical relation of the two sides.

In the second part of its course, between the scalene muscles, the artery is more accessible, although it is rarely ligatured in this situation. It would be necessary to divide the clavicular origin of the sterno-mastoid, the cervical fascia, and the scalenus anticus to reach the vessel; the phrenic nerve and the subclavian vein would be the chief objects exposed to injury. This operation was performed first

In the *second* (the highest) part of its course, the artery lies between the scalene muscles. It is *covered* by skin, platysma, and superficial fascia, by the clavicular origin of the sterno-mastoid, the deep cervical fascia, and by the scalenus anticus and phrenic nerve, which separate it from the subclavian vein. *Behind* the artery is the scalenus medius; *above* it, is the brachial plexus; *below* it, is the pleura. Only one branch, the superior intercostal, is given off from this part of the artery.

In the *third* part of its course, the artery passes downwards and outwards, and lies in the supra-clavicular triangle upon the surface of the first rib. Here it is most superficial, and is *covered* by the skin, platysma, the two layers of the cervical fascia, and the clavicular branches of the superficial cervical plexus; subsequently by the suprascapular artery and vein, the clavicle, the subclavius muscle, with its nerve; and, what is of much more consequence, it is here crossed by the external jugular and (often) the supra and posterior scapular veins; so that there is here a confluence of large veins in front of the artery. The subclavian vein is situated below the artery, but on a plane anterior to it. *Below* it, is the first rib, and behind it the scalenus medius. *Above* the artery, and to its outer side, are the trunk nerves of the brachial plexus and the omohyoid m. One of these nerves (the conjoined fifth and sixth cervical) runs so nearly parallel with the artery, and *on a plane anterior* to it, that is quite possible to mistake the nerve for the artery in the operation of tying it. We have heard a hospital surgeon of great experience say that he had seen this mistake committed on three separate occasions. In this part of its course, the artery as a rule gives off no branches; the most frequent exceptions are the posterior scapular and supra-scapular.

Left Subclavian Artery.

The left subclavian is the last of the three great branches which arise from the arch of the aorta. It ascends nearly vertically out of the chest, and then arches in front of the apex of the lung and pleura to reach the inner border of the scalenus anticus, behind which it runs over the first rib.

In the first part of its course the left subclavian lies deeply in the chest near the spine. On its *outer* or left side it is covered by the pleura; on its *inner* or right side are at first the trachea, then the œsophagus and thoracic duct; in *front* are the left lung, covered with its pleura, the pneumogastric and phrenic nerves, and cardiac branches, all of which lie parallel with it. Behind the common carotid, and the left brachial plexus, it enters the upper part of the chest it is covered by the sterno-mastoid, the hyoid, the sterno-mastoid, the supra-clavicular vessels, and the vertebral veins, and

and with success by Dupuytren in the year 1819. More recently it has been performed by Dr. Warren, of Boston. The patient recovered, though the pleura was wounded.*

But in the last part of its course, that is, on the outer side of

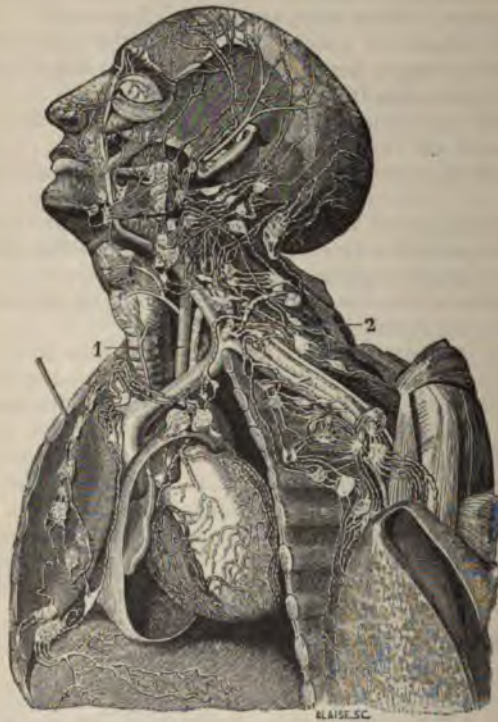


FIG. 48.—LYMPHATIC VESSELS COMING FROM THE GLANDS OF THE NECK AND AXILLA.

1. Superior extremity of the thoracic duct passing behind the internal jugular vein, in an arch.
2. Terminal portion of this arch, which enters in the angle made by the union of the internal jugular and the subclavian veins on the left side.

the scalenus, the artery may be tied with comparative facility. The incision should be made from three to four inches (7.5 to 10 c.m.) in length, parallel with the upper border of the clavicle. We divide the platysma, some of the supra-clavicular nerves, and the

* "Med. Chirurg. Trans.," vol. xxix, p. 25.

cervical fascia. The external jugular vein and its tributaries must be drawn to the outer side, or divided and tied at both ends.

The connective tissue should now be carefully cut through, and the posterior belly of the omo-hyoid sought for, as it runs just above the clavicle. After clearing away some fat and cellular tissue, the outer border of the scalenus anticus must be felt for, behind which the artery will be found lying upon the first rib. The operator now passes his finger downwards along the outer border of this muscle, as far as its insertion into the tubercle of the first rib, which can always be distinctly felt. The artery having been exposed by carefully dividing a layer of fascia immediately covering the vessel, the ligature is to be passed round the artery from above downwards, care being taken not to include in the ligature one of the cords of the brachial plexus.

Mr. Ramsden, of St. Bartholomew's Hospital, was the first who tied the subclavian in the third part of its course, in the year 1809; since that time the operation has been repeatedly performed, with very favorable results.

In the hands of a surgeon possessed of a practical knowledge of anatomy the operation is easy, provided all circumstances be favourable: but circumstances are often very unfavourable. Anatomical deviations are by no means rare, and it often happens that the aneurismal or other tumour, on account of which the operation is performed, raises the clavicle beyond its natural level, and so disturbs the parts, that to expose the artery and place a ligature around it becomes exceedingly difficult. Under such circumstances one cannot be surprised that even distinguished anatomists have committed mistakes. Sir Astley Cooper* failed in one instance. Dupuytren perforated the artery with the point of the needle, and included one of the nerves in the ligature: fatal hæmorrhage was the result.† We were present at an operation in which the large nerve (a branch of the brachial plexus) which runs parallel with and on a plane anterior to the artery was mistaken for it and tied, the surgeon being deceived by the pulsation communicated to the nerve.

The description of the means whereby the collateral circulation is maintained is deferred until the branches of the subclavian have been made out and described.

The branches of the subclavian extend so widely, that in the present dissection we can trace them only for a short distance. They are four in number:—

1. The vertebral.
2. The thyroid axis, a short, thick trunk which gives off the inferior thyroid, supra-scapular, and posterior scapular.
3. The internal mammary.

* *London Medical Review*, vol. ii, p. 300.

† *Edinburgh Med. and Surg. Journal*, vol. xvi, 1820.

4. The superior intercostal, which gives off the deep cervical.

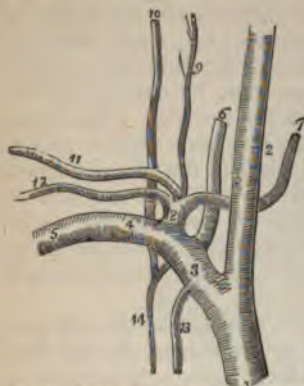


FIG. 49.—BRANCHES OF THE SUBCLAVIAN ARTERY.

1. Innominate artery. 2. Common carotid artery. 3. Subclavian artery. 4. Second and third portions of subclavian artery and commencement of axillary artery. 6. Vertebral artery. 7. Inferior thyroid artery. 8. Thyroid axis. 9. Ascending cervical artery. 10. Profunda cervicis artery. 11. Transversalis colli artery. 12. Suprascapular artery. 13. Internal mammary artery. 14. Superior intercostal artery.

As a rule, the vertebral, the thyroid axis, and the internal mammary are given off from the subclavian in the first part of its course, and the superior intercostal in the second part. The most frequent deviation is, that the posterior scapular (*transversalis colli*) arises from the subclavian in the third part of its course. On the left side, the superior intercostal is frequently given off in the first part of the course of the subclavian.

Vertebral Artery. This, the first and largest branch, arises from the upper and back part of the subclavian. It ascends in the neck, and for a short distance lies in the interval between the *scalenus anticus* and the *longus colli*. Here it enters the foramen in the transverse process of the six cervical vertebræ, and ascends through the foramina in the transverse processes of the succeeding vertebræ. In the interval between the axis and the

atlas, the artery makes a sigmoid curve, that it may not be stretched in the rotation of the head. Having traversed the foramen of the atlas, the artery curves backwards along the groove in its arch, perforates the posterior occipito-atlantal ligament and the dura mater, then enters the skull through the foramen magnum, and unites with its fellow near the lower border of the pons Varolii to form the basilar artery.

Directly after the artery is given off from the subclavian, it lies behind the internal jugular vein, the inferior thyroid artery, and the vertebral vein, and, on the left side, behind the thoracic duct. As it lies upon the groove on the neural arch of the atlas, it is separated from it by the suboccipital nerve, and is situated within the suboccipital triangle. After it has passed through the foramen magnum, the artery turns round the medulla oblongata, and is placed between the hypoglossal nerve and the anterior root of the suboccipital nerve.

The vertebral artery is accompanied by slender nerves from the inferior cervical ganglion of the sympathetic. These nerves communicate with the spinal nerves forming the brachial plexus.

Destined for the brain, the vertebral gives off no branches in the neck, except a few small muscular ones to the deeply-seated muscles, and which anastomose with the deep cervical, ascending cervical, and occipital arteries; it furnishes, however, *lateral spinal* branches to the spinal cord and its membranes which pass through the intervertebral foramina.

Each spinal branch divides into two branches; one, passing along the root of the spinal nerve, is distributed to the spinal cord and its membranes; the other ramifies over the posterior surface of the body of the vertebra.

The cranial branches of the vertebral artery are mentioned at length in the description of the arteries of the brain.

The *vertebral vein* is formed by small branches from the muscles near the foramen magnum. It descends in front of the artery through the foramina in the transverse processes, and, emerging through the transverse process of the sixth, crosses the subclavian artery and joins the brachio-cephalic vein, its orifice being guarded by a single or a double valve. It receives the veins from the neighbouring muscles—the dorsi-spinal veins, veins from the spinal canal, the deep and ascending cervical, and the first intercostal veins. In some subjects it communicates with the lateral sinus by a branch through the posterior condylar foramen.

The cervical nerves pass through the intervertebral foramina behind the vertebral artery, so that the artery runs *behind* its vein and in *front* of the nerves.

Thyroid Axis.

The *thyroid axis* arises from the subclavian near the inner edge of the scalenus anticus, and after a course of a quarter of an inch (6.2 mm.) divides into three branches, which take different directions—namely, the inferior thyroid, the supra-scapular, and the posterior scapular.

1. The *inferior thyroid* artery ascends tortuously behind the sheath of the common carotid and the sympathetic nerve, to the deep surface of the thyroid body, in which it communicates freely with the superior thyroid and with its fellow. Besides small branches to the trachea, the œsophagus, and the larynx, it gives off—

The *ascending cervical* artery, which runs up close to the spine, between the scalenus anticus and the rectus capitis anticus major, and terminates in small branches, some of which supply these muscles; others enter the intervertebral foramina, and supply the spinal cord, and its membranes. It anastomoses with the vertebral and ascending pharyngeal arteries.

2. The *supra-scapular* artery (*transversalis humeri*) runs outwards over the scalenus anticus, covered by the sterno-mastoid m., then directly *beneath* and parallel with the clavicle: crossing over the third part of the subclavian artery, it passes beneath the posterior belly of the omo-hyoid to the superior border of the scapula. Here it is covered by the trapezius, passes *above* the transverse ligament which bridges over the notch; it gives off some branches which ramify in the supra-spinous fossa, and a large communicating branch which passes behind the

neck of the scapula to reach the infra-spinous fossa, and inosculates freely in the infra-spinous fossa with the dorsalis scapulae, a branch of the sub-scapular, and with the posterior scapular artery. Near the notch it is joined by the supra-scapular nerve, which runs *through* it. The branches of this artery are numerous but small, and are as follow: the *inferior sterno-mastoid* (p. 90); the *supra-acromial*, which anastomoses with the acromio-thoracic artery; *articular* branches to the shoulder-joint; the *infra-spinous*, which ramifies in the infra-spinous fossa; and the *sub-scapular*, which ramifies in the substance of the subscapularis muscle.

3. The *transversalis colli* artery, of which the normal origin is said to be from the thyroid axis, very frequently arises from the subclavian in the last part of its course. It is larger than the preceding artery, and runs tortuously across the side of the neck (higher than the supra-scapular), over the scalene muscles and the great nerves of the brachial plexus (sometimes between them), and divides into two branches, the superficial cervical and the posterior scapular. The *posterior scapular* disappears beneath the trapezius and the levator anguli scapulae to reach the superior angle of the scapula. It then runs beneath the rhomboid muscles, which it supplies, down to the inferior angle of the scapula, anastomosing freely with the terminations of the supra- and sub scapular arteries, and with the posterior branches of some of the intercostal arteries. The *superficial cervical* is given off in the space between the sterno-mastoid and trapezius. This vessel proceeds tortuously across the posterior triangle of the neck to the under surface of the trapezius, to which, with the levator anguli scapulae, it is principally distributed.

The *superficialis colli* often comes *direct* from the thyroid axis.

The *veins* corresponding to the supra-scapular and posterior scapular arteries terminate in the external jugular, sometimes in the subclavian. The middle thyroid vein crosses in front of the common carotid artery, and joins the internal jugular.

Internal Mammary. This artery arises from the subclavian opposite to the thyroid axis. It descends slightly inwards behind the clavicle and the subclavian vein, and enters the chest between the cartilage of the first rib and the pleura. It then passes behind the costal cartilages about half an inch (12.5 mm.) from the border of the sternum. Its further course will be examined in the dissection of the chest. The corresponding vein, which results from the union of the two venae comites, most frequently terminates in the brachio-cephalic vein.

Superior Intercostal. This artery is given off by the subclavian behind the scalenus anticus on the right side, and to its inner side on the left, so that you must divide the muscle to see it. It enters the chest behind the pleura, to the outer side of the first dorsal ganglion of the sympathetic. It runs over the necks of the first and second ribs, and furnishes the arteries of the two upper intercostal spaces, and a posterior branch which is distributed to the muscles of the back and the spinal cord. It usually inosculates with the first intercostal branch of the aorta. The corresponding *vein* terminates on the right side in the vena azygos major; on the left in the brachio-cephalic.

Deep Cervical Artery. This artery arises from the superior intercostal, seldom direct from the subclavian. It goes to the back of the neck between the first rib and the transverse process of the seventh cervical vertebra, and ascends between the complexus and the semi-spinalis colli, both of which it supplies. It sometimes inosculates with the princeps cervicis, a branch of the occipital (p. 123).

To test your knowledge of the branches of the subclavian artery, reflect upon the answer to the following question: "If the artery were tied in the *first* part of its course before it gives off any branches, how would the arm be supplied with blood?" The answer is, by six collateral channels, as follow: 1. By the communications between the superior and inferior thyroid; 2. Between the two vertebral; 3. Between the internal mammary and the intercostals and the epigastric; 4. Between the thoracic branches of the axillary and the intercostal branches of the aorta; 5. Between the superior intercostal and the aortic intercostals; 6. Between the princeps cervicis and the deep cervical. Most of these inosculations are shown in the diagram (Fig. 50).

Again, if the subclavian were tied in the *third* part of its course, the circulation would be carried on by the communications: 1. Between the supra-scapular and the dorsalis scapulæ, a branch of the subscapular; 2. Between the supra-acromial branch of the supra-scapular and the acromio-thoracic; 3. Between the posterior scapular

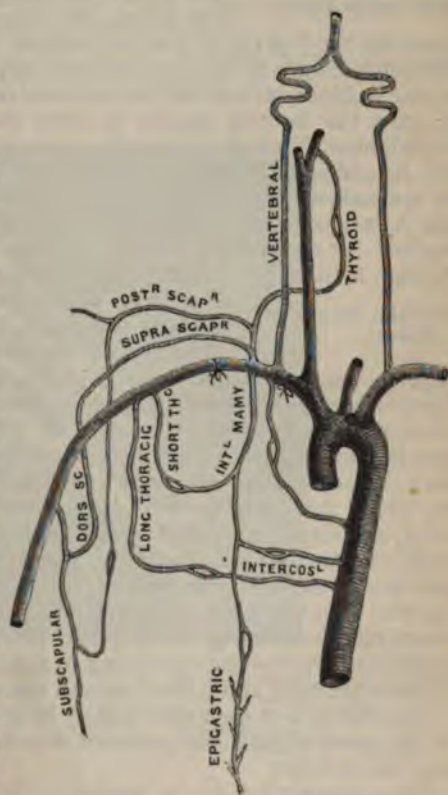


FIG. 50.—DIAGRAM TO SHOW THE INOSCULATIONS OF THE SUBCLAVIAN ARTERY.

and the subscapular and dorsalis scapulæ; 4. Between the internal mammary, the aortic intercostals and superior intercostal, on the one hand, and the long and short thoracic branches of the axillary, on the other.

Subclavian Vein.

The subclavian vein does not form an arch like the artery, but proceeds in a nearly straight line over the first rib to join the internal jugular. It extends from the outer margin of the first rib to midway between the inner border of the scalenus anticus and the sterno-clavicular articulation, where it joins the internal jugular to form the brachio-cephalic vein. Throughout its whole course the vein is situated on a plane anterior to and a little lower than the artery, from which it is separated by the scalenus anticus, the phrenic and pneumogastric nerves. It has a pair of valves just before its junction with the internal jugular. It receives the anterior jugular, the external jugular, and through it the supra-scapular and posterior scapular veins.

Brachial Plexus of Nerves.

The large nerves forming the plexus which supplies the upper extremity are the anterior divisions of the four lower cervical and the larger portion of the first dorsal, with a small fasciculus derived from the fourth cervical nerve. Emerging from the intervertebral foramina the nerves appear between the anterior and middle scalene muscles, and pass with the subclavian artery into the axilla. In the neck the nerves have no plexiform arrangement, and it is only in the axilla that they branch and communicate largely with each other, and form the *brachial plexus* of nerves. The nerves in the neck are wide and are situated higher than the subclavian artery, and nearly on the same plane; but as they descend beneath the clavicle, they converge and form large communications with each other, thus constituting the brachial plexus which completely surrounds the artery—one cord lying to the outer side, a second lying to the inner side, and a third behind the vessel.

The plexus is crossed superficially by the omo-hyoid muscle, and by the supra-scapular and posterior scapular arteries, and their corresponding veins.

The arrangement of the nerves in the formation of the plexus is very variable, and often not alike on both sides. The most usual arrangement is that at the outer border of the scalenus anticus the fifth and sixth cervical nerves unite to form an upper trunk; the eighth and the first dorsal n. form a lower trunk; the seventh cervical runs for some distance alone, and forms a middle trunk. Now each of these four upper primary nerves divides into an anterior and a posterior branch: the anterior branches given off from the fifth, sixth, and seventh form the *outer cord* of the plexus; the anterior branches given off from the eighth cervical and first dor-

sal form the *inner cord*; while the posterior branches of all the nerves (namely, the fifth, sixth, seventh, and eighth cervical) unite to form the *posterior cord*.*

The branches arising from the plexus are best arranged into those given off above the clavicle, and those given off below it. The following are those given off *above* the clavicle.

a. The branch forming one of the roots of the phrenic arises from the fifth cervical. (Not in the diagram.)



FIG. 51.—DIAGRAM OF THE FORMATION OF THE BRACHIAL PLEXUS AND ITS BRANCHES. C 4-8. Anterior trunks of the cervical nerves. D 1. Anterior trunk of the first dorsal n. 9. N. to the rhomboid m. 10. Supra-scapular. 11. N. to subclavius m. 12-13. Anterior thoracic. 14, 15, 16. Subscapular n. 17. Lesser int. cutaneous. 18. Musculo-cutaneous. 19. Circumflex. 20. Median. 21. Musculo-spiral. 22. Ulnar. 23. Int. cutaneous. 24. Ext. respiratory of Bell.

b. *Nerve to the subclavius m.*—This proceeds from the fifth and sixth cervical, and crosses the subclavian artery in the third part of its course. It frequently sends a filament, which passes in front of the subclavian vein to join the phrenic nerve.

* Very frequently the posterior branch of the eighth cervical nerve does not, strictly speaking, form part of the posterior cord, but is continued on as a separate fasciculus to form part of the musculospiral nerve. For a description of the arrangement of the nerves constituting the plexus, see a paper, by Lucas, *Guy's Hospital Reports*, 1875; also Turner, in the *Journal of Anatomy*, 1872.

c. Nerves to the *scaleni* and the *longus colli* muscles are given off from the lower cervical nerves as they leave the intervertebral foramina.

d. Nerve to the *rhomboid muscles*.—This arises from the fifth cervical nerve, passes through the *scalenus medius*, and accompanies the posterior scapular artery, beneath the *levator anguli scapulæ*, which, as well as the *rhomboid muscles*, it supplies.

e. The *supra-scapular* nerve arises from the cord formed by the fifth and sixth cervical n., runs to the upper border of the scapula, where it meets with the corresponding artery, and then passes through the notch in the scapula. In the supra-spinous fossa it gives off two branches to the supra-spinatus m. and an upper articular branch to the shoulder; it then descends behind the acromion process to the infra-spinous fossa, distributing a branch to the infra-spinatus muscle, and a lower articular filament to the shoulder joint.

f. The *posterior thoracic nerve* (called *external respiratory* by Sir C. Bell) to the *serratus magnus* arises from the fifth and sixth cervical (sometimes also from the seventh) in the substance of the *scalenus medius*. It passes through this muscle and subsequently emerges below the *rhomboid* nerve; it then descends behind the brachial plexus and the subclavian vessels to the outer surface of the *serratus magnus*, to the several digitations of which it is exclusively distributed.

g. An *articular branch* is distributed to the shoulder joint, besides some filaments to the constituent bones.

It only remains to be observed that the upper cord of the brachial plexus receives a branch from the lower cord of the cervical, and that each of its component nerves communicates by slender filaments with the sympathetic.

Below the clavicle the plexus gives off branches for the supply of the arm; namely, from the outer cord, the external anterior thoracic (to the *pectoralis major*), the musculo-cutaneous, and the outer head of the median; from the inner cord, the internal anterior thoracic n. (to the *pectoralis minor*), the inner head of the median, the ulnar, the internal cutaneous, and the lesser internal cutaneous (nerve of Wrisberg) nerves; from the posterior cord, the three subscapular (to the *subscapularis*, the *latissimus dorsi*, and *teres major*), the circumflex (to the *deltoid* and *teres minor*) and the musculo-spiral nerves: all of which will be described more fully in the dissection of the upper extremity.

TEMPORAL AND PTERYGO-MAXILLARY REGIONS.

In this dissection the parts should be examined in the following order:—

- | | |
|---|--|
| 1. Superficial and deep fasciæ. | 6. Pterygoid muscles. |
| 2. Superficial arteries and nerves of the temple. | 7. Internal maxillary artery and branches. |
| 3. Masseter muscle. | 8. Inferior maxillary nerves and branches. |
| 4. Temporal aponeurosis. | |
| 5. Temporal muscle. | |

To expose the temporal region, the skin of the temple should be reflected from below upwards. Beneath the skin you come upon a layer of tough connective tissue, continuous, above, with the aponeurosis of the scalp; below, with the fascia covering the masseter and the parotid gland. In this tissue are contained the superficial temporal vessels and nerves.

Temporal Artery. This is the smaller of the two terminal branches of the external carotid. Arising in the substance of the parotid gland near the neck of the jaw, it passes *over* the root of the zygoma, close to the meatus auditorius externus, ascends for about $1\frac{1}{2}$ inches (*3.8 cm.*) on the temporal fascia, and there divides into an anterior and a posterior branch. Above the zygoma it is superficial, being covered only by the *atrahens aurem* and a strong layer of fascia; here it is accompanied by branches of the facial nerve, and by the auriculo-temporal branch of the inferior division of the fifth nerve. It gives off the following branches:—

a. Several small branches to the parotid gland, the temporo-maxillary articulation, and the masseter.

b. The *transversalis faciei* (p. 61).

c. The *anterior auricular* branches, two in number, *superior* and *inferior*, ramify on the front of the pinna of the ear, inosculating with branches of the posterior auricular.

d. The *middle temporal*, a small vessel given off while the artery is still in the parotid gland, pierces the temporal fascia above the zygoma, and running in the substance of the temporal muscle anastomoses with the temporal branches of the internal maxillary.

Of the two branches into which the temporal divides, the *anterior* runs tortuously towards the external angle of the frontal bone, distant from it about an inch. Its ramifications extend over the forehead, supplying the orbicularis and occipitofrontalis *m.*, and inosculate with the supra-orbital and frontal arteries. The *posterior* runs towards the back of the head, and inosculates freely with the occipital and posterior auricular. The anterior branch, although the smaller, is usually selected for arteriotomy, the posterior being covered by a strong and unyielding fascia.

The *temporal vein* is formed by the junction of the veins accompanying the terminal branches of the temporal artery, which are

situated superficial to the arteries; just above the zygoma it is joined by the middle temporal vein which takes its origin from a plexus in the temporal fossa. The common temporal vein, formed by the union of these three veins, passes over the zygoma, enters the parotid gland, and joins the internal maxillary vein to form the temporo-maxillary vein.

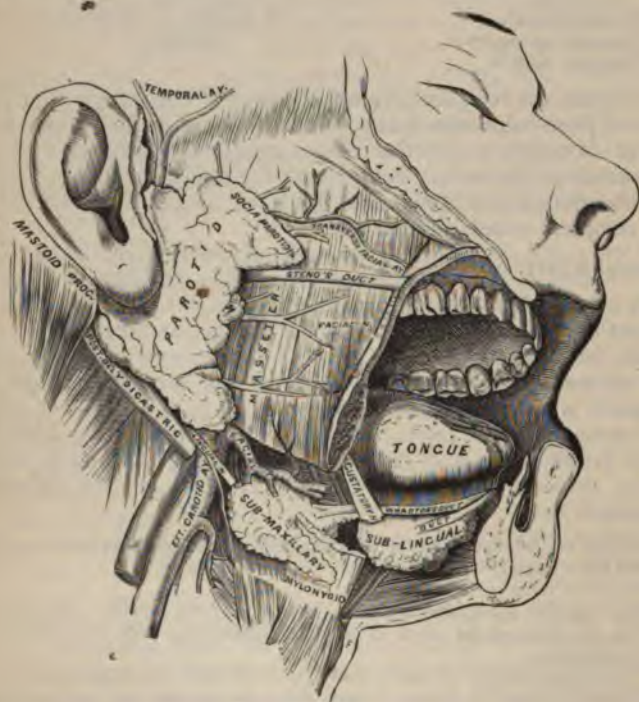


FIG. 52.

Auriculo-temporal Nerve.

This nerve supplies the temple and side of the head with common sensation. It arises, close to the foramen ovale, from the third division of the fifth pair by two roots (between which the middle meningeal artery runs). From its origin it proceeds outwards beneath the external pterygoid, between the neck of the jaw and the internal lateral ligament. It then ascends beneath the parotid, over the root of the zygoma, where it accompanies the temporal artery, and

divides, like it, into an *anterior* and a *posterior* branch (Fig. 33, p. 85).

The posterior branch is the smaller of the two; the anterior forms communications with the temporal branches of the facial, and the orbital branch of the superior maxillary. The ramifications of the nerve correspond with those of the artery.

Near their origin the roots of the nerve are connected by fine filaments with the otic ganglion, and close to the condyle of the jaw the nerve sends round the external carotid artery *two communicating branches* to the temporo-facial branch of the facial nerve. It here distributes *parotid branches* to the gland; *articular branches* to the temporo-maxillary articulation, to the meatus auditorius and the membrana tympani. Above the zygoma it gives off *two auricular filaments*; the *upper* ramifies in the skin of the outer aspect of the ear, mainly on the tragus and upper half of the auricle; the *lower* supplies the lobule and lower part of the pinna.

Lastly, in the subcutaneous tissue of the temple, we find the temporal branches of the facial nerve, which supply the frontalis, the attrahens aurem, the orbicularis palpebrarum, tensor tarsi, and corrugator supercili.

Masseter Muscle. This muscle *arises* from the lower edge of the zygoma, and is *inserted* into the outer side of the ramus and coronoid process of the jaw. The masseter is composed of superficial and deep fibres which cross like the letter X. The *superficial* fibres, constituting the principal part of the muscle, arise from the anterior two-thirds of the zygoma and the malar process of the superior maxilla, by tendinous fibres which occupy the front border of the muscle, and send aponeurotic partitions into its substance. These fibres pass downwards and backwards, this direction giving them greater advantage, and are inserted into the angle and part of the ramus of the jaw. The *deep* fibres, mainly muscular (which are concealed by the parotid gland), arise from the posterior third of the zygoma, incline forwards, and are inserted into the upper half of the ramus and the coronoid process. Besides these, a few fibres, arising from the inner surface of the zygoma, are inserted into the coronoid process and the tendon of the temporal muscle. Its *action* is to raise the jaw and help to masticate the food. Its nerve comes from the inferior maxillary.

The following objects lie superficial to the masseter: 1. Zygomatici major and minor; 2. Orbicularis palpebrarum; 3. Glandula socia parotidis and parotid duct; 4. Transversalis faciei artery; 5. Facial artery and vein; 6. Branches of the facial nerve.

Temporal Fascia. This strong, shining aponeurotic membrane covers the temporal muscle, its chief use being to give additional origin to its fibres. It is attached above to

situated superficial to the arteries; just above the zygoma it is joined by the middle temporal vein which takes its origin from a plexus in the temporal fossa. The common temporal vein, formed by the union of these three veins, passes over the zygoma, enters the parotid gland, and joins the internal maxillary vein to form the temporo-maxillary vein.

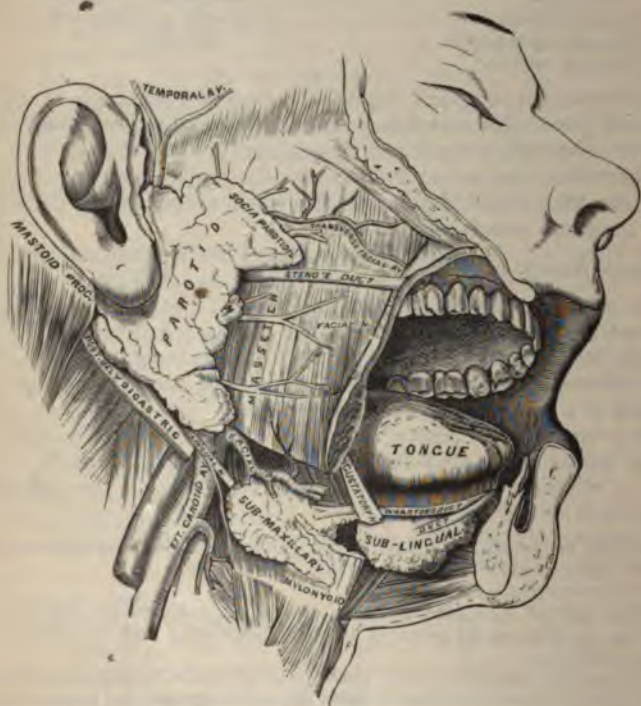


FIG. 52.

Auriculo-temporal Nerve.

This nerve supplies the temple and side of the head with common sensation. It arises, close to the foramen ovale, from the third division of the fifth pair by two roots (between which the middle meningeal artery runs). From its origin it proceeds outwards beneath the external pterygoid, between the neck of the jaw and the internal lateral ligament. It then ascends beneath the parotid, over the root of the zygoma, where it accompanies the temporal artery, and

divides, like it, into an *anterior* and a *posterior* branch (Fig. 33, p. 85).

The posterior branch is the smaller of the two; the anterior forms communications with the temporal branches of the facial, and the orbital branch of the superior maxillary. The ramifications of the nerve correspond with those of the artery.

Near their origin the roots of the nerve are connected by fine filaments with the otic ganglion, and close to the condyle of the jaw the nerve sends round the external carotid artery *two communicating branches* to the temporo-facial branch of the facial nerve. It here distributes *parotid branches* to the gland; *articular branches* to the temporo-maxillary articulation, to the meatus auditorius and the membrana tympani. Above the zygoma it gives off *two auricular filaments*; the *upper* ramifies in the skin of the outer aspect of the ear, mainly on the tragus and upper half of the auricle; the *lower* supplies the lobule and lower part of the pinna.

Lastly, in the subcutaneous tissue of the temple, we find the temporal branches of the facial nerve, which supply the frontalis, the *attrahens aurem*, the *orbicularis palpebrarum*, *tensor tarsi*, and *corrugator supercillii*.

Masseter Muscle. This muscle *arises* from the lower edge of the zygoma, and is *inserted* into the outer side of the ramus and coronoid process of the jaw. The masseter is composed of superficial and deep fibres which cross like the letter X. The *superficial* fibres, constituting the principal part of the muscle, arise from the anterior two-thirds of the zygoma and the malar process of the superior maxilla, by tendinous fibres which occupy the front border of the muscle, and send aponeurotic partitions into its substance. These fibres pass downwards and backwards, this direction giving them greater advantage, and are inserted into the angle and part of the ramus of the jaw. The *deep* fibres, mainly muscular (which are concealed by the parotid gland), arise from the posterior third of the zygoma, incline forwards, and are inserted into the upper half of the ramus and the coronoid process. Besides these, a few fibres, arising from the inner surface of the zygoma, are inserted into the coronoid process and the tendon of the temporal muscle. Its *action* is to raise the jaw and help to masticate the food. Its nerve comes from the inferior maxillary.

The following objects lie superficial to the masseter: 1. Zygomatici major and minor; 2. Orbicularis palpebrarum; 3. Glandula sociæ parotidis and parotid duct; 4. Transversalis faciei artery; 5. Facial artery and vein; 6. Branches of the facial nerve.

Temporal Fascia. This strong, shining aponeurotic membrane covers the temporal muscle, its chief use being to give additional origin to its fibres. It is attached above to

the temporal ridge, and, increasing in thickness as it descends, divides near the zygoma into two layers, which are attached to the outer and inner borders of the zygomatic arch. These layers are separated by fat, in which is found a filament from the orbital branch of the superior maxillary nerve, and the orbital branch of the temporal artery. The density of this aponeurosis explains why abscesses in the temporal fossa rarely point outwards; the pus generally makes its way, beneath the zygoma, into the mouth.

Reflect the aponeurosis, and notice that it is separated from the

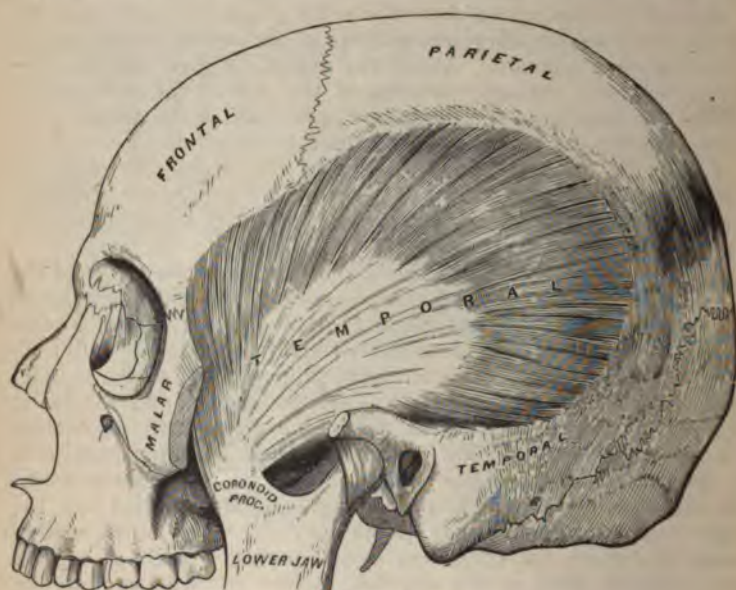


FIG. 53.

temporal muscle, near the zygoma, by fat. The absorption of this fat, and the wasting of the muscle, occasion the sinking of the temple in emaciation and old age.

Dissection.

Divide the zygomatic arch on each side of the masseter, and turn it downwards, taking care of the masseteric nerve and artery which enter its under aspect. Observe the direction of the superficial and deep fibres, and the tendinous partitions which augment the power of the muscle by increasing its extent of origin. The masseteric nerve and artery enter the under surface of the muscle near to its posterior border,

through the sigmoid notch of the jaw; the artery comes from the internal maxillary, the nerve from the motor division of the inferior maxillary.

Temporal Muscle. This broad, fan-shaped muscle *arises* from the whole of the temporal fossa (except the malar surface) and the deep surface of the temporal fascia. Its fibres converge to a strong tendon, which is inserted into the inner surface, the apex, and anterior border of the coronoid process, as far forwards as the last molar tooth.

The fibres of the muscle, converging from their wide origin, pass under the zygomatic arch, and terminate upon their tendon, the outer surface of which is partially concealed by the insertion of those fibres which come from the temporal aponeurosis: remove them, and see how this tendon radiates into the muscle like the ribs of a fan. Its nerves (two deep temporal) are branches of the inferior maxillary (p. 146).

Between the posterior border of this muscle and the neck of the inferior maxilla, the masseteric nerve and artery pass to their destination; in front of the muscle the buccal branch of the inferior maxillary nerve descends to the buccinator with its companion artery.

The temporal muscle is in relation on its deeper surface with the external pterygoid and buccinator muscles, the internal maxillary artery and vein, and the deep temporal arteries and nerves.

Pterygo-maxillary Region. The zygomatic arch having been already divided, the structures should be cleaned so as to expose the coronoid process of the jaw, the insertion of the temporal muscle, and the loose fat which surrounds it. Next, saw through the coronoid process in a direction downwards and forwards, so as to include the insertion of the muscle, and reflect it upwards without injuring the subjacent vessels and nerves.

Dissection. To gain a good view of the muscles, nerves, and vessels of the pterygo-maxillary region, a portion of the ascending ramus of the jaw must be removed with a Hey's saw, as shown in the diagram on the next page.

In this region we have to examine the two pterygoid muscles, the trunk and branches of the internal maxillary artery, the inferior maxillary nerve, and the internal lateral ligament of the lower jaw. All these structures are imbedded in loose soft fat, which must be cautiously removed without injuring them.

External Pterygoid. This muscle *arises* by two heads, one, the upper, from the great wing of the sphenoid and from the ridge below it; the lower, from the outer surface of the external pterygoid plate, a few fibres taking origin from the

outer side of the tuberosities of the palate and superior maxillary bones. The muscle passes horizontally backwards and is *inserted* into the neck of the jaw, and slightly into the border of the inter-articular fibro-cartilage of the temporo-maxillary articulation.

The advantage of the insertion of some of its fibres into the inter-articular cartilage is, that the cartilage follows the condyle in all its movements. When the jaw is dislocated, it is chiefly by the action of this muscle, which draws the condyle forwards into the zygomatic fossa, the inter-articular cartilage being dislocated with the condyle.

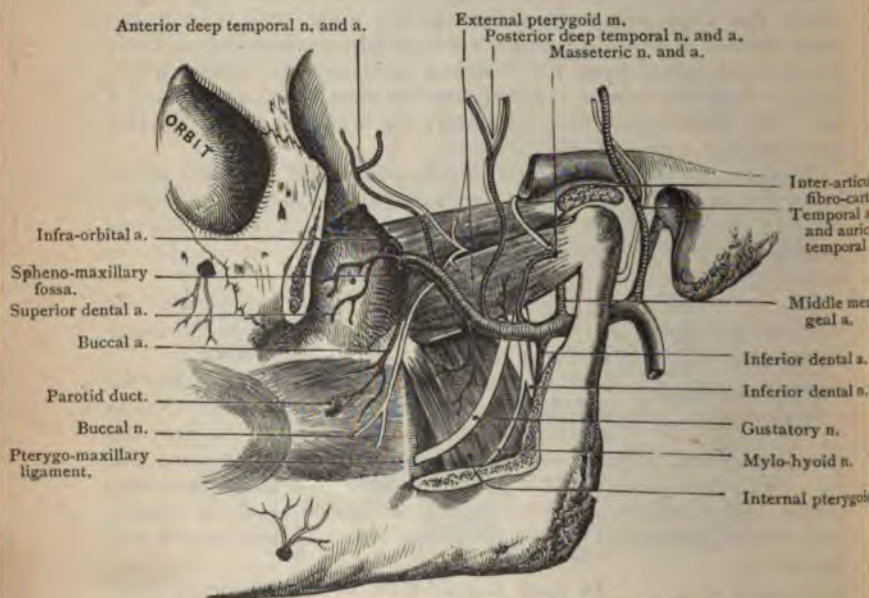


FIG. 54.—PTERYGOID MUSCLES AND INTERNAL MAMMARY ARTERY.

By its deep surface the muscle is in relation with the internal pterygoid m., the internal lateral ligament, the anterior meningeal media, the auriculo-temporal, the gustatory, the inferior dental, and chorda tympani nerves, and occasionally with the internal maxillary artery. Between its two heads of origin the buccal and anterior deep temporal nerves emerge.

Internal Pterygoid. This muscle *arises* by musculo-tendinous fibres from the inner surface of the external pterygoid plate of the sphenoid bone and from that portion of the tuberosity of the palate bone which forms the lower part of the pterygoid

fossa, also by a smaller slip in front of the external pterygoid from the external surface of the tuberosities of the palate and superior maxillary bones. It is *inserted* into the rough surface on the inner side of the angle of the lower jaw, as high as the dental foramen.

The internal pterygoid is in relation superficially with the external pterygoid, the internal lateral ligament, the internal maxillary artery and vein, the inferior dental vessels and nerve, the mylo-hyoid artery and nerve, the chorda tympani, and the buccal nerves; by its deep surface, with the tensor palati and superior constrictor muscles.

Notice particularly the direction of the fibres of the pterygoid muscles. The fibres of the external run horizontally outwards and backwards from their origin; the fibres of the internal run downwards, backwards, and outwards from their origin. The internal pterygoid has tendinous septa like the masseter. Both the pterygoids get their nerves from the motor division of the inferior maxillary nerve.

The internal pterygoid raises the lower jaw, acting in concert with the temporal and masseter muscles; it moreover assists the external pterygoid and anterior part of the masseter to draw the jaw forwards. The external pterygoid draws the jaw forwards and somewhat to the opposite side, and also in conjunction with the internal pterygoid produces the lateral movements of the jaw essential to the mastication of the food. Consequently they are enormously developed in all ruminants and comparatively feebly in carnivorous animals. The antagonistic muscles of the forward action of the two pterygoids are the temporal m. and the deep fibres of the masseter.

Dissection. Saw through the neck of the jaw, disarticulate the condyle with its fibro-cartilage from the glenoid cavity, and turn it forwards with the external pterygoid, so that the condyle can be replaced if desirable. A little dissection will bring into view the internal lateral ligament, the internal maxillary artery and vein, the inferior maxillary nerve and its branches, and the chorda tympani nerve.

Internal Maxillary Artery. This is the larger of the two terminal branches into which the external carotid divides, opposite the neck of the jaw in the parotid gland.

It passes horizontally forwards between the neck of the jaw and the internal lateral ligament, then runs tortuously, in some cases above, in others beneath, the external pterygoid, enters the sphenomaxillary fossa between the two heads of the external pterygoid, where it terminates by dividing into numerous branches.

The course of this artery is divided into three stages. In the first, the artery lies between the neck of the jaw and the internal

lateral ligament; in the second, it lies either over or under the external pterygoid; in the third, it lies in the sphenomaxillary fossa.

BRANCHES OF THE INTERNAL MAXILLARY ARTERY IN THE THREE STAGES OF ITS COURSE.

<i>Branches in the First Stage.</i>	<i>Branches in the Second Stage.</i>	<i>Branches in the Third Stage.</i>
<i>a.</i> Tympanic.	Six to the five muscles of mastication, namely:	<i>i.</i> Superior dental.
<i>b.</i> Meningea media.	<i>e.</i> Masseteric.	<i>j.</i> Infra-orbital.
<i>c.</i> Meningea parva.	<i>f.</i> Anterior and posterior deep temporal.	<i>k.</i> Descending palatine.
<i>d.</i> Inferior dental.	<i>g.</i> External and internal pterygoid.	<i>l.</i> Vidian.
	<i>h.</i> Buccal.	<i>m.</i> Pterygo-palatine.
		<i>n.</i> Nasal or sphenopalatine.

Branches in the First Part.

a. The *tympanic* ascends behind the articulation of the jaw, and passes through the Glaserian fissure to the tympanum. It supplies that cavity and the membrana tympani, and anastomoses with the stylo-mastoid and Vidian arteries. It occasionally gives off a *deep auricular* branch which pierces the anterior wall of the external auditory meatus, supplying the skin of this canal. This artery is not infrequently given off from a branch of the internal maxillary artery.

b. The *middle meningeal* artery ascends between the two roots of the auriculotemporal nerve, behind the external pterygoid, and enters through the foramen spinosum into the cranium, where it ramifies between the dura mater and the bones. In the skull it gives off small branches to the Gasserian ganglion; a *petrosal* branch passing through the hiatus Fallopii; *orbital* branches entering the orbit through the sphenoidal fissure; and *temporal* branches which pierce the great wing of the sphenoid to enter the temporal fossa. Its further course is described at p. 38.

c. The *meningea parva* (not marked in the plan) ascends through the foramen ovale into the skull, and supplies chiefly the ganglion of the fifth cranial nerve. It often comes from the meningea media.

d. The *inferior dental* artery descends behind the neck of the jaw to the dental foramen, which it enters with the dental nerve. It then proceeds through a canal in the diploë to the symphysis, where it minutely inosculates with its fellow. In this canal, which runs beneath the roots of all the teeth, the artery gives branches which ascend through the little foramina in the fangs, and supply the pulp in their interior. Opposite the foramen mentale arises the mental branch already described (p. 68). Before entering the dental foramen the artery furnishes a small branch—*mylo-hyoid*—which accompanies the nerve proceeding to the mylo-hyoid muscle.

Branches in the Second Part.

e. The *masseteric* branch passes through the sigmoid notch of the jaw behind the temporal muscle to the under surface of the masseter, with the masseteric nerve, and inosculates with the facial and transverse facial arteries.

f. The *anterior and posterior deep temporal* arteries ascend to supply the temporal muscle, ramifying between the muscle and the bone, one near the front, the other near the posterior border of the muscle. They communicate with the superficial and middle temporal arteries, with the terminal branches of the lachrymal a., and with the temporal branches of the arteria meningea media.

g. The *pterygoid* branches supply the internal and external pterygoid muscles.
 h. The *buccal* branch runs forward with the buccal nerve to the buccinator, where it anastomoses with the facial artery.
 i. The *superior dental* branch runs along the tuberosity of the superior maxillary bone, and sends small arteries through the foramina in the bone to the pulps of the molar and bicuspid teeth. It also supplies the gums and the mucous membrane of the antrum.

Branches in the Third Part. j. The *infra-orbital* branch ascends through the spheno maxillary fissure, then runs forward along the infra-orbital canal with the superior maxillary nerve, and emerges upon the face at the infra-orbital foramen, beneath the levator labii superioris. In the infra-orbital canal the artery sends branches, *anterior dental*, downwards through little canals in the bone to the incisor and canine teeth, and upwards into the orbit to the lachrymal gland, the inferior oblique, and inferior rectus. After issuing from the foramen it sends upwards branches to the lachrymal sac, and de-

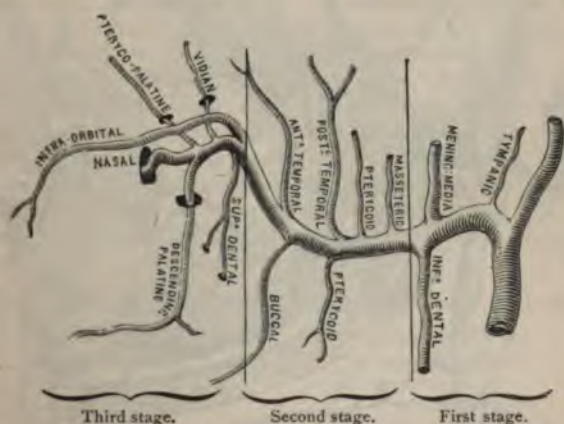


FIG. 55.—PLAN OF INTERNAL CAROTID ARTERY.

scending branches to the upper lip. The former anastomose with the nasal branches of the ophthalmic and facial arteries; the latter with the superior coronary, transverse facial, and buccal arteries.

k. The *descending palatine*, a branch of considerable size, runs down the posterior palatine canal with the palatine nerve (a branch from Meckel's ganglion), and then along the roof of the hard palate, towards the anterior palatine canal, in which, much diminished in size, it inosculates on the septum nasi with a branch of the spheno-palatine artery. It supplies the gums, the glands, and mucous membrane of this part, and furnishes branches to the soft palate.

l. The *Vidian*, an insignificant branch, runs backwards through the Vidian canal with the Vidian nerve, and is distributed to the Eustachian tube, the pharynx, and the tympanum.

m. The *pterygo-palatine* is a small but constant branch which runs backwards through the pterygo-palatine canal with the pharyngeal nerve from Meckel's ganglion, and ramifies upon the upper part of the pharynx and the Eustachian tube.

n. The *nasal* or *spheno-palatine* branch enters the nose through the spheno-palatine foramen in company with the nasal nerve from Meckel's (spheno-palatine) ganglion, and ramifies upon the spongy bones, the ethmoidal cells, and the antrum. One large branch, the *artery of the septum*, runs along the septum nasi towards the anterior palatine canal, where it joins the descending palatine artery.

Observe that all the branches of the internal maxillary artery in the first and third parts of its course traverse bony canals, while the branches in the second part go directly to muscles.

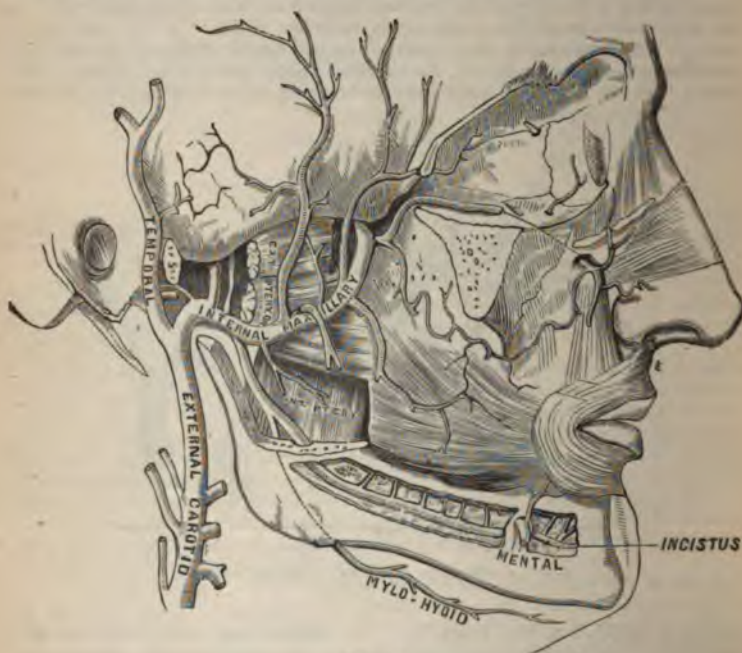


FIG. 56.

Pterygoid Plexus of Veins.

The *internal maxillary vein* is formed by the veins corresponding to the branches of the artery. As the vein lies between the temporal and external pterygoid muscles it forms a plexus—*pterygoid plexus*—which communicates, above, with the cavernous sinus by branches which come through the foramina at the base of the skull; in front it communicates with the facial vein. It joins the temporal in the substance of the parotid gland, and thus communicates with the external jugular vein.

**Inferior Maxillary
Nerve and Branches.**

This great nerve is the largest of the three divisions of the fifth cerebral nerve. It differs from the other two divisions, *i. e.*, the ophthalmic and the superior maxillary, in that it contains motor as well as sensory filaments, the motor being furnished by the small non-ganglionic root of the fifth nerve. It is necessary to remember this point of its physiology in order to understand its extensive distribution; for the sensory portion supplies the parts to which it is distributed with common sensation only, whilst the motor portion supplies all the muscles concerned in mastication.

The nerve, composed of sensory and motor filaments, emerges from the skull through the foramen ovale as a thick trunk, under the name of the inferior maxillary. It lies directly external to the Eustachian tube, and is covered by the external pterygoid muscle, which must be turned on one side to expose it. Immediately after its exit from the skull, the nerve divides into two parts, an anterior, or motor division, and a posterior, or sensory division. From the *anterior* portion (chiefly motor) are derived branches distributed to the muscles of mastication and the buccal nerve. From the *posterior* (mainly sensory) come the following branches: the auriculo-temporal, gustatory, and inferior dental; there are also motor branches to the mylo-hyoid and anterior belly of the digastricus. This apparent anomaly will be presently explained.

- BRANCHES OF THE INFERIOR MAXILLARY NERVE.

Anterior Portion.

Auriculo-temporal.
Inferior dental.
Gustatory or lingual.
Mylo-hyoideus.
Anterior belly of digastricus.

Posterior Portion.

To temporal muscle.
— masseter.
— external pterygoid.
— internal pterygoid.
— buccal.

The *deep temporal branches*, two in number, *anterior* and *posterior*, pass outwards close to the great wing of the sphenoid bone, and ascend with the temporal arteries to the temporal muscle. A *middle temporal* nerve is not infrequently present, and ascends beneath the temporal muscle to enter its deeper aspect. The posterior branch is occasionally joined with the masseteric nerve, the anterior with the buccal nerve.

The branch to the *masseter* runs outwards above the external pterygoid, through the sigmoid notch of the jaw, to the under surface of the muscle.

The branch of the *external pterygoid* comes, apparently, from the buccal nerve in its passage through this muscle.

The branch to the *internal pterygoid* muscle proceeds from the

inner side of the main trunk, close to the otic ganglion, and, descending between the internal pterygoid and the tensor palati, enters the inner and deeper aspect of the muscle.

The *buccal branch*, a sensory nerve, united at its origin with the anterior deep temporal and external pterygoid nerves, passes either above or between the fibres of the external pterygoid to the buc-

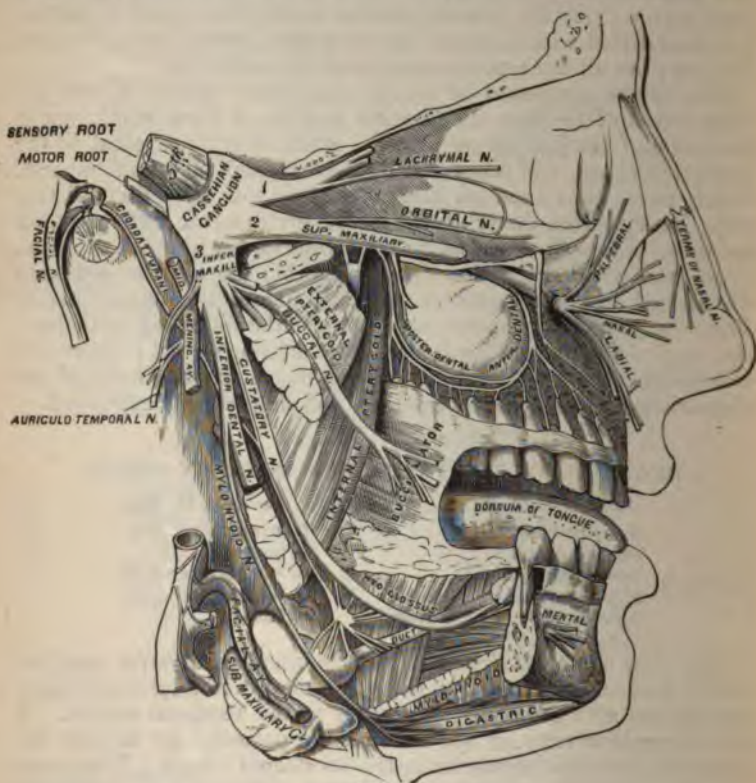


FIG. 57.

cinator, where it spreads out into filaments, which form a plexus with the buccal branches of the facial nerve, and then supply the skin, mucous membrane, and glands of the cheek with common sensation. The motor power of the buccinator, remember, is derived from the facial nerve. That this buccal branch is mainly sensory is proved by the action of the muscle still continuing when

the motor division of the fifth nerve is paralyzed. The evidence is corroborated by a case in which this buccal branch proceeded from the second division of the fifth nerve; no communication being discovered, after very careful dissection, between it and the motor root of the third division.*

The *auriculo-temporal* branch arises by two roots which embrace the middle meningeal artery before it enters the skull. The nerve runs backwards behind the external pterygoid and the neck of the jaw, ascends at first beneath the parotid gland, then over the root of the zygoma with the temporal artery, and divides, like it, into an anterior and a posterior branch. The posterior branch supplies the pinna and surrounding tissues; the anterior is distributed to the skin covering the vertex and temporal region, communicating with the temporal branches of the facial nerve and the orbital branch of the superior maxillary.

The auriculo-temporal communicates at its origin with the otic ganglion, and then ascends behind the jaw with the temporal branches of the facial n.; it also gives off an *articular branch* to the temporo-maxillary joint; *two branches* to the meatus auditorius and the membrana tympani; *parotid branches* to the gland; *auricular branches*, two in number—an *inferior*, which is distributed to the ear below the auditory meatus, and a *superior* to the tragus and auricle. Its branches have been described (p. 30).

The *inferior dental* branch emerges beneath the external pterygoid, and descends between the ramus and the internal lateral ligament of the jaw to the dental foramen, which it enters with the dental artery. It then runs in the canal in the diploë of the jaw and furnishes filaments which ascend through the canals in the fangs of the teeth to the pulp in their interior. Opposite the foramen mentale it divides into two branches, the *mental* and *incisor*. Observe that the same nerve which supplies the teeth supplies the gums; hence the sympathy between them.

a. The *mylo-hyoid* branch, apparently arising from the dental, is derived from the motor root of the fifth, and may, with careful dissection, be traced to it. It leaves the sheath of the inferior dental nerve near the foramen in the jaw, and runs in a groove on the inner side of the ramus to the lower surface of the mylo-hyoid, which muscle it supplies together with the anterior portion of the digastricus.

b. The *dental* branches pass upwards to the fangs of the molar and bicuspid teeth.

c. The *incisor* branch is the continuation of the nerve, and passes to the symphysis, supplying the canine and incisor teeth.

d. The *mental* branch (sometimes called *labial*) emerges through the foramen

* Turner, "On the Variation of the Buccal Nerve." *Journal of Anat. and Phys.*, No. I, 1866.

mentale, and soon divides into numerous branches; some ascend to the lower lip beneath the depressor labii inferioris, and communicate with the facial nerve; others pass inwards to the skin of the chin.

The *gustatory* or *lingual nerve* lies at first behind the external pterygoid m., then ascends obliquely forwards between the ramus of the jaw and the internal pterygoid m., and subsequently for a short distance between the jaw and the superior constrictor of the pharynx. Here it lies close under the mucous membrane of the mouth near the last molar tooth of the lower jaw. Division of it in this situation relieves pain in cancer of the tongue. The gustatory n. then rests upon the stylo-glossus and the hyo-glossus m., and after crossing Wharton's duct passes to the tip of the tongue.

The nerve at first lies in front of the inferior dental nerve (with which it is frequently connected), and beneath the internal maxillary a. Beneath the external pterygoid, the gustatory n. is joined at an acute angle by the *chorda tympani* (a branch of the facial). This branch emerges through a small canal, *canal of Huguier*, by the side of the Glaserian fissure, and passing behind the dental n., meets the gustatory, and runs along the lower border of this nerve to supply the submaxillary gland; part of it joins the submaxillary ganglion, and it is then eventually distributed to the lingualis muscle.

The gustatory nerve in its course gives off—

a. Communicating branches to the hypoglossal n., forming two or more loops at the anterior border of the hyo-glossus muscle.

b. Communicating branches to the submaxillary ganglion.

c. Branches to the mucous membrane of the mouth, gums, and sublingual gland.

d. Lingual branches which pass to the papillæ of the sides and tip of the tongue; here also we find communications between this nerve and the hypoglossal.

The duct of the submaxillary gland (p. 110), *Wharton's duct*, can now be traced to its termination. It passes from its under surface, runs forwards under the mylo-hyoideus and upon the hyo-glossus muscle; it then passes beneath the gustatory nerve, and subsequently runs between the sublingual gland and the genio-hyo-glossus, to open into the floor of the mouth, by the side of the frænum linguæ. Its length is about two inches (5 c. m.); its dimensions are not equal throughout; it is dilated about the middle, and contracted at the orifice. Saliva, collected in the dilated portion, is sometimes spirted to a considerable distance out of the narrow orifice, in consequence of the sudden contraction of the neighbouring muscles.

The gland is supplied with nerves by branches from the submaxillary ganglion, from the sympathetic, and the mylo-hyoid nerves.

In the floor of the mouth there occasionally exists a cystic tumour, called a *ranula*, with semi-transparent walls, perceptible beneath the tongue. By some of the older writers it was looked upon as an abnormal dilatation of the submaxillary duct. There is, however, no reason for believing this swelling (except very rarely) to be connected with the duct. It is rather a cyst formed in the loose areolar tissue under the tongue, or is an enlargement of one of the small bursæ which normally exist in this situation. The character of the saliva presents no agreement with the fluid contained in these cysts, which is thickly glairy, like the white of an egg.

**Internal Lateral
Ligament of the
Lower Jaw.**

This so-called ligament (which is more like a layer of fascia) passes from the spinous process of the sphenoid bone to the inner side of the foramen dentale. Between this ligament and the neck of the jaw we find the internal maxillary artery and vein, the auriculo-temporal nerve, the middle meningeal artery, the inferior dental nerve and artery, and a portion of the parotid gland.

At this stage of the dissection you will be able to trace the course and relations of the internal carotid artery. But before doing this, examine the several objects which intervene between the external and internal carotids. These are—1. The stylo-glossus; 2. The stylo-pharyngeus; 3. The glosso-pharyngeal nerve; 4. The stylo-hyoid ligament.

Stylo-glossus. This *arises* from the front of the styloid process near the apex, and from the stylo-maxillary ligament. It passes at first downwards and then horizontally forwards, and is *inserted* along the side of the tongue as far as the tip, some of its lower fibres decussating with those of the hypo-glossus. Its action is to retract the tongue. Its nerve is a branch of the hypo-glossal.

Stylo-pharyngeus. This *arises* from the inner side of the styloid process near the base, and is *inserted* into the upper and posterior edges of the thyroid cartilage. It descends along the side of the pharynx between the superior and the middle constrictors; some of its fibres blend with the constrictor muscles; others join those of the palato-pharyngeus at its insertion. Curving round its lower border is seen the glosso-pharyngeal nerve, from which its nerve-supply is derived. Its *action* is to raise the larynx with the pharynx in deglutition.* (See Fig. 82.)

Between the stylo-glossus and stylo-pharyngeus, and nearly parallel

* Varieties of this muscle are frequently met with, chiefly as supernumerary muscles. They arise variably from neighboring parts of the base of the skull close to the styloid process, and are inserted either into the pharyngeal constrictors or into the aponeurosis of the pharynx.

with both, is the *stylo-hyoid ligament*. It extends from the apex of the styloid process to the lesser cornu of the os hyoides. It is often more or less ossified.

The *ascending palatine artery*, a branch of the facial (p. 115), runs up between the stylo-glossus and the stylo-pharyngeus, and divides into branches which supply these muscles, the palate, the side of

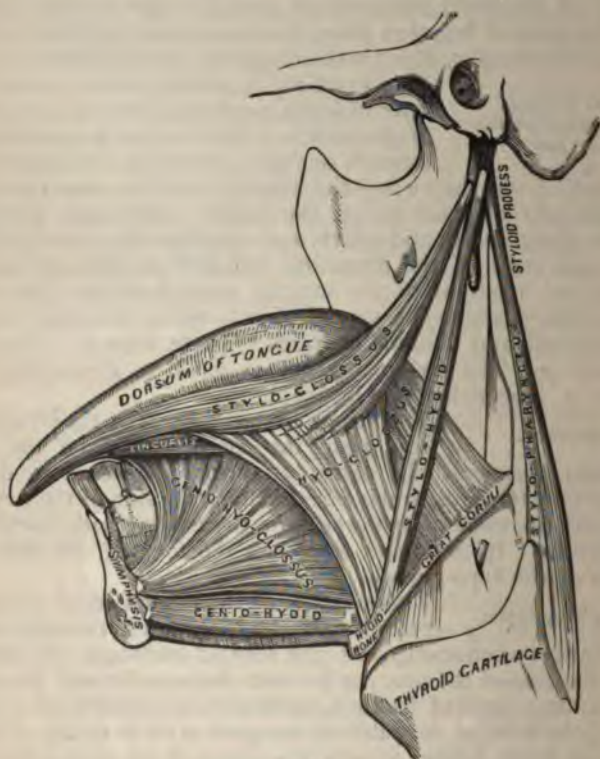


FIG. 58.

the pharynx, and the tonsils. It inosculates with the descending palatine, a branch of the internal maxillary.

Glosso-pharyngeal Nerve.

The glosso-pharyngeal nerve is observed curving forwards round the lower border of the stylo-pharyngeus (p. 155). It is the ninth cranial nerve, arises by five or six filaments from the groove between

the olivary body and the restiform tract of the medulla oblongata, leaves the skull through the middle part of the foramen jugulare in a separate sheath of dura mater, in front of the pneumogastric and spinal accessory nerves, and descends between the internal jugular vein and the internal carotid artery. It then crosses in front of the artery below the styloid process, and proceeds along the lower border of the stylo-pharyngeus. At this point it curves forwards over that muscle and the middle constrictor of the pharynx, and disappears beneath the hyo-glossus, where it divides into its terminal branches, which supply the mucous membrane of the pharynx, the back of the tongue, and the tonsils.

The glosso-pharyngeal is, at its origin, purely a sensory nerve. But soon after its exit from the skull it receives *communications* from the facial, the pneumogastric, and the sympathetic, so that it soon becomes a compound nerve—*i. e.*, composed of both sensory and motor filaments. At the base of the skull it presents two ganglia—the *jugular* and the *petrous* (ganglion of Andersch). The branches given off by the petrous ganglion will be dissected hereafter; at present the student can only make out the branches which this nerve gives off in the neck, namely:—

Carotid branches, which surround the internal carotid artery as far as its origin, and communicate with the pharyngeal branch of the pneumogastric and with the sympathetic.

Pharyngeal branches, three or four in number, which form by the side of the middle constrictor of the pharynx, a plexus, the *pharyngeal plexus*, supplemented by filaments derived from the pneumogastric, the *nervus accessorius*, the external laryngeal, and the sympathetic. Its branches supply the constrictor muscles and the mucous membrane of the pharynx, the back of the tongue, and the tonsils.

Muscular branches which enter the stylo-pharyngeus m.

Tonsillar branches which are given to the soft palate and the fauces, and to the tonsils forming a plexus (*circulus tonsillaris*).

Lingual branches, two in number, which are distributed to the base and lateral aspects of the tongue: one branch turns upwards and is distributed to the papillæ circumvallatæ, and the mucous membrane of the posterior third of the tongue as far backwards as the epiglottis; the other passes to the middle of the side of the tongue communicating with the gustatory nerve.

The styloid process must now be cut through at its base, and turned forwards with the muscles arising from it. The internal carotid artery will thus be exposed in the cervical region, as far as the carotid canal. The part of the artery contained within the carotid canal will be described hereafter.

Internal Carotid Artery.

The *internal carotid artery* proceeds from the bifurcation of the common carotid at the upper border of the thyroid cartilage, and ascends vertically to the base of the skull *by the side of the pharynx*, in front of the transverse processes of the three upper cervical verte-

bræ. It enters the skull through the carotid canal in the temporal bone, runs tortuously by the side of the body of the sphenoid, and terminates in branches which supply the orbit and the brain. It is divided into four portions—the cervical, petrous, cavernous, and cerebral. In the *cervical part* of its course it is situated immediately to the outer side of the external carotid artery, behind the inner border of the sterno-mastoid. It soon gets beneath the external carotid, and lies deeply beneath the parotid gland, and ascends by the side of the pharynx and tonsil. It *lies upon* the rectus capitis anticus major, the superior laryngeal nerve, and the superior cervical ganglion of the sympathetic; to its *outer side* is the internal jugular vein and the pneumogastric nerve; to its *inner side* is the pharynx, the tonsil, and the ascending pharyngeal artery, it is *crossed*, successively, by the hypoglossal nerve, the occipital artery, the digastricus, and stylo-hyoid muscles; higher up it is crossed by the styloid process, the stylo-glossus, and stylo-pharyngeus muscles, by the glosso-pharyngeal nerve and the stylo-hyoid ligament, all of which last-named structures intervene between it and the external carotid.

The most important relation of the artery, in a surgical point of view, is that it ascends close by the *side of the pharynx and tonsil*. In opening an abscess, therefore, near the tonsil, or at the back of the pharynx, be careful to introduce the knife with its point inwards towards the mesial line; observe this caution the more, because in some subjects the internal carotid makes a curve, or even a complete curl upon itself, in its ascent near the pharynx. In such cases an undue deviation of the instrument in an outward direction might injure the vessel.

Ascending Pharyngeal Artery.

This artery generally arises from the back part of the external carotid about half an inch (12.5 mm.) above the angle of the common carotid. It ascends in a straight course between the internal carotid artery and the side of the pharynx, towards the base of the skull, resting upon the rectus capitis anticus major. It gives off three sets of branches:—

a. Pharyngeal branches, three or four in number: the two lower supply the inferior and middle constrictors, and stylo-pharyngeus, anastomosing with the superior thyroid a.; the upper branch, the *palatine*, ascends upon the superior constrictor, runs down with the levator palati, above the superior constrictor, and supplies the muscles of the palate, the Eustachian tube, and the tonsil.

b. Prevertebral branches, which supply the prevertebral muscles, the superior cervical ganglion of the sympathetic, the lymphatic glands, and the pneumogastric and hypoglossal nerves.

c. Meningeal branches, which supply the dura mater; passing through the foramen lacerum medium, the anterior condylar foramen, and the foramen jugulare with the internal jugular vein.

Pneumogastric Nerve.

The *pneumogastric nerve* is the tenth cranial nerve, and has the longest course of all the cerebral nerves. It arises from the medulla oblongata by a series of roots, from twelve to fifteen in number, from the front of the restiform body. It passes out of the skull in a common sheath of dura mater and arachnoid, with the *nervus accessorius* through the foramen jugulare.

Within the foramen jugulare a small ganglion—*ganglion of the root* (Arnold's ganglion)—about one-sixth of an inch (*4 mm.*) in length, is situated upon the pneumogastric nerve, and is joined by a branch from the *nervus accessorius*. This ganglion will be described hereafter. About half an inch (*12.5 mm.*) below the preceding the pneumogastric nerve swells out, and forms a second ganglion—*ganglion of the trunk*—(inferior ganglion), of a reddish-grey colour. This ganglion occupies about an inch (*2.5 c. m.*) of the nerve, but does not involve the whole of its fibres, the branch from the spinal accessory joining the pneumogastric below the ganglion. It is united to the hypoglossal nerve, from which it receives filaments; it also receives filaments from the first and second spinal nerves, and from the superior cervical ganglion of the sympathetic.

Thus, the pneumogastric, at its origin probably a nerve of sensation only, becomes, in consequence of the connecting filaments from these various branches, a compound nerve, and in all respects analogous to a spinal nerve.

Leaving the skull at the foramen jugulare, the nerve descends in front of the cervical vertebræ, lying successively upon the *rectus capitis anticus major* and the *longus colli*. In the upper part of the neck it is situated, lying in the same sheath, between the internal carotid artery and the internal jugular vein; lower down it lies between and behind the common carotid and the internal jugular vein. It enters the chest on the right side, crossing in front of the first part of the subclavian artery, nearly at a right angle; on the left, running nearly parallel with it.

In their course through the chest the pneumogastric nerves have not similar relations. The *right* nerve lies beneath the subclavian vein, and then descending behind the right brachio-cephalic vein by the side of the trachea, is continued behind the right bronchus to the posterior part of the œsophagus. The *left* nerve passes behind the left brachio-cephalic vein, then crosses in front of the arch of the aorta, and behind the left bronchus to the anterior part of the œsophagus. Both nerves subdivide on the œsophagus into a plexus, the right nerve forming the *posterior œsophageal plexus*, the left the *anterior*. Each plexus again collects its fibres together to form a single trunk; thus two main nerves are formed which pass with the œsophagus through the diaphragm; of these

the right is distributed over the posterior, the left over the anterior surface of the stomach.*

In their long course from the medulla oblongata to the abdomen the pneumogastric nerves supply branches to most important organs; namely, to the pharynx, the larynx, the heart, the lungs, the œsophagus, the stomach, and the liver.

The branches of the pneumogastric are those of communication and those of distribution:—

1. The *branches of communication* are those in connection with the ganglion of the root and the ganglion of the trunk.

a. The *ganglion of the root* has connecting filaments with the accessory portion of the spinal accessory, the superior cervical ganglion of the sympathetic, and with the petrous ganglion of the glosso-pharyngeal.

b. The *ganglion of the trunk* has communicating filaments with the hypoglossal, the loop between the first two cervical nerves, and the superior cervical ganglion of the sympathetic.

2. The *branches of distribution* are—

a. The *auricular* (Arnold), which cannot at present be seen, will be made out in the dissection of the nerve at the base of the skull.

b. The *pharyngeal* arises from the upper part of the ganglion of the trunk, and, receiving a filament from the accessory part of the spinal accessory, descends either in front of or behind the internal carotid. The nerve, after passing to the inner side of the internal carotid, divides into branches, which with the other filaments (described p. 157) upon the middle constrictor muscle form the *pharyngeal plexus*. From this plexus branches are distributed to the muscles and the mucous membrane of the pharynx.†

c. The *superior laryngeal*, derived from the middle of the ganglion of the trunk, descends behind the internal carotid, and divides into two branches, the internal and the external laryngeal.

The *internal laryngeal* passes to the interval between the os hyoides and the thyroid cartilage, and enters the larynx (with the superior laryngeal a.), through the thyro-hyoid membrane, to be distributed, as a nerve of sensation, to the mucous membrane of the larynx and epiglottis. The *external laryngeal*, the smaller, gives off some branches to the pharyngeal plexus, the inferior constrictor, and the thyroid body, and then descends by the side of the larynx beneath the depressors of the os hyoides to supply the crico-thyroid muscle; it communicates with the superior cardiac nerve of the sympathetic.

d. The *cervical cardiac branches* descend behind the sheath of the carotid artery to the cardiac plexus. The *upper branches*, one or two in number, are small, and proceed from the ganglion of the trunk; they join the cardiac branches of the sympathetic and the deep cardiac plexus; the *lower* comes from the trunk of the pneumogastric before it enters the chest. Subsequently, the right lower cardiac nerve descends by the side of the innominate artery to join the deep cardiac plexus; the left passes over the arch of the aorta to join the superficial cardiac plexus.

* The differences in the course and destination of the right and the left pneumogastric nerves may be explained in the process of development. The student is therefore referred to works which treat of this subject.

† A branch from the plexus is described by Luschka as receiving filaments from the pharyngeal branches of the glosso-pharyngeal and pneumogastric nerves, and joining with the hypoglossal as it winds round the occipital artery.

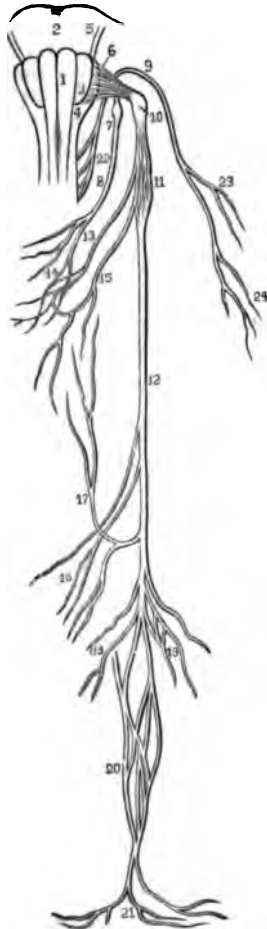


FIG. 59.—ORIGIN AND DISTRIBUTION OF THE GLOSSO-PHARYNGEAL, PNEUMOGASTRIC, AND SPINAL ACCESSORY NERVES.

1, 3, 4. Medulla oblongata. 1. Ant. pyramid. 3. Olivary body. 4. Restiform body. 2. Pons. 5. Seventh or facial. 6. Origin of the glosso-pharyngeal. 7. Ganglion of Andersch. 8. Trunk of the nerve. 9. Spinal accessory nerve. 10. Superior or ganglion of the root of the pneumogastric nerve. 11. Inferior or ganglion of the trunk. 12. Trunk. 13. Pharyngeal branch forming pharyngeal plexus (14), assisted by a branch from the glosso-pharyngeal (8), and one from the superior laryngeal nerve (15). 16. Cardiac branches. 17. Recurrent laryngeal branch. 18. Anterior pulmonary and cardiac branches. 19. Posterior pulmonary and cardiac branches. 20. Oesophageal plexus. 21. Gastric branches. 22. Origin of the spinal portion of the spinal accessory nerve. 23. Branches of the whole nerve to sterno-mastoid muscle. 24. Branches to the trapezius.

c. The *inferior or recurrent laryngeal nerve* turns, on the right side, under the subclavian artery (p. 128), and ascends obliquely inwards to the larynx behind the common carotid and the inferior thyroid arteries; it lies subsequently in the groove between the œsophagus and the trachea. On the left side, it turns under the arch of the aorta, just on the outer side of the remains of the ductus arteriosus; after which it runs up between the trachea and the œsophagus. On both sides the nerves enter the larynx beneath the lower border of the inferior constrictor, and supply all the intrinsic muscles of the larynx, except the crico-thyroid. These nerves, as they turn under their respective vessels, give off cardiac branches to the deep cardiac plexus. They supply also filaments to the trachea, œsophagus, and inferior constrictor muscle.

The remaining branches of the pneumogastric nerve to the lungs, heart, œsophagus, and stomach will be examined in the dissection of the chest.

Spinal Accessory Nerve.

The *spinal accessory nerve* issues through the middle part of the foramen jugulare, in a sheath of dura mater common to it and the pneumogastric nerve. It arises by numerous filaments from the side of the medulla oblongata below the pneumogastric, and from the lateral column of the spinal cord as low down as the sixth cervical vertebra. The filaments which arise from the medulla oblongata join to form the *accessory portion* of the nerve; the spinal filaments ascend between the ligamentum denticulatum and the posterior roots of the cervical spinal nerves, and form the *spinal portion* of the nerve. These portions converge to the jugular foramen, where they communicate with each other more or less, and are then continued onwards below the jugular foramen as two portions—the internal or accessory, which joins the pneumogastric n.; the external or spinal, which is distributed to muscles.

The *accessory part*, within the foramen jugulare, sends one or more filaments to the ganglion of the root of the pneumogastric. It lies close to the pneumogastric nerve at the ganglion of the trunk, and is finally incorporated with the nerve below the ganglion. It sends filaments to the pharyngeal and superior laryngeal branches of the pneumogastric.

The *spinal part* separates from the accessory part below the foramen jugulare. It then takes a curved course backwards and outwards, lying in front of the internal jugular vein and the transverse process of the atlas, and behind the digastric and stylo-hyoid muscles. It pierces the upper part of the sterno-mastoid muscle accompanied by the superior sterno-mastoid artery, a branch of the occipital, and supplies the muscle, joining in its substance with branches from the third cervical n. The nerve then crosses obliquely the occipital triangle, where it communicates with the second and third cervical nerves. It is eventually distributed to

the under aspect of the trapezius, where it is joined by branches from the third and fourth cervical nerves.

Hypoglossal Nerve. This nerve arises, by from ten to fifteen filaments, from the groove between the anterior pyramid and the olivary body. It passes through the dura mater in two fasciculi, which emerge from the skull through the anterior condylar foramen, and then unite to form a single nerve. It comes forward between the internal jugular vein and the internal carotid artery, where it is intimately connected with the pneumogastric nerve. Its further course has been described (p. 119).

In the anterior condylar foramen the hypoglossal gives off a small filament to the diploë and to the dura mater around the foramen magnum. At the base of the skull it gives off several branches, which connect it with the ganglion of the trunk of the pneumogastric nerve. These two nerves are sometimes almost inseparably united. It gives off also several delicate filaments to the superior cervical ganglion of the sympathetic, and communicates with the loop formed by the first two spinal nerves in front of the atlas.

Sympathetic Nerve. Now examine the cervical ganglia of the sympathetic system of nerves. This system consists of a series of ganglia arranged on each side of the spine, from the first cervical to the last sacral vertebra. The successive ganglia of the same side are connected by intermediate nerves, so as to form a continuous cord on each side of the spine; this constitutes what is called the trunk of the sympathetic system, and is connected with all the spinal nerves. Its upper or cephalic extremity enters the cranium through the carotid canal, surrounds the internal carotid artery, communicates with the third, fourth, fifth, and sixth cranial nerves, and joins its fellow of the opposite side upon the anterior communicating artery.* Its sacral extremity joins its fellow by means of the little *ganglion impar*, situated in the mesial line, upon the coccyx.

The ganglia are connected together by branches composed of grey and white nerve-fibres; they are also connected with the spinal nerves by two filaments—one, of white nerve-fibres which passes from the spinal nerve to the ganglion; the other, of grey, from the ganglion to the spinal nerve. Branches of distribution are also given off by the ganglia, some to the various blood-vessels and viscera, forming intricate plexuses upon them; others to the various ganglia of the viscera—the cardiac and semilunar ganglia.

The different portions of the sympathetic gangliated cord receive, respectively, the distinguishing names of the cervical, dorsal,

* Here is situated the so-called *ganglion of Ribes*.

lumbar, sacral, and coccygeal. At present we have only to consider the cervical portion of it.

To expose the cervical ganglion of the sympathetic, the internal carotid artery, the pneumogastric, glosso-pharyngeal, and hypoglossal nerves should be cut through, near the base of the skull; then by careful dissection the superior cervical ganglion can be traced out.

Cervical Ganglia of Sympathetic.

In the cervical portion of the sympathetic are three ganglia, named from their position, superior, middle, and inferior.

The *superior cervical ganglion*, the largest of the three, is situated near the base of the skull, opposite the second and third cervical vertebræ, upon the rectus capitis anticus major, and lies behind and on the inner side of the internal carotid artery. It is of a reddish-grey colour like the other ganglia, of an elongated oval shape, varying in length from one to two inches (2.5 to 5 cm.).

To facilitate the description of its several branches, we divide them into an upper, a lower, an external, an internal, and an anterior set—

a. Its *upper or cranial* branch runs with the internal carotid a. into the carotid canal of the temporal bone, and there divides into two branches, an outer and an inner. The *outer* and larger branch accompanies the artery through its bony canal, ramifies upon it by the side of the body of the sphenoid, and so constitutes the "CAROTID PLEXUS."* From this outer branch a filament proceeds to the Gasserian ganglion; another to the sixth cranial nerve; a third joins the great petrosal branch of the facial, and forms the Vidian nerve, and thus communicates with the sphenopalatine ganglion. It also communicates in the carotid canal with the tympanic branch of the glosso-pharyngeal. The *inner* branch, running on with the artery to the cavernous sinus, there forms another plexus, called from its position the "CAVERNOUS PLEXUS." Here the sympathetic is seen to communicate with the third, the fourth, and the ophthalmic branch of the fifth and sixth cranial nerves, and with the ophthalmic ganglion. Lastly, from both these plexuses secondary plexuses proceed, of which the minute filaments ramify on, and supply the coats of, the terminal branches of the internal carotid.

b. The *lower branch* descends and joins the middle cervical ganglion of the sympathetic.

c. The *external branches* are numerous, and connect the ganglion with the ganglion of the pneumogastric and hypoglossal nerves, and with the four upper cervical spinal nerves. A small twig also joins the petrosal ganglion of the glosso-pharyngeal and the upper ganglion of the pneumogastric in the foramen jugulare.

d. The *internal branches* are distributed to the pharynx, larynx, and the heart. The pharyngeal branches join the pharyngeal plexus on the middle constrictor of the pharynx; the laryngeal join the superior laryngeal nerve; the cardiac nerves, one or more in number—*superior cardiac*—descend behind the sheath of the carotid in front of the inferior thyroid artery and recurrent laryngeal nerve, and, entering the chest, join the superficial and deep cardiac plexuses.

* A small ganglion, the *carotid ganglion*, is sometimes met with in this plexus on the under aspect of the artery.

e. The anterior branches lie in front of the external carotid artery and ramify around this vessel and its branches, forming the various plexuses, and named, on account of their delicacy, the *nervi molles*. In some of these plexuses are occasionally seen several ganglia, the intercarotic,* lingual, temporal, and pharyngeal

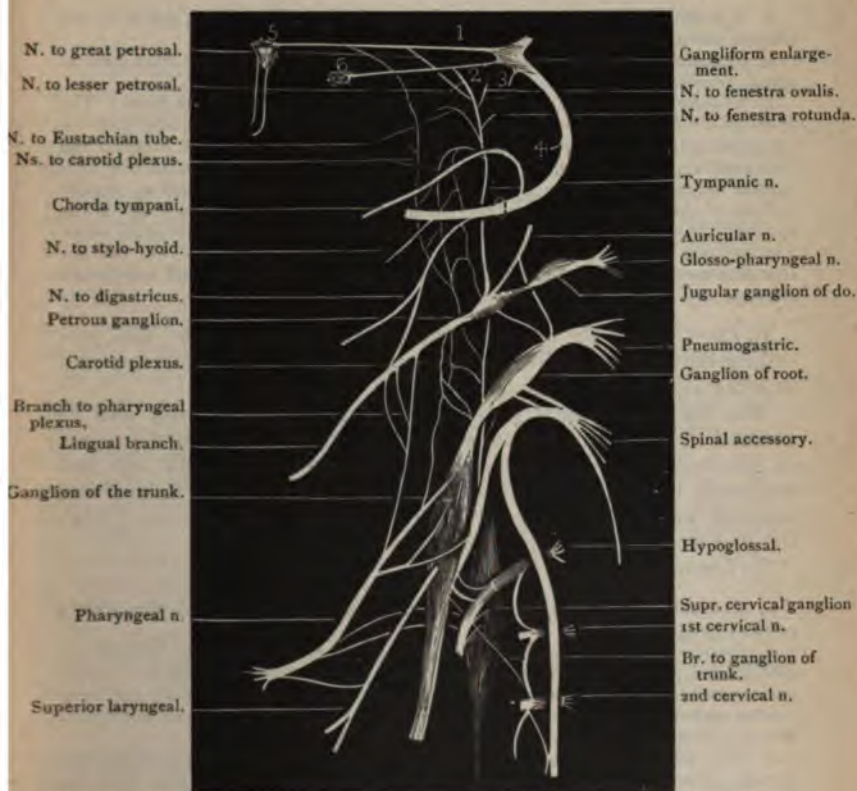


FIG. 60.—DIAGRAM OF THE COMMUNICATIONS OF THE FACIAL GLOSSO-PHARYNGEAL, PNEUMOGASTRIC, SPINAL ACCESSORY, HYPGLOSSAL, SYMPATHETIC, AND THE TWO UPPER CERVICAL NERVES.

1. Great petrosal nerve. 2. Lesser petrosal nerve. 3. External petrosal nerve. 4. Nerve to Stapedius muscle. 5. Spheno-palatine ganglion. 6. Otic ganglion.

ganglia. They are connected with the several ganglia about the head and neck; namely, the ophthalmic, spheno-palatine, otic, and submaxillary.

* Situated in the angle at the bifurcation of the common carotid into the external and internal carotid arteries; it corresponds in structure with the coccygeal gland.

The *middle cervical ganglion*, the smallest of the three ganglia, is something less than a barleycorn in size. It is situated behind the carotid sheath, about the fifth or sixth cervical vertebra, on or near the inferior thyroid artery.

a. It is connected by branches with the superior ganglion above, and with the inferior cervical ganglion below.

b. Its *external branches* usually pass outwards to join the fifth and sixth cervical spinal nerves.

c. Its *internal branches* are distributed to the thyroid body and the heart. The *branches to the thyroid body* accompany the inferior thyroid artery, and join the superior cardiac nerve, and in the gland they communicate with the external and recurrent laryngeal nerves. The *middle cardiac nerve*, the largest of the three cardiac nerves, descends, on the right side behind the common carotid a., usually in front of the first part of the subclavian artery, into the chest, when it lies on the trachea. It is joined by some cardiac filaments from the recurrent laryngeal nerve and superior cardiac nerve, and joins the deep cardiac plexus. On the left side this cardiac nerve enters the chest between the left carotid and subclavian arteries.

In cases where the middle cervical ganglion is absent, the preceding nerves are supplied by the sympathetic cord connecting the superior and inferior ganglia.

The *inferior cervical ganglion* is of considerable size, and is situated in the interval between the base of the transverse process of the seventh cervical vertebra and the neck of the first rib, immediately behind the vertebral artery, and to the inner side of the superior intercostal artery. Not infrequently it is coalesced with the first dorsal sympathetic ganglion.

Its branches are as follow :—

a. *Superior branches* which pass upwards and connect it with the middle cervical ganglion.

b. *Inferior branches* which descend, some in front of, and some behind, the subclavian a., to join the first dorsal ganglion. One of these, the *inferior cardiac nerve*, passes behind the subclavian a. in front of the trachea, to join the deep cardiac plexus, beneath the arch of the aorta, and communicates with the recurrent laryngeal and middle cardiac nerves.

c. *External branches* which communicate with the seventh and eighth cervical nerves; others form a plexus around the vertebral artery, which join with the fourth, fifth, and sixth cervical nerves.

DISSECTION OF THE THORAX.

Before the several organs contained in the thorax are examined, the student should have some knowledge of its framework. The ribs with their cartilages describe a series of arcs increasing in length from above downwards, and form, with the dorsal vertebræ behind and the sternum in front, a barrel of a conical shape, broader in the lateral than in the antero-posterior diameter. The spaces between the ribs are occupied by the intercostal muscles. In each intercostal space there are two layers of these muscles, arranged like the letter X. The fibres of the outer layer run obliquely from above downwards and forwards; those of the inner layer in the reverse direction. The base is closed in the recent state by a muscle—the diaphragm—which forms a muscular partition between the chest and the abdomen. This partition is arched upwards, so that it constitutes a vaulted floor for the chest, and by its capability of alternately falling and rising, it increases and diminishes the capacity of the thorax.

In front, the diaphragm is attached to the ensiform cartilage, but it slopes posteriorly, to become attached to the last rib. The circumference of the diaphragm is convex and muscular; in the centre it is flattened and aponeurotic. On the right side it corresponds, in front, with the upper border of the cartilage of the fifth rib; on the left side it corresponds with the upper border of the sixth rib.

The upper opening of the osseous thorax is bounded posteriorly by the body of the first dorsal vertebra, laterally by the first ribs, and in front by the upper border of the manubrium sterni.*

* That the student may have some knowledge of the diameters of the chest at different situations, the following measurements have been taken from a well-articulated male skeleton of the average height: The *antero-posterior* diameter at the upper opening of the thorax is $2\frac{3}{4}$ inches (5.6 cm.), at the articulation of the manubrium with the gladiolus it is $4\frac{1}{2}$ inches (11.2 cm.), and at the junction of the gladiolus with the ensiform cartilage it has increased to $5\frac{5}{8}$ (14.25 cm.) inches. The *transverse diameter* of the upper opening was found to be $4\frac{3}{8}$ inches (11 cm.); between the second ribs, 7 inches (17.5 cm.); between the third, $8\frac{3}{8}$ inches (20.3 cm.); the diameter increased in regular proportion as far as the ninth rib, where it attained a measurement of $10\frac{5}{8}$ inches (26.6 cm.); below this it gradually decreased. The upper border of the manubrium corresponds to the second dorsal vertebra. The articulation of the manubrium and the gladiolus is on a level with the fourth dorsal vertebra; and, lastly, the junction of the ensiform cartilage with the gladiolus is on a level with the border of the ninth or tenth dorsal vertebra.

Such, in outline, is the framework of the thorax, which contains the heart with its large vessels and the lungs. Its walls are composed of different structures—bone, cartilage, muscles, and ligaments, which fulfil two important conditions: 1st, by their solidity and elasticity they protect the important organs contained in the thorax; 2ndly, by their alternate expansion and contraction they act as mechanical powers of respiration. For they can in-

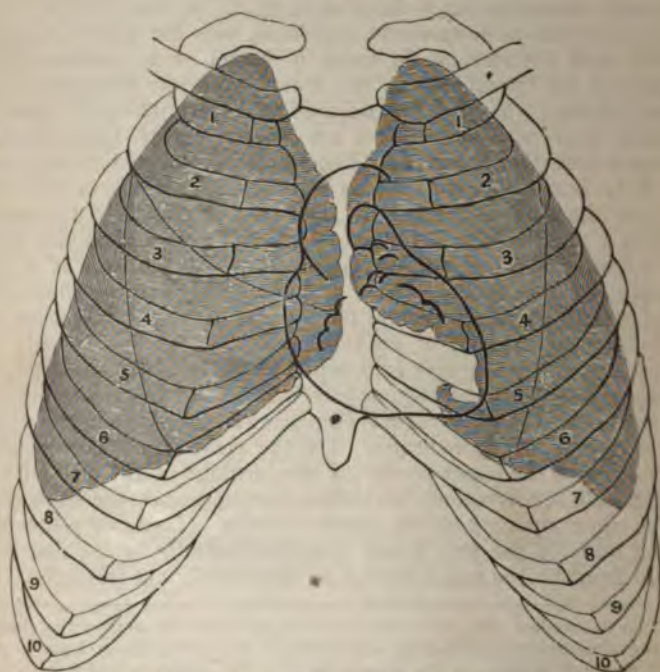


FIG. 61.—FORM OF THE LUNGS, AND THE EXTENT TO WHICH THEY OVERLAP THE HEART AND ITS VALVES.

crease the capacity of the chest in three directions: in height, by the descent of the diaphragm; in width, by the rotation of the ribs; and in depth, by the elevation of the sternum.

The chest of the female differs from that of the male in the following points: Its general capacity is less; the sternum is shorter; the upper opening is larger in proportion to the lower; the upper ribs are more moveable, and therefore permit a greater

enlargement of the chest at its upper part, in adaptation to the condition of the abdomen during pregnancy.

The *upper opening of the thorax* gives passage to the trachea, the œsophagus, the large vessels of the head and neck and upper extremities, viz., the innominate, the left carotid, and subclavian arteries, with the left innominate and right subclavian and internal jugular veins, the superior intercostal and internal mammary arteries, the inferior thyroid veins, the sterno-hyoid, sterno-thyroid, and longus colli muscles of each side, the pneumogastric, the left recurrent laryngeal, the phrenic, and the sympathetic nerves; the cardiac branches of the sympathetic, and the cardiac branches of the pneumogastric; also to the anterior branch of the first dorsal nerve as it passes up to join the brachial plexus, the thoracic duct, the thymus gland (in early life), and, lastly, to the apices of the lungs, which, with their pleural covering, rise up on each side into the neck for about one inch and a half (3.75 cm.) above the first rib; the interspaces between these various structures being occupied by a dense fibro-cellular tissue, continuous with the deep cervical fascia.

The diaphragm, which forms the base of the thorax, is pierced by the following foramina: The *aortic opening*, for the passage of the aorta, vena azygos major, thoracic duct; the *œsophageal opening*, for the œsophagus, pneumogastric nerves, and œsophageal branch of the coronaria ventriculi artery; the *foramen quadratum*, for the vena cava inferior, a branch of the right phrenic nerve and lymphatics from the liver; the *right crus* transmits the greater and lesser splanchnic nerves; the *left crus*, in addition, transmits the vena azygos minor. In front there are the narrow intervals for the passage of the internal mammary arteries.

Dissection. An opening must be made into the chest by carefully removing the upper four-fifths of the sternum, and the cartilages of all the true ribs.* In doing this, care must be taken not to wound the pleura, which is closely connected with the cartilages. On one side the internal mammary artery should be dissected; on the other, removed.

In the dissection of the chest let us take the parts in the following order:—

1. Triangularis sterni, with the internal mammary artery.
2. Mediastina, anterior, middle, and posterior.
3. Pleura.
4. Position and form of the lungs.
5. Pericardium.

* Those who are more proficient in dissection should not remove the whole of the sternum, but leave a quarter of an inch of its upper part with the first rib attached to it. This portion serves as a valuable landmark, although it obstructs, to a certain extent, the view of the subjacent vessels.

6. Position and relations of the heart.
7. Posterior mediastinum and its contents; namely, the aorta, the thoracic duct the vena azygos, the œsophagus, and pneumogastric nerves.
8. Right and left brachio-cephalic veins and superior vena cava.
9. Course of the phrenic nerves.
10. Course and relations of the arch of the aorta.
11. The three great branches of the arch.
12. Sympathetic nerve.
13. Intercostal muscles, vessels, and nerves.
14. Nerves of the heart; cardiac plexuses.

Triangularis Sterni. On the under surface of the sternum and cartilages of the ribs is a thin, flat muscle, named the *triangularis sterni*. It arises from the ensiform cartilage, the lower part of the side of the sternum, and the cartilages of two or three lower true ribs. Its fibres ascend obliquely outwards, and are inserted by fleshy digitations into the lower borders of the cartilages of the true ribs—from the sixth to the second. Its lowest digitation runs transversely outwards, each successive one, however, becomes more oblique, so that the highest one is nearly vertical in direction. The muscle is evidently a continuation upwards of the anterior portion of the transversalis abdominis. Its action is to draw down the costal cartilages, and thus it acts in expiration. Its nerves come from the intercostal nerves, its arteries from the internal mammary.

Internal Mammary Artery. This artery is given off from the subclavian in the first part of its course opposite the thyroid axis. It passes down behind the clavicle, and on entering the chest it lies between the cartilage of the first rib and the pleura, and is crossed by the phrenic nerve. It then descends perpendicularly, about half an inch (12.5 mm.) from the sternum, lying on the pleura and behind the costal cartilages; lower down it gets between the cartilages of the ribs and the triangularis sterni, as far as the seventh costal cartilage, where it divides into two branches, the *musculo-phrenic* and the *superior epigastric*. The latter branch then enters the wall of the abdomen behind the rectus abdominis, and finally inosculates with the deep epigastric (a branch of the external iliac). The branches of the internal mammary are as follows:—

a. Arteria comes nervi phrenici.—A very slender artery, which accompanies the phrenic nerve between the pleura and pericardium to the diaphragm, and anastomoses with the phrenic branches of the abdominal aorta and internal mammary.

b. Mediastinal, pericardiac, sternal, and thymic.—These branches supply the cellular tissue of the anterior mediastinum, the pericardium, and the triangularis sterni. The *thymic* are only visible in childhood, and disappear with the thymus gland.

c. Anterior intercostal.—Two for each intercostal space are distributed to the

five or six upper intercostal spaces. They pass outwards, and lie at first between the pleura and the internal intercostal muscle, and subsequently between the two intercostals. They inosculate with the intercostal arteries from the aorta.

d. The *perforating arteries* pass through the same number of intercostal spaces as the preceding branches, and supply the pectoral muscle and skin of the chest. In the female they are of large size (especially the third), to supply the mammary gland.

e. The *musculo-phrenic* branch runs outwards behind the cartilages of the false ribs, pierces the attachment of the diaphragm, and terminates near the last intercostal space. It supplies small branches to the diaphragm, to the sixth, seventh, and sometimes the eighth intercostal spaces.

Two *venæ comites* accompany the artery, and form a single trunk at the upper part of the chest, which terminates in the brachiocephalic vein of its own side.

Lymphatic Glands. There are several *lymphatic glands* in the neighbourhood of the internal mammary artery. They receive the lymphatics from the upper part of the abdominal wall, the diaphragm, the inner portion of the mammary gland, and the intercostal spaces. On the right side they terminate in the right lymphatic duct, on the left in the thoracic duct. In disease of the inner portion of the mamma these glands may enlarge without any enlargement of those in the axilla.

Pleura. As the lungs are constantly gliding to and fro within the chest they are provided with a serous membrane to facilitate their motion. This membrane is termed the *pleura*. There is one for each lung. Each pleura forms a completely closed sac, and, like all other serous sacs, has a *parietal* and a *visceral layer*—that is, the first layer lines the containing walls, the latter is reflected over the contained organ or viscus. Its several parts are named after the surface to which they adhere: the parietal layer, which lines the ribs and intercostal muscles, is called *pleura costalis*; the visceral layer, which invests the lungs, *pleura pulmonis*; between these two layers is a space which is termed *the cavity of the pleura*.

Each pleura occupies its own half of the thorax; they do not communicate with one another, nor do they come into contact with each other, except for the short distance of about two inches (5 *cm.*) in front, behind the sternum.

Unlike the peritoneum, the pleura forms no folds except a small one, called *ligamentum latum pulmonis*, which extends from the root of the lung to the diaphragm.

The *pleura costalis* (Fig. 62), in front, lines part of the back of the sternum and the inner surfaces of the costal cartilages; laterally, it is reflected over the ribs and the intercostal muscles; posteriorly, it is traced over the sides of the bodies of the dorsal vertebræ; thence it passes to the back of the pericardium, over the

posterior aspect of the root of the lung. It may now be traced, as the *pleura pulmonalis*, over the surface of the lung, to which it is intimately adherent, into the fissures between the lobes, as far as the anterior border of the lung; thence round its pericardial aspect to the front of the root of the lung, passing forwards over the pericardium to the back of the sternum. Its only reflection, the *ligamentum latum pulmonis*, has been already alluded to. Below, the pleura covers the diaphragm.

The pleura rises as a conical dome into the base of the neck, about an inch (2.5 cm.) above the first rib, and is strengthened in this situation by expansions from the scaleni muscles.*

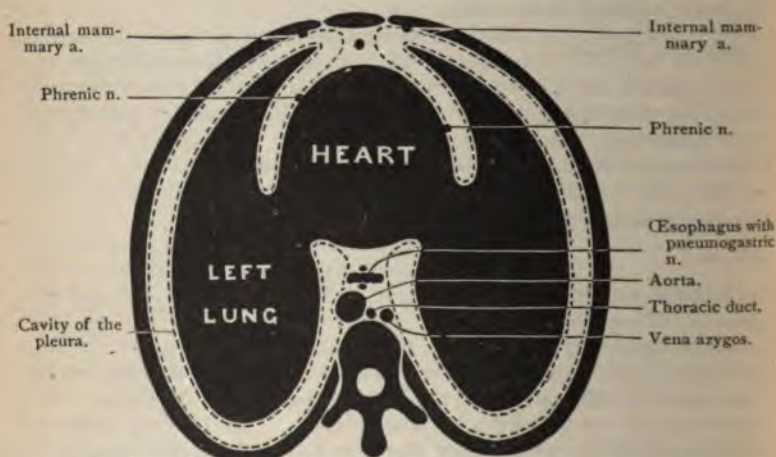


FIG. 62.—DIAGRAM OF THE REFLECTIONS OF THE PLEURAL SACS IN DOTTED LINES.

The thickness of the pleura differs: on the lung it is thin, semi-transparent, and firmly adherent; on the ribs and diaphragm it is thick, and may be easily separated from its osseous and muscular connections.†

* A slip is described by Sibson as passing from the transverse process of the last cervical vertebra, and, spreading out, is inserted into the pleural dome and the inner margin of the first rib.

† From the prevertebral fascia, a ligamentous band passes downwards along the inner border of the lung to be attached to the pericardium and the central tendon of the diaphragm. As it passes downwards it embraces the root of the lung, and supports it in its proper position. This band has been described as the "suspensory ligament of the diaphragm," by Teutleben.

The spaces called *anterior* and *posterior mediastina*, formed by the separation of the pleuræ, will be described further on.

In health the internal surface of the pleura is smooth, polished, and lubricated by moisture sufficient to facilitate the sliding of the lung. When this surface is thickened and roughened by inflammation, the moving lung produces a friction sound. When the pleural sac is distended by serum, it constitutes hydro-thorax; when by pus, empyema; when by air, pneumo-thorax; when by blood, hæmo-thorax.

Introduce your hand into the pleural sac, and ascertain that the reflection of the pleura on to the diaphragm corresponds with an imaginary line commencing at the lower part of the sternum and sloping along the cartilages of the successive ribs down to the lower border of the last rib. Supposing a ball to lodge in the pleural sac, it might fall upon the dome of the diaphragm, and roll down to the lowest part of the pleural cavity. The place, therefore, to extract it, would be in the back, at the eleventh intercostal space. This operation has been done during life with success.

If a transverse section were made through the chest (*see* Fig. 62), you would observe that as the pleuræ nowhere come into actual contact, a space is left between them extending from the sternum to the spine, and which is larger in the middle than in front or behind. This interval is called by anatomists the *interpleural space* or the mediastinum, and for convenience sake is subdivided into three parts—an *anterior*, *middle*, and *posterior mediastinum*.

**Mediastina, Anterior,
Middle, and Pos-
terior.**

The *mediastina* are the spaces which the two pleural sacs leave between them in the antero-posterior plane of the chest, and which contain all the thoracic viscera except the lungs.

There is an anterior, a middle, and a posterior mediastinum. To put these spaces in the simplest light, let us imagine the heart and lungs to be removed from the chest, and the two pleural sacs to be left in it by themselves. The two sacs, if inflated, would then appear like two bladders, in contact only in the middle, as shown by the dotted outlines in the annexed scheme (Fig. 63). The interval marked *a*, behind the sternum, would represent the *anterior mediastinum*; the interval *b*, the *posterior mediastinum*. Now let us introduce the heart again, between the two pleural sacs: these must give way to make room for it, so that the two sacs are largely separated in the middle line of the chest; and the space thus occupied by the heart and large vessels takes the name of the *middle mediastinum*.

Looking at the chest in front, the *anterior mediastinum* appears as shown in the diagram (Fig. 64). It is not precisely vertical in

its direction, for it inclines slightly towards the left, owing to the position of the heart. Its area varies; thus it is very shallow from before backwards; it is extremely narrow in the middle where the

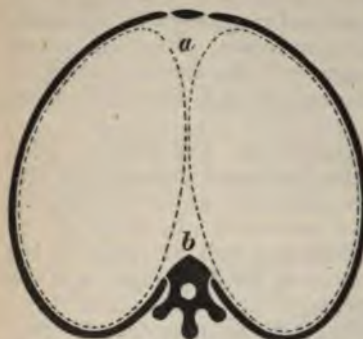


FIG. 63.

edges of the lungs nearly meet; it is wider above, and widest of all below, where the lungs diverge. Posteriorly it is limited by the pericardium covering the heart, aorta and its branches, and the pulmonary artery.

What parts are contained in the anterior mediastinum? The remains of the thymus gland, the origins of the sterno-hyoid, sterno-thyroid, and triangularis sterni muscles, the left brachio-cephalic vein (which crosses behind the first bone of the sternum), a few lymphatic glands,

and the left internal mammary artery and vein.

The *posterior mediastinum* (Fig. 62) is triangular in shape, placed in front of the dorsal vertebræ; it contains the œsophagus, the two pneumogastric nerves, the descending aorta, the thoracic duct, the greater and smaller azygos veins, the left superior intercostal vein, and some lymphatic glands. This space will be described in detail at a later stage.

The *middle mediastinum* is the largest of the mediastina, and contains the heart enclosed in the pericardium, the vena cava superior, the ascending aorta, the pulmonary arteries and veins, the phrenic nerves with their accompanying arteries, and the bifurcation of the trachea.

A *superior mediastinum* has also been described comprising that part of the interpleural space which lies above a horizontal plane, extending behind from the lower part of the body of the fourth dorsal vertebra to the articulation between the manubrium and gladiolus in front. The contents of this mediastinum include all those structures found above this nearly horizontal plane, and are the transverse portion of the arch of the aorta and its three large branches, the trachea, œsophagus, and thoracic duct, the innominate veins, superior vena cava, left recurrent laryngeal nerve, phrenic, pneumogastric, and cardiac nerves, lymphatic glands, and the thymus or its remains.

Before passing to the dissection of the contents of the thorax, the student should carefully trace the outline of the free borders of the pleuræ as seen in the front of the chest. As the margins of

the lungs for all practical purposes correspond with the borders of the pleuræ, we shall confine our description to the more important of the two structures, viz., the lungs. The value of this investigation is, that we are enabled to trace upon a living chest the outlines of the lungs, and know what parts are naturally resonant on percussion.

Commencing from above (Fig. 64), we find that the apex of

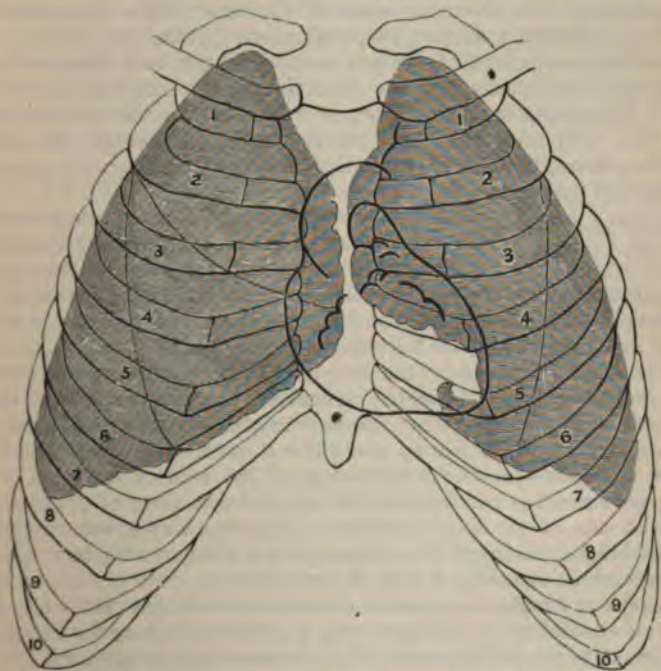


FIG. 64.—FORM OF THE LUNGS, AND THE EXTENT TO WHICH THEY OVERLAP THE HEART AND ITS VALVES.

the lung extends into the neck, from an inch to an inch and a half (2.5 to 3.75 cm.) above the clavicle. This part of the lung ascends behind the subclavian artery and the scalenus anticus muscle, and deserves especial attention, because it is, more than any other, the seat of tubercular disease. From the sternal end of the clavicles the lungs converge towards the middle line, where their borders nearly meet opposite the junction of the second rib. There is thus little or no lung behind the manubrium sterni.

From the level of the second costal cartilage to the level of the fourth, the inner margins of each lung run nearly parallel and almost in contact behind the middle of the sternum; consequently they overlap the great vessels at the root of the heart.

Below the level of the fourth costal cartilage the margins of the lungs diverge from each other, but not in an equal degree. The *left* presents the notch for the heart, and follows nearly the course of the fourth costal cartilages; at the lower part of its curve it projects more or less over the apex of the heart like a little tongue. The *right* descends almost perpendicularly behind the sternum as low as the attachment of the ensiform cartilage, and then turning outwards corresponds with the direction of the sixth costal cartilage. Hypertrophy of the heart, or effusion into the pericardium, will not only raise the point where the lungs diverge above the ordinary level, but also increase their divergence; hence the greater dulness on percussion.

**Position and Form
of the Lungs.**

The two lungs are situated in the chest: each in its own half of the thorax, with the heart, enclosed in its pericardium, between them. Each fits accurately into the cavity which contains it. Each, therefore, is conical in form; the *apex* projects into the root of the neck, a little more than an inch (2.5 cm.) above the sternal end of the clavicle; the *base* is broad and rests on the diaphragm, the posterior part being thin and extending as far as the eleventh rib. Its *outer surface* is convex and adapted to the ribs; its *inner surface* is excavated, to make room for the heart in front; and behind presents a deep fissure—*hilum pulmonis*—for the attachment of the root of the lung. Its *posterior surface* is convex, and fits into the concavity of the thorax, on each side of the spinal column. The best way to see the shape of the lungs is to inject them through the trachea with wax, which is tantamount to taking a cast of each thoracic cavity. In such a preparation, besides the general convexities and concavities alluded to, you would find in the right lung a little indentation for the right brachio-cephalic vein; in the left an indentation for the arch of the aorta and the left subclavian artery.

Each lung is divided into an *upper* and a *lower lobe* by a deep fissure, which commences, behind, about three inches (7.5 cm.) from the apex, and proceeds obliquely downwards and forwards to the junction of the sixth rib with its cartilage (Fig. 64). Speaking broadly, nearly the whole of the anterior portion of the lung is formed by the upper lobe; nearly the whole of the posterior portion by the lower lobe. It should be noticed, however, that the upper lobe of the right lung is divided by a second fissure which marks off, from its lower part, a triangular portion called its *middle lobe*.

The dimensions of the right lung are greater than those of the left in all directions except the vertical; the reason of this exception is the greater elevation of the diaphragm on the right side by the liver. On an average the right lung weighs 22 ounces (623 *gram.*), the left 20 ounces (566 *gram.*).

The lungs weigh $\frac{1}{37}$ of the total weight in the male, $\frac{1}{42}$ in the female. The specific gravity is 0.7, and, according to some authors, the absolute weight in the male is 1270 grammes (about 45 oz.); in the female, 1030 grammes. In an adult male the cubical dimensions of the lungs are 7000 c.c., *i. e.*, distended to the utmost. The dimensions in extreme expiration, 2500 c.c., or 4500 c.c. less than in extreme inspiration.

The constituents of the root of the lung will be described hereafter when they can be more satisfactorily displayed.

Præcordial Region. The *præcordial region* is the outline of the heart traced upon the front wall of the chest. It is important for auscultatory purposes that we should know how much of the heart is covered and separated from the wall of the chest by intervening lung (Fig. 64). The following will give a fair indication: "Make a circle of two inches (5 *cm.*) in diameter round a point midway between the nipple and the end of the sternum. This circle will define, sufficiently for all practical purposes, that part of the heart which lies immediately behind the wall of the chest, and is not covered by lung or pleura."*

This part of the *præcordial region* is naturally less resonant to percussion, for it is here uncovered, except by pericardium and loose connective tissue, and lies close behind the thoracic wall. In the rest of the *præcordial region* the heart is covered and separated from the chest wall by intervening lung.

Where should we put the stethoscope when we listen to the valves of the heart? For practical purposes it is enough to remember that the mouth of an ordinary-sized stethoscope will cover a portion of them all, if it be placed a little to the left of the mesial line of the sternum opposite the third intercostal space (Fig. 64, p. 175). They are all covered by a thin portion of lung; for this reason we ask a patient to stop breathing while we listen to his heart.

Position and Form of the Heart. The heart is situated obliquely in the chest between the lungs. Its base, *i. e.*, the part by which it is attached, and from which its great vessels proceed, is directed upwards towards the right shoulder; its apex points downwards and to the left, between the fifth and sixth costal cartilages. It is supported towards the abdomen, by the

* Latham's *Clinical Lectures*.

tendinous centre of the diaphragm. It is maintained in its position by a membranous bag termed the pericardium, which is lined by a serous membrane to facilitate its movements. The pericardium must first claim our attention.

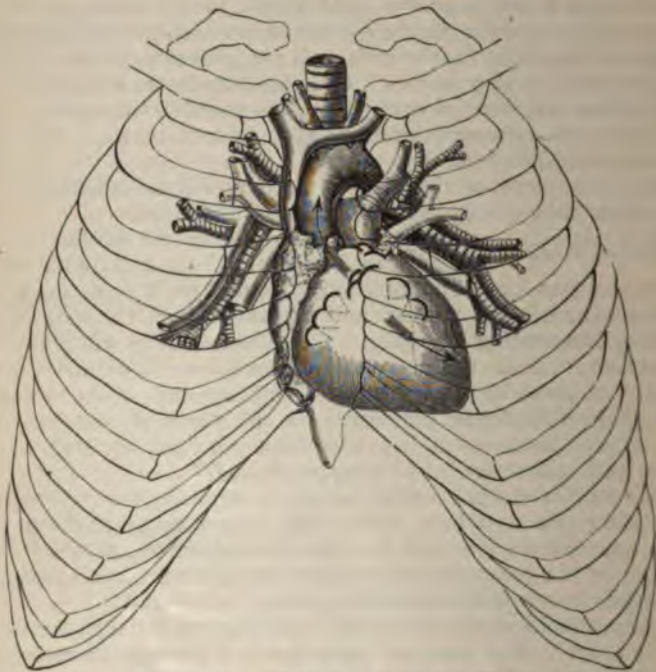


FIG. 65.—RELATIVE POSITION OF THE HEART AND ITS VALVES WITH REGARD TO THE WALLS OF THE CHEST.

The valves are denoted by curved lines. The *aortic valves* are opposite the third intercostal space on the left side, close to the sternum. The *pulmonary valves* are just above the aortic, opposite the junction of the third rib with the sternum. The *mitral valves* are opposite the third intercostal space, about one inch to the left of the sternum. The *tricuspid valves* lie behind the middle of the sternum, about the level of the fourth rib. *Aortic murmurs*, as shown by the arrow, are propagated up the aorta; *mitral murmurs*, as shown by the arrow, are propagated towards the apex of the heart.

Pericardium. The *pericardium* is the conical membranous bag which encloses the heart and the large vessels at its base. It is broadest *below*, where it is attached to the tendinous centre of the diaphragm, and to the muscular part in connection with the tendon, further to the left side than to the right; *above*, it is prolonged over the great vessels of the heart, about two

or three inches (5 to 7.5 cm.) from their origin, and is connected with the deep cervical fascia. *On each side*, it is in contact with the pleura,* the phrenic nerve running down between them. *In front* of it is the anterior mediastinum; *behind* it is the posterior. Of the objects in the posterior mediastinum, that which is nearest to the pericardium is the œsophagus and the left pneumogastric nerve. It should be remembered that the œsophagus is in close contact with the back of the pericardium and left auricle for nearly two inches (5 cm.); this fact accounts for what is sometimes observed in cases of pericarditis where there is much effusion: namely, pain and difficulty in swallowing.

The pericardium is a *fibro-serous* membrane and consists of two layers—an external or fibrous, and an internal or serous. Its *fibrous* layer, a dense membrane, constitutes its chief strength, and is attached, below, to the central tendon and the adjoining muscular part of the diaphragm. Above, it forms eight tubular sheaths for the great vessels at the base of the heart; namely, one for the vena cava superior, four for the pulmonary veins, two for the pulmonary arteries, and one for the aorta. The *serous* layer forms a shut sac. Its parietal layer lines the fibrous layer to which it is intimately attached, and is reflected over the great vessels and the heart to form its visceral layer. To see where the serous layer is reflected over the vessels, distend the pericardium with air. Thus you will find that this layer is reflected over the aorta as high as the commencement of the transverse portion of the arch of the aorta. It is reflected over the front and sides of the vena cava superior.

The serous layer of the pericardium covers the large vessels to an extent greater than is generally imagined; though the extent is not precisely similar in all bodies. The aorta and pulmonary artery are enclosed in a complete sheath, two inches (5 cm.) in length, so that these vessels are covered all round by the serous layer, except where they are in contact. Indeed, you can pass your finger behind them both, through a foramen bounded, in front, by the two great vessels themselves; behind, by the upper part of the auricles; and above, by the right pulmonary artery. Again, the back of the aorta, where it lies on the auricles, is covered by the serous pericardium. The superior cava is covered all round, except behind, where it crosses the right pulmonary artery. The inferior cava within the pericardium is partly covered in front. The left pulmonary veins are covered nearly all round; the right less so. Behind the auricles, chiefly the left, the serous layer extends upwards in the form of a pouch, rising above their upper border, so as to be loosely

* Some muscular fibres have been pointed out by Dr. W. S. Forbes in the newly-born, passing from the muscular fibres of the diaphragm to the base of the fibrous pericardium. (A. H.)

connected to the left bronchus. The object of these serous reflections is to facilitate the free action of the heart and the great vessels at its base.

In the healthy state the capacity of the pericardium nearly corresponds to the size of the heart when distended to its utmost. The healthy pericardium, with the heart *in situ*, may be made to hold, in the adult, about ten ounces of fluid (295.7 c.c.). The pericardium is not extensile. When an aneurism bursts into it, death is

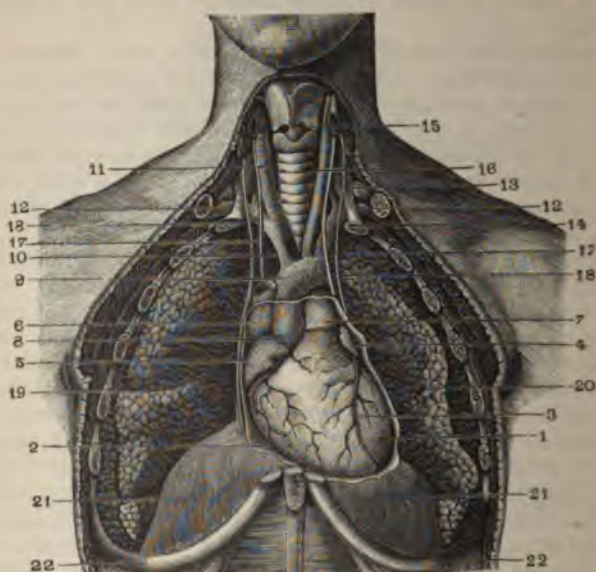


FIG. 66.—RELATION OF THE PERICARDIUM.

1. Left side of the heart. 2. Right side of the heart. 3. Coronary artery. 4. Left auricle. 5. Right auricle. 6. Superior vena cava. 7. Pulmonary artery. 8. Origin of the aorta. 9. Arch of the aorta. 10. Innominate artery. 11. Right common carotid artery. 12. Subclavian arteries. 13. Scalenus anticus muscle. 14. First rib. 15. Larynx. 16. Trachea. 17. Pæumogastric nerve. 18. Phrenic nerve. 19. Right lung. 20. Left lung. 21, 21. Diaphragm. 22, 22. Seventh rib.

caused, not by loss of blood, but by compression of the heart in consequence of the inextensibility of the pericardium.

The pericardium derives its blood from the internal mammary, bronchial, and œsophageal arteries; its nerve-supply from the phrenic nerves.

On separating the left pulmonary artery and pulmonary vein, you will notice a fold of serous membrane about three-quarters of an

inch (18 mm.) long and about one inch (2.5 cm.) in depth; this is the *vestigial fold of the pericardium*, described by Marshall.* It passes from the side of the left auricle, curving round the lower left pulmonary vein, to the left superior intercostal vein. It is a vestige of the left v. c. superior (duct of Cuvier) which exists in foetal life.

Open the pericardium, and observe that the heart is conical in form, and convex everywhere except upon its lower surface, which is flat, and rests upon the tendinous centre of the diaphragm. When the pericardium is thus laid open, the following objects are exposed, viz.: 1. Part of the right ventricle; 2. Part of the left ventricle; 3. Part of the right auricle with its appendix overlapping the root of the aorta; 4. The appendix of the left auricle overlapping the root of the pulmonary artery; 5. The aorta; 6. The pulmonary artery; 7. The vena cava superior; 8. The right and left coronary arteries (Fig. 66).

Position of the Heart.—Continued.

The heart, then, placed behind the lower half of the sternum, occupies more of the left than the right half of the chest, and rests upon the tendinous centre of the diaphragm, which is a little below the lowest part of the fifth rib. At each contraction the apex of the heart may be felt beating between the cartilages of the fifth and sixth ribs, about two inches (5 cm.) below the nipple and an inch (2.5 cm.) to its sternal side, or about three and a half inches (8.7 cm.) to the left of the middle of the sternum. Speaking broadly, the base corresponds with a line drawn across the sternum along the upper borders of the third costal cartilages. The right border of the heart is formed almost entirely by the free margin of the right auricle, and, when distended, bulges nearly an inch (2.5 cm.) to the right of the sternum. The left border of the heart is formed by the round border of the left ventricle, and reaches from a point, commencing at the second left intercostal space, to a point placed two inches (5 cm.) below the nipple and an inch (2.5 cm.) to its sternal side. The horizontal border is formed by the sharp margin of the right ventricle, and extends from the sternal attachment of the fifth right costal cartilage to meet the lowest point of the left margin.

The normal position which the cardiac valves hold to the thoracic walls is difficult to define with precision, and this probably accounts for the discrepancies noticed in anatomical works on this subject. The following relations are the results of carefully made observations in the post-mortem room: The *right*

* * * On the Development of the Great Anterior Veins in Man and Mammalia," *Philosoph. Transactions*, 1850.

auriculo-ventricular valves are situated behind the sternum on the level of the fourth costal cartilage; the *left auriculo-ventricular valves* are opposite the third intercostal space, about one inch (2.5 cm.) to the left of the sternum; the cusps of these valves extend as low as the fifth costal cartilage. The *pulmonary valves* lie immediately behind the junction of the third left costal cartilage with the sternum; the *aortic valves* are on a level with the upper border of the third intercostal space just at the left of the middle line of the sternum.*

The position of the heart varies a little with the position of the body. Of this anyone may convince himself by leaning alternately forwards and backwards, by lying on this side and on that, placing at the same time his hand upon the præcordial region. He will find that he can, in a slight degree, alter the place and the extent of the impulse of the heart. Inspiration and expiration also alter the position of the heart.

The student should now make out the large vessels in connection with the base of the heart, leaving the consideration of this organ to a later stage of the dissection.

Before we can display the brachio-cephalic veins, the layer of the deep cervical fascia must be removed, which descends over them from the neck and is lost upon the pericardium. Their coats are intimately connected with this fascia; and one of its functions appears to be to keep the veins permanently open for the free return of blood to the heart.

Brachio-cephalic Veins.

The *right* and *left brachio-cephalic* (innominate) veins are formed, near the sternal end of the clavicle, by the confluence of the internal jugular and subclavian veins. They differ in their course and relations, and must, therefore, be described separately.

The *left brachio-cephalic vein* passes from the left side obliquely behind the first bone of the sternum, the sterno-hyoid and thyroid muscles, the remains of the thymus gland, towards the right side, to form with the right innominate vein the vena cava superior (Fig. 67). It is about three inches (7.5 cm.) in length, and its direction inclines a little downwards. It is larger than the right brachio-cephalic, and crosses over the trachea and the origins of the three primary branches of the arch of the aorta. We are reminded of this fact in some cases of aneurism of these vessels—for what happens? The vein becomes compressed between the aneurism and the sternum; hence the swelling and venous congestion of the parts from which it returns its blood; namely, of the left arm, and the

* Anatomists differ much in the description they give of the relations of the valves to the thoracic walls; in fact no two agree in all the details.

left side of the neck. The upper border of the vein is not far from the upper border of the sternum: in some cases it lies even higher, and we have seen it crossing in front of the trachea fully an inch (2.5 *cm.*) above the sternum. This occasional deviation should be borne in mind in the performance of tracheotomy.

The *right brachio-cephalic vein* descends nearly vertically to join the superior vena cava, opposite the first right intercostal space. It is about an inch and a half (3.7 *cm.*) in length, and is situated about one inch (2.5 *cm.*) from the mesial line of the sternum. On its left side, but on a posterior plane, runs the arteria innominata; on its right side is the pleura (Fig. 66). Between the vein and the pleura is the phrenic nerve. The brachio-cephalic

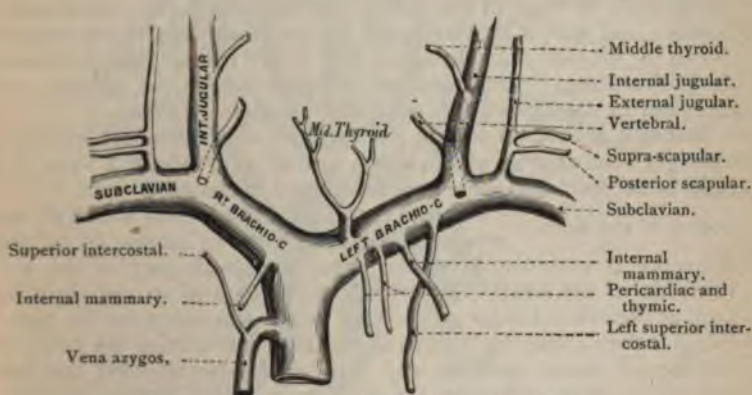


FIG. 67.—SUPERIOR VENA CAVA AND ITS TRIBUTARIES.

veins are not provided with valves. The veins which generally empty themselves into the right and left brachio-cephalic are as follow:—

The **RIGHT B.-C. Vein** receives—

- The vertebral.
- The internal mammary.
- The inferior thyroid.

The **LEFT B.-C. Vein** receives—

- The vertebral.
- The internal mammary.
- The inferior thyroid.
- The superior intercostal.
- The pericardiac.
- The thymic.

Opening into the point of junction of the internal jugular and subclavian veins, on the right side is the right lymphatic duct; on the left side is the thoracic duct.

Vena Cava Superior. This is the great vein through which the impure blood from the head, upper extremities, and chest returns into the right auricle. It is formed by the junction of the right and left brachio-cephalic veins, which unite at nearly a right angle opposite the upper part of the first intercostal space on the right border of the sternum; that is, about the level of the highest point of the arch of the aorta. The vena cava descends vertically, with a slight inclination backwards, to the upper and anterior part of the right auricle. It is from two and a half to three inches (6.2 to 7.5 cm.) long, and has no valves. The lower half of it is covered by the pericardium; you must, therefore, open this sac to see how the serous layer of the pericardium is reflected over the front and sides of the vein. In respect to its relations, notice that the vein lies in front of the right bronchus and the right pulmonary vessels; and that it is overlapped by the ascending aorta, which lies to its left side. In the upper half of its course, that is, above the pericardium, it is covered on its right side by the pleura; on this side, in contact with it, descends the phrenic nerve.

Before it is covered by the pericardium, the vena cava receives the right vena azygos, which opens into it after hooking over the right bronchus; also some pericardiac and mediastinal veins.

Course of the Aorta. The aorta is the great trunk from which all the arteries of the body carrying arterial blood are derived. It commences at the upper and back part of the left ventricle of the heart. It ascends forwards and to the right as high as the lower border of the first intercostal space on the right side; it then arches backwards towards the left side of the body of the second dorsal vertebra, and turning downwards over the left side of the third, completes the arch at the fifth dorsal vertebra. The aorta descends through the thorax on the left side of the bodies of the remaining dorsal vertebræ as far as the diaphragm; it enters the abdomen through the aortic opening of the diaphragm, and descends as far as the left side of the body of the fourth lumbar vertebra, where it bifurcates into the right and left common iliac arteries. The aorta has received different names in the various parts of its course; thus, the arched portion extending from its origin at the left ventricle to the fifth dorsal vertebra, is called the *arch of the aorta*; the portion between this vertebra and the diaphragm is the *descending thoracic aorta*; and the remainder of its course to its division at the fourth lumbar vertebra is known as the *abdominal aorta*.

**Course and Relations
of the Arch of the
Aorta.**

The arch of the aorta, as before stated, commences at the upper part of the left ventricle, and describes an arch which terminates at the fifth dorsal vertebra. Its origin is situated behind the pulmonary artery, and on the left side of the middle of

the sternum, about the level of the lower border of the third costal cartilage. The direction of the arch, therefore, is from the sternum to the spine and rather obliquely from right to left.

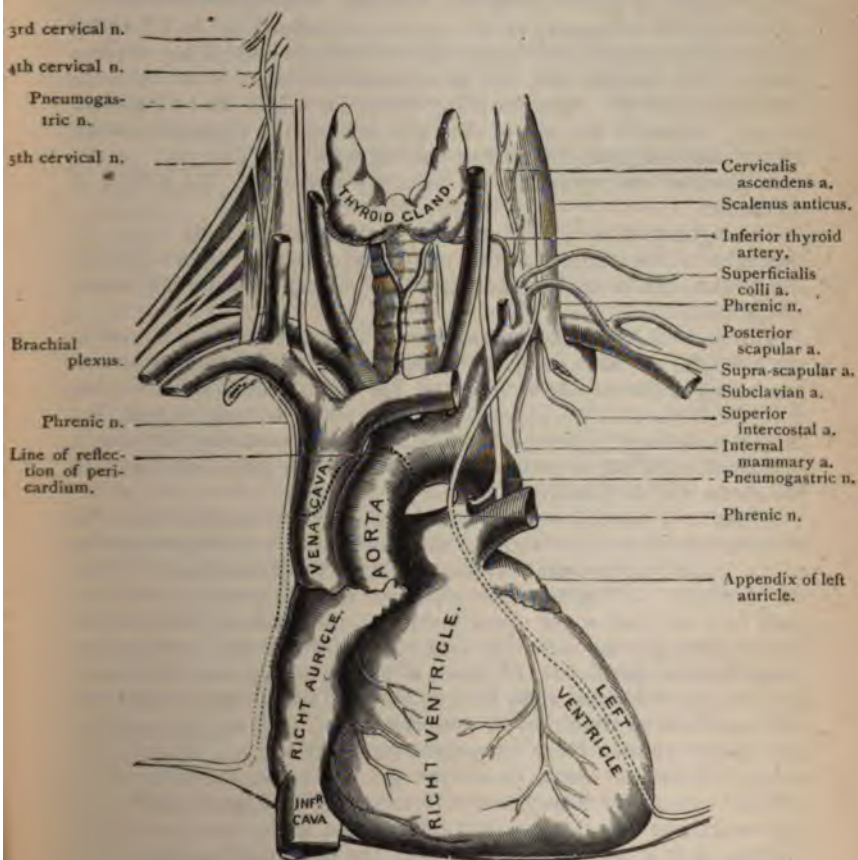


FIG. 68.

For convenience of description, the arch of the aorta is divided into an ascending, a transverse, and a descending portion.

Ascending Portion.—To see this portion of the aorta, the pericardium must be opened. You then observe that this part of the artery is enclosed all round by the serous layer of the pericardium,

except where it is in contact with the pulmonary artery. It is about two inches (*5 cm.*) in length, and ascends with a slight curve, the convexity looking forwards and to the right side, as far as the upper border of the second costal cartilage of the right side, where it lies almost in contact with the sternum. Its commencement is covered by the pulmonary artery, and is overlapped by the appendix of the right auricle, and higher up by the remains of the thymus gland. On its *right side*, but on a posterior plane, is the superior vena cava and the right auricle; on its *left side* is the pulmonary artery; *behind it* are part of the right auricle, the right pulmonary artery and vein, and the root of the right lung. This part of the arch gives off the right and left coronary arteries for the supply of the heart.

The right border of the ascending portion of the arch bulges to the right of the sternum to the extent of a quarter of an inch (*6 mm.*), and may be seen at the sternal end of the second right intercostal space.

The arch of the aorta presents partial dilatations in certain situations. One of these, called the *great sinus of the aorta*, is observed on the right side of the arch, about the junction of the ascending with the transverse portion; it is little marked in the infant, but increases with age. Three other dilatations (the *sinuses of Valsalva*), one corresponding to each of the valves at the commencement of the aorta, will be examined hereafter.

Transverse portion.—This portion of the aorta arches from the front to the back of the thorax, and extends from the upper border of the second right costal cartilage to the left side of the third dorsal vertebra. Its highest convex portion ascends usually to about an inch (*2.5 cm.*) below the upper border of the sternum, and its concavity corresponds with the articulation of the first and second bones of the sternum. *In front* it is covered by the left pleura and lung, and is crossed by the left phrenic, the left pneumogastric, the superficial cardiac nerves, the pericardiac, and the left superior intercostal veins. Near its *summit* runs the left brachio-cephalic vein. Within its *concavity* are the left bronchus, the bifurcation of the pulmonary artery, the left recurrent laryngeal nerve, and the remains of the ductus arteriosus. The artery *rests* upon the trachea (a little above its bifurcation), the deep cardiac plexus, the œsophagus, the thoracic duct, and the left recurrent laryngeal nerve. From the upper part of the transverse portion of the arch arise the arteria innominata, the left carotid, and the left subclavian arteries; and lying in front of these arteries is the left-brachio-cephalic vein.

Descending portion.—This part of the arch lies upon the left side of the body of the fourth dorsal vertebra, and at the lower

border of the body of the fourth, or the upper part of the fifth, dorsal it takes the name of the descending thoracic aorta. On its *right side* are the œsophagus and thoracic duct; on its *left* is the pleura; *in front* are the pleura and the root of the left lung; *behind*, it lies on the anterior common ligament, corresponding to the fourth dorsal vertebra.

What parts are contained within the arch of the aorta?—The left bronchus, the right pulmonary artery, the left recurrent nerve, the remains of the ductus arteriosus, and the superficial cardiac plexus of nerves.

**Relations of the Arch
of the Aorta to the
Sternum.**

These relations vary according to the size of the heart, the obliquity of the ribs, and the general development of the chest. In a well-formed adult the ascending aorta is, at the most prominent part of its bulge, about half an inch (*12.5 mm.*) behind the first bone of the sternum. The highest part of the arch is about one inch (*2.5 cm.*) below the upper edge of the sternum.*

The branches given off from the ascending portion of the arch are the right and left coronary arteries, which pass, one in front of, and the other behind, the heart to supply its muscular tissue.

The *right coronary artery* arises from the anterior sinus of Valsalva, and passes to the right between the pulmonary artery and the right auricular appendix, running in the auriculo-ventricular groove.

The *left coronary artery*, larger than the preceding, is given off from the left posterior sinus of Valsalva, and passes between the pulmonary artery and left auricular appendix; it runs down in the anterior interventricular sulcus towards the apex of the heart.

The further description of these vessels will be considered in the dissection of the heart.

From the highest part of the arch arise three large arteries for the head, neck, and upper limbs; namely, the brachio-cephalic or innominate artery, the left carotid, and the left subclavian.

**Brachio-cephalic or
Innominate Artery.** This, the largest of the three, arises from the commencement of the transverse part of the arch. It ascends obliquely towards the right, and, after a course of about one inch and a half to two inches,

* The relations of the arch of the aorta to the sternum vary even in adults, more especially if there be any hypertrophy of the heart. As an instance among many, we may mention that of a young female who died of phthisis. The position of the aortic valves was opposite the middle of the sternum, on a level with the middle of the second costal articulation. The highest part of the arch was on a level with the upper border of the sternum; the arteria innominata was situated entirely in front of the trachea; and the left brachio-cephalic vein crossed the trachea so much above the sternum that it would have been directly exposed to injury in tracheotomy.

divides behind the right sterno-clavicular joint into two arteries of nearly equal size—the right subclavian and the right common carotid.

The relations of the innominate artery are as follow: *In front* it has the manubrium sterni, the right sterno-clavicular joint, the origins of the sterno-hyoid and thyroid muscles, the remains of the thymus gland, the left brachio-cephalic vein, the right inferior thyroid vein, and the right inferior cervical cardiac branch of the pneumogastric nerve. *Behind*, it rests upon the trachea. On its *left side* are the left common carotid and the remains of the thymus. On its *right side* are the lung and pleura, the right brachio-cephalic vein, and the pneumogastric nerve.

With the anatomy of the parts before you, you can understand that an aneurism of the innominate artery might be distinguished from an aneurism of the aorta—1. By a pulsation in the neck between the sterno-mastoid muscles, *i. e.*, in the fossa above the sternum; 2. By occasional dyspnoea owing to pressure on the trachea; 3. By venous congestion in the *left arm*; 4. By the aneurismal thrill being confined to the *right arm*.*

**Left Common
Carotid Artery.**

This artery arises from the arch of the aorta, close to, and to the left of, the arteria innominata. It ascends obliquely to the left sterno-clavicular joint, and thence to the neck, where its course nearly corresponds with the right common carotid (p. 98). *In front* it has the sternum, the left sterno-hyoid and thyroid muscles, the left brachio-cephalic vein, and the remains of the thymus gland; *behind*, it has at first the trachea, and higher up the œsophagus and thoracic duct; to the *right side* is the innominate artery; to the *left side* are the left subclavian artery and left pneumogastric nerve.

**Left Subclavian
Artery.**

This is the third branch of the transverse part of the arch, and arises from it opposite the third dorsal vertebra. It ascends nearly vertically out of the chest to the inner border of the first rib, and then curves outwards behind the scalenus anticus. *In front* it has the lung covered with pleura, the pneumogastric, phrenic, and cardiac nerves, the left common carotid, the left internal jugular, and the left innominate veins, the sterno-hyoid, sterno-thyroid, and sterno-

* If the innominate artery be ligatured, the circulation would be maintained by the following collateral branches: 1. Between the branches of the two external carotids, which anastomose across the middle line. 2. Between the aortic intercostal and the superior intercostal. 3. Between the aortic intercostals and the internal mammary, long thoracic, alar thoracic, and subscapular arteries. 4. Between the internal mammary and deep epigastric. 5. Between the inferior thyroid arteries. 6. Between the two vertebrals. 7. Between the two internal carotides.

mastoid muscles. To its *right side* are the left carotid, œsophagus, and trachea; between the artery and the œsophagus is the thoracic duct; to its *left side* is the lung covered with pleura; *behind it* are the longus colli muscle covering the vertebræ, the œsophagus, thoracic duct, and the inferior cervical ganglion of the sympathetic. The upper part of its course, where the vessel passes in front of the apex of the lung, has been described with the anatomy of the neck (p. 130).

Course of the Phrenic Nerves through the Chest.

The *phrenic nerve* comes from the third, fourth, and fifth cervical nerves, but chiefly from the fourth. It descends on the scalenus anticus, gradually inclining to its inner border, and enters the chest between the subclavian vein and artery. It then crosses over the internal mammary artery and runs in front of the root of the lung, between the pleura and the pericardium to the diaphragm (Fig. 68), to the under surface of which it is distributed.

The phrenic nerve is joined on the scalenus anticus by an offset from the fifth cervical branch of the brachial plexus; by another filament from the sympathetic nerve; and very frequently by a small loop from the nerve to the subclavian muscle; occasionally also by a branch from the descendens noni.

In what respects do the phrenic nerves differ from each other in their course? The right phrenic runs along the outer side of the brachio-cephalic vein and superior vena cava; the left crosses in front of the transverse part of the arch of the aorta; besides which, the left is rather longer than the right, since it curves over the apex of the heart.

Before the phrenic nerve divides into branches to supply the diaphragm, it sends off minute filaments to the pleura and the pericardium; after it has pierced the diaphragm it distributes branches to the peritoneum. The *right* phrenic gives off one or two filaments, which unite with some filaments from the solar plexus and form a small ganglion, from which branches are distributed to the supra-renal capsule, the hepatic plexus, and the inferior vena cava. The *left* phrenic gives off a branch which joins a twig from the sympathetic near the œsophageal opening of the diaphragm, but there is no appearance of a ganglion.

Having studied these anatomical details, consider for a moment what symptoms are likely to be produced by an aneurism of the arch of the aorta, or any of the primary branches. A glance at the important parts in the neighbourhood helps to answer the question. The effects will vary according to the part of the artery which is the seat of the aneurism, and according to the size, the form, and the position of the tumour. One can understand that compression of the vena cava superior, or either of the brachio-cephalic veins, would occasion congestion and œdema of the parts from which they return the blood; that compression of the trachea or one of the bronchi might occasion dyspnoea, and thus simulate disease

of the larynx; * that compression of the œsophagus would give rise to symptoms of obstruction. Nor must we forget the immediate vicinity of the thoracic duct and the recurrent nerve, † and the effects which would be produced by their compression. Can one, then, be surprised that a disease which may give rise to so many different symptoms should be a fertile source of fallacy in diagnosis?

Thus you can understand how aneurisms of the aorta may prove fatal by bursting into the contiguous tubes or cavities; for instance, into the trachea, the œsophagus, the pleura, or the pericardium. You will see, too, why an aneurism of the first part of the arch is so much more dangerous than elsewhere. The reason is, that in this part of its course the aorta is covered only by a thin layer of serous membrane. If an aneurism takes place here, the coats of the vessel soon become distended, give way, and allow the blood to escape into the pericardium—an occurrence which is speedily fatal, because, the pericardium being filled with blood, the heart is prevented from acting.

Posterior Mediastinum and its Contents.

The posterior mediastinum (p. 174) is formed by the reflection of the pleural sac on each side, from the root of the lung to the sides of the bodies of the dorsal vertebræ. It is bounded in front by the pericardium and the roots of the lungs. To obtain a view of it, cut away the ribs nearly as far as their angles, draw out the right lung towards the left side, and fasten it firmly to the left side of the thorax. Remove the pleura of the right side from the ribs, and the posterior aspect of the root of the right lung, and then by a little careful dissection the space and the structures contained in it will be displayed. This mediastinum contains the descending thoracic aorta with some of the right aortic intercostal arteries; in front of the aorta, the œsophagus, with the pneumogastric nerves, the left in front and the right behind; on the right of the aorta is the vena azygos major, between this vein and the aorta is the thoracic duct; superiorly is the trachea; inferiorly are the splanchnic nerves and some lymphatic glands. To expose these last we must remove the pleura and a layer of dense fascia which lines the chest outside it.

Descending Thoracic Aorta.

We have already traced the arch of the aorta to the body of the fifth dorsal vertebra (p. 187). From this point the aorta descends on the left side of the spine, gradually approaching towards the middle line. The artery, moreover, following the dorsal spinal curve, is not vertical, but concave forwards. Opposite the last dorsal vertebra it passes between the crura of the diaphragm and enters the abdomen. It is contained in the posterior mediastinum; on its *left side* it is covered with pleura enclosing the left lung, and below it has the

* In the Museum of Guy's Hospital there is a preparation, No. 1,487, in which laryngotomy was performed under the circumstances described in the text.

† See *Med. Gaz.*, Dec. 22, 1843: a case in which loss of voice was produced by the pressure of an aneurismal tumour upon the left recurrent nerve.

oesophagus to the left; on its *right* run the vena azygos, the oesophagus, and thoracic duct; *in front* of it are the root of the left lung and the pericardium. Lower down the oesophagus is in front of the artery, and subsequently lies a little to its left side; *behind* are the vertebral column and the vena azygos minor. Its branches will be described presently.

Vena Azygos Major. This vein commences in the abdomen opposite the first or second lumbar vertebra, by small branches from one of the lumbar veins of the right side, and generally communicates with the renal, or the vena cava itself. This, indeed, is the main point about the origin of the vena azygos, that it communicates directly or indirectly with the vena cava inferior. It enters the chest through the aortic opening of the diaphragm, and ascends on the right side of the aorta through the posterior mediastinum, in front of the bodies of the lower dorsal vertebræ, and over the right intercostal arteries. When the vein reaches the level of the third dorsal vertebra it arches forwards over the right bronchus, and terminates in the superior vena cava, just before this vessel is covered by pericardium. In its course it receives nine or ten of the lower intercostal veins of the right side, the spinal veins, the posterior mediastinal, the oesophageal, and the right bronchial veins. Opposite the sixth or seventh dorsal vertebra it is joined by the left vena azygos. It is occasionally connected with the right superior intercostal vein.

The left vena azygos, *vena azygos minor*, runs up the *left* side of the spine. This vein commences in the abdomen from one of the lumbar veins of the left side, or from the left renal. It then ascends

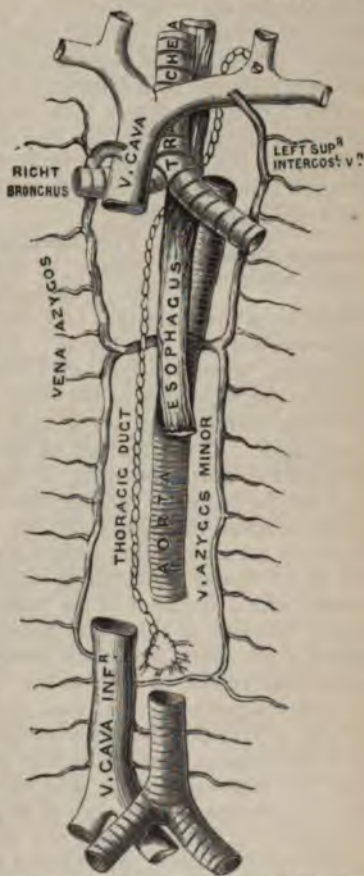


FIG. 69.—DIAGRAM TO SHOW THE COURSE OF THE VENA AZYGOS AND THE THORACIC DUCT.

on the left side of the aorta, through the left crus of the diaphragm. On a level with the sixth or seventh dorsal vertebra it passes beneath the aorta and thoracic duct to join the azygos major. Before passing beneath the aorta it usually communicates with the left superior intercostal vein. It generally receives six or seven of the lower intercostal veins of the left side, the œsophageal and mediastinal veins. These azygos veins are provided with imperfect valves, and are supplemental to the inferior vena cava.

The *left upper azygos vein* receives the intercostal vein of the left side, usually from the fourth to the sixth; it communicates above with the left superior intercostal vein, and opens below, either directly into the vena azygos major, or indirectly into it through the vena azygos minor.

Thoracic Duct and Receptaculum Chyli. The *thoracic duct* (Fig. 69) is a canal, from fifteen to eighteen inches (37.5 to 45 cm.) long, through which the contents of the lacteal vessels from the intestines and the lymphatics from the lower limbs are conveyed into the blood. These vessels converge to an oval dilatation, termed *receptaculum chyli* (cistern of Pecquet), situated a little to the right side of the front of the body of the second lumbar vertebra, behind the aorta and close to the right crus of the diaphragm. Then, getting to the right side of the aorta, it ascends through the aortic opening of the diaphragm into the chest, and runs up the posterior mediastinum, still along the right side of the aorta, between this vessel and the vena azygos major, and opposite the sixth dorsal vertebra crosses over the vena azygos minor. Near the *third* dorsal vertebra it inclines to the left side, and then passes behind the arch of the aorta and the œsophagus, and ascends on the left side of this tube, between it and the left pleura; subsequently the duct passes up between the œsophagus and the left subclavian artery, as high as the seventh cervical vertebra, resting on the longus colli. It then emerges from beneath the carotid sheath, curves downwards over the subclavian artery, in front of the scalenus anticus, and opens into the back part of the confluence of the left internal jugular and subclavian veins. The orifice of the duct is guarded by two valves which permit fluid to pass from the duct into the vein, but not *vice versâ*. Valves, disposed like those in the venous system, are placed at short intervals along the duct, more numerous in its upper part, so that its contents can only pass upwards.* The diameter of the duct varies in different parts

* The thoracic duct varies in size in different individuals. It may divide in its course into two branches, which subsequently reunite; instead of one there may be several terminal orifices. Instances have been observed in which the duct has terminated on the right instead of the left side (Fleischmann, *Leichenöffnungen*, 1815; also Morrison, *Journal of Anat.*, vol. vi, p. 427). It has been seen to terminate in the vena azygos (Müller's *Archiv*, 1834).

of its course ; at its commencement it is about one-fourth of an inch (*6 mm.*) in diameter, at the sixth dorsal it is about one-sixth of an inch (*4 mm.*), and it enlarges again towards the termination. It receives the lymphatics from the lower extremities, and from all the abdominal viscera (except the convex surface of the liver and the abdominal walls) ; above these it receives the lymphatics from the left side of the thorax, the left lung, the left side of the heart, the left upper extremity, and the left side of the head and neck.

Œsophagus. The *œsophagus* is that part of the alimentary canal which conveys the food from the pharynx to the stomach. It commences at the lower border of the fifth cervical vertebra, at the back of the cricoid cartilage ; runs down in front of the spine, to the right side of the transverse portion of the arch of the aorta, then through the posterior mediastinum in front of the descending aorta, and passes through the œsophageal opening in the diaphragm to end in the stomach, opposite the ninth dorsal vertebra. It is from nine to ten inches (*22.5 to 25 cm.*) long. Its course is not exactly straight, for it describes three curves—one an antero-posterior, the other two lateral curves. In the neck at its commencement it lies at first in the middle line ; it then gets behind, and a little to the left of the trachea ; in the chest, *i.e.* about the fourth dorsal vertebra, it inclines towards the right side to make way for the aorta ; but it again inclines to the left before it passes through the diaphragm. Its antero-posterior curve corresponds to the curve of the spinal column.

The œsophagus, in the neck, rests *behind*, upon the front of the spine covered by the longus colli muscle ; in *front* it has the trachea ; on *each side* it is in relation with the thyroid body, the common carotid (chiefly the left), and inferior thyroid arteries, and the recurrent laryngeal nerves ; to the *left* of it is the thoracic duct.

In the thorax, the œsophagus has, *in front*, the trachea, the left bronchus, the arch of the aorta, the left carotid, and left subclavian arteries ; and, lastly, for about two inches (*5 cm.*), the posterior surface of the pericardium (behind the left auricle) ; this accounts for the pain which is sometimes experienced, in cases of pericarditis, during the passage of food ; *behind*, it rests upon the spinal column, the longus colli, the thoracic duct, the third, fourth, and fifth intercostal arteries of the right side ; and, lastly, it lies in front of and slightly to the left side of the aorta ; *laterally*, the aorta and pleura are to the *left*, and the vena azygos major to the *right* of the tube. As it passes down in the interpleural space, it is in connection with both pleuræ. The œsophagus is surrounded by a plexus of nerves formed by the pneumogastric nerves, the left being in front of, the right behind it.

The œsophagus is supplied with blood by the inferior thyroid, the œsophageal branches of the aorta, the coronaria ventriculi, and the left phrenic artery. It is supplied with nerves by the pneumogastric and the sympathetic, which ramify between the two muscular layers. The œsophagus is composed of three coats, an external or muscular, a middle or areolar, and an internal or mucous. The muscular coat consists of an outer longitudinal, and an inner circular layer of fibres. The longitudinal layer is particularly strong, and arranged in the upper part mainly in three fasciculi, an anterior attached to the vertical ridge on the cricoid cartilage, and two lateral, which are continuous with the inferior constrictor; these, lower down, spread out and form a continuous layer round the œsophagus and support the circular fibres. Under the microscope the muscular fibres composing the upper part are seen to consist entirely of the striped variety; at the lower part, almost exclusively of the non-striped variety. The middle coat is composed of areolar tissue, and connects very loosely the muscular and mucous coats, thereby allowing the mucous membrane to move very freely in its muscular envelope. The mucous membrane is of a pale colour and considerable thickness, and in the contracted state of the œsophagus is arranged in longitudinal folds within the tube, which lies flattened in front of the spine. On the surface of the mucous membrane there are numerous minute papillæ placed obliquely. It is lined by a very thick layer of scaly epithelium. In the submucous tissue are many small compound racemose glands—*œsophageal glands*—especially towards the lower end of the œsophagus.

**Course and
Branches of the
Pneumogastric
Nerves.**

The course of the pneumogastric nerves in the chest is not the same on both sides. The *right* pneumogastric nerve enters the chest between the subclavian artery and vein, descends behind the right innominate vein by the side of the trachea to the back of the root of the lung, where it breaks up into a plexus forming the posterior pulmonary plexus. From this plexus two cords descend to the posterior surface of the œsophagus, upon which they divide into numerous branches; forming, with corresponding branches of the left pneumogastric nerve, the œsophageal plexus (*plexus gulæ*). The plexus then reunites into a single trunk, consisting also of some fibres from the left pneumogastric, and passes into the abdomen through the œsophageal opening in the diaphragm. The *left* pneumogastric descends into the chest between the left subclavian and carotid arteries, and behind the left brachio-cephalic vein. It then crosses in front of the arch of the aorta, and passes behind the root of the left lung to the anterior surface of the œsophagus, upon which it also assists to form a plexus with the

nerve of the right side. The branches of the pneumogastric nerve in the chest are as follow:—

a. The inferior laryngeal or recurrent.—This nerve on the right side turns under the subclavian and the common carotid arteries (Fig. 68); on the left, under the arch of the aorta, below the ductus arteriosus, and ascends to the larynx. It passes beneath the inferior thyroid artery, and lying in the groove between the trachea and œsophagus, it enters the larynx beneath the lower border of the inferior constrictor of the pharynx. It supplies with motor nerves all the muscles which act upon the rima glottidis, except the crico-thyroid (supplied by the external laryngeal nerve). As they turn beneath their respective arteries, they give off branches to the deep cardiac plexus; also some small filaments to the inferior cervical ganglion of the sympathetic. In the neck it distributes small branches to the trachea, œsophagus, and inferior constrictor muscle.

b. Cardiac branches.—These are very small, and join the cardiac plexuses (Fig. 59, p. 161); the right arise from the right pneumogastric, and the right recurrent laryngeal, close to the trachea; the left come from the left recurrent laryngeal nerve. On both sides these branches pass to the deep cardiac plexus.

c. Pulmonary branches.—These accompany the bronchial tubes. The greater number run behind the root of the lung and constitute the *posterior* pulmonary plexus. A few, forming the *anterior* pulmonary plexus, supply the front part of the root of the lung. Both these plexuses are joined by filaments from the second, third, and fourth thoracic ganglia of the sympathetic. The nerves of the lungs are, however, very small, and cannot be traced far into their substance.*

d. Œsophageal plexus.—Below the root of the lung each pneumogastric nerve is subdivided so as to form an interlacement of nerves round the œsophagus (plexus gulæ). From this plexus numerous filaments supply the coats of the tube; but the majority of them are collected into two nerves—the one, chiefly the continuation of the left pneumogastric nerve, lying in front of the œsophagus; the other, chiefly that of the right, lying behind it. Both nerves pass through the œsophageal opening in the diaphragm for the supply of the stomach, the left also sending filaments to join the hepatic plexus; the right sending branches to the cœliac, splenic, and left renal plexuses.

Having examined the contents of the posterior mediastinum from the right side, now do so from the left. The left lung should be turned out of its cavity and fastened by hooks towards the right side. After removing the pleura, we see the descending thoracic aorta, the pneumogastric nerve crossing the arch and sending the recurrent branch under it; also the first part of the left subclavian, covered externally by the pleura. The pneumogastric nerve must be traced behind the root of the left lung to the œsophagus, and the œsophageal plexus of this side dissected. Lastly, notice the lesser vena azygos, which crosses under the aorta about the sixth or seventh dorsal vertebra to join the vena azygos major.

Thoracic Portion of
the Sympathetic.

This portion of the sympathetic system is generally composed of twelve ganglia covered by the pleura, one ganglion being found over the head of each rib, except the last two, which lie on the side of

* Upon this subject, see the beautiful plates of Scarpa.

the bodies of the vertebræ. Often there are only ten ganglia, in consequence of two of them being fused here and there. The first thoracic ganglion is the largest.

The ganglia are connected together by thick branches, and each

ganglion is connected *externally* by two branches with the corresponding intercostal nerves. The nerves proceeding from the ganglia pass inwards to supply the thoracic and part of the abdominal viscera. The *internal* branches which proceed from the six upper ganglia are small, and are distributed as follows (Fig. 70):—

a. Minute nerves from the first and second ganglia to the deep *cardiac plexus*.

b. Minute nerves from the third and fourth ganglia to the *posterior pulmonary plexus*.

The branches arising from the six lower ganglia unite to form three nerves—the *great splanchnic*, the *lesser*, and the *smallest splanchnic nerves*.

a. The *great splanchnic* nerve is generally formed by branches from the fifth or sixth to the tenth ganglion, and also receiving filaments, according to Beck, from all the thoracic ganglia above the sixth. They descend obliquely by the sides of the bodies of the dorsal vertebræ, along the posterior mediastinum, and unite into a single nerve, which passes through the corresponding crus of the diaphragm, and joins the semi-lunar ganglion of the abdomen, sending also branches to the renal and supra-renal plexuses.

b. The *lesser splanchnic* nerve is commonly formed by branches from the tenth



FIG. 70.—DIAGRAM OF THE THORACIC PORTION OF THE SYMPATHETIC.

and eleventh ganglia. It passes through the crus of the diaphragm to the coeliac plexus, and occasionally to the renal plexus.*

c. The *smallest splanchnic* nerve comes from the twelfth ganglion, passes through the crus of the diaphragm, and terminates in the lower part of the coeliac and renal plexuses. (This is not represented in the diagram.)

* In a few instances we have traced a minute filament from one of the ganglia into the body of a vertebra. According to Cruveilhier each vertebra receives one

Intercostal Muscles. The intercostal muscles fill in the intervals between the ribs and are arranged in each interval in two layers, an external and an internal, which cross each other like the letter X. The *external intercostals*, eleven on each side, run obliquely from behind forwards, like the external oblique muscle of the abdomen. They connect the contiguous borders of the ribs, passing from the outer lip of the rib above to the upper border of the rib below; they extend from the tubercles of the ribs behind to the costal cartilages in front, and are continued forwards to the sternum as a thin membrane. The *internal* run from before backwards like the internal oblique, and pass from the inner lip of the groove in the rib above and from the costal cartilage, and are inserted into the upper border of the rib below. Observe that a few fibres of the inner layer pass over one or even two ribs, chiefly near the angles (especially of the lower ribs), and terminate upon a rib lower down.*

Neither of these layers of intercostal muscles extends all the way between the sternum and the spine; the outer layer, beginning at the spine, ceases at the cartilages of the ribs; the inner, commencing at the sternum, ceases at the angles of the ribs.

The intercostal muscles present an intermixture of tendinous and fleshy fibres; and they are covered inside and outside the chest by a glistening fascia, to give greater protection to the intercostal spaces.

The external intercostal muscles elevate the ribs, and are therefore muscles of inspiration. The internal intercostal muscles depress the ribs, and are therefore muscles of expiration.

Intercostal Arteries. There are eleven intercostal arteries on each side which lie between the internal and external intercostal muscles. The *two upper* arteries are derived from the superior intercostal branch of the subclavian; the remaining *nine* are furnished by the thoracic aorta; and since this vessel lies rather on the left side of the spine, the right intercostal arteries are longer than the left. The upper intercostal arteries from the aorta ascend obliquely to reach their intercostal spaces; the lower run more transversely. They are given off from the back of the descending aorta, and as they pass outwards across the bodies of the vertebræ they are covered by the pleura and the sympathetic nerves; the right, in addition, pass behind the œsophagus, thoracic duct, and the vena azygos major; the left behind the left superior intercostal vein and the vena azygos minor. Having reached the intercostal space, each artery divides into an *anterior* and a *posterior* branch. The *anterior* branch in direction and size

* These irregular muscular bundles are called the *subcostal muscles*.

appears to be the continuation of the common trunk. At first it runs *along the middle of the intercostal space*, lying upon the external intercostal muscle, and separated from the cavity of the chest by the pleura and intercostal fascia. Here, therefore, it is liable to be injured by a wound in the back. But near the angle of the rib it passes between the intercostal muscles, and occupies the groove in the lower border of the rib above. Here it gives off a small branch, the *collateral intercostal*, which runs for some distance along the upper border of the rib below. After supplying the muscles, the main trunk anastomoses with the anterior intercostal branch of the internal mammary artery. In some cases this branch is as large as the intercostal itself, and situated so as to be directly exposed to injury in the operation of tapping the chest.

In its course along the intercostal space, each artery sends branches to the intercostal muscles and the ribs. About midway between the sternum and the spine, each gives off a small branch, which accompanies the lateral cutaneous branch of the intercostal nerve. The continued trunk, gradually decreasing in size, becomes very small towards the anterior part of the space, and is placed more in the middle of it. Those of the true intercostal spaces inosculate with branches of the internal mammary and thoracic branches of the axillary; those of the false run between the layers of the abdominal muscles, and anastomose with the epigastric and lumbar arteries.

The *posterior* or *dorsal* branch passes backwards between the transverse processes of the vertebræ, on the inner side of the anterior costo-transverse ligament, and is distributed to the muscles and skin of the back. Each sends an artery through the intervertebral foramen to the spinal cord and its membranes.

On the right side the intercostal veins terminate in the vena azygos major; on the left, the seven or eight lower terminate in the vena azygos minor, the remainder in the left superior intercostal vein.

The usual relation which the intercostal vessels and nerve bear to each other in the intercostal space, is, that the *vein lies uppermost, the nerve lowest, and the artery between them.*

Dorsal Nerves.

The *dorsal nerves* are twelve in number, the first emerging between the first and second dorsal vertebræ, and do not form a plexus as in the cervical, lumbar, and sacral regions. Each dorsal nerve (like all the spinal nerves) arises from the spinal cord by two roots, an anterior or motor, and a posterior or sensory. The sensory root has a ganglion upon it. The two roots unite in the intervertebral foramen and form a *compound* nerve. After passing through the foramen, it is

connected by two filaments with the sympathetic nerve, and then divides into an *anterior* and a *posterior* branch. The *posterior* or *dorsal* branches pass backwards between the transverse processes of the dorsal vertebræ and divide into internal and external branches; the *internal* branches pass between the multifidus spinæ and semispinalis dorsi, pierce the rhomboidei and trapezius muscles; the six upper branches become cutaneous at the spinous processes of the vertebræ; the six lower supply only the multifidus spinæ, not giving off any cutaneous filaments; the *external* branches pass through the longissimus dorsi and supply this muscle, the ilio-costalis and their continuations and the levatores costarum; the six lower branches, in addition, distribute cutaneous filaments to the skin. These branches will be described more fully later on in the dissection of the back.

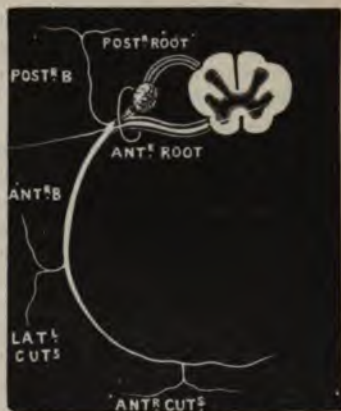


FIG. 71.—DIAGRAM OF A SPINAL NERVE.

Intercostal Nerves. The *intercostal nerves* are the *anterior* divisions of the dorsal nerves, and are twelve in number. Each nerve receives a filament from the sympathetic, and then proceeds between the intercostal muscles in company with, and immediately below, the corresponding artery. Midway between the spine and sternum, they give off *lateral cutaneous branches*, which supply the skin over the scapula and the thorax. The intercostal nerves terminate in front in the *anterior cutaneous nerves*. In the anterior part of the intercostal space the nerves lie in the substance of the internal intercostal muscles, and at the costal cartilages get to the inner side of the muscles, passing between them and the pleura.

The intercostal nerves are divided into two sets: the six upper are called the pectoral intercostals, because they supply the structures of the pectoral region; the six lower, the abdominal intercostals, because they supply the chest and abdominal walls.

The *upper* or *pectoral intercostal nerves* pass between the external and internal intercostal muscles, run forwards in the substance of the latter muscle, and at the sternal end of the intercostal spaces pierce the internal intercostal muscles and the pectoralis major, to be ultimately distributed to the skin of the chest. The upper inter-

costal nerves supply the levatores costarum, serratus posticus superior, the intercostals, and the triangularis sterni.

The *lower or abdominal intercostal nerves* pass like the upper nerves between the intercostal muscles as far forwards as the costal cartilages. They pass behind these, and then run between the transversalis and internal oblique, as far as the outer border of the rectus. Piercing the sheath of the muscle, they supply it, and subsequently end as the anterior cutaneous nerves of the abdomen. They supply the intercostal muscles, the serratus posticus inferior, and the abdominal parietal muscles.

Notice that the first dorsal nerve ascends nearly perpendicularly over the neck of the first rib to form part of the brachial plexus. This nerve, however, gives off a small branch, the first intercostal nerve, to supply the first intercostal space. This, as a rule, has no lateral cutaneous branch.

Intercostal lymphatic glands.—These are situated near the heads of the ribs; there are some between the layers of the intercostal muscles. They are of small size, and their efferent vessels go into the thoracic duct. Some of the upper ones on the right side pass into the right lymphatic duct. We have seen these intercostal glands enlarged and diseased in phthisis.

**Bronchial and
Œsophageal
Arteries.**

Small *bronchial arteries*, arising on the right side most frequently from the first aortic intercostal (third intercostal) artery, and on the left from the thoracic aorta, accompany the bronchial tube on its posterior aspect into the substance of the lung.* Their distribution and office will be considered with the anatomy of the lung. *Œsophageal arteries*, four or five in number, proceed from the front of the thoracic aorta to ramify on the œsophagus, where they inosculate above with the œsophageal branches of the inferior thyroid, and below with the œsophageal branches of the coronaria ventriculi and phrenic arteries. Small *posterior mediastinal arteries* are given off from the posterior part of the aorta, and supply the lymphatic glands and tissues of the posterior mediastinum.

Having finished the posterior mediastinum, replace the lung, and turn your attention once more to the great vessels at the root of the heart.

Pulmonary Artery. This vessel is about two inches (5 cm.) in length, and conveys the venous blood from the heart to the lungs. It proceeds from the upper part of the base of the right ventricle, and passes upwards and backwards along the

* On the left side there are usually two bronchial arteries—a superior, arising from the highest part of the thoracic aorta, and an inferior, arising about an inch (2.5 cm.) lower down.

left side of the aorta to the concavity of the arch of the aorta, where it divides into two branches, a right and a left, one for each lung. At its origin it has on each side an auricular appendix and a coronary artery, and lies in front of the root of the aorta. The pulmonary artery and the aorta are surrounded for two inches (5 cm.) by a common sheath of pericardium. The right branch, the larger and longer, passes horizontally below the arch of the aorta, behind the ascending aorta and the superior vena cava, to the root of its lung; the left is easily followed to its lung by removing the layer of pericardium investing it, when it will be found to pass horizontally in front of the descending aorta and the left bronchus to the root of the left lung.

Search should be made for a short fibrous cord which connects the commencement of the left pulmonary artery with the concavity of the arch of the aorta. This cord is the remains of the *ductus arteriosus*, a canal which in foetal life conveyed blood from the pulmonary artery to the aorta.

Draw towards the left side the first part of the arch of the aorta, and dissect the pericardium from the great vessels at the base of the heart. Thus a good view will be obtained of the trachea and its bifurcation into the two bronchi. Below the division of the trachea the right pulmonary artery is seen passing in front of the right bronchus. The superior vena cava and aorta are seen in front of, and nearly at right angles to, the right pulmonary artery. The vena azygos major is seen arching over the right bronchus and terminating in the vena cava superior, just before this vein pierces the pericardium. Notice, especially, a number of lymphatic glands called *bronchial*, at the angle of bifurcation of the trachea. The situation of these glands in the midst of so many tubes explains the variety of symptoms which may be produced by their enlargement.

Nerves of the Heart and Cardiac Plexuses. The nerves of the heart come from the pneumogastric and its recurrent branch, and the three cervical ganglia of the sympathetic. The pneumogastric gives off (generally) two or more filaments (cardiac), which proceed from the main trunk in the neck, or from its recurrent branch. The sympathetic sends three (cardiac) filaments: one from the upper cervical ganglion, a second from the middle, and a third from the lower; and they are called, respectively, the upper, middle, and lower cardiac nerves of the sympathetic.

The minute and delicate nerves from these several sources on each side pass downwards to the base of the heart. They vary very much in their precise relations to the great vessels upon which they run; but, speaking generally, it may be said that the nerves on the right side run chiefly behind the arch of the aorta;

those on the left, in front of it. Eventually they form, by their mutual subdivisions and interlacement, an intricate network of nerves, termed, according to their position, the superficial and the deep cardiac plexus.

The *superficial and smaller cardiac plexus* lies in the concavity of the arch of the aorta in front of the right pulmonary artery. It is closely connected with the deep plexus. It receives the upper cardiac branch of the left sympathetic, the lower cervical cardiac branch from the left pneumogastric, and filaments from the deep plexus. In it is usually found a small ganglion, *ganglion of Wisberg*,

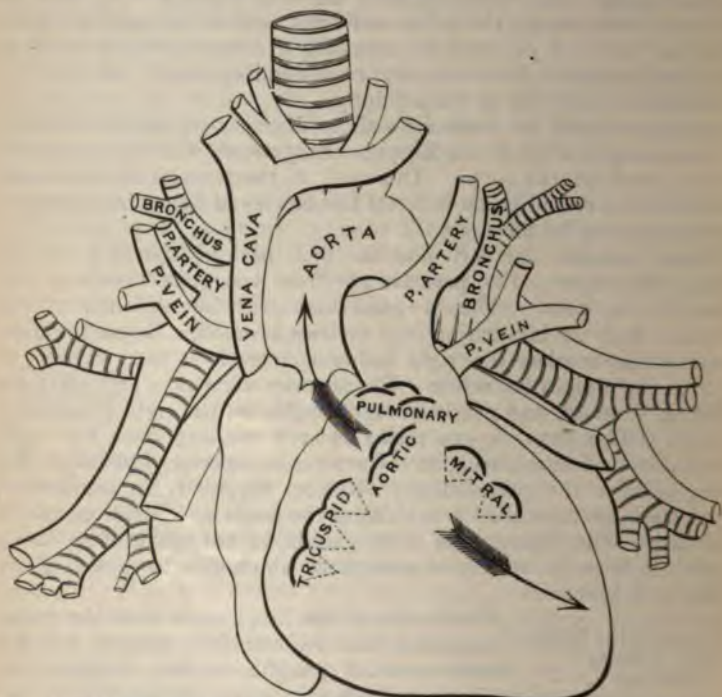


FIG. 72.—DIAGRAM SHOWING THE CONSTITUENTS OF THE ROOT OF EACH LUNG, AND THEIR RELATIVE POSITION; ALSO THE POSITION OF THE VALVES OF THE HEART. THE ARROWS INDICATE THE DIRECTIONS IN WHICH AORTIC AND MITRAL MURMURS ARE PROPAGATED.

placed beneath the arch of the aorta on the right side of the ductus arteriosus. This plexus distributes branches to the anterior coronary and the anterior pulmonary plexuses.

The *deeper and larger cardiac plexus* is situated behind the arch of the aorta in front of the bifurcation of the trachea and immediately above the right pulmonary artery. To see it the pericardial covering of the aorta must be carefully removed and the vessel hooked forwards and to the left. This plexus is formed by all the

cardiac branches of the right and left sympathetic ganglia, and by the cardiac branches of the pneumogastric and recurrent laryngeal nerves, except the left superior cardiac branch of the sympathetic and the left cervical cardiac branch of the pneumogastric, both of which pass to the superficial cardiac plexus. The branches from the *right* side of this plexus descend chiefly in front of the pulmonary artery and pass to the anterior pulmonary plexus and to the anterior coronary plexus; a few branches which pass behind the pulmonary artery are distributed to the right auricle and to the posterior coronary plexus. The branches from the *left* side of the plexus go to the left auricle, the anterior pulmonary plexus, but chiefly to the posterior coronary plexus.

From the cardiac plexuses, as a common centre, the nerves pass off to the heart, forming plexuses around the coronary arteries. Thus, the *anterior coronary plexus* (derived chiefly from the superficial cardiac) accompanies the anterior coronary artery. The *posterior coronary plexus* (derived chiefly from the left side of the deep cardiac) runs with the posterior coronary artery. The two plexuses communicate at the apex of the heart, and in the ventricular septum.

It is not an easy matter to trace the nerves into the substance of the heart. For this purpose a horse's heart is the best, and previous maceration in water is desirable. The nerves in the substance of the heart are peculiar in this respect; that they present minute ganglia in their course, which are presumed to preside over the rhythmical contractions of the heart.

Constituents of the Root of each Lung. Draw aside the margin of the right lung; divide the superior vena cava above the vena azygos, and turn down the lower part. Remove the layer of pericardium which covers the pulmonary veins, and the constituent parts of the root of the right lung will be exposed. It is composed of the pulmonary artery, the pulmonary veins, bronchus, bronchial vessels, anterior and posterior pulmonary plexuses, and some lymphatics. The following is the disposition of the large vessels forming the root of the lung. In front are the two pulmonary veins; behind the veins are the subdivisions of the pulmonary artery; behind the artery are the divisions of the bronchus. From above downwards they are disposed thus: On the right side we find—1st, the bronchus; 2d, the artery; 3d, the veins. On the left we find—1st, the artery; 2d, the bronchus; 3d, the veins—as shown in Fig. 72.

DISSECTION OF THE HEART.

The heart is conical in form, and more or less convex on its external aspect, with the exception of that portion lying on the tendinous centre of the diaphragm, which is flattened. It is situated obliquely in the thorax between the two lungs, and is completely surrounded by the pericardium. It extends from the fifth to the eighth dorsal vertebra, with its base directed upwards and to the right, its apex downwards and to

the left, where during life it beats in the fifth intercostal space, two inches (5 cm.) below the nipple and an inch (2.5 cm.) to its sternal side. The position which the heart bears to the thoracic walls has been already described (p. 177); it varies, however, in different subjects, and as a rule is higher in the dead body than in the living, owing to the shrinking of the lungs.

The anterior surface of the heart is convex and looks upwards and forwards; the posterior surface is flattened and rests upon the diaphragm: the former is chiefly formed by the right ventricle, the latter by the left ventricle. The right border is sharp (*margo acutus*); while the left border is thick and rounded (*margo obtusus*).

Size and Weight. The size of the heart is dependent upon so many conditions, that the following measurements must be received with more or less limitation. An average heart will measure, in its transverse direction at the base, three and a half inches (8.7 cm.); in its length, about five inches (12.5 cm.); in its thickness, two and a half inches (6.2 cm.). The weight is from ten to twelve ounces (283 to 336.6 grm.) in the male, and from eight to ten (226.4 to 283 grm.) in the female; but much depends upon the size and condition of the body generally. As a rule, the heart gradually increases in length, breadth, and thickness from childhood to old age.

Notice two longitudinal grooves (*sulci*) on the front and back surfaces of the heart, which extend from the base of the ventricles to the apex, and which indicate the septum between the two ventricles; the anterior groove lies nearer to the left side, the posterior to the right side of the heart.

A circular groove, nearer the base, marks the separation between the auricles and ventricles. In the circular and longitudinal furrows, surrounded by more or less fat, run the coronary vessels, the nerves, and the lymphatics.

The heart is a double hollow muscular organ; that is, it is composed of two hearts, a right and a left, separated by a septum, and not communicating with each other except during uterine, and rarely in adult, life. Each half consists of two cavities, an *auricle* and a *ventricle*, which communicate by a wide orifice, the auriculo-ventricular opening. The right half of the heart propels venous blood to the lungs, and is called the *pulmonary*; the left propels arterial blood from the lungs throughout the body, and is called the *systemic*. These two hearts are not placed apart, because important advantages result from their union. By being enclosed in a single bag they occupy less room in the chest; and the action of their corresponding cavities being precisely synchronous, their fibres, mutually intermixing, contribute to their mutual support.

The cavities of the heart should now be examined in the order in which the blood circulates through them.

Right Auricle. This is situated at the right side of the base of the heart, and forms a quadrangular cavity, the *atrium* or *sinus venosus*, between the two *venæ cavæ*, from which it receives the blood. From its front a small pouch projects towards the left, and overlaps the root of the aorta; this part is termed the *appendix auriculæ*, and resembles a dog's ear in shape.

Make a crucial incision over the anterior surface of the auricle, extending one prong into the appendix. The interior is lined by a polished membrane called the *endocardium*, and is everywhere smooth except in the appendix, where the muscular fibres are collected into bundles, called, from their resemblance to the teeth of a comb, *musculi pectinati*. They radiate from the auricle to the edge of the auriculo-ventricular opening.

The following objects are seen on opening the auricle:—

Superior vena cava.	Eustachian valve.
Inferior vena cava.	Coronary valve.
Coronary sinus.	Annulus ovalis.
Auriculo-ventricular opening.	Fossa ovalis.
Foramina Thebesii.	Tubercle of Lower.

Musculi pectinati.

Examine carefully the openings of the two *venæ cavæ*: they are not directly opposite to each other; the *superior cava* opens into the auricle on a plane rather in front, and a little to the left, of the inferior, so that its orifice is opposite to the auriculo-ventricular opening. The *inferior cava*, after passing through the tendinous centre of the diaphragm, makes a slight curve to the left before it opens into the lowest part of the auricle; its direction is upwards and inwards, so that the stream of blood is directed towards the auricular septum. The orifice of each vena cava is nearly circular, and surrounded by circular muscular fibres continuous with those of the auricle.

The posterior wall of the auricle is formed by the partition between the auricles, the *septum auricularum*. Upon this septum, above, and to the left of the orifice of the vena cava inferior, is an oval depression (*fossa ovalis*), bounded by a prominent border (*annulus ovalis*). This depression indicates the remains of the opening (*foramen ovale*) through which the blood in foetal life passed from the right into the left auricle. After birth this opening closes; but if the closure is imperfect, the stream of dark blood in the right auricle mixes with the florid blood in the left, and occasions what is called *cyanosis*. A valvular communication, however, not infrequently exists between the auricles in this situation which is not attended with indications of this disease.

A more or less noticeable fold of the lining membrane, the *Eustachian valve*, may be seen projecting from the front margin of the vena cava inferior to the front border of the fossa ovalis. It is placed between the inferior vena cava and the lower margin of the annulus ovalis. Curved in shape, it passes forwards and ends in two cornua; of which, one is attached to the annulus ovalis, the other is lost on the wall of the auricle. It consists of a reduplication of the endocardium and contains some muscular tissue. It is the remnant of a valve, which was of considerable size in foetal life, and served to direct the current of blood from the vena cava inferior, through the foramen ovale, into the left auricle.

To the left of the Eustachian valve, that is, between its remains

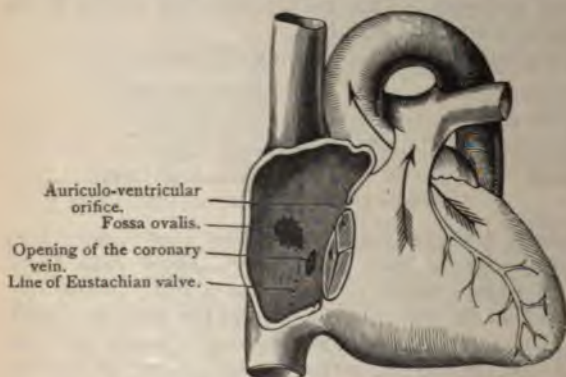


FIG. 73.—DIAGRAM OF THE INTERIOR OF THE RIGHT AURICLE.

and the auriculo-ventricular opening, is the orifice of the *coronary sinus*. The sinus is about an inch (2.5 cm.) in length and receives the great cardiac vein, the posterior cardiac vein, and the oblique vein (of Marshall), and will nearly admit the end of the little finger. It is surrounded by muscular fibres, and is guarded by a semicircular fold of the endocardium, called the *valve of Thebesius*,* to prevent regurgitation of the blood during the auricular contraction.

Here and there upon the posterior wall of the auricle may be observed minute openings, called *foramina Thebesii*; some being the orifices of small veins returning blood from the substance of the heart; others being simple depressions in the muscular tissue. To the left, and rather in front of the orifice of the vena cava in-

* This valve is occasionally double.

ferior, is the *auriculo-ventricular* opening, guarded by the tricuspid valve. It is oval in form, and will admit the passage of three fingers. Lastly, between the orifices of the superior and inferior venæ cavæ is a rounded elevation, the *tubercle of Lower** (not seen in the diagram), which is supposed to direct the current of blood, in foetal life, from the superior cava to the auriculo-ventricular opening.

The *musculi pectinati* are parallel muscular elevations running across the inner surface of the auricular appendix, and to a slight extent also of the sinus venosus.

Right Ventricle. This forms the right border and about two-thirds of the front surface of the heart. To examine its interior, a triangular flap should be raised from its anterior wall. The apex of this flap should be below; one cut along the right edge of the ventricle, the other along the line of the ventricular septum. Observe that the wall of the ventricle is much thicker than that of the auricle. The cavity of the ventricle is conical, with base upwards and to the right. Its inner wall is convex, and is formed by the septum ventriculorum. The upper and front part presents a smooth passage, the *infundibulum* or *conus arteriosus*, which leads to the opening of the pulmonary artery. It is situated to the left and in front of the auriculo-ventricular opening, and about three-fourths of an inch (18 mm.) higher.

The following objects are seen in the right ventricle:—

Columnæ carneæ.
Chordæ tendineæ.

Auriculo-ventricular opening.
Pulmonary opening—

guarded by the tricuspid and semilunar valves.

From its walls project bands of muscular fibres, *columnæ carneæ*, of various length and thickness, which cross each other in every direction; this muscular network is generally filled with coagulated blood. Of these *columnæ carneæ* there are three kinds: one stands out in relief from the ventricle; another is attached to the ventricle by its extremities only, the intermediate portion being free; a third, and by far the most important set, called *musculi papillares*, is fixed by one extremity to the wall of the ventricle, while the other extremity gives attachment to the fine tendinous cords, *chordæ tendineæ*, which regulate the action of the tricuspid valve. The number of these *musculi papillares* is equal to the number of the chief segments of the valve; hence there are three in the right, and two in the left ventricle. Of those in the right ventricle, one is attached to the septum.

There are two openings in the right ventricle. One, the *auriculo-ventricular*, through which the blood passes from the aur-

* Most distinct in quadrupeds.

icle, is oval in form and placed at the base of the ventricle. It is surrounded by a ring of fibrous tissue, to which is attached the tricuspid valve.

Tricuspid Valve.

This is situated at the right auriculo-ventricular opening, and consists of three triangular flaps. Like all the valves of the heart, it is formed by a fold of the lining membrane (*endocardium*) of the heart, strengthened by fibrous tissue, in which a few muscular fibres may be demonstrated. The bases of the valves are continuous with one another, so that they form a membranous ring between the auricle and ventricle, while the segments project into the cavity of the right ventricle. Of its three flaps, the largest or anterior is so placed, that, when not in action, it partially covers the orifice of the pulmonary artery; another, the internal, corresponds with the inferior wall of the ventricle; the third, or posterior, rests upon the septum ventriculorum.

Observe the arrangement of the tendinous cords which regulate the action of the valve. First, they are all attached to the ventricular surface of the valve. Secondly, the tendinous cords proceeding from a given papillary muscle are attached to the adjacent halves of two of the flaps; consequently, when the ventricle contracts, and the papillary muscle also, the adjacent borders of the flaps will be approximated. Thirdly, to insure the strength of every part of the valve the tendinous cords are inserted at three different points of it in straight lines; accordingly, they are divisible into three sets. Those of the first, which are three or four in number, are attached to the base of the valve; those of the second, from four to six, proceed to the middle of its ventricular surface; those of the third, which are the smallest and most numerous, are attached to its free margin.*

Pulmonary or Semi-lunar Valves.

These are three semicircular membranous folds, like watch-pockets, situated at the orifice of the pulmonary artery. They are attached by their convex borders to the root of the artery; their free edges look

* The best mode of showing the action of the valve is to introduce a glass tube into the pulmonary artery, and then to pour water through it into the ventricle until the cavity is quite distended. By gently squeezing the ventricle in the hand, so as artificially to imitate its natural contraction, the tricuspid valve will flap back like a flood-gate, and close the auriculo-ventricular opening. In this way one can understand how, when the ventricle contracts, the blood catches the margin of the valve, and by its pressure gives it the proper distention and figure requisite to block up the aperture into the auricle. It is obvious that the tendinous cords will prevent the valve from flapping back into the auricle; and this purpose is assisted by the papillary muscles, which nicely adjust the degree of tension of the cords at a time when they would otherwise be too much slackened by the contraction of the ventricle.

upwards, and present a festooned border, in the centre of which is a small cartilaginous body called the *nodulus* or *corpus Arantii*. The use of these bodies is plain. Since the valves are semilunar, when they fall together they would not exactly close the artery; there would be a space of a triangular form left between them in the centre, just as there is when we put the thumb, fore, and middle fingers together. This space is filled up by these nodules, so that the closure becomes complete.

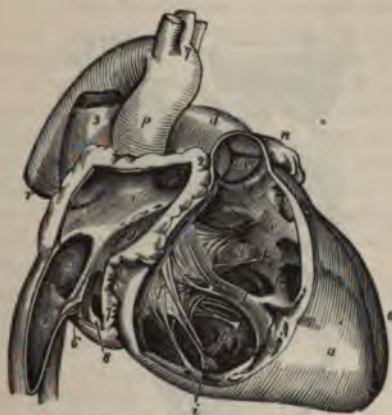


FIG. 74.—ANATOMY OF THE HEART—RIGHT SIDE.

1. Cavity of right auricle. 2. Appendix auriculæ; in its cavity are seen the muscoli pectinati. 3. Superior vena cava, opening into the upper part of right auricle. 4. Inferior vena cava. 5. Fossa ovalis; the prominent ridge surrounding it is the annulus ovalis. 6. Eustachian valve. 7. Opening of the coronary vein. 8. Coronary valve. 9. Entrance of the auriculo-ventricular opening. Between the figures 1 and 9, two or three foramina Thebesii are seen. *a*. Right ventricle. *b, c*. Cavity of right ventricle, on the walls of which columnæ carneæ are seen; *c* is placed in the channel leading upwards to the pulmonary artery. *d, e, f*. Tricuspid valve; *e* is placed in the anterior flap, *f* on the right flap. *g*. Long columnæ carneæ, to the apex of which the anterior and right flaps are connected by chordæ tendinæ. *h*. The "long moderator band." *i*. The two columnæ carneæ of the right flap. *k*. Attachment by chordæ tendinæ of the left limb of the anterior flap. *l, l*. Chordæ tendinæ of the more fixed portion of the valve. *m*. Valve of the pulmonary artery. *n*. Apex of left appendix auriculæ. *o*. Left ventricle. *p*. Ascending aorta. *q*. Its transverse portion with the three arterial trunks which arise from the arch. *r*. Descending aorta.

The valves, two anterior and one posterior, are composed of folds of the *endocardium*, or lining membrane of the heart. Between the folds is a thin layer of fibrous tissue, which is prolonged from the fibrous ring at the orifice of the artery. This layer of fibrous tissue, however, reaches the free edge of the valve at three points only: namely, at the centre, or *corpus Arantii*, and at each extremity. Between these points it stops short, and leaves a crescent-shaped portion of the valve, which is thinner than the rest, and

consists of the endocardial membrane. This crescent-shaped portion, called the *lunula*, is not wholly without fibrous tissue; a thin tendinous cord runs along its free edge, to give it additional strength to resist the pressure of the blood. Behind each of the valves the artery bulges and forms three slight dilatations called the *sinuses of Valsalva*. These, we shall presently see, are more marked at the orifice of the aorta.

The action of these valves is evident. During the contraction of the ventricle the valves lie against the side of the artery, and

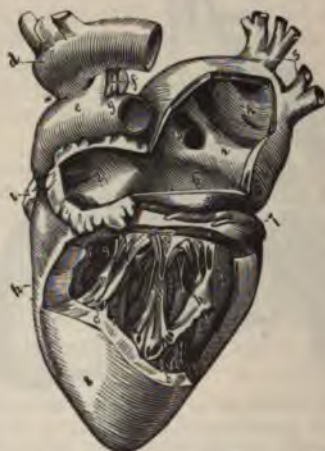

FIG. 75.—ANATOMY OF THE HEART—LEFT SIDE.

1. Cavity of left auricle. 2. Cavity of the appendix auriculæ, near the apex of which are seen musculi pectinati. 3. Opening of the two right pulmonary veins. 4. The sinus into which the left pulmonary veins open. 5. Left pulmonary veins. 6. Auriculo-ventricular opening. 7. Coronary vein, lying in the auriculo-ventricular groove. 8. Left ventricle. 9, 9. Cavity of the left ventricle; the figures rest on the septum ventriculorum. *a*. Mitral valve; its flaps are connected by chordæ tendinæ to *b*, *b*, *b*. Columnæ carnæ. *c*, *c*. Fixed columnæ carnæ, forming part of the internal surface of the ventricle. *d*. Arch of the aorta, from the summit of which the three trunks (arterial) are seen. *e*. Pulmonary artery. *f*. Obliterated ductus arteriosus. *g*. Left pulmonary artery. *h*. Right ventricle. *i*. Point of the appendix of right auricle.

offer no impediment to the current of blood; during its dilatation the elasticity of the distended artery would force back the column of blood, but that the valves, being caught by the refluent blood, bag, and fall together so as to close the tube. The greater the pressure, the more complete is the closure. The coats of the artery are very elastic and yielding, while the valve, like the circumference to which it is attached, is quite unyielding; consequently, when the artery is distended by the impulse of the blood, its wall

is removed from the contact of the free margin of the valves, and these are the more readily caught by the regurgitating motion of the blood. The force of the reflux is sustained by the tendinous part of the valves, and by the muscular wall of the ventricle (probably in a state of contraction). The valves are capable of sustaining a weight of sixty-three pounds before they give way. The thinner portions (*lunulæ*) become placed so as to lie side by side, each one with that of the adjacent valve. This may be demonstrated by filling the artery with water.

Left Auricle.

This is situated at the left side and posterior part of the base of the heart, and is somewhat smaller than the right auricle. It consists, like the right auricle, of a cavity—the sinus venosus—and the auricular appendix. It is quadrilateral, and receives the four pulmonary veins, two on either side, which return the oxygenated blood from the lungs. From its upper and left side, the *auricular appendix* projects towards the right, curling over the root of the pulmonary artery. The auricle should be opened by a horizontal incision along the ventricular border of the auricle, and another should be made upwards from the centre of the first incision.

The interior of the *atrium* is smooth and flat, but in the appendix there are numerous raised muscular bands, the *musculi pectinati*. The interior presents the following objects for examination:—

- The orifices of the four pulmonary veins.
- The auriculo-ventricular opening.
- The *musculi pectinati*.

The openings of the pulmonary veins are seen in the posterior wall, two on the right side (sometimes three), and two on the left side. They are not guarded by valves. Upon the septum between the auricles is a semilunar depression, indicating the remains of the foramen ovale. The *auriculo-ventricular opening*, situated at the lower and front part of the auricle, is smaller than that of the right side, and somewhat oval. Its long axis is nearly transverse, and, in the adult, will admit the passage of two fingers. The *musculi pectinati* are also smaller and fewer than in the right auricle.

Left Ventricle.

This occupies the left border, and forms the apex of the heart. One-third of it only is seen on the anterior surface, the rest being on the posterior. To examine the interior, raise a triangular flap, with the apex below, from its front wall. Observe that its wall is about three times as thick as that of the right ventricle, and that this thickness gradually diminishes towards the apex. The interior of the left ventricle presents the following objects for examination:—

- | | |
|-------------------------------|--|
| Auriculo-ventricular opening. | Auriculo-ventricular or mitral valves. |
| Aortic opening. | Semilunar valves. |
| | Columnæ carneæ. |

These parts so closely resemble that of the right that there is no necessity to describe them in detail. The *auriculo-ventricular valve* consists of two flaps; hence its name, *mitral* or *bicuspid*. The larger of these flaps is placed between the aortic and auriculo-ventricular orifices. There are only two *musculi papillares*: one attached to the anterior, the other to the posterior wall of the ventricle. They are thicker, and their *chordæ tendineæ* stronger, than those of the right ventricle, but their arrangement is precisely similar. From the upper and back part of the ventricle a smooth passage leads to the orifice of the aorta. This orifice is placed in the groove between the two auricles, and somewhat in front and to the right side of the left auriculo-ventricular opening. The two orifices are close together, and only separated by the larger flap of the mitral valve. The aortic orifice is guarded by three semilunar valves, of which the arrangement, structure, and mode of action are similar to those of the pulmonary artery. Their framework is proportionately stronger, consistently with the greater strength of the left ventricle, and the greater impulse of the blood. In the *sinuses of Valsalva* are observed the orifices of the two coronary arteries; the left arising from the sinus behind the left posterior segment; the right from behind the anterior segment.

Size of the Auriculo-ventricular and Arterial Openings.

(8.7 cm.); and that

Coronary Arteries.

The heart is supplied with blood by the two coronary arteries, a right or posterior, and a left or anterior. They are about the size of a crow's quill. Both arise from the aorta just above the free margins of the two semilunar valves, and thus always allow the passage of blood; both run in the furrows on the surface of the heart; both are accompanied by the cardiac nerves and by lymphatics.

The *anterior* or *left coronary* artery, the smaller of the two, arises from behind the left posterior valve of the aortic orifice. It appears between the pulmonary artery and the appendix of the left auricle, and then divides into two branches: one which seems the continuation of the main trunk and runs down the inter-ventricular furrow on the anterior surface of the heart to the apex; the other passes transversely to the left, in the left auriculo-ventricular groove to the back of the heart.

The *posterior* or *right coronary* artery arises from behind the anterior cusp of the aortic opening, and descends obliquely between the pulmonary artery and the appendix of the right auricle. It then turns to the right in the groove between the right ventricle and auricle to the back of the heart, where it divides into two branches; one of which descends in the posterior inter-ventricular furrow towards the apex of the heart; the other, which appears to be the continuation of the main

* Dr. Peacock, *Croonian Lectures*, 1865.

trunk, runs in the left auriculo-ventricular groove. Besides these branches, the right coronary gives off a large branch which runs along the free border of the right ventricle.

Thus, the leading trunks of the coronary arteries run in the furrows of the heart, usually surrounded by fat. Their numerous branches supply the walls of the auricles and ventricles, and their terminations communicate with each other.

Coronary Veins and Sinus.

The vein which corresponds with the anterior coronary artery ascends in the anterior inter-ventricular sulcus, and then curves round the left side of the heart in the left auriculo-ventricular groove, where it takes the name of the *great cardiac vein*. This vein soon dilates into a large trunk, the *coronary sinus*, which opens at the back of the right auricle below the Eustachian valve.

Another vein, known as the *posterior cardiac*, ascends along the posterior inter-ventricular groove, to open by valved orifices into the coronary sinus; while others, the *anterior cardiac veins*, three or four in number, are seen running up on the anterior surface of the right ventricle to terminate directly in the right auricle.

The *venæ Thebesii* transmit the blood directly from the muscular structure into the right auricle by small apertures, the foramina Thebesii. The *coronary sinus* is about an inch (2.5 cm.) in length, and receives the great cardiac vein, the posterior cardiac vein, and the oblique vein of Marshall, placed on the posterior surface of the left auricle. Its orifice in the right auricle is guarded by a semi-lunar valve (*valve of Thebesius*) to prevent regurgitation of the blood. It is covered and more or less supported in its course by muscular fibres passing from one auricle to the other.

The *lymphatics* of the heart pass mainly into a trunk which runs in the anterior inter-ventricular groove, and then, passing into the glands between the aorta and trachea, open into the right lymphatic duct; other smaller lymphatics pass into the thoracic duct.

The *nerves* are derived from the cardiac plexuses, which have been already described, p. 202.

Fibrous Rings of the Heart.

What may be termed the fibrous skeleton of the heart consists of four rings, which surround, respectively, the four orifices at its base; namely, the two auriculo-ventricular, the aortic, and the pulmonary. These rings give attachment by their external circumference to the muscular fibres of the heart, and from their internal circumference send fibrous prolongations to form the framework of the several valves. The skeleton is strongest just in the triangular interspace between the aortic and the two auriculo-ventricular orifices (letter A in Fig. 76). In some animals, as in the ox and the elephant, there is here an irregularly triangular bone, known as the *os cordis*.

The relative position of these rings is best seen by removing the auricles and the great vessels at the base of the heart—leaving the several valves, and looking at them from above, as shown in the diagram. The pulmonary ring is on the highest level, and nearest to the sternum; below it, is the aortic ring lying between and in front of the auriculo-ventricular rings, which are on the lowest level.

Attachment of the Large Arteries to the Ventricles.

The fibrous rings at the arterial orifices present three festoons with their concavities directed upwards. These give attachment, above, to the middle coat of the artery; below, to the muscular fibres of the ventricles; and, internally, to the fibrous tissue of the valves. The vessels are also connected to the heart by the serous layer of the pericardium, and by a continuation of the lining membrane of the ventricle.

Epicardium.

This, the visceral layer of the pericardium, closely invests the external surface of the heart, and presents the usual appearances of a visceral serous membrane.

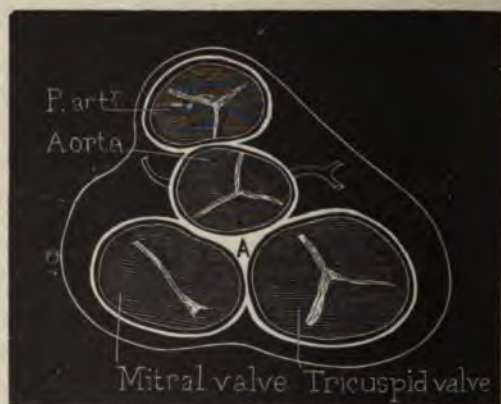


FIG. 76.—DIAGRAM OF THE RELATIVE POSITION OF THE VALVES OF THE HEART, SEEN FROM ABOVE.

A is placed on the triangular interval where the fibrous skeleton is the thickest.

Endocardium.

This smooth membrane lining the cavities of the heart resembles the visceral layer of the pericardium, and is continuous with the inner coat of the blood-vessels. It may be easily stripped off, and is thin and semi-transparent, thicker in the left than in the right cavities, thickest of all in the left auricle.

Arrangement of the Muscular Fibres of the Auricles.

The fibres of the auricles are distinct from those of the ventricles. They consist of a *superficial* layer common to both cavities, and a *deeper* layer proper to each. The *superficial* fibres run transversely across the auricles, and are most marked on the anterior surface; some pass into the inter-auricular septum. Of the *deeper* fibres, some are *annular* and surround the auricular appendages and the entrance of the great veins, upon which a few

may be traced for a short distance; others, *looped*, run over the auricles, and are attached in front and behind to the auriculo-ventricular rings.

Arrangement of the Muscular Fibres of the Ventricles.

Speaking generally, it may be said that the right and left ventricles of the heart are two conical muscular sacs, enclosed in a third, which not only envelopes them, but is reflected into the interior of both, at their apices, so as to line their cavities. All the muscular fibres are attached by one end to the fibrous rings of the orifices, and, by the other end, after a more or less spiral course, they reach the rings again, either directly or through the medium of the chordæ tendinæ and valves.

The external or superficial fibres pass from the base, where they are attached to the auriculo-ventricular rings, to the apex. This layer is thin in front, but behind it is better marked, and here the fibres do not pass into the septum, but over it, while in front they pass over the anterior septum, only at the base and apex of the ventricle. The fibres run more or less spirally towards the apex, where they form a whorl and pass into the left ventricle, so as to form, in part the innermost vertical muscular layer, in part the fleshy columns of its cavity. The superficial anterior fibres pass backwards to the left, and form, behind, the posterior papillary muscle; and, on the other hand, the superficial posterior fibres pass over the right side of the heart and constitute the anterior papillary muscle.

The remaining fibres of the left ventricle, which constitute its chief thickness, are attached to the fibrous rings at the base of the heart. They pass, more or less obliquely, in the posterior and anterior walls, and entering the lower end of the septum pass in three different directions: one set, upwards in the septum to be attached to the fibrous tissue in the triangular interspace; a second set pass through the septum to form the posterior wall of the right ventricle and its posterior papillary muscle; while the third set take a transverse circular course in the left ventricle, some of its fibres being continuous with those of the right ventricle.

The fibres of the right ventricle are arranged on a plan similar to that of the left ventricle, of which it may be considered an appendage. The fibres, which correspond to those forming the chief thickness of the left ventricle, are similarly arranged into an anterior, middle, and posterior set: the anterior pass backwards into the septum to reach the posterior wall of the left ventricle and interlace in the septum with the posterior set which pass forwards in the septum to the front wall of the left ventricle; the middle set come chiefly from the outer wall of the right ventricle, deep down at the lower part of the septum, and then ascend to be attached to the fibro-cartilage. Besides these there are more or less numerous annular fibres encircling the right ventricle.*

Thickness of the Cavities.

The average thickness of the right auricle is about $\frac{1}{2}$ of an inch (2 mm.); that of the left $\frac{1}{3}$ of an inch (3 mm.). The average thickness of the right ventricle at its thickest part—*i. e.*, the base—is about $\frac{1}{2}$ of an inch (4 mm.); that of the left ventricle at its thickest part—*i. e.*, the middle—is about half an inch (12.5 mm.). In the female the average is less.

* There are other accounts given of the arrangements of the muscular structure of the heart, and that given by Pettigrew is one which is adopted by many of the best anatomists. For further information on this subject consult Pettigrew, *Philosoph. Transactions*, 1864; Dr. Sibson, *Medical Anatomy*, 1869; Winckler, *Müller's Archiv*, 1865; Quain's *Anatomy*, vol. ii, p. 495, 1882.

**Peculiarities of the
Fœtal Circulation.**

The heart and the circulation of the fœtus differ from that of the adult in the following points:—

1. The *Eustachian valve* is well developed as a crescentic fold which guides the current of blood from the inferior vena cava through the right auricle into the foramen ovale.
2. The *foramen ovale* is widely open up to the fourth month, after which a septum grows up from the lower border of the left side, so that at the sixth month the blood can only pass in the onward direction into the left auricle.
3. The *right and left pulmonary arteries* are very small and ill developed, so as to admit very little blood to the lungs.
4. The *ductus arteriosus*, from the commencement of the left pulmonary artery to the aorta, is widely open.
5. The *hypogastric or umbilical arteries*, branches of the anterior division of the internal iliac, emerge through the umbilicus and pass to the placenta, so that the impure blood may be oxygenated.
6. The *umbilical vein* returns the pure blood partly to the liver, and partly through the—
7. *Ductus venosus* into the inferior vena cava.
8. The *right and left ventricles* are of equal thickness, because they have equal work to perform.

FETAL CIRCULATION.

Arterial blood is brought from the placenta by the umbilical vein (Fig. 77), and enters at the umbilicus, whence it passes to the under surface of the liver. Here it gives off some branches to the left lobe, and others to the lobulus Spigelii and lobulus quadratus, which eventually return their blood into the inferior vena cava. At the transverse fissure it divides into two branches—one, the smaller, termed the *ductus venosus*, passes straight to enter into the inferior vena cava, having previously joined the left hepatic vein; the other, or right division, joins the vena portæ, and, after ramifying in the right lobe of the liver, returns its blood through the hepatic veins into the inferior vena cava.

From the inferior vena cava, which thus receives its blood from three sources, the blood enters the right auricle, and the stream (directed by the Eustachian valve) flows through the foramen ovale into the left auricle, where it becomes mingled with a little blood, which is returned from the pulmonary veins. From the left auricle it runs through the left auriculo-ventricular opening into the left ventricle, and thence through the aorta into the great vessels of the head and upper extremities (only a small quantity passing into the descending thoracic aorta), which are thus supplied by almost pure blood. From the head and upper limbs the blood returns (impure) through the superior vena cava into the right auricle, whence, mixed with a small quantity derived from the inferior cava, it passes into the right ventricle. From the right ventricle the blood passes through the pulmonary artery and the ductus arteriosus into the commencement of the descending aorta, only a very small quantity of it being distributed to the lungs; the lungs are in the fœtus almost solid organs, and the blood distributed to them is

returned by the pulmonary veins into the left auricle. The blood which passes into the descending aorta, through the ductus arteriosus, is mingled with the small amount coming through the arch, and is then conveyed through the abdominal aorta into the iliac arteries; part is transmitted through the umbilical arteries (branches of the internal iliac arteries) to the placenta to become re-oxygenated; part passes into the lower extremities through the external iliac and femoral arteries.

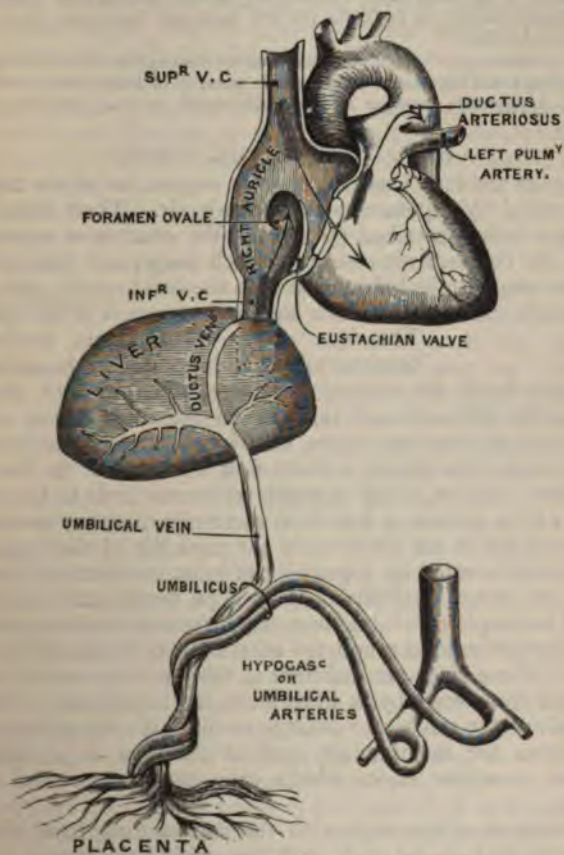


FIG. 77.—SCHEME OF THE FETAL CIRCULATION.

Changes in the Circulation at Birth.

The following changes take place in the circulation after birth:—

1. The *umbilical vein* becomes obliterated from the second to the fifth day after birth, and subsequently forms the round ligament of the liver.

2. The *ductus venosus* also becomes closed about the same period, and may be traced as a thickened cord in the fissure of the *ductus venosus*.

3. The *foramen ovale* becomes closed from the sixth to the tenth day; but not infrequently a small indirect valvular communication may be found forming a communication between the two auricles.

4. The *ductus arteriosus* contracts immediately after birth, and becomes closed from the sixth to the tenth day. It eventually forms a fibrous cord connecting the left pulmonary artery with the aorta, the left recurrent laryngeal nerve winding round its left border.*

5. The *pulmonary arteries* enlarge and convey venous blood to the lungs. These organs during foetal life receive only a small quantity of blood from these arteries.

6. The *hypogastric arteries* become obliterated on the fourth or fifth day after birth.

STRUCTURE OF THE LUNGS.

The lungs are very vascular, spongy organs in which the blood is oxygenated by exposure to atmospheric air. Their situation and shape have been described (p. 176). We must now examine the trachea, the common air-passage to both lungs, and then trace this tube downwards to its bifurcation into the two bronchi, which, with their minute subdivisions, form the main structure of the lungs.

Trachea.

This is a partly cartilaginous, partly membranous tube, and is situated in the middle line. It extends from the cricoid cartilage, *i.e.*, opposite the upper border of the sixth cervical vertebra, to the third dorsal vertebra, where it divides into two tubes, the right and left bronchus—one for each lung. Its length is from four and a half to five inches (*11.2 cm. to 12.5 cm.*), and its width from two-thirds to five-sixths of an inch (*16 to 20 mm.*); but these measurements vary according to the age and sex of the patient and the capacity of the lungs. The trachea is surrounded by a quantity of loose connective tissue, so as to allow of its free mobility. It is kept permanently open by a series of incomplete cartilaginous rings, from sixteen to twenty in number, which extend round the anterior two-thirds of its circumference. These rings are deficient at the posterior part of the tube, where it is completed by a fibro-muscular membrane. This deficiency allows the trachea to enlarge or diminish its calibre; and for this purpose the membranous part of the tube is provided with unstriped muscular fibres which can approximate the ends of the rings.

The relations of the trachea to the surrounding parts should be considered, first, in the neck, and then within the thorax.

*The initial cause of the closure of the *ductus arteriosus* has been attributed to the contraction of the muscular fibres reflected to the fibrous pericardium from the diaphragm, the upper portion of the pericardium being held firmly through the attachment of the cervical fascia to it and the first rib, thereby preventing the descent of the central tendon of the diaphragm. The muscular fibres act as tendons of the pericardium, which embrace the duct in question. (A. H.)

In the neck, it has, in *front* of it, the isthmus of the thyroid body, the sterno-hyoid and sterno-thyroid muscles, the inferior thyroid veins, two layers of the deep cervical fascia, the arteria thyroidea ima, if present, and (at the root of the neck) the innominate and left common carotid arteries. *Laterally*, it is in relation with the lobes of the thyroid body, the common carotid arteries, the recurrent laryngeal nerves, and the inferior thyroid arteries. *Behind* it is the œsophagus, inclining slightly to the left.

In the chest the trachea is contained in the superior mediastinum, and has, in *front* of it, the manubrium sterni, the origins of the sterno-hyoid and thyroid muscles, the left brachio-cephalic vein, the first parts of the innominate and left common carotid arteries, the transverse portion of the arch of the aorta, and the deep cardiac plexus. On the *right* side are the pleura and right pneumogastric nerve; on the *left*, the pleura, the left carotid, the left pneumogastric, cardiac, and recurrent laryngeal nerves.

Bronchi, Right and Left. The two *bronchi* differ in length, direction, and diameter. The *right*, wider but shorter than the left, is about an inch (2.5 *cm.*) long, and passes more horizontally to the root of its lung, on a level with the fourth dorsal vertebra. It is larger in all its diameters than the left; hence, foreign bodies which have accidentally dropped into the trachea are more likely to be carried into the right bronchus by the current of the air. The vena azygos major arches over the right bronchus to terminate in the superior vena cava. The *left* is about two inches (5 *cm.*) in length, and, descending more obliquely to its lung than the right, enters it on a level with the fifth dorsal vertebra. The left bronchus passes under the arch of the aorta, in front of the œsophagus and the thoracic duct, and subsequently crosses in front of the descending aorta.

The *cartilages* of the trachea vary in number from sixteen to twenty, of the right bronchus from six to eight, and of the left from nine to twelve. Those of the trachea form about two-thirds of a circle, somewhat like a horseshoe in shape, are about one-sixth of an inch (4 *mm.*) in their vertical direction, and one-twenty-fifth (1 *mm.*) in thickness, and thicker in the middle than at the upper and lower borders. The cartilages are connected and covered on their outer and inner surfaces by a tough membrane, consisting of connective and elastic tissues. This membrane is attached above to the circumference of the cricoid cartilage, and is continued through the whole extent of the trachea and bronchial tubes. Posteriorly, where the cartilages are deficient, it completes the integrity of the air tube. In this tissue, which is of a pale reddish colour, is a layer of unstriped muscular fibres, arranged in a transverse and a longitudinal direction.

The first cartilage is the broadest and is frequently divided at one end; the last cartilage is placed at the bifurcation of the trachea, and is shaped like the letter V; its angle projects into the centre of the main tube, and its sides belong one to each bronchus.

Muscular Fibres. — This thin stratum of unstriped muscular fibres consists of two layers, and is brought into view when the fibrous membrane and tracheal glands have been removed. The longitudinal fibres are the more external, and are attached by minute tendons to the extremities of the cartilages; the transverse fibres (*trachealis muscle*) extend transversely between the posterior free ends of the cartilages. By their contraction they approximate the ends of the cartilages and diminish the calibre of the trachea.

Elastic Tissue. This lines the whole tube, but is most abundant at the posterior or membranous part of the trachea, and its fibres run in a longitudinal direction. It is this layer which raises the mucous membrane into folds, and its elasticity admits of the elongation and the recoil of the tube.

Tracheal Glands. Upon the outer surface of the fibrous layer of the trachea are a number of small mucous glands, most numerous on the posterior part of the tube. They are compound racemose glands lined with columnar epithelium, and their excretory ducts pierce the fibrous and muscular layers, and terminate on the free surface of the mucous membrane. In health their secretion is clear, and just sufficient to lubricate the air-passages. In bronchitis they are the sources of the abundant viscid expectoration.

Mucous Membrane. The *mucous membrane* lining the air-passages is a continuation of that of the larynx. Its colour in the natural state is nearly white, but in catarrhal affections it becomes bright red in consequence of the accumulation of blood in the capillary vessels. It is continued into the ultimate air-cells, where it becomes thinner and more transparent. In its deeper layer is found a considerable amount of elastic tissue, in its superficial layer a quantity of lymphoid tissue. Its surface is lined with a layer of columnar ciliated epithelial cells. The vibratile movement of the cilia is directed in such a way as to favour the expectoration of the mucus. The ciliated epithelium lining the mucous membrane ceases at the commencement of the air-cells, where it is replaced by the squamous variety.

At the root of the lung each bronchus divides into two branches, an upper and a lower, corresponding to the lobes of the lung; on the right side the lower branch sends a small division to the third lobe of the lung. The tubes diverge through the lung, and divide into branches, successively smaller and smaller, until they lead to the air-cells. These ramifications do not communicate with each

other; hence, when a bronchial tube is obstructed, all supply of air is cut off from those cells to which it leads.

The several tissues—cartilaginous, fibrous, muscular, mucous, and glandular—which compose the air-passages, are not present in equal proportions throughout all their ramifications, but each is placed in greater or less amount where it is required. The cartilaginous rings necessary to keep the larger tubes permanently open become, in the smaller tubes, fewer and less regular in form. As the subdivisions of the tubes multiply, the cartilages consist of small pieces placed here and there; they become less and less firm, and finally disappear when the tube is reduced to $\frac{1}{25}$ of an inch (1 mm.) in diameter. The smallest air-passages are entirely membranous, being formed of fibrous, elastic, and muscular tissues.

The Lungs. The lungs are two in number, and occupy the lateral cavities of the chest. Each is conical in shape, its apex extending into the neck, the base resting on the upper or convex surface of the diaphragm. The lung presents for examination—an apex, a base, two surfaces, and two borders.

The *apex* extends upwards about an inch and a half (3.7 cm.) above the first rib, and is generally marked by a slight groove for the subclavian artery. The *base* is concave, and slopes downwards at its posterior part. Its *outer surface*, in contact with the chest wall, is smooth and convex, and is deeper behind than in front. Its *inner surface* is concave, and hollowed out to accommodate the heart and its large vessels. Its *anterior border* is sharp and overlaps the large vessels and the pericardium. The *posterior border* is rounded and rests in the broad groove on the side of the bodies of the dorsal vertebræ. On the inner concave surface, a little above the middle and nearer the posterior than the anterior border, is the *root*, where the large vessels and bronchi pass to and from the lungs.

Each lung is traversed on its external surface by an oblique fissure which passes deeply into its interior. It extends from the upper part of the posterior border, downwards and forwards to the anterior border, and on the right side there is a second fissure passing, forwards and upwards from the oblique fissure, to the middle of the anterior margin. The left lung presents a deep notch in the anterior border in which the pericardium is seen as far as the apex of the heart.

Contractibility of the Lung.

When an opening is made into the chest, the lung, which was in contact with the ribs, immediately recedes from them, and, provided there be no adhesions, gradually contracts. If the lungs be artificially inflated, either in or out of the chest, we observe that they spontaneously expel a part of the air. This disposition to contract, in the living and the dead lung, is due to the elastic tissue in the bronchial tubes and the air-cells; but more especially to a layer of delicate elastic tissue on

the surface of the lung, which has been described by some anatomists as a distinct coat, under the name of the second or inner layer of the pleura.*

Colour. The lungs are of a livid red or violet colour; they often present a mixture of tints, giving them a marble-like appearance. This is not the natural colour of the organ, since it is produced in the act of dying. It depends upon the stagnation of the venous blood, which the right ventricle still propels into the lungs, though respiration is failing. The tint varies in particular situations in proportion to the amount of blood, and is always deepest at the back of the lung. But the colour of the proper tissue of the lung, apart from the blood which it contains, is pale and light grey. This colour is seldom seen except in the lungs of infants who have never breathed, or after death from profuse hæmorrhage.

Upon or near the surface of the lungs, numerous dark spots are observed which do not depend upon the blood, since they are seen in the palest lungs. They vary in number and size, and increase with age. The source of these discolorations is not exactly known; but they are probably deposits of minute particles of carbonaceous matter which have been inhaled with the air.

The lungs are composed of cartilaginous and membranous tubes, of which the successive subdivisions convey the air into closely-packed minute cells, called the *air-vesicles*; of the ramifications of the pulmonary artery and veins; of the bronchial vessels concerned in their nutrition; of lymphatics and nerves. These component parts are united by connective tissue, and covered externally by pleura. The part at which they respectively pass in and out is called the *root of the lung*.

The lungs are the lightest organs in the body, and float in water, their specific gravity varying from .345 to .746. When entirely deprived of air they sink. This is observed in certain pathological conditions; *e.g.*, when one lung is compressed by effusion into the chest, or rendered solid by inflammation.

The surface of the lung is closely invested by a thin, transparent layer of *serous membrane*, immediately beneath which is a fine areolar tissue, called *subserous*, which is very soft and elastic so as to allow of the free expansion of the organ. This tissue sends inwards prolongations, called *interlobular*, which map out the lungs into a number of angular spaces of various sizes termed *lobules*; those on the surface, indicated by faint white lines, are larger than those in the interior of the lung. Each lobule is a lung in miniature, and consists of a small bronchial tube and its termination in dilated

* In some animals, the seal especially, the elasticity of this tissue is very strongly marked.

extremities, called *infundibula*, of ramifications of the pulmonary vessels, lymphatics, and nerves, and, lastly, of the bronchial vessels. The cells of the interlobular tissue have no communication with the air-vesicles, unless the latter be ruptured by excessive straining, and then this connective tissue becomes inflated with air and is called *interlobular emphysema*. When infiltrated with serum it constitutes *œdema* of the lung.

Each bronchial tube divides and subdivides into smaller and smaller divergent tubes, until each has reached a reduced size of about $\frac{1}{25}$ of an inch (1 mm.); it then enters a pulmonary lobule, when it is termed a *lobular bronchial tube*, and presents on its walls numerous dilatations, called air-cells or *alveoli*, which vary from $\frac{1}{50}$ to $\frac{1}{70}$ of an inch (or about $\frac{1}{2}$ to $\frac{1}{3}$ mm.) in diameter (Fig. 78). Thus reduced in size, the walls of the tubes no longer present traces of cartilaginous tissue, but are composed of a delicate elastic membrane upon which the capillaries ramify in a very minute network.* Each tube finally terminates in an enlarged irregular passage—*alveolar passage*—from which proceed on all sides numerous blind dilatations, named *infundibula*.

The smaller bronchial tubes are encircled by more or less complete rings of cartilage; but as the tubes lessen in calibre, the rings become less perfect; so that when the tubes are reduced to $\frac{1}{25}$ of an inch (1 mm.) in diameter the rings entirely disappear. The continuation of the air-tubes consists simply of fibrous tissue which becomes gradually thinner, so that in the smallest tubes they are reduced to simply membranous tubes, and are continued on as irregular passages—*intercellular passages*†—which are studded with numerous small saccules termed *air-cells* or *alveoli*.

The *air-cells* are small, shallow, polyhedral depressions, $\frac{1}{100}$ of an inch (25 μ) in diameter, separated by thin partitions or septa which communicate freely with the intercellular passages, but not with each other.



FIG. 78.—ULTIMATE AIR-CELLS OF THE LUNG (FROM KÜLLIKER). MAGNIFIED TWENTY-FIVE TIMES.

* In phthisis the expectoration contains some of the *débris* of this elastic framework of the air-vesicles; it can be seen under the microscope, and is a test of the character of the sputa.

† Rainey, *Med. Chir. Trans.*, vol. xxviii, 1845.

The *mucous membrane* which invests the divisions of the bronchi as far as the intercellular passages is lined with epithelium of the columnar ciliated variety. At this situation the character of the epithelium changes to that of a squamous kind consisting of a single layer of flat polygonal nucleated cells.

The structure of the air-cells differs in some important features from that of the smaller bronchial tubes; the muscular tissue disappears, the elastic tissue is no longer arranged in bundles, but becomes frayed out and intermingled with the connective tissue.

Pulmonary Vessels. The *pulmonary artery* conveying venous blood to the lungs divides and subdivides with the bronchial tubes, and terminates in a fine dense capillary plexus on the walls of the intercellular passages and air-cells, beneath the epithelium. These plexuses—the *pulmonary capillaries*—form a single layer of capillaries which is so close that the interstices are even narrower than the blood-vessels. The plexus which ramifies over the air-cell does not communicate with the plexus covering another air-cell. The blood and air are not in actual contact. Nothing, however, intervenes but the wall of the cell and the capillary vessels, which are such delicate structures that they oppose no obstacle to the free interchange of gases by which the blood is purified. This purification is effected by the taking in of oxygen, and the elimination of carbonic acid and watery vapour. The most complete purification takes place in the single layer of capillaries between the folds of membrane projecting into the cell; for in this situation both sides of these vessels are exposed to the action of the air. The blood, circulating in steady streams through this capillary plexus, returns through the pulmonary veins. These, at first extremely minute, gradually coalesce into larger and larger branches which anastomose very freely, and accompany the arteries. They finally emerge from the root of the lung by two large trunks which carry the oxygenated blood to the left auricle of the heart. The pulmonary veins are not provided with valves.

Bronchial Arteries. These small arteries, two or more in number, are the nutrient vessels of the lungs. The right arises either from the first aortic intercostal, or, conjointly with the left bronchial, from the thoracic aorta. The left, usually two in number, come from the thoracic aorta. They enter the lung behind the divisions of the bronchi, which they accompany. The bronchial vessels are distributed in various ways; some of their branches supply the coats of the air-passages, the large blood-vessels, and the lymphatic glands; others the interlobular tissue; a few reach the surface of the lung and ramify beneath the pleura. The right *bronchial veins* terminate in the vena azygos, the left in the superior intercostal vein.

The *nerves* of the lung are derived from the pneumogastric and the sympathetic. They enter with the bronchial tubes, forming a plexus in front and behind them, *anterior* and *posterior pulmonary plexus*, in which are found minute ganglia.

The *lymphatics* of the lungs consist of a superficial and deep set; some commence in the lymphatic capillaries in the interlobular tissue, and thence pass to the surface, forming a network which communicates with the subpleural lymphatic plexus; others take their origin in the mucous membrane of the bronchial tubes; and all eventually enter the bronchial glands. Of these the larger are situated about the bronchi near the root of the lung, particularly under the bifurcation of the trachea.

DISSECTION OF THE PHARYNX.

To obtain a view of the pharynx cut through the trachea, the
 Dissection. œsophagus, the large vessels, and nerves of
 the neck, a short distance above the first rib,
 and then separate them from the prevertebral muscles which lie
 immediately in front of the bodies of the cervical vertebræ, and to
 which they are but loosely connected. Saw out a V-shaped piece
 from the temporal and occipital bones, the prongs of the V pointing
 towards the anterior condyloid foramina. Introduce a fine jig-saw
 and aim for the insertion of the rectus capitis anticus muscle on the
 basilar process of the occipital bone passing behind the jugular
 foramina. When this is accomplished the student will find that the
 pharynx and larynx are left attached to the anterior half of the
 section, the spinal column and the prevertebral muscles to the
 posterior half. Tow should then be introduced through the mouth
 and œsophagus to distend the walls of the pharynx.

One side of the pharynx should be dissected to show the constrictor muscles, the other should be reserved for the vessels and nerves in immediate relation with the pharynx.

General Description of Pharynx.

The term *pharynx* is applied to that part of the alimentary canal which receives the food after it has been masticated, and propels it downwards into the œsophagus. It is a funnel-shaped muscular bag, about four and a half inches (11.3 cm.) in length, and broader in its transverse than in its antero-posterior diameter. Its broadest portion is situated opposite the os hyoides, and it then gradually tapers as far as the cricoid cartilage, where it is continuous with the œsophagus, which is its narrowest portion. Its *upper part* is attached to the basilar process of the occipital bone and the petrous portions of the temporal bones; *behind*, it is loosely connected by

deep cervical fascia with the prevertebral muscles; * in *front*, it is attached to the internal pterygoid plates and hamular processes of the sphenoid, to the pterygo-maxillary ligaments, the lower jaw, the tongue, the hyoid bone, and the stylo-hyoid ligaments, and to the thyroid and cricoid cartilages; *laterally*, it is loosely connected to the styloid muscles, and it has in close relation with it the common and internal carotid arteries, the glosso-pharyngeal, pneumogastric, spinal accessory, hypoglossal, and sympathetic nerves; the internal pterygoid, tensor palati, and stylo-pharyngeus muscles; the lingual and ascending pharyngeal arteries, the superior laryngeal and external laryngeal nerves, the ascending palatine artery, and the internal jugular vein. Its dimensions are not equal throughout. Its breadth at the upper part is equal to that of the posterior openings of the nose; here it is only required to convey air, but it becomes much wider in the situation where it transmits the food—that is, at the back of the mouth; thence it gradually contracts to the œsophagus. The pharynx, therefore, may be compared to a funnel communicating in front by wide apertures with the nose, the mouth, and the larynx; while the œsophagus represents the tube leading from its lower end. The upper part of the funnel forms a cul-de-sac at the basilar process of the occipital bone. At this part there is, on each side, the opening of a narrow canal, called the Eustachian tube, through which air passes to the tympanum of the ear. †

Before the muscles of the pharynx can be examined, we must remove a layer of thin fascia, termed the *pharyngeal fascia*. It is the layer of deep cervical fascia behind the pharynx, and must not be confounded with the proper *pharyngeal aponeurosis*, which intervenes between its muscular and mucous walls.

At the back of the pharynx, near the base of the skull, are a few *lymphatic glands*. They sometimes enlarge, and form a perceptible tumour in the pharynx.

In removing the fascia from the pharyngeal muscles, notice that a number of veins ramify and communicate in all directions.

* It is in this tissue (which never contains fat) that post-pharyngeal abscesses are seated.

† Observe that the pharynx conducts to the œsophagus by a gradual contraction of its channel. This transition, however, is in some cases sufficiently abrupt to detain a foreign body, such as a morsel of food more bulky than usual, at the top of the œsophagus. If such a substance become firmly impacted in this situation, one can readily understand that it will not only prevent the descent of food into the stomach, but that it may occasion, by its pressure on the trachea, alarming symptoms of suffocation. Supposing that the obstacle can neither be removed by the forceps, nor pushed into the stomach by the probang, it may then become necessary to extract it by making an incision into the œsophagus on the left side of the neck.

They constitute the *pharyngeal venous plexus*, and terminate in the internal jugular veins.

Constrictor Muscles of the Pharynx. They are three in number and arranged so that they overlap each other, *i. e.*, the inferior overlaps the middle, and the middle the superior

(Fig. 79). They have the same attachments on both sides of the

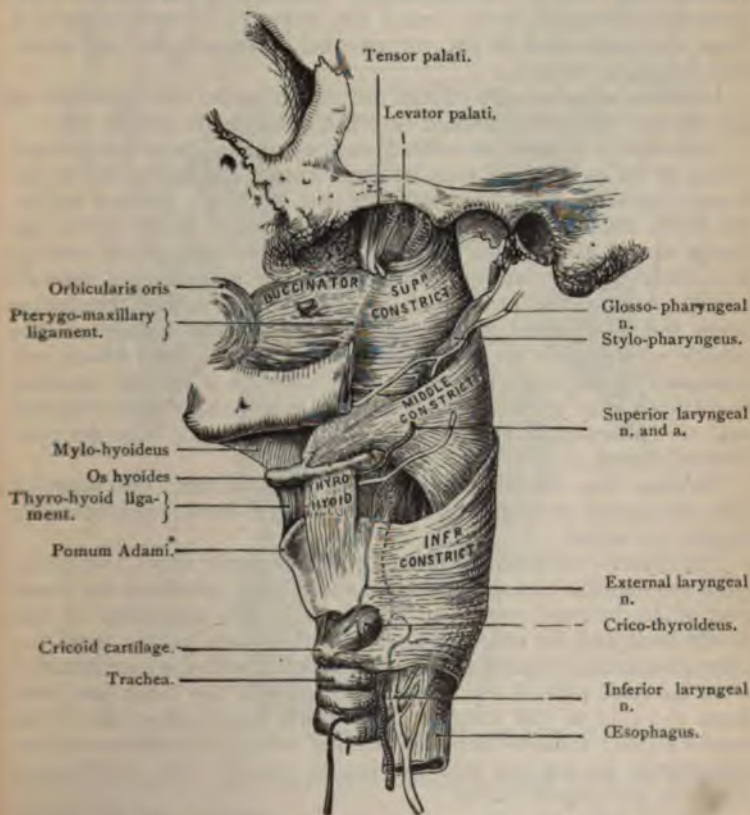


FIG. 79.—SIDE VIEW OF THE MUSCLES OF THE PHARYNX.

body; and the fibres from the right and left meet together and are inserted in the mesial line, the insertion being marked by a white longitudinal line, called the *raphé*.

The *inferior constrictor*, the most superficial and thickest of the

thin constrictors, *arises* from the side of the cricoid cartilage behind the crico-thyroid muscle, from the surface behind the oblique ridge and the lower cornu of the thyroid cartilage. Its fibres expand over the lower part of the pharynx. The superior fibres ascend; the middle run transversely; the inferior descend slightly, and are *inserted* into the posterior median raphé. The lower fibres are continuous with those of the œsophagus. Beneath its lower border the recurrent laryngeal nerve enters the larynx. Its nerve-supply is from the pharyngeal plexus, the external laryngeal, and the recurrent laryngeal nerves.

In order to completely expose the next muscle, the right half of the inferior constrictor should be reflected from the middle line.

The *middle constrictor arises* from the upper edge of the greater cornu of the os hyoides, from its lesser cornu, and part of the stylo-hyoid ligament, and is *inserted* into the posterior median raphé. Its fibres take different directions, so that, with those of the opposite muscle, they form a lozenge. The lower angle of the lozenge is covered by the inferior constrictor; the upper angle ascends nearly to the basilar process of the occipital bone, and terminates upon the pharyngeal aponeurosis. The external surface of the muscle is covered at its origin by the hyo-glossus, from which it is separated by the lingual artery; while beneath it are the superior constrictor, the stylo-pharyngeus, and palato-pharyngeus muscles and the pharyngeal aponeurosis. Its nerve comes from the pharyngeal plexus.

Between the middle and inferior constrictors, the superior laryngeal artery and nerve perforate the thyro-hyoid membrane to supply the larynx.

The *superior constrictor* consists of pale muscular fibres, and *arises* from the hamular process of the sphenoid bone, and from the lower part of its internal pterygoid plate; from the tuberosity of the palate bone and the reflected tendon of the tensor palati; from the pterygo-maxillary ligament (which connects it with the buccinator); from the back part of the mylo-hyoid ridge of the lower jaw, and from the side of the tongue. The fibres pass backwards to the mesial raphé; some of them are *inserted* through the medium of the pharyngeal aponeurosis into the basilar process. Its nerve comes from the pharyngeal plexus.

The upper border of the superior constrictor presents, on either side, a free semilunar edge with its concavity upwards, so that, between it and the base of the skull, a space is left in which the muscle is deficient (Fig. 80). Here the pharynx is strengthened and walled in by its own aponeurosis. The space is called the *sinus of Morgagni*; and in it, with a little dissection, we expose the muscles which raise and tighten the soft palate, *i.e.*, the levator

palati and the tensor palati. The Eustachian tube opens into the pharynx just here. The fibres of the stylo-pharyngeus pass in between the superior and middle constrictors, and expand upon the side of the pharynx; some of them mingle with those of the constrictors, so as to be able to lift up the pharynx in deglutition; but

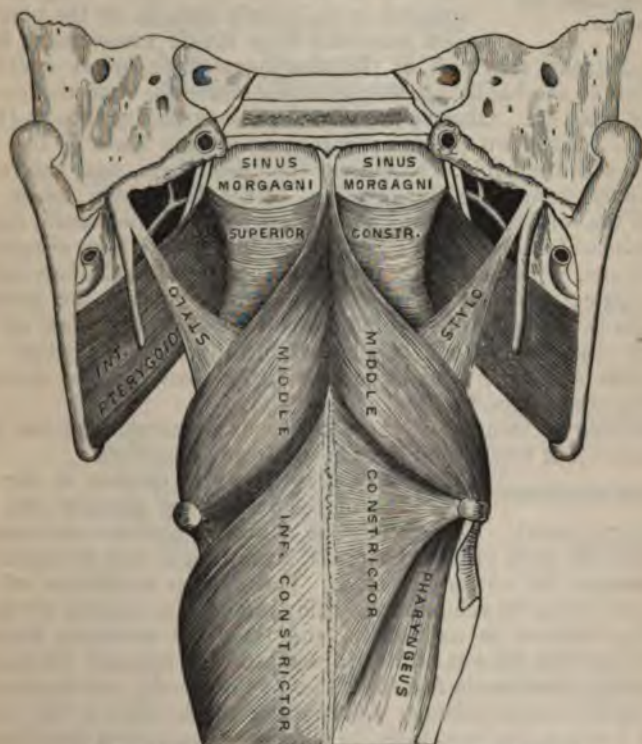


FIG. 80.—VIEW OF THE CONSTRICTOR MUSCLES FROM BEHIND.

most of them are inserted into the superior and posterior margins of the thyroid cartilage.

Pharyngeal
Aponeurosis.

The *pharyngeal aponeurosis* intervenes between the muscles and the mucous membrane of the pharynx. It is attached to the basilar process of the occipital bone, and to the points of the petrous portions of the temporal bones. It maintains the strength and integrity of the pharynx at its upper part, where the muscular fibres are deficient;

but it gradually diminishes in thickness as it descends, and is finally lost on the œsophagus. Notice the number of mucous glands upon this aponeurosis, especially near the base of the skull and the Eustachian tube. These glands sometimes enlarge and occasion deafness from the pressure on the tube.

Openings into the Pharynx.

Lay open the pharynx by a longitudinal incision in the middle line, up to the pharyngeal tubercle; then divide transversely, for a short distance, that part of the pharyngeal aponeurosis which is attached to the basilar process, so as the better to view the cavity of the pharynx. Observe the seven openings leading into it (Fig. 81): 1. The two posterior nares; below the nares is the soft palate, with the uvula. 2. On either side of them, near the lower turbinated bones, are the openings of the Eustachian tubes. 3. Below the soft palate is the communication with the mouth, called the isthmus faucium. On either side of this are two folds of mucous membrane, constituting the anterior and posterior half-arches of the palate; between them are the tonsils. Below the isthmus faucium is the epiglottis, which is connected to the base of the tongue by three folds of mucous membrane. 4. Below the epiglottis is the aperture of the larynx. 5. Lastly, is the opening into the œsophagus.*

The pharynx consists of three coats, viz., muscular, fibrous, and mucous. The two former have been already described.

Mucous Membrane. The *mucous membrane* is common to the entire tract of the respiratory passages and the alimentary canal. This membrane, however, presents varieties in the different parts of these channels, according as they are intended as passages for air or for food. The mucous membrane of the pharynx above the velum palati, being intended to transmit air only, is very delicate in its texture, and lined by columnar ciliated epithelium like the rest of the air-passages. But opposite the fauces, the mucous membrane resembles that of the mouth, and is provided with squamous epithelium. At the back of the larynx the membrane is corrugated into folds, to allow the expansion of the pharynx during the passage of the food.

The membrane is lubricated by a secretion from the numerous mucous glands which are situated in the submucous tissue throughout the whole extent of the pharynx, particularly in the neighbourhood of the Eustachian tubes.†

* On reflecting the mucous membrane at the pharyngeal termination of the Eustachian tube, a thin pale muscle, the *salpingo-pharyngeus*, can be made out. It arises by a thin tendon from the Eustachian tube, and joins the palato-pharyngeus. It is lost among the fibres of the constrictor muscles.

† This aggregation of mucous glands is called the pharyngeal tonsil.

Posterior Openings of the Nasal Fossæ. These are two oval openings, each of which is about an inch (2.5 cm.) in the long, and half an inch (13 mm.) in the short diameter. They are bounded above by the body of the sphenoid bone, exter-

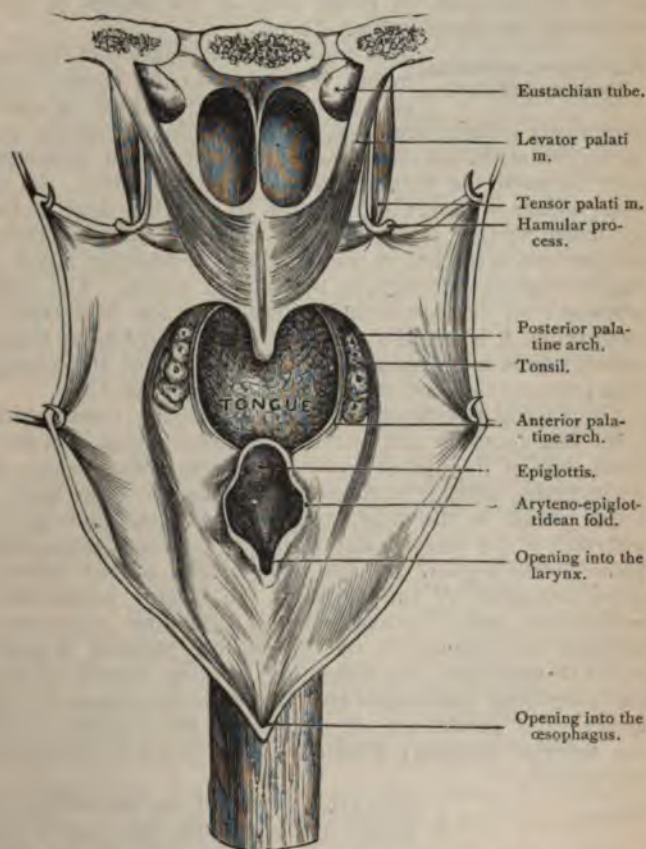


FIG. 81.—DIAGRAMMATIC VIEW OF THE PHARYNX LAID OPEN FROM BEHIND.

nally by its pterygoid plate, below by the horizontal portion of the palate bone; they are separated from each other by the vomer.

On removing the mucous membrane from the posterior part of the roof of the nose and the top of the pharynx, you will find

beneath it much fibrous tissue. Hence polypi growing from these parts are, generally, of a fibrous nature.

Isthmus Faucium. This name is given to the opening by which the mouth communicates with the pharynx. It is bounded above by the soft palate and uvula, below by the root of the tongue, and on either side by the arches of the palate, enclosing the tonsils between them.

Soft Palate, or Velum, Pendulum Palati. This moveable prolongation of the roof of the mouth is attached to the border of the hard palate, and laterally to the side of the pharynx.

Posteriorly it has a free edge, with a pendulous conical projection in the centre, called the *uvula*. It constitutes an imperfect partition between the mouth and the posterior nares. Its upper or nasal surface is convex and continuous with the floor of the nose; its lower surface is concave, in adaptation to the back of the tongue, and is marked in the middle by a ridge or raphé, indicating its original formation by two lateral halves. The soft palate, when at rest, hangs obliquely downwards and backwards; but in swallowing, it is raised to the horizontal position by the levatores palati, comes into apposition with the back of the pharynx, and thus prevents the food from passing through the nose.

On making a perpendicular section through the soft palate, you come first upon the oral mucous membrane; then you see that the great bulk of it is made up of *muciparous glands*, which lie thick on its under surface to lubricate the passage of the food. Above these glands is the thin layer of the palato-glossus, then the insertion of the tensor palati forming the broad aponeurosis of the palate; still higher, are the two portions of the palato-pharyngeus, separated by the fibres of the levator palati, the azygos uvulæ, and, lastly, the nasal mucous membrane. The soft palate is supplied with blood by the descending palatine branch of the internal maxillary, the ascending palatine branch of the facial, the ascending pharyngeal and the dorsales linguæ of the lingual artery. Its nerves are derived from the palatine branches of the superior maxillary division of the fifth and from the glosso-pharyngeal.

Uvula. The uvula projects from the middle of the soft palate, and gives the free edge of it the appearance of a double arch. It contains a number of muciparous glands, and a small muscle, the *azygos uvulæ*. Its length varies according to the state of its muscle. It occasionally becomes permanently elongated, and causes considerable irritation, a tickle in the throat, and harassing cough. When you have to remove a portion of it, cut off only the redundant mucous membrane.

Arches or Pillars of the Palate.

The *soft palate* is connected with the tongue and pharynx by two folds of mucous membrane on each side, enclosing muscular fibres. These are the *anterior* and *posterior arches* or *pillars* of the palate. The *anterior arch* describes a curve downwards and forwards, from the base of the uvula to the side of the tongue. It is well seen when the tongue is extruded. The *posterior arch*, commencing at the side of the uvula, curves downwards and backwards, along the free margin of the palate, and terminates on the side of the pharynx. The posterior arches, when the tongue is depressed, can be seen through the span of the anterior. The pillars of each side diverge from their origin, and in the triangular space thus formed is situated the tonsil. The chief use of the arches of the palate is to assist in deglutition. The anterior, enclosing the *palato-glossi* muscles, contract so as to prevent the food from coming back into the mouth; the posterior, enclosing the *palato-pharyngei*, contract like side curtains, and co-operate in preventing the food from passing into the nose. In vomiting, food does sometimes escape through the nostrils, but one cannot wonder at this, considering the violence with which it is driven into the pharynx.

Muscles of the Soft Palate.

The muscles of the soft palate lie immediately beneath the mucous membrane. There are five pairs—namely, the *levatores palati*, the *circumflexi* or *tensores palati*, the *palato-glossi*, the *palato-pharyngei*, and the *azygos uvulæ*. This last pair is sometimes described as a single muscle. To clean the muscles, the soft palate should be made tense by means of hooks, as they are severally dissected.

Levator Palati.

This muscle *arises* from the under aspect of the apex of the petrous portion of the temporal bone, and from the under part of the cartilage of the Eustachian tube. It descends obliquely inwards, and then passes over the concave border of the superior constrictor into the pharynx, where its fibres spread out and are *inserted* along the upper surface of the soft palate below the *azygos uvulæ*, meeting those of its fellow in the middle line (Fig. 81). Its action is to raise the soft palate, so as to make it horizontal in deglutition and in speaking preventing the nasal twang. It is supplied by the descending palatine branch from the sphenopalatine ganglion. (Fig. 82.)

Circumflexus or Tensor Palati.

This muscle is situated between the internal pterygoid m. and the internal pterygoid plate of the sphenoid bone. It *arises* by a flattened muscular belly from the scaphoid fossa, and from the spine of the sphenoid; from the outer and anterior side of the cartilage of the Eustachian tube. Thence it descends perpendicularly, and ends in a tendon which winds round the hamular process, where there

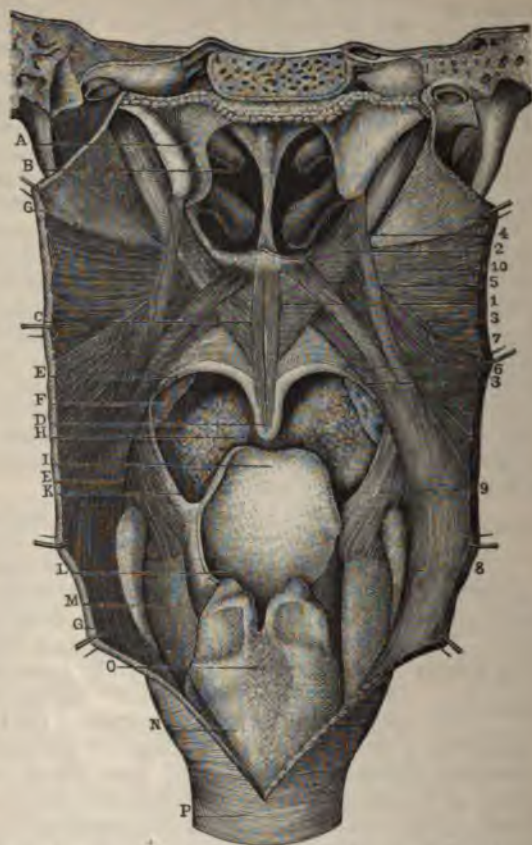


FIG. 82.—PHARYNX OPENED POSTERIORLY, SHOWING LARYNX, TONGUE, AND SOFT PALATE.

A. Cartilaginous expansion of the Eustachian tube. B. Posterior nasal openings. C. Soft palate. D. Uvula. E. Posterior pillar of the palate. F. Tonsil. G, G. Pharynx opening. H. Base of the tongue. I. Epiglottis. K. Left glosso-epiglottide. L. Superior opening of the larynx. M. Thyroid cartilage. N. Posterior surface of the larynx. O. Group of grape-like glands constantly found in these positions. P. Extremity of the esophagus. 1. Azygos uvulae muscle. 2. Levator palati muscle. 3. Palato-pharyngeus muscle. 4. Salpingo-pharyngeus muscle. 5. Internal pterygoid muscle. 6. Fibres proceeding from the middle of the palato-pharyngeus muscle. 7. Superior fibres of the palato-pharyngeus muscle going to interlace on the lateral and posterior surface of the pharynx with the opposite side. 8. Inferior fibres of the palato-pharyngeus muscle being inserted into the posterior margin of the thyroid cartilage near the base of the superior constrictor muscle. 9. Anterior fibres of the stylo-pharyngeus muscle at 1st, to the lateral fold of the epiglottis; 2d, to the superior cornu of the thyroid cartilage; 3d, to the base and superior margin. 10. Superior constrictor of the pharynx.

is a synovial bursa. Now changing its direction, the tendon passes horizontally inwards, and expands into a broad aponeurosis, which is *inserted* into the horizontal plate of the palate bone, and is also connected to its fellow of the opposite side. It gives strength to the soft palate. A synovial membrane facilitates the play of the tendon round the hamular process. Its *action* is to draw down and tighten the soft palate, and, owing to its insertion into the palate bone, also to keep the Eustachian tube open. Its nerve is derived from the otic ganglion, and enters the muscle on its inner aspect.

**Azygos or Levator
Uvulæ.**

This consists of two thin bundles of parallel muscular fibres situated one on each side of the middle line. It *arises* from the aponeurosis of the palate and descends along the uvula nearly down to its extremity. It receives its nerve from the descending palatine branch of the spheno-palatine ganglion.

**Palato-glossus and
Palato-pharyngeus.**

These muscles are contained within the arches of the soft palate, and the mucous membrane must be removed in order to expose them.

The *palato-glossus*, within the anterior arch, proceeds from the interior surface of the soft palate to the side of the tongue, and is lost in the stylo-glossus muscle. The *palato-pharyngeus*, within the posterior arch, arises from the posterior border of the soft palate by two origins, separated by the levator palati. As it descends its fibres spread out and, passing along the side of the pharynx, blend with the fibres of the inferior constrictor and the stylo-pharyngeus.

The action of the palato-glossus is to draw down the palate when the tongue is fixed; to elevate the sides of the tongue when the soft palate is fixed; both motions combined close this portion of the fauces, as is necessary in swallowing. Their separate action is called into play in speaking. The action of the palato-pharyngeus is to draw together the posterior pillars; to depress the palate when the pharynx is fixed; to elevate the pharynx when the palate is fixed. Both these muscles are supplied by the descending palatine branches of the spheno-palatine ganglion.

Tonsils. The tonsils are two glandular bodies, $\frac{1}{2}$ of an inch (13 mm.) long, $\frac{1}{3}$ of an inch (8 mm.) in width and thickness, situated at the entrance of the fauces, between the arches of the soft palate. They are rounded in shape, and their use is to lubricate the fauces during the passage of the food. On their inner surface are visible from twelve to fifteen orifices leading into crypts, which make the tonsil appear like the shell of an almond. Hence, as well as from their oval figure, they are called *amygdalæ*. (Fig. 83.)

These openings lead into small follicles in the substance of the

tonsil, lined by mucous membrane. Their walls are thick, and around them is a layer of closed cells (like Peyer's glands) situated in the submucous tissue. The fluid secreted by these cells is viscid and transparent, in the healthy state; but it is apt to become white and opaque in inflammatory affections of the tonsils, and occasionally accumulates in these superficial depressions, giving

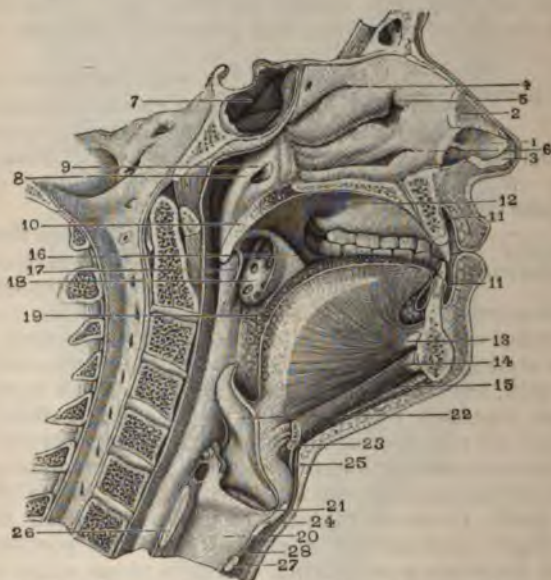


FIG. 83.—VERTICAL SECTION OF THE NASAL FOSSE AND MOUTH.

1. Left nares. 2. Lateral cartilage of the nose. 3. Portion of the internal alar cartilage forming the skeleton of the lower part. 4. Superior meatus. 5. Middle meatus. 6. Inferior meatus. 7. Sphenoidal sinuses. 8. External boundary of the posterior nares. 9. Internal elliptical opening of the Eustachian tube. 10. Soft palate. 11. Vestibule of the mouth. 12. Vault of the palate. 13. Genio-glossus muscle. 14. Genio-hyoid muscle. 15. Cut margin of the mylo-hyoid muscle. 16. Anterior pillar of the palate (ant. half-arch), presenting a triangular figure with the base inferiorly, covering partly the tonsil. 17. Posterior pillar (post. half-arch) of the palate. 18. Tonsil. 19. Follicular (mucous) glands at the base of the tongue. 20. Cavity of the larynx. 21. Ventricle of the larynx. 22. Epiglottis. 23. Cut os hyoides. 24. Cut thyroid cartilage. 25. Thyro-hyoid membrane. 26. Section of posterior portion of the cricoid cartilage. 27. Section of the anterior portion of the same cartilage. 28. Crico-thyroid membrane.

rise to the deceptive appearance of a small ulcer, or a slough, or even a false membrane on the part.

The tonsil lies close to the inner side of the internal carotid artery. It is only separated from this vessel by the ascending pharyngeal artery, the superior constrictor, and the aponeurosis of

the pharynx. Therefore, in removing a portion of the tonsil, or in opening an abscess near it, the point of the instrument should never be directed outwards, but *inwards* towards the mesial line.* The tonsil is supplied with blood by the tonsillar and palatine branches of the facial, and by the descending palatine branch of the internal maxillary. Nerves are furnished to it from the glosso-pharyngeal and from Meckel's ganglion.

Eustachian Tube. This canal conveys air from the pharynx to the tympanum. Its orifice is situated opposite the back part of the inferior turbinated bone. The direction of the tube from the pharynx is upwards, backwards, and outwards; it is an inch and a half (*3.8 cm.*) long. The narrowest part is about the middle, and here its walls are in contact. Near the tympanum its walls are osseous, but towards the pharynx they are composed of fibro-cartilage and fibrous membrane. The cartilaginous end, about an inch (*2.5 cm.*) in length, projects between the origins of the levator and the tensor palati, and gives attachment to some of their fibres, and also some of the palato-pharyngeus, now called the salpingo-pharyngeus. It is situated at the base of the skull, in the furrow between the petrous portion of the temporal and the great wing of the sphenoid bone. It adheres closely to the bony furrow, as well as to the fibro-cartilage filling up the foramen lacerum medium. The orifice is not trumpet-shaped, as usually described, but an elliptical slit about half an inch (*13 mm.*) long, and nearly perpendicular. The fibro-cartilage bounds it only on the inner and upper part of the circumference; the integrity of the canal below is maintained by tough fibrous membrane.

The Eustachian tube is lined by a continuation of the mucous membrane of the pharynx, and covered by ciliated epithelium. That which lines the cartilaginous portion of the tube is thick and vascular, and gradually becomes thinner towards the tympanum. Hence, inflammatory affections of the throat or tonsils are liable to be attended with deafness, from temporary obstruction of the tube.

Mucous glands surround the orifice of the tube, and are similar in nature and function to the glands beneath the mucous membrane of the mouth, the palate, and the pharynx.

*Cases are related by Portal and Béclard, in which the carotid artery was punctured in opening an abscess in the tonsil. The result was immediately fatal hemorrhage. It should, however, be borne in mind that the artery usually injured is the tonsillar branch of the facial artery, and not the internal carotid. The surgical treatment of this accident is therefore ligature of the external carotid artery between its superior thyroid and lingual branches, and not ligature of the common carotid artery, as is often recommended.

Hard Palate. The hard palate, formed by the superior maxillary and palate bones, is a resisting surface for the tongue in tasting, in mastication, in deglutition, and in the articulation of sounds. The tissue covering the bones is thick and close in texture, and firmly united to the asperities on the bones. But it is not everywhere of equal thickness. Along the raphé in the mesial line it is much thinner than at the sides; for this reason, the hard palate is in this situation more prone to be perforated in syphilitic disease.

A thick layer of glands (*glandulæ palatineæ*) is arranged in rows on either side of the hard palate. These glands become more numerous and larger towards the soft palate. Their orifices are visible to the naked eye. The mucous membrane has a very thick epithelial coat, which gives the white colour to the palate. The descending palatine branch of the internal maxillary artery, and the palatine nerves from the superior maxillary, may be traced along each side of the roof of the mouth. The ramifications of these arteries and nerves supply the soft as well as the hard palate.

Mechanism of Deglutition. With the anatomy of the parts fresh in your mind, consider for a moment the mechanism of deglutition. The food, duly masticated, is collected into a mass upon the back of the tongue; the lower jaw is then closed to give a fixed point for the action of the muscles which raise the os hyoides and larynx, and the food is carried back into the pharynx by the pressure of the tongue against the palate, at the same time that the pharynx is elevated and expanded to receive it (by the stylo-pharyngei on each side).* The food, having reached the pharynx, is prevented from ascending into the nasal passages by the approximation of the posterior palatine arches and the elevation of the soft palate, which thus forms a horizontal temporary roof to the pharynx; it is prevented from returning into the mouth by the pressure of the retracted tongue and the contraction of the anterior palatine arches: it cannot enter the larynx, because its upper opening is closed and protected by the falling of the epiglottis: † consequently, being forcibly compressed by the constrictors of the pharynx, the food passes into the œsophagus, through which it is conveyed into the stomach by the undulatory contraction of that tube.

The food passes with different degrees of rapidity through the

* The larynx being also elevated and drawn forwards, a greater space is thus left between it and the vertebræ for the distention of the pharynx.

† This falling of the epiglottis is effected, not by special muscular agency, but by the simultaneous elevation of the larynx and the retraction of the tongue. A perpendicular section through all the parts concerned is necessary to show the working of this mechanism.

different parts of its course ; but most rapidly through the pharynx. The necessity of this is obvious, as the air-tube must be closed while the food passes over it, and the closure produces a temporary interruption to respiration. The progress of the food through the cesophagus is slow and gradual.

DISSECTION OF THE LARYNX.

The larynx is the upper dilated part of the windpipe, in which phonation takes place. It consists of numerous cartilages articulated together to form an open tube, and to protect the delicate structures concerned in vocalisation.

It forms a prominence in the middle line of the neck, covered in front by the integument and cervical fasciæ, the sterno-hyoid, sterno-thyroid, and thyro-hyoid muscles, and the thyroid body. It has the large vessels of the neck on each side. Above, it is attached to the hyoid bone ; below, it is continuous with the trachea ; behind it is the pharynx, into the anterior part of which it opens.

Before commencing the dissection of the larynx the student should make himself acquainted with the cartilages which compose it and the ligaments which connect them, as seen in a dry preparation.

Os Hyoides.

This bone, named from its resemblance to the Greek Upsilon, is situated between the larynx and the tongue, and serves for the attachment of the muscles of the tongue. It may be felt immediately below, and one inch and a half (3.8 cm.) behind, the symphysis of the jaw. It is arched in shape, and consists of a body, two greater and two lesser cornua. The *body* (*basi-hyal*) is the thick central portion. Its anterior surface is convex and has a median vertical ridge, on each side of which are depressions for the attachments of muscles ; its posterior surface is smooth, deeply concave, and corresponds to the epiglottis. The *greater cornua* (*thyro-hyals*), right and left, project backwards for about an inch and a half (3.8 cm.), with a slight inclination upwards, and terminate in blunt ends tipped with cartilage. In young subjects they are connected to the body of the bone by fibro-cartilage ; this, in process of years, becomes ossified. The *lesser cornua* (*cerato-hyals*) are connected, one on each side, to the point of junction between the body and the greater cornua, by means of a little joint lined with synovial membrane, which admits of free motion. They are of the size of a barley-corn, and give attachment to the stylo-hyoid ligaments (Fig. 84).

Ligaments.

a quantity of elastic tissue. There is: 1. The *thyro-hyoid membrane*, a broad fibrous

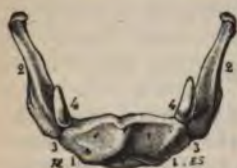

FIG. 84.—ANTERIOR VIEW OF OS HYOIDES.

1, 1. Anterior or convex surface of the body. 2, 2. Greater cornua. 3, 3. Articulation of the greater cornua with the body. 4, 4. Lesser cornua.

small nodule of cartilage (*corpus triticeum*).

Cartilages of the Larynx.

The framework of the larynx is composed of nine cartilages, viz., the thyroid, the cricoid, the two arytenoid, the two cornicula laryngis, the two cuneiform cartilages, and the epiglottis. These are connected by joints and elastic ligaments, so that they can be moved upon each other by their respective muscles; the object of this motion being to act upon two elastic ligaments, called the *vocal cords* or *bands*, upon the vibration of which phonation depends.

Thyroid Cartilage.

This cartilage, so called because it shields the mechanism behind it, consists of two lateral halves (*ala*), united at an acute angle in front, which forms the prominence termed the *pomum Adami*. This prominence presents a notch at its upper part, to allow it to play behind the os hyoides in deglutition. There is a bursa in front of it. Each ala is somewhat quadrilateral in form, and presents for examination two surfaces and four borders. The *outer surface* of each ala is marked by an oblique line passing downwards and forwards from the base of the upper cornu, which gives attachment to the sterno-thyroid and thyro-hyoid muscles. The smooth surface behind the ridge gives attachment to the inferior constrictor. The *inner surface* is smooth, slightly concave, and is covered with mucous membrane. In the acute angle in front there are attached from above downwards the epiglottis, the false or ventricular bands, and true vocal cords or bands, the thyro-arytenoidei and thyro-epiglottidei muscles. The *inferior* border is slightly arched in the middle, affording attachment to the crico-thyroid membrane, and on either side pro-

The os hyoides is connected with the thyroid cartilage by several ligaments, which contain a quantity of elastic tissue. There is: 1. The *thyro-hyoid membrane*, which proceeds from the superior border of the thyroid cartilage to the upper and posterior part of the hyoid bone. In front of this membrane there is a bursa, of which the use is to facilitate the play of the thyroid cartilage behind the os hyoides. The central portion is stronger than the lateral, and is called the *anterior thyro-hyoid ligament*. Through the lateral part of this membrane the superior laryngeal nerve and artery enter the larynx. 2. The right and left *lateral thyro-hyoid ligaments* extend between the extremities of the greater cornua of the os hyoides and the ascending cornua of the thyroid cartilage. They contain a

The framework of the larynx is composed of nine cartilages, viz., the thyroid, the cricoid, the two arytenoid, the two cornicula laryngis,

the two cuneiform cartilages, and the epiglottis. These are connected by joints and elastic ligaments, so that they can be moved upon each other by their respective muscles; the object of this motion being to act upon two elastic ligaments, called the *vocal cords* or *bands*, upon the vibration of which phonation depends.

This cartilage, so called because it shields the mechanism behind it, consists of two lateral halves (*ala*), united at an acute angle in front, which forms the prominence termed the *pomum Adami*. This prominence presents a notch at its upper part, to allow it to play behind the os hyoides in deglutition. There is a bursa in front of it. Each ala is somewhat quadrilateral in form, and presents for examination two surfaces and four borders. The *outer surface* of each ala is marked by an oblique line passing downwards and forwards from the base of the upper cornu, which gives attachment to the sterno-thyroid and thyro-hyoid muscles. The smooth surface behind the ridge gives attachment to the inferior constrictor. The *inner surface* is smooth, slightly concave, and is covered with mucous membrane. In the acute angle in front there are attached from above downwards the epiglottis, the false or ventricular bands, and true vocal cords or bands, the thyro-arytenoidei and thyro-epiglottidei muscles. The *inferior* border is slightly arched in the middle, affording attachment to the crico-thyroid membrane, and on either side pro-

sents a convex prominence, which gives attachment to the crico-thyroid muscle and the crico-thyroid membrane. The *superior* border is nearly horizontal, and affords attachment to the thyro-hyoid membrane. The *posterior* border is thick, rounded, and nearly vertical, and gives insertion to the stylo-pharyngeus and palato-pharyngeus muscles. This border terminates, above and below, in round projections called the *upper* and *lower cornua*. The upper is the longer; the lower articulates with the side of the cricoid cartilage (Figs. 85, 86).

Cricoid Cartilage. This cartilage, named from its resemblance to a ring, is situated below the thyroid. It is not of equal depth all round. It is narrow in front, where it may be felt about a quarter of an inch (6 mm.) below the thyroid; from this part, the upper border gradually rises, so that, posteriorly, the ring is an inch (2.5 cm.) in vertical depth, and occupies part of the interval left between the alæ of the thyroid. In the middle of this broad posterior surface is a vertical ridge, on either side of which observe a superficial excavation for the origin of the crico-arytenoidei postici: to the lower part of the vertical ridge are attached some of the longitudinal fibres of the œsophagus. On its *upper* part are two oval slightly convex surfaces for the articulation of the arytenoid cartilages, between which is a concavity for the attachment of the arytenoideus. In front, its upper border presents a broad excavation to which the crico-thyroid membrane (on which is seen the crico-thyroid artery), is attached. On its *outer* surface, external to the depression for the crico-arytenoideus posticus, is an elevated facet which articulates with the inferior cornu of the thyroid cartilage. In front of this articular surface it gives attachment to the inferior constrictor of the pharynx. The *lower* border is straight, and is connected by fibrous membrane to the first ring of the trachea. The *inner* surface is smooth, and the upper border is elliptical, its lower being nearly circular. (Figs. 85-86.)

Ligaments.

The thyroid cartilage is connected to the cricoid by a membrane—the *crico-thyroid*. It consists of a median triangular portion, composed mainly of elastic tissue, with its base directed downwards. The lateral portions are thin and membranous, extending as far backwards as the articular facets for the thyroid cartilage, and are intimately connected with the inferior vocal cords or vocal bands. Between the inferior cornu of the thyroid cartilage and the cricoid there is a distinct joint, having a synovial membrane, and strengthened by a *capsular ligament*. The articulation allows of a movement revolving upon its own axis, and, consequently, permits the approximation of the two cartilages. (Fig. 86.)

Arytenoid Cartilages. These cartilages are situated, one on each side, at the back of the upper border of the cricoid cartilage. In the recent state, before the membranes and muscles have been removed, the space between them resembles the lip of a

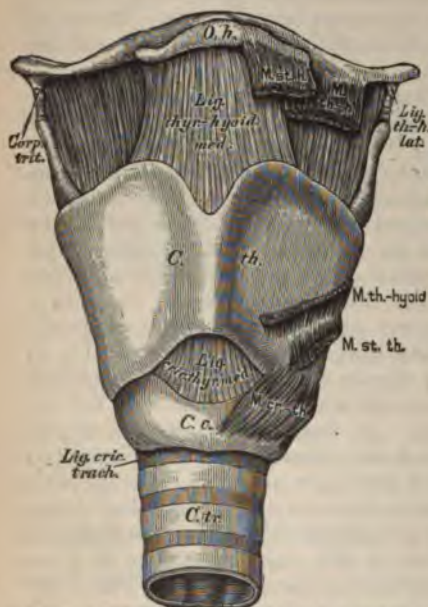


FIG. 85.—LARYNX, FRONT VIEW, WITH THE LIGAMENTS AND INSERTION OF MUSCLES.

O. h., Os hyoides; *C. th.*, Thyroid cartilage; *Corp. trit.*, Corpus triticeum; *C. c.*, Cricoid cartilage; *C. tr.*, Tracheal cartilage; *Lig. thyr-hyoid med.*, Middle thyro-hyoid ligament; *Lig. th-h. lat.*, Lateral thyro-hyoid ligament; *Lig. cric-thyr med.*, Middle crico-thyroid ligament; *Lig. cric-trach.*, Crico-tracheal ligament; *M. st-h.*, Sterno-hyoideus muscle; *M. th-hyoid.*, Thyro-hyoideus muscle; *M. st-th.*, Sterno-thyroides muscle. *M. cr-th.*, Crico-thyroides muscle.

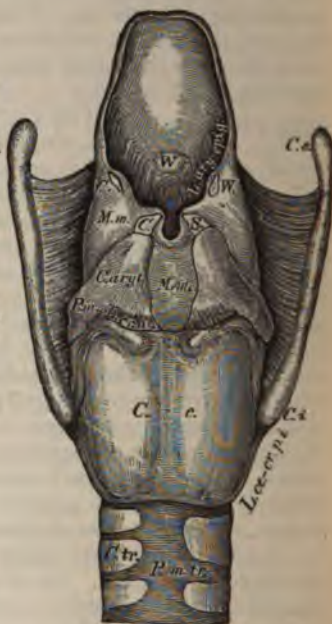


FIG. 86.—POSTERIOR VIEW OF THE LARYNX, WITH THE MUSCLES REMOVED.

E., Epiglottis cushion (*W.*); *L. ar-ep.*, Aryteno-epiglottic fold or ligament; *M. m.*, Membrana mucosa; *C. W.*, Cartilage of Wisberg or cuneiform; *C. S.*, Cartilage of Santorini or cornicula laryngis; *C. aryt.*, Arytenoid cartilage; *C. c.*, Cricoid cartilage; *P. m.*, Muscular process or external angle; *L. cr-ar.*, Crico-arytenoid ligament; *C. s.*, Superior cornu; *C. i.*, Inferior cornu of the thyroid cartilage; *L. cr-p. i.*, Posterior inferior cerato-cricoid ligament; *C. tr.*, Tracheal cartilage; *P. m. tr.*, Membranous portion of the trachea.

pitcher; hence their name. Each is pyramidal, with the apex upwards, is about one-half of an inch (13 mm.) in height, and one-quarter of an inch (6 mm.) in diameter at its base, and presents for examination three surfaces (marked off by three borders), a base

and an apex. The *posterior* surface of each is triangular and concave, and gives attachment to the arytenoideus muscle; the *anterior* surface is irregular and convex, affording attachment to the thyroarytenoideus, and to the ventricular bands or false vocal cord; the *internal* surface, the narrowest and nearly flat, faces the corresponding surface of the opposite cartilage, and is covered with mucous membrane. The *base* is broad, and presents a smooth, somewhat concave, triangular surface which articulates with the cricoid cartilage; in front of the base is the pointed *anterior angle*, which gives attachment to the true vocal cord or vocal bands, and contributes to form part of the boundary of the rima glottidis; at the outer and back part of the base is the *external angle*, into which certain muscles moving the cartilage are inserted, viz., the crico-arytenoideus posticus and crico-arytenoideus lateralis. The base is articulated with the cricoid by a joint which has a loose capsular ligament and a synovial membrane, permitting motion in all directions, like the first joint of the thumb. The *apex* is truncated and points backwards and inwards. It is surmounted by a cartilaginous nodule, called the *corniculum laryngis*.

Cornicula Laryngis. Are two small conical cartilaginous nodules, and continue the direction of the arytenoid cartilages upwards and inwards.

Cuneiform Cartilages. These cartilages, sometimes called the cartilages of Wrisberg, are conical in form, and somewhat curved, with their broader part directed upwards and forwards. They are contained in the aryteno-epiglottic fold. (Fig. 86.)

Epiglottis. This piece of yellow fibro-cartilage is situated in the middle line, and projects over the larynx like a valve. It is like a leaf with its stalk directed downwards. Its ordinary position is perpendicular, leaving the upper opening of the larynx free for respiration; but during the elevation of the larynx in deglutition it becomes horizontal, falls downwards and backwards over the larynx, and prevents the entrance of food into it. This descent of the epiglottis is accomplished, not by special muscular agency, but by the simultaneous elevation of the larynx and the retraction of the tongue. Its *apex* or lower part is attached by the *thyro-epiglottic ligament* to the angle of the thyroid cartilage; it is also connected by an elastic ligament, *hypo-epiglottic*, to the posterior surface of the os hyoides. *Laterally*, its borders are rather turned backwards, and to them are attached two folds of mucous membrane, which pass to the arytenoid cartilages, called the *aryteno-epiglottic folds*. Its *anterior surface* is only free at its base, where it is connected with the base of the tongue by the three *glosso-epiglottic folds*. Its *posterior or laryngeal surface* is smooth, concavo-convex and free, and looks towards the larynx. The surface of the

epiglottis is closely invested by mucous membrane; this being removed, the yellow cartilage of the epiglottis is seen pitted and often perforated by the small mucous glands.

The cartilages of the larynx resemble those of the ribs in structure. In the young they are dense and elastic, but some have a tendency to ossify with age. In very old subjects the thyroid and cricoid cartilages are often completely ossified, and their interior presents an areolar tissue, containing oily matter, analogous to the spongy texture of the bones. The epiglottis, cornicula laryngis, and cuneiform cartilages are rarely ossified, on account of their consisting of yellow fibro-cartilage resembling that of the ear and nose.

The larynx must now be examined in its perfect condition.

**Mucous Membrane
of the Larynx.**

The mucous membrane lines the whole of the interior of the larynx, being continuous above with that of the pharynx and mouth, below with that of the trachea. It is intimately adherent to the posterior part of the epiglottis and to the true vocal bands or cords; elsewhere it is loosely connected to the subjacent structures by an abundance of areolar tissue, which admits of its being elevated into large folds. This is chiefly found about the upper opening of the larynx, and it deserves notice from the rapidity with which it becomes the seat of serous effusion in acute inflammation of the larynx, and thus produces symptoms of suffocation. In the remaining part of the interior of the larynx the mucous membrane is moderately adherent to the subjacent tissues, and at the ventricular band or false vocal cord it reduplicates upon itself and then lines the sacculus laryngis. Naturally, the mucous membrane is of pale rose colour, except where it covers the cushion of the epiglottis, where it is bright pink. It is covered by columnar ciliated epithelium below the ventricular bands or false vocal cords, and this variety is continued up the epiglottis as high as its middle; above this, by squamous epithelium. From the root of the tongue to the anterior surface of the epiglottis, the membrane forms three folds, *glosso-epiglottic*, one median and two lateral, containing elastic tissue. From the epiglottis, to which it is intimately adherent, it is continued backwards on either side to the apices of the arytenoid cartilages, forming the *aryteno-epiglottic folds* which bound the upper entrance into the larynx.

The mucous membrane of the larynx is remarkable for its acute sensibility. This is requisite to guard the upper opening of the larynx during the passage of the food over it. The larynx is closed during the act of deglutition; but if, during this process, anyone attempt to speak or laugh, the epiglottis is raised, and allows the food to pass, as it is termed, the wrong way. As soon as the for-

eign body touches the mucous membrane of the larynx a spasmodic fit of coughing expels it.

The sub-mucous tissue of the larynx is studded with mucous glands. An oblong mass of them lies in the aryteno-epiglottic fold, and they are particularly numerous about the ventricles of the larynx. The surface of the epiglottis towards the tongue is abundantly provided with them. Their ducts pass through the epiglottis, and may be recognised as minute openings on its laryngeal aspect.

Superior Opening of the Larynx. This is the opening through which the larynx communicates with the pharynx. Its outline is triangular, with its base directed forwards, and it slopes from before backwards. Anteriorly it is bounded by the epiglottis, laterally by the aryteno-epiglottic folds and cuneiform cartilages, posteriorly by the arytenoid cartilages and the cornicula laryngis. The apex presents the funnel-shaped appearance from which the arytenoid cartilages derive their name.

On looking down through this superior opening you see the *cavity of the larynx*, which is divided into an upper and a lower part by the narrow triangular fissure, called the *glottis*, or *rima glottidis*; so that the upper part gradually narrows to this chink, while the lower part gradually widens and becomes continuous at the lower border of the cricoid cartilage with the trachea.

The objects seen above the *rima glottidis* are, in the middle line, below the base of the epiglottis, a round elevation covered with mucous membrane of a bright pink colour, termed the *cushion* of the epiglottis; on each side is an arched fold, the *ventricular bands* or *false vocal cords*, with their concavity looking downwards, and forming the upper boundary of a small recess, the *ventricle of the larynx*, leading into a pouch, called the *sacculus laryngis*; below this are the two white bands, the *vocal bands* or *true vocal cords*, which form the boundaries of the glottis. The larynx below the vocal bands gradually enlarges and presents nothing calling for special description.

Glottis, or Rima Glottidis.

The *rima glottidis* is the triangular horizontal opening between the vocal bands. Its apex is directed forwards, its base backwards. The anterior two-thirds of this opening is bounded by the vocal bands, the posterior third by the arytenoid cartilages. The length in the male is nearly an inch (24 mm.), its width at rest from one-fourth to one-third of an inch (6 to 8 mm.); in the female its length is two-thirds of an inch (16 mm.); its width one-sixth of an inch (4 mm.). Before the age of puberty these dimensions are much less.

Ventricular Bands.

These are the prominent crescentic folds of mucous membrane which form the upper boundaries of the ventricles and inclose within them thin ligamentous

fibres, called the *superior thyro-arytenoid ligaments*. They are called the *false vocal cords* because they have little or nothing to do with the production of the voice. They are composed of elastic tissue like the vocal bands; but they also contain fatty tissue, which the vocal bands do not.

Vocal Bands.*

These two bands, called also the *inferior thyro-arytenoid ligaments*, are composed of yellow elastic tissue, and extend horizontally from the angle of the thyroid cartilage to the anterior angles of the base of the arytenoid cartilages. Their inner or free edges are thin and sharp and look upwards; their outer borders are continuous with the crico-thyroid

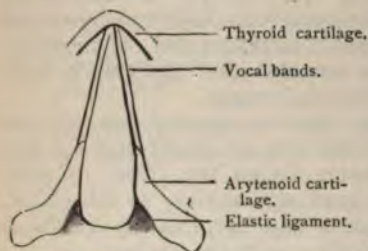


FIG. 87.—SHAPE OF THE GLOTTIS WHEN AT REST.

membrane, and are in contact with the thyro-arytenoidei muscles. They diverge as they pass backwards, and are covered with very thin and closely adherent mucous membrane, having columnar ciliated epithelium. We shall presently see that, by the muscles which act upon the arytenoid cartilages, these bands can be approximated or separated from each other; in other words, the rima glottidis can be

closed or dilated. When sufficiently tightened, and brought parallel by means of certain muscles, the bands are made to vibrate by the current of the expired air, and thus is produced sound.

In the adult male the vocal bands measure about seven-twelfths of an inch ($1\frac{1}{2}$ mm.); in the female about five-twelfths of an inch ($1\frac{1}{3}$ mm.). In boys they are shorter; hence their peculiar voice. At puberty the bands lengthen and the voice breaks.

The glottis admits of being dilated, contracted, and even completely closed, by its appropriate muscles. When at rest its shape is triangular, as shown in Fig. 87, where the arytenoid cartilages are cut through on a level with the vocal cords. During every inspiration the glottis is dilated by the crico-arytenoidei postici; it then becomes pear-shaped (Fig. 90). During expiration it resumes its triangular shape, and this return to a state of rest is effected, not by muscular agency, but by two elastic ligaments shown in Fig. 87, which draw the arytenoid cartilages together.

[* The editor desires to emphasize the change of cord to band, false vocal to ventricular, for anatomical reasons which to any dissector are apparent. Ventricular band locates the position and does away with the explanation that this portion has nothing to do with phonation. A. H.]

Thus, then, the glottis, like the chest, is dilated by *muscular* tissue; like the chest, also, it is contracted by *elastic* tissue. In speaking or singing the glottis assumes what is called the vocalising position—that is, the opening becomes narrower, and its edges nearly parallel.

Ventricles of the Larynx.

These are the recesses between the ventricular and vocal bands, and each leads to a small conical pouch, the *sacculus laryngis*. Each

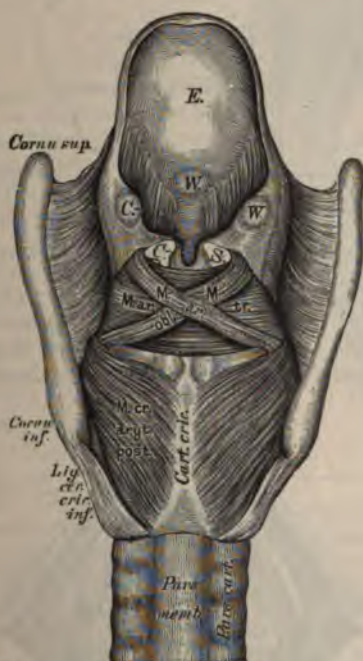

FIG. 83.—POSTERIOR VIEW OF THE LARYNX, WITH ITS MUSCLES.

E., Epiglottis, with the cushion (*W.*); *C. W.*, Cartilage of Wrisberg; *C. S.*, Cartilage of Santorini; *Cart. cric.*, Cricoid cartilage; *Cornu sup.*, Superior cornua of the thyroid cartilage; *M. ar. tr.*, Transverse portion of the arytenoid; *Mm. ar. obl.*, Oblique portion of the arytenoid; *M. cr. aryt. post.*, Crico-arytenoid muscle; *Pars memb.*, Tracheal membrane.

ascends for about half an inch (*13 mm.*), as high as the upper border of the thyroid cartilage, which bounds it on its outer side, while on the inner side is the ventricular band. It contains from sixty to seventy muciparous glands. Over its inner and upper part is a layer of muscular tissue, *compressor sacculi laryngis* of Hilton

(aryteno-epiglottideus inferior), which connects it with the aryteno-epiglottic fold; on its outer side is the upper part of the thyro-arytenoideus.

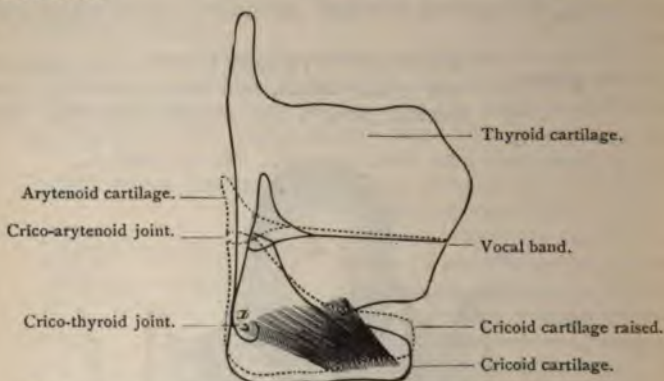


FIG. 89.—DIAGRAM SHOWING THE ACTION OF THE CRICO-THYROID MUSCLE.

Intrinsic Muscles of the Larynx.

There are eleven muscles which act upon the larynx, five on each side and one in the middle. The five pairs are the crico-thyroidi, the crico-arytenoidei postici, the crico-arytenoidei laterales, the

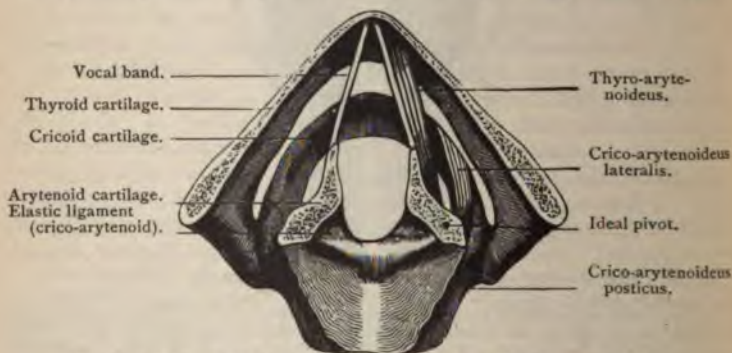


FIG. 90.—GLOTTIS DILATED: MUSCLES DILATING IT REPRESENTED WAVY.

thyro-arytenoidei, and the aryteno-epiglottidei. The single one is the arytenoideus.

M. Crico-thyroides. This muscle is situated on the front of the larynx. It *arises* from the front and side of the cricoid cartilage, ascends obliquely outwards, and is *inserted*

into the inferior border and lower cornu of the thyroid. Its *action* is to tighten the vocal cords. It does this by raising the anterior part of the cricoid cartilage, since this cartilage cannot be raised without lengthening these cords, as shown by the dotted line, Fig. 89. Its nerve is the *external laryngeal* branch of the superior laryngeal. Between the anterior borders of the two muscles is seen the crico-thyroid membrane, which is divided in laryngotomy.

M. Crico-arytenoideus Posticus.

This muscle *arises* from the broad depression on the posterior part of the cricoid cartilage; its fibres converge and pass outwards and upwards, to be *inserted* into the outer angle of the base of the arytenoid (Fig. 88). Its *action* is to dilate the glottis. It does this by drawing the posterior tubercle of the arytenoid cartilage *towards* the mesial line, and therefore the anterior angle (to which the vocal cord is attached) *from* the mesial line (Fig. 90). In this movement the arytenoid cartilage rotates as upon a pivot, and acts as a lever of the first order, the fulcrum or ideal pivot being intermediate between the power and the weight. This muscle dilates the glottis at each inspiration. Its nerve comes from the inferior laryngeal.

M. Arytenoideus.

This single muscle is situated immediately at the back of the arytenoid cartilages. The fibres pass across from one cartilage to the other, running in a transverse direction. *Action*.—By approximating the arytenoid cartilages, they assist in contracting the glottis. It is supplied by the inferior laryngeal nerve.

M. Aryteno-epiglottideus.

This muscle *arises* from the inferior and outer angle of the arytenoid cartilage, and, crossing its fellow like the letter X, is *inserted* partly into the apex of the opposite arytenoid cartilage and partly into

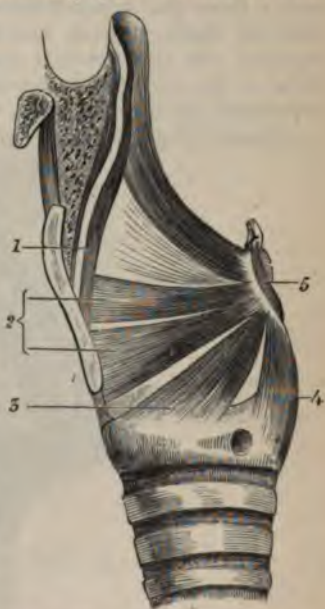

FIG. 91.—SIDE VIEW OF THE MUSCLES OF THE LARYNX.

1. Thyro-epiglottideus. 2. Thyro-arytenoideus, upper and lower portions. 3. Crico-arytenoideus lateralis. 4. Crico-arytenoideus posticus. 5. Arytenoideus.

the aryteno-epiglottic fold. This is sometimes spoken of as part of the arytenoideus.

M. Crico-arytenoideus Lateralis.

To expose this muscle reflect the crico-thyroid muscle, the crico-thyroid membrane, and then cut away the ala of the thyroid cartilage. It *arises* from the upper border of the side of the cricoid cartilage, and the fibres, passing backwards and upwards, converge to be *inserted* into the external angle of the base of the arytenoid, in front of the crico-arytenoideus posticus. *Action*.—By drawing the arytenoid cartilages inwards, the muscles of opposite sides contract the glottis (Fig. 92). Its nerve comes from the inferior laryngeal.

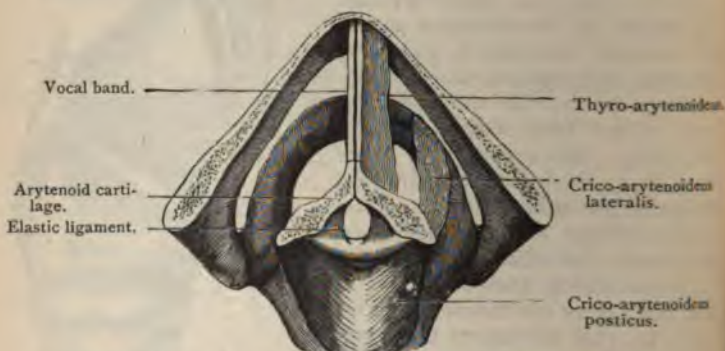

FIG. 92.—GLOTTIS CLOSED: MUSCLES CLOSING IT REPRESENTED WAVY.

M. Thyro-arytenoideus.

This muscle *arises* from the side of the angle of the thyroid cartilage and the crico-thyroid membrane, runs horizontally backwards, and is *inserted* into the base and anterior surface of the arytenoid. Its fibres run parallel with the true vocal cord, and some of them are directly inserted into it. It consists of two fasciculi—an upper and a lower. The *lower* and larger portion is inserted into the anterior angle and the anterior surface of the arytenoid; the *upper* is inserted into the upper part of the anterior surface and the anterior border of the arytenoid. Its nerve comes from the inferior laryngeal (Fig. 93).

This muscle relaxes the vocal cord. More than this, it puts the lip of the glottis in the vocalising position; in this position the margins of the glottis are parallel, and the chink is reduced to the breadth of a shilling.

The following table shows the action of the several muscles which act upon the glottis:—

Crico-thyroidei,	Stretch the vocal bands.
Thyro-arytenoidei,	Relax the vocal bands, and place them in the vocalising position.
Crico-arytenoidei postici,	Dilate the glottis.

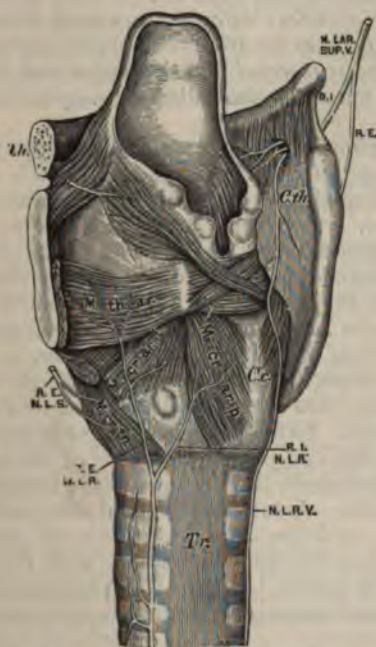


FIG. 93.—NERVES OF THE LARYNX.

O. A., Os hyoides; C. th., Thyroid cartilage; C. C., Cricoid cartilage; Tr., Trachea; M. th. ar., Thyro-arytenoideus muscle; M. cr. ar. p., Posterior crico-arytenoideus muscle; M. cr. ar. l., Lateral crico-arytenoideus muscle; M. cr. th., Crico-thyroideus muscle; N. lar. sup. v., Superior laryngeal nerve; R. I., Internal branch; R. E., External branch; N. L. R. V., Recurrent laryngeal nerve; R. I. N. L. R., Internal branch of the recurrent nerve; R. E. N. L. R., External branch of the recurrent laryngeal nerve.

Crico-arytenoidei laterales,	Draw together the arytenoid cartilages	} close the glottis.
Arytenoideus,	Ditto ditto ditto	
Aryteno-epiglottidei,	Contract the upper opening of the larynx.	

The epiglottis is connected by muscles with the arytenoid and thyroid cartilages: they are the thyro-epiglottideus, the aryteno-epiglottideus superior and inferior.

The *thyro-epiglottideus* is a thin muscle, arising from the angle of the thyroid cartilage just above the thyro-arytenoideus, and is inserted by diverging fibres into the border of the epiglottis and into the aryteno-epiglottic fold.

The *aryteno-epiglottideus superior* passes as thin muscular fibres from the tip of the arytenoid cartilage to the mucous membrane attached to the side of the epiglottis.

The *aryteno-epiglottideus inferior*, separated from the preceding by a distant interval, arises from the anterior surface of the arytenoid cartilage, and is inserted into the upper and inner part of the epiglottis. This muscle is also called the *compressor sacculi laryngis* of Hilton.*

The *blood-vessels of the larynx* are derived from the *superior* and *inferior thyroid arteries*. The laryngeal branch of the superior thyroid passes through the thyro-hyoid membrane with the corresponding nerve, and divides into branches, which supply the muscles and the mucous membrane. The laryngeal branches of the inferior thyroid ascend behind the cricoid cartilage. A constant little artery passes through the crico-thyroid membrane.

The *nerves of the larynx* are the *superior* and *inferior (recurrent) laryngeal* branches of the pneumogastric. (Fig. 93.)

The *superior laryngeal*, having passed through the thyro-hyoid membrane, divides into branches, distributed to the mucous membrane of the larynx. Its filaments spread out in various directions: some to the anterior and posterior surfaces of the epiglottis, and to the aryteno-epiglottidean folds, others to the interior of the larynx and the vocal cords. A constant filament descends behind the ala of the thyroid cartilage, and communicates with the inferior laryngeal, and another communication with the same nerve is found behind the larynx beneath the pharyngeal mucous membrane. Its external laryngeal branch supplies the crico-thyroid muscle.

The *inferior (or recurrent) laryngeal nerve* enters the larynx beneath the inferior constrictor, and ascends behind the joint between the thyroid and cricoid cartilages. It supplies all the intrinsic muscles of the larynx except the crico-thyroid. If the recurrent nerve be divided or in any way injured, the muscles moving the glottis become paralysed, but its sensibility remains unimpaired. When the nerve is compressed by a tumor—for instance, an aneurism of the arch of the aorta—the voice is changed to a whisper, or even lost.

* The *tritico-glossus* is a small muscle frequently present; it arises from the corpus triticeum, and passing forwards and upwards joins the cerato-glossus to be inserted into the tongue.

**Difference between
the Male and the
Female Larynx.**

Until the approach of puberty, there is no great difference in the relative size of the male and female larynx. The larynx of the male, within two years after this time, becomes nearly doubled in size; that of the female grows, but to a less extent.

The larynx of the adult male is in all proportions about one-third larger than that of the adult female.

The *alæ* of the thyroid cartilage form a more acute angle in the male; hence the greater projection of the pomum Adami and the greater length of the vocal cords in the male.

The average length of the vocal bands is in the	{	Male	$\frac{7}{8}$ of an inch	(14 mm.)
		Female	$\frac{5}{8}$ "	(11 mm.)
The average length of the glottis is in the	{	Male	nearly "	(24 mm.)
		Female	$\frac{3}{8}$ of "	(16 mm.)

The size of the larynx does not necessarily follow the proportions of the general stature; it may be as large in a little person as in a tall one; this corresponds with what we know of the voice.

DISSECTION OF THE TONGUE.

The tongue is a complex muscular organ, subservient to taste, speech, suction, mastication, and deglutition. It is situated in the space formed by the lower dental arch; its upper surface is convex and free, as is also its anterior part or tip, which lies behind the lower incisor teeth; its posterior and inferior part is connected to the os hyoides by the *hyo-glossi*, to the styloid process of the temporal bone by the *stylo-glossi*, and to the symphysis of the lower jaw by the *genio-hyo-glossi* muscles.

The upper surface or *dorsum* is convex, and slopes on all sides from the centre; it is divided into two symmetrical halves by a median groove—*raphé*—running along the middle, and terminates posteriorly in a depression—the *foramen cæcum*—into which open several mucous glands. The posterior third of the *dorsum* is comparatively smooth; the anterior two-thirds is rough, and covered with small eminences called *papillæ*.

Mucous Membrane. The surface of the tongue is covered with mucous membrane, which is composed of structures similar to those of the skin generally—that is to say, it consists of a *cutis vera* with numerous elevations called *papillæ*, and of a thick layer of squamous epithelium. The *cutis* is much thinner than that of the skin of the body, and affords insertion to some muscular fibres of the tongue.

The mucous membrane on the *under aspect* of the tongue is smooth and comparatively thin, and, in the middle line in front, forms a fold—the *frænum lingue*—which connects it to the mucous membrane of the floor of the mouth. On each side of the *frænum* are the elevated orifices of the submaxillary ducts; and further back, in the furrow between the tongue and gums, are the openings of the sublingual ducts. *Laterally*, the mucous membrane is reflected from the under part of the tongue to the lower jaw, and forms the floor of the mouth.

From the posterior part of the tongue the mucous membrane passes to the soft palate on each side, forming the folds termed the *anterior palatine arches*,

which enclose the palato-glossi; there are also three folds to the epiglottis, termed the *glosso-epiglottic*, *two lateral* and *one median*, the latter enclosing a layer of elastic tissue called the *glosso-epiglottic ligament*. This ligament raises the epiglottis when the tongue is protruded from the mouth; hence the rule of never pulling the tongue forwards when passing a tube into the œsophagus, otherwise the tube might pass into the larynx.

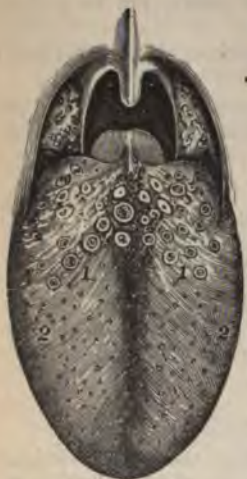

FIG. 94.—UPPER SURFACE OF THE TONGUE, WITH THE FAUCES AND TONSILS.

1. Papillæ circumvallatæ. 2. Papillæ fungiformes.

Papillæ of the Tongue.

The anterior two-thirds of the tongue is studded with numerous small eminences called *papillæ*; these, according to their size and form, are distinguished into three kinds, viz., *papillæ circumvallatæ*, *papillæ fungiformes*, and *papillæ filiformes* (Fig. 94).

The *papillæ circumvallatæ* vary in number from eight to twelve, and are arranged at the back of the tongue in two rows, which converge like the branches of the letter V, with the apex backwards, towards the foramen cæcum. Each of these papillæ is circular, from the $\frac{1}{10}$ th to $\frac{1}{12}$ th of an inch (.8 mm. to 1 mm.) wide, and slightly broader above than below. Each is surrounded by a circular fossa, which itself is bounded by an elevated ring (*vallum*).

The *papillæ fungiformes*, smaller and more numerous than the *circumvallatæ*, are scattered chiefly over the sides and tip of the tongue, and sparingly over its upper surface. They vary in shape, some being cylindrical, others having rounded heads like mushrooms: whence their name. Near the apex of the tongue they may be distinguished during life from the other papillæ by their redder colour. In scarlatina, and some exanthematous fevers, these papillæ become elongated, and of a bright red colour; as the fever subsides, their points acquire a brownish tint,

giving rise to what is called the strawberry tongue.

The *papillæ filiformes (conicæ)* are the smallest and most numerous. They are so closely aggregated that they give the tongue a velvet-like appearance. Their points are directed backwards, so that the tongue feels smooth if the finger be passed over it from apex to base, but rough if in the contrary direction. These papillæ consist of small conical processes arranged for the most part in a series of lines running parallel to the two rows of the *papillæ circumvallatæ*. Each papilla is covered with a thick layer of epithelium, which is prolonged into a number of fine hair-like processes.

The papillæ are covered with one or more layers of squamous epithelium. That which covers the filiform is superimposed so thickly as to give it sometimes the appearance of a brush when seen under the microscope. The various kinds of fur on the tongue consist of thick and sodden epithelium.

Glands.

Numerous small racemose and acino-tubular glands, *lingual glands*, are found in the submucous tissue at the root of the tongue. They are similar in structure and secretion to the tonsillar and palatine glands, so that there is a complete ring of glands round the isthmus faucium. Small round orifices upon their surface indicate the termination of their ducts. Other mucous glands, with ducts from one-quarter to half an inch long, are situated in the muscular substance of the tongue.

Lymphoid Tissue. A considerable amount of *lymphoid tissue* is situated at the back of the tongue, which in some parts is collected into definite masses called *follicles*. Small depressions also occur in this situation, whose walls are studded with lymphoid tissue, and into which some of the mucous glands open.

Glands beneath the Apex of the Tongue. On the inner surface of the apex of the tongue is placed, on either side, a group of glands presumed to be salivary. Considering each group as one gland, observe that it is oblong, with the long diameter from $\frac{7}{8}$ to $\frac{3}{4}$ of an inch (15 to 21 mm.), parallel with the axis of the tongue. It lies near the mesial line, a little below the ranine artery, on the outer side of the branches of the gustatory nerve, under some of the fibres of the stylo-glossus. Four or five ducts proceed from each group, and terminate by separate orifices on the under surface of the tongue.

Muscular Fibres of the Tongue. The substance of the tongue is composed of muscular fibres and of a small quantity of fat. The *extrinsic* muscles of the tongue have been described in the dissection of the submaxillary region (p. 118). We have now to examine its *intrinsic* muscles. For this purpose the mucous membrane must be removed from the dorsum of the tongue. On dissection it will be found that the great bulk of the organ consists of fibres which proceed in a longitudinal direction, constituting the *linguales* muscles.

The *superficial lingualis* runs longitudinally beneath the mucous membrane of the dorsum; its fibres are attached posteriorly to the hyoid bone and run forwards to the front and margin of the tongue. Posteriorly the muscle is thin and is covered by the fibres of the palato-glossus and hyo-glossus.

The *inferior lingualis* is larger than the preceding, and is situated on the under aspect of the tongue between the genio-hyo-glossus and the hyo-glossus. It may be readily exposed by dissecting the under surface of the tongue immediately on the outer aspect of the genio-hyo-glossus. It arises posteriorly from the hyoid bone and the substance of the tongue, and its fibres pass forwards to the tip of the tongue after being reinforced by fibres from the stylo-glossus. On its under aspect it is in relation with the ranine artery.

The *transverse fibres* form a considerable part of the thickness of the tongue and arise from the fibrous septum. They pass outwards between the superficial and inferior linguales, ascending as they near the sides of the tongue, where the fibres become continuous with those of the palato-glossus. A considerable amount of fat is found among these fibres.

The *vertical fibres* run in a curved direction, descending from the dorsum to the under aspect of the tongue, with the concavity outwards. They interlace with the transverse fibres and with the genio-hyo-glossus.

On tracing the genio-hyo-glossi into the tongue, we find that some of their fibres ascend directly to the surface; others cross in the middle line, intersect the longitudinal fibres, and finally terminate upon the sides of the tongue. Lastly, the fibres of the stylo-glossi should be traced along the side of the tongue to the apex.

Fibrous Septum of the Tongue. The *fibrous septum* of the tongue is a vertical plane of fibrous tissue which extends, in the mesial line, from the base to the apex. It is thick posteriorly, where it is connected behind with the hyoid bone, and is lost in front between the muscles. In it is sometimes found a piece of fibro-cartilage, called *nucleus fibrosus lingua*, a representative of the lingual bone in some of the lower animals.

The *arteries* supplying the tongue are the dorsal and ranine branches of the lingual arteries. It is important to bear in mind that the arteries do not anastomose across the middle line, and only very slightly at the apex, so that it is pos-

sible to cut along the septum of the tongue from the apex to the base with very little hæmorrhage,—a fact of much importance in the removal of the tongue or cancer of that organ.

The *nerves* to the tongue should now be followed to their termination. The *hypoglossal* supplies with motor power all the muscles. The *gustatory* or *lingual* branch of the inferior division of the fifth is distributed to the mucous membrane and papillæ of the apex and sides of tongue, supplying the anterior two-thirds with common sensations. Upon this nerve depends the sensation of all ordinary impressions, such as that of hardness, softness, heat, cold, and the like.

The *glosso-pharyngeal* nerve supplies the mucous membrane at the back and the sides of the tongue, and the papillæ *circumvallatæ*. Under the microscope small ganglia may be distinguished on the terminal fibres of this nerve.

DISSECTION OF THE SUPERIOR MAXILLARY NERVE.

To trace this nerve and its branches we must remove the outer wall of the orbit as far as the foramen rotundum, so^a as to expose the spheno-maxillary fossa.

The superior maxillary nerve is a sensory nerve, and is the second division of the fifth cranial nerve. Proceeding from the Gasserian ganglion (Fig. 95), it leaves the skull through the foramen rotundum, and passes horizontally forwards across the spheno-maxillary fossa. It then passes into the orbit through the spheno-maxillary fissure, enters the infra-orbital canal with the corresponding artery, and finally emerges upon the face, through the infra-orbital foramen, beneath the levator labii superioris, where it divides into a number of spreading branches, distributed to the lower eyelid, the nose, and the upper lip. The branches given off are:—

1. Within the skull.

a. A *recurrent branch*, to the dura mater and middle meningeal artery, is given off near the Gasserian ganglion.

2. In the spheno-maxillary fossa.

b. The *orbital branch* already described (p. 80).

c. Two *spheno-palatine branches* which descend to the spheno-palatine ganglion (Meckel's), situated in the spheno-maxillary fossa (Fig. 95).

d. The *dental branches* are three in number: the two posterior are given off immediately before the nerve enters the infra-orbital canal, and descends along the tuberosity of the superior maxillary bone; the anterior is given off in the infra-orbital canal. The *posterior* branch divides into two branches, which send small filaments to the gums and the mucous membrane of cheek, and then run in bony canals in company with small arteries to supply the molar teeth and the antrum; the *middle* branch passes down in a special canal in front of the antrum to be distributed to the bicuspid teeth; the *anterior* branch, the largest, is given off before the nerve emerges from the infra-orbital foramen, and enters the canal in the front wall of the antrum; it divides into *dental* branches for the supply of the canine and incisor teeth, and into a *nasal* branch for the mucous membrane of the floor of the nasal fossa. The anterior branch while in its bony canal gives off some

filaments which join with the posterior dental branches, and above the canine fossa it also forms a communication with a nasal branch from the spheno-palatine ganglion, to form the *ganglion of Bochdalek*.

z. The terminal branch of the superior maxillary nerve is called the *infra-orbital*, which divides on the face into palpebral, nasal, and labial branches. These have been already dissected and described (p. 67).

Dissection.

At this stage the student should make the dissection to expose the spheno-palatine ganglion and its branches. To do this it is necessary to saw through the skull rather on one side of its middle line, so as to expose the cavity of the nose. Search must now be made for the spheno-palatine foramen (just external to which is the spheno-palatine ganglion),

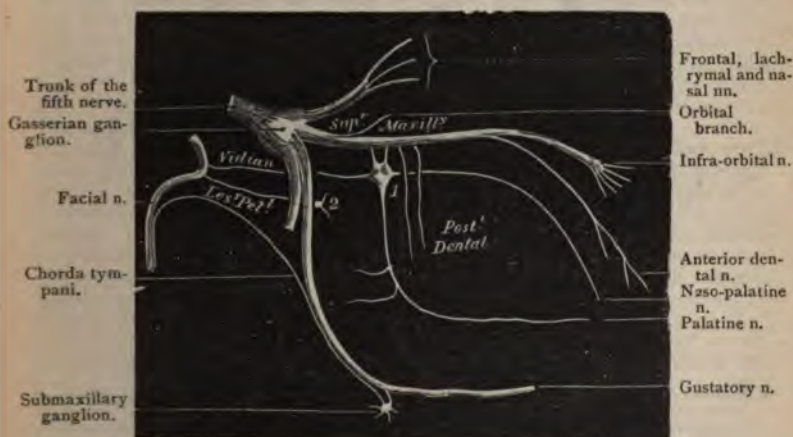


FIG. 95.—DIAGRAM OF THE SUPERIOR MAXILLARY NERVE.
1. Spheno-palatine ganglion. 2. Otic ganglion.

which is situated immediately above the posterior extremity of the middle turbinated bone. Remove the mucous membrane at this point, when the terminal branch of the internal maxillary artery, which comes through this foramen into the nose, may be readily made out. The student should next cut away the thin plate of bone which forms the inner boundary of the posterior palatine canal. Then, by tracing upwards the branches contained within the canal, he will find the ganglion.

Spheno-palatine Ganglion.

This ganglion is called, after its discoverer, *Meckel's ganglion*. It is the largest of the ganglia in connection with the branches of the fifth cerebral nerve, is triangular, convex on its outer surface, of

reddish-grey colour, about one-fifth of an inch (5 mm.) in diameter, and is placed immediately below the superior maxillary nerve, as it crosses the spheno-maxillary fossa. Like other ganglia, it has three roots—a *sensory*, from the superior maxillary; a *motor*, from the great petrosal branch of the fascia; and a *sympathetic*, from the carotid plexus.

Its branches pass *upwards* to the orbit, *downwards* to the palate, *inwards* to the nose, and *backwards* to the pharynx, as follows:—

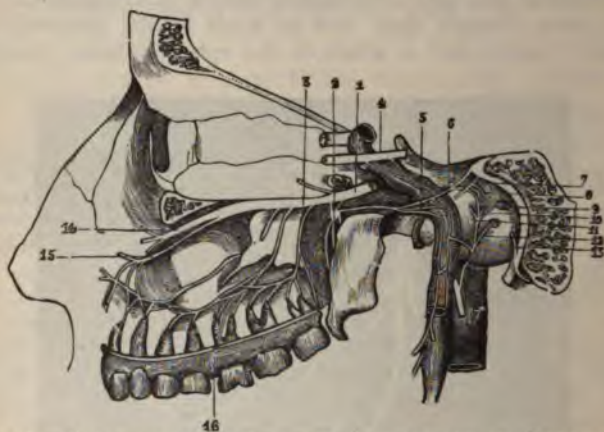


FIG. 96.—DEEP VIEW OF THE SPHENO-PALATINE GANGLION AND ITS CONNECTION WITH OTHER NERVES. (After Hirschfeld.)

1. Superior maxillary nerve. 2. Spheno-palatine ganglion, from the lower part of which are seen proceeding the palatine nerves. 3. Posterior superior dental branches. 4. Sixth nerve receiving two filaments from the carotid plexus of the sympathetic nerve. 5. The carotid branch of the Vidian. 6. The great petrosal branch of the Vidian. 7. Lesser petrosal nerve. 8. External deep petrosal nerve, uniting with lesser petrosal nerve. 9. The internal deep petrosal nerve joining the great petrosal nerve. 10. Filament to fenestra ovalis. 11. Filament to Eustachian tube. 12. Filament to fenestra rotunda. 13. Chorda tympani. 14. Infra-orbital nerve. 15. Anterior dental nerve. 16. Junction of posterior and anterior dental filaments. 17. Glossopharyngeal nerve giving off tympanic branch.

a. Ascending branches.—These are very small, and run through the spheno-maxillary fissure to be distributed to the periosteum of the orbit.*

b. Descending branches.—To see these the mucous membrane must be removed from the back part of the nose; we shall then be able to trace the nerves through their bony canals. Their course is indicated by their accompanying arteries. They descend through the palatine canals, and are three in number. The *anterior palatine* nerve, the largest, descends through the posterior palatine canal to the roof of the mouth, and then divides into branches, which run in grooves in the hard palate nearly to the gums of the incisor teeth, where it communicates with

* Anatomists describe several branches ascending from the ganglion; one to join the sixth nerve (Böck); another to join the ophthalmic ganglion (Tiedemann); and, lastly, some to join the optic nerve through the ciliary branches (Hirzel).

naso-palatine nerve. Within its canal it sends two *inferior nasal branches* which enter the nose through foramina in the palate bone to supply the membrane of the middle and lower spongy bones. The *posterior or smaller palatine* divides in the same canal with the anterior, or in a smaller one of its own, and supplies the mucous membrane of the soft palate, the tonsil, and (according to Eckel) the levator palati muscle.* The *external palatine* may be traced in a canal down to the soft palate, where it terminates in branches to the uvula, palate, and tonsil. The two last branches communicate with the tonsillar filaments of the glosso-pharyngeal to form the tonsillar plexus of nerves.

Internal branches.—These, three or four in number, pass through the sphenoptine foramen to the mucous membrane of the nose. To see them clearly they should have been steeped in dilute nitric acid; afterwards, when well dried, these minute filaments may be recognised beneath the mucous membrane entering the turbinated bones. The *upper nasal* branches, four or five in number, pass inwards, and are distributed on the two upper spongy bones, the upper back part of the septum, and the posterior ethmoidal cells. The *naso-palatine* (nerve of Cotunnus) traverses the roof of the nose, distributes branches to the back part of the septum narium, and then proceeds obliquely forwards, along the septum, to the foramen incisivum, through which it passes, and finally terminates in the palate behind the incisor teeth, communicating here with the anterior sphenoptine nerve.

Posterior branches.—The *pharyngeal nerve* (pterygo-palatine), very small, arises off from the back of the ganglion, and, after passing through the pterygo-sphenoptine canal with its corresponding artery, supplies the mucous membrane of the soft palate of the pharynx and the Eustachian tube. The *Vidian nerve* is the principal branch. It proceeds backwards from the posterior part of the ganglion, through the Vidian canal, where it distributes small branches to the back part of the roof of the nose and septum. It then traverses the fibro-cartilage of the foramen rotundum medium, and divides into two branches. Of these two branches one, the *smaller*—the *carotid*—joins the sympathetic plexus on the outer side of the internal carotid artery; the other, the *great petrosal*, enters the cranium and runs beneath Gasserian ganglion and the dura mater in a small groove on the anterior surface of the petrous bone; it then enters the hiatus Fallopii, and joins the facial nerve in the aqueductus Fallopii.

It would seem to be more in accordance with modern views to regard the Vidian nerve, not as dividing to form the carotid and great superficial petrosal nerves, but rather as formed by the junction of these branches. In this view the Vidian runs, not *from*, but *to*, the sphenoptine ganglion.

Otic Ganglion. The otic ganglion (Arnold's) is situated on the inner side of the inferior maxillary division of the fifth nerve, immediately below its exit through the foramen ovale (Fig. 96). It is oval, of red-grey colour, and always small. Its *inner* surface is in contact with the circumflexus palati muscle and the cartilage of the Eustachian tube; *behind* it is in contact with the middle meningeal artery; *externally* it is in relation with the inferior maxillary nerve, where the motor root joins the sensory root.

This ganglion has branches of connection with other nerves; namely, a *sensory*

* According to Longuet (*Anat. et Physiol. du Système Nerveux*, Paris, 1842), the posterior palatine nerve supplies the levator palati and the azygos uvulæ with force or power. In this view of the subject the nerve is considered to be the continuation or terminal branch of the motor root of the ganglion; that, namely, which is derived from the facial. This opinion is supported by cases in which the uvula has been drawn to have been drawn on one side in consequence of paralysis of the opposite facial nerve.

from the auriculo-temporal nerve; a *motor* from the branch of the inferior maxillary, which goes to the internal pterygoid muscle; and a *sympathetic* from the plexus around the arteria meningea media. It communicates also with the facial and the glosso-pharyngeal nerves by the *lesser petrosal nerve*. This branch passes backwards, either through the foramen ovale or the foramen spinosum, or through

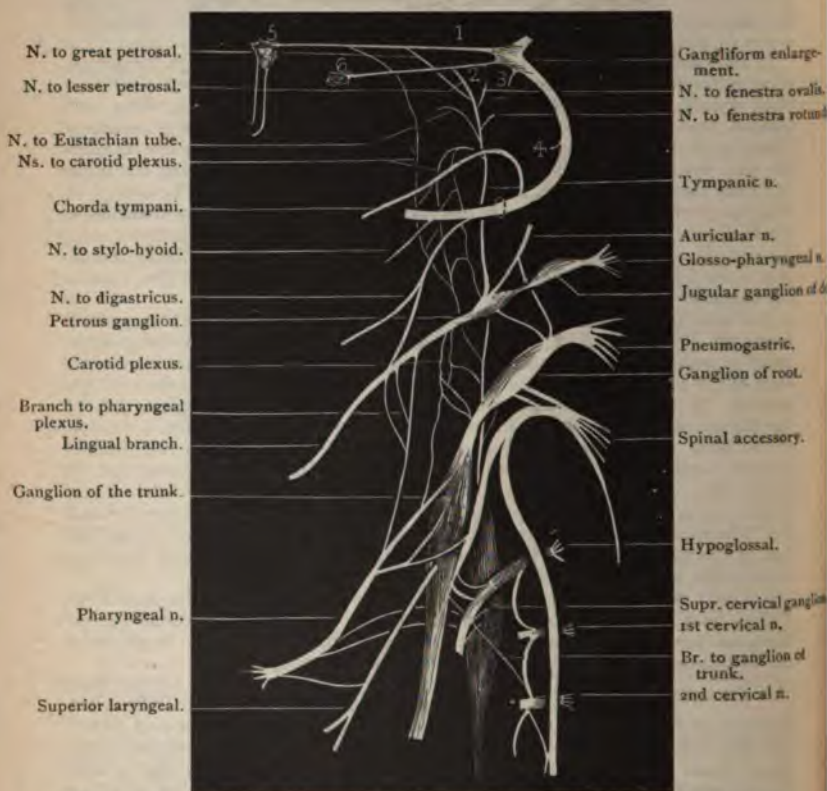


FIG. 97.—DIAGRAM OF THE COMMUNICATIONS OF THE FACIAL, GLOSSO-PHARYNGEAL, PNEUMOGASTRIC, SPINAL ACCESSORY, HYPOGLOSSAL, SYMPATHETIC, AND THE TWO UPPER CERVICAL NERVES.

1. Great petrosal nerve. 2. Lesser petrosal nerve. 3. External petrosal nerve. 4. Nerve to Stapedius muscle. 5. Spheno-palatine ganglion. 6. Otic ganglion.

a small hole between them, and runs beneath the dura mater in a minute groove on the petrous bone, external to that for the *great petrosal nerve*. Here it divides into two filaments, one of which joins the facial nerve in the aquæductus Fallopii; the other joins the tympanic branch of the glosso-pharyngeal. These nerves are

ult to trace, not only on account of their minuteness, but because they frequently run in canals in the temporal bone.

The otic ganglion sends a branch forwards to the tensor palati, and one backwards to the tensor tympani, on the outer side of the Eustachian tube.

SECTION OF THE NINTH, TENTH, AND ELEVENTH CRANIAL NERVES AT THE BASE OF THE SKULL.

In this dissection we propose to examine the glosso-pharyngeal, pneumogastric, spinal accessory nerves in the jugular fossa, and the ganglia and nerves belonging to them in this part of their course. These are difficult to trace, and cannot be followed unless the nerves have been previously hardened by spirit and bones softened in acid. The next thing to be done is to remove the outer wall of the jugular fossa.

Glosso-pharyngeal nerve. This nerve emerges from the cranium through a separate tube of dura mater, in front of that for the tenth and eleventh cranial nerves. Looking at it from the interior of the skull, we notice that it is situated in front, and rather to the inner side of the jugular fossa, where it lies in a groove.

In its passage through the foramen, the nerve presents two enlargements, termed the *jugular* and the *petrous ganglia*.

The *jugular ganglion* is found upon the nerve immediately after its entrance into the canal of the dura mater, and averages about the $\frac{1}{20}$ th of an inch (.5 mm.) in length and breadth. It is situated on the outer side of the nerve, and does not enclose all its fibers. According to our observation, this ganglion is not infrequently absent (Fig. 97).

The *petrous ganglion* is lodged in a groove in the lower part of the jugular fossa. It is oval, about a quarter of an inch (6 mm.) long, and involves all the filaments of the nerve. From it are given off branches of communication with other nerves, the *tympenic nerve* (Fig. 97).*

The *communicating branches* which connect this ganglion with the pneumogastric are, one to its auricular branch, and a second to the ganglion of the root of the vagus. It is also connected with the sympathetic by a small filament from the superior cervical ganglion. Another communicating branch pierces the posterior belly of the digastric to join the facial just external to the stylo-mastoid foramen.

The *tympenic nerve* (Jacobson's) ascends, through a minute canal in the bony wall which separates the carotid from the jugular fossa, to the inner wall of the tympanic membrane, grooving the surface of the promontory, where it terminates in six or seven filaments. Of these three are branches of distribution, and three of communication with other nerves. The *branches of distribution* are, one each to the fenestra rotunda and the fenestra ovalis, which pass backwards, and one to the Eustachian tube, which is directed forwards. The *branches of communication* are four small nerves; one or two traverse a bony canal in the anterior wall of the tympanic membrane, arching forwards, join the plexus on the outer side of the carotid artery; the other, the *small deep petrosal nerve*, runs in a canal in the processus cochleariformis, passes through the foramen lacerum medium to join the carotid plexus; a fourth ascends in front of the fenestra ovalis, and, passing forwards, joins the great petrosal nerve in the hiatus Fallopii; the fourth leaves the front of the tympanic membrane, and is named the *small superficial petrosal nerve*, through a canal, where it

This nerve, though commonly called Jacobson's, was fully described by H. Sch.

is joined by a filament from the geniculate ganglion of the facial nerve; then passing beneath the canal for the tensor tympani, it emerges through a foramen on the anterior surface of the pars petrosa, external to the hiatus Fallopii; it proceeds along the anterior surface of pars petrosa, and emerges from the skull between the great wing of the sphenoid and the petrous bones to join the otic ganglion. Thus the tympanic branch is distributed to the mucous membrane of the tympanum and the Eustachian tube, and communicates with the sphenopalatine ganglion through the great petrosal nerve, and with the otic ganglion through the lesser petrosal (Fig. 96).

Pneumogastric Nerve.

This nerve leaves the cranium with the nervus accessorius through a common canal in the dura mater, behind that for the glosso-pharyngeal. At its entrance into the canal it is composed of a number of separate filaments, which are soon collected into a single trunk. In the jugular foramen the nerve presents a ganglionic enlargement, called the *ganglion of the root*; and, after the nerve has emerged from the jugular foramen, it presents a second ganglion—the *ganglion of the trunk* of the nerve—where it is joined by the accessory portion of the spinal accessory nerve. The *ganglion of the root* is about $\frac{1}{4}$ th of an inch (3.5 mm.) in length. It is connected by filaments with the sympathetic through the superior cervical ganglion, with the petrous ganglion of the glosso-pharyngeal, with the auricular branch of the facial, and with the spinal accessory by one or two branches. It gives off the *auricular branch*,* which is distributed to the pinna of the ear. This branch, shortly after its origin, is joined by a branch from the petrous ganglion of the glosso-pharyngeal, and, passing outwards behind the internal jugular vein, it enters a minute foramen in the jugular fossa near the styloid process. It then proceeds through a canal in the bone, crosses the aquæductus Fallopii, where it communicates with the facial nerve, and passes to the outside of the skull through the fissure between the mastoid process and the meatus auditorius externus. It here divides into two branches, one being distributed to the skin of the auricle, and communicating with the great auricular nerve; the other communicating with the posterior auricular branch of the facial over the mastoid process. This ganglion also sends backwards a *meningeal branch*, which passes through the jugular foramen to be distributed to the dura mater of the posterior fossa (Fig. 97).

The *ganglion of the trunk* has communications with the hypoglossal nerve, with the loop formed between the first and second cervical nerves, and with the superior cervical ganglion of the sympathetic. It gives off, as branches of distribution, the pharyngeal and superior laryngeal nerves. This has been previously described (p. 160).

Facial Nerve in the Temporal Bone.

The facial nerve is contained within the meatus auditorius internus, together with the auditory nerve. At the bottom of the meatus the two nerves are connected by one or more filaments. The facial nerve then enters the aquæductus Fallopii. This is a tortuous canal in the substance of the temporal bone, and terminates at the styloid-mastoid foramen. The nerve proceeds from the meatus auditorius internus for a short distance outwards towards the hiatus Fallopii, where it presents a ganglionic enlargement—the *intumescencia gangliiformis*, or *geniculate ganglion*—where it is joined by several nerves; it then makes a sudden bend backwards along the inner wall of the tympanum above the fenestra ovalis, and, lastly, curving downwards along the back of the tympanum, it leaves the skull through the stylo-mastoid foramen.

* Arnold's nerve.

Its *branches of communication* in the temporal bone are:—

Those in the meatus auditorius internus—

a. With the auditory nerve.

Those in the aquæductus Fallopii—

b. With Meckel's ganglion through the large petrosal nerve.

c. With the otic ganglion through the small superficial petrosal nerve.

d. With the sympathetic around the middle meningeal artery through the external superficial petrosal nerve.

Its *branches of distribution* are:—

e. The tympanic branch.

f. The chorda tympani.

a. The *communicating branches* with the auditory are by several filaments, in the meatus auditorius internus.

b. The *large petrosal nerve* joins the carotid branch from the sympathetic to form the Vidian nerve, which joins the sphenopalatine ganglion (Fig. 98, 3).

c. The *small superficial petrosal nerve* passes along the anterior surface of the pars petrosa to join the otic ganglion below the foramen ovale (Fig. 98, 4).

d. The *external superficial petrosal nerve* passes from the geniculate ganglion to the sympathetic plexus around the middle meningeal artery (Fig. 98, 5).

e. The *tympanic branch* passes through a foramen in the base of the posterior pyramid to supply the stapedius and the laxator tympani (Fig. 97, 4).*

f. The *chorda tympani* is given off from the facial nerve before its exit from the stylo-mastoid foramen.† It ascends a short distance in a bony canal at the back of the tympanum, and enters that cavity through a small foramen—*foramen chordæ posterius*—below and external to the pyramid, close to the *membrana tympani*. It runs forwards, ensheathed in mucous membrane, through the tympanum, between the handle of the malleus and the long process of the incus, to the anterior part of that cavity. It emerges through a small aperture—*foramen chordæ anterioris*—then traverses a special bony canal—*canal of Huguier*—and makes its exit close to the *fissura Glaseri*. It passes downwards and forwards between the two pterygoid muscles, behind the *arteria meningeæ media*, the

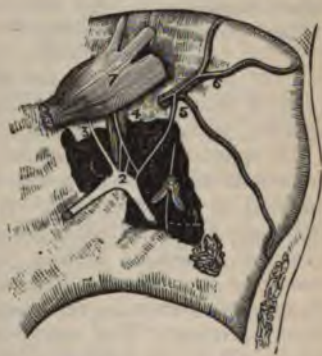

FIG. 98.—THE GENICULATE GANGLION OF THE FACIAL NERVE, AND ITS CONNECTIONS WITH THE OTHER NERVES. (From Bidder.)

1. The chorda tympani. 2. The geniculate ganglion of the facial nerve. 3. The great petrosal nerve. 4. The lesser petrosal nerve lying over the tensor tympani. 5. The external petrosal nerve communicating with the sympathetic plexus on the arteria meningeæ media (6). 7. The Gasserian ganglion.

* This is often not muscular, but ligamentous in structure.

† In the foetus this nerve is given off outside the foramen, but subsequently the bone grows downwards so as to enclose more of the facial nerve, and with it the chorda tympani.

auriculo-temporal and inferior dental nerves, to join, at an acute angle, the lower border of the gustatory nerve. It then proceeds in part to the submaxillary ganglion, and in part to the lingualis muscle.

External to the stylo-mastoid foramen, the facial nerve communicates with the pneumogastric, the glosso-pharyngeal, the great auricular, the auriculo-temporal nerves, and with the carotid plexus; and on the face, with the numerous branches of the three divisions of the fifth nerve. Its branches of distribution, close to the stylo-mastoid foramen, are the posterior auricular, digastric, and stylo-hyoid branches; and on the face, branches to all the facial muscles and the platysma myoides.

Course of the Internal Carotid through Base of Skull. The cervical portion of the internal carotid has been already described (p. 157). Its subsequent course may be divided into the petrous, cavernous, and cerebral portions.

In the *petrous portion*, the artery takes a very tortuous course; at first it ascends for a short distance; it then curves forwards and inwards; and lastly, it again ascends to reach the side of the body of the sphenoid. It is situated in front of the tympanum, from which it is separated by a thin lamella of bone, which is frequently absorbed in advanced age. It gives off a *tympanic branch* to the tympanum and membrana tympani.

In the *cavernous portion*, the artery again makes a series of curves; at first it ascends forwards on the side of the body of the sphenoid, and then curves upwards on the inner side of the anterior clinoid process. The artery in this part of its course lies in the inner wall of the cavernous sinus, having the sixth nerve below and to its outer side. From this portion are given off *arteria receptaculi* to supply the pituitary body, Gasserian ganglion, and neighbouring structures; the *anterior meningeal* to supply the dura mater; and the *ophthalmic artery* already described (p. 76).

In the *cerebral portion*, it pierces the dura mater on the inner side of the anterior clinoid process, and is surrounded by a sheath of the arachnoid membrane. It gives off the *anterior cerebral*, the *middle cerebral*, the *anterior choroid*, and the *posterior communicating arteries*.

The internal carotid is accompanied in the carotid canal by the cranial branch of the superior cervical ganglion of the sympathetic, described p. 164. Its position on the inner wall of the cavernous sinus, and the nervous plexuses upon it, are described at p. 44.

At this stage of the dissection we may conveniently trace the anterior divisions of the two upper cervical nerves.

Suboccipital Nerve. The anterior division of the *first cervical* or *sub-occipital nerve* descends in front of the transverse process of the atlas to form a loop with the ascending branch of the second cervical nerve. It lies

beneath the vertebral artery, on the inner side of the rectus capitis lateralis, to which it gives a branch; as also, one to the occipito-atloid joint, one to the rectus capitis anticus minor, and one to the sympathetic around the vertebral artery. From its loop of communication with the second nerve it gives filaments of communication to the superior cervical ganglion, to the hypoglossal and pneumogastric nerves; and muscular branches to the longus colli and rectus capitis anticus major.

Second Cervical Nerve.

The anterior division of this nerve emerges between the arches of the atlas and axis, and passes between the vertebral artery and the intertransverse muscle, in front of which it subdivides into an ascending branch which joins the first cervical nerve, and into a descending which joins the third cervical nerve.

DISSECTION OF THE NOSE.

Presuming that the dissector is familiar with the bones composing the skeleton of the nose, we shall now describe: 1. The nasal cartilages; 2. The general figure and arrangement of the nasal cavities; 3. The membrane which lines them; and, 4. The distribution of the olfactory nerves.

Cartilages of the Nose.

The framework of the external nose is formed by five cartilages; on each side by two lateral cartilages; and by one in the centre, which completes the septum between the nasal fossæ.

The *lateral cartilages* are termed, respectively, upper and lower, which are covered externally by integument, and are lined internally by mucous membrane. The *upper*, triangular in shape, is connected superiorly to the margin of the nasal and superior maxillary bones; anteriorly, which is its thickest part, to the cartilage of the septum; and, inferiorly, to the lower cartilage by means of a tough, fibrous membrane. The *lower* is elongated, and curved upon itself in such a way as to form not only half the apex, but the outer and inner boundaries of the external opening of the nostrils. Superiorly, it is connected by fibrous membrane to the upper cartilage; internally, it is in contact with its fellow of the opposite side, forming the upper part of the *columna nasi*; posteriorly, it is attached by fibrous tissue to the superior maxillary bone; in this tissue are usually found two or three nodules of cartilage, called *cartilaginee sesamoideæ*; below, it is firmly connected to dense connective tissue. By their elasticity these several cartilages keep the nostrils continually open, and restore them to their ordinary size whenever they have been expanded by muscular action.

The *cartilage of the septum* is placed perpendicularly in the middle line; it may lean a little, however, to one side or the other, and in some instances it is perforated, so that the two nasal cavities communicate with each other. The cartilage is smooth and flat, and its outline is nearly triangular. The posterior border is received into a groove in the perpendicular plate of the ethmoid; the anterior border is much thicker than the rest of the septum, and is connected, superiorly, with the nasal bones, and on either side with the lateral cartilages. The inferior border is attached to the vomer and the median ridge at the junction of the palatine processes of the superior maxillæ.

The nose receives its blood-supply from the lateralis nasi, the artery of the septum, the facial, the nasal branch of the ophthalmic, and the infra-orbital arteries. The veins are returned to the facial and ophthalmic veins. The nerves are derived from the nasal branch of the ophthalmic, the infra-orbital, and infra-trochlear nerves. Its muscles are supplied by branches from the facial nerve.

The muscles moving the nasal cartilages have been described with the dissection of the face (p. 56).

Interior of the Nose. A vertical section should be made through the right nasal cavity, a little on the same side of the middle line,* to expose the partly bony and partly cartilaginous partition of the nasal cavities (*septum narium*). Each nasal fossa is narrower above than below. The greatest perpendicular depth of each fossa is about the centre; from this point the depth gradually lessens towards the anterior and the posterior openings of the nose. Laterally, each fossa is very narrow, in consequence of the projection of the turbinated bones towards the septum: this narrowness in the transverse direction explains the rapidity with which swelling of the lining membrane from a simple cold obstructs the passage of air.

Boundaries of Nasal Fossæ.

The nasal fossæ are bounded by the following bones:—*superiorly*, by the nasal, the nasal spine of the frontal, the cribriform plate of the ethmoid, the body of the sphenoid, and the sphenoidal turbin-

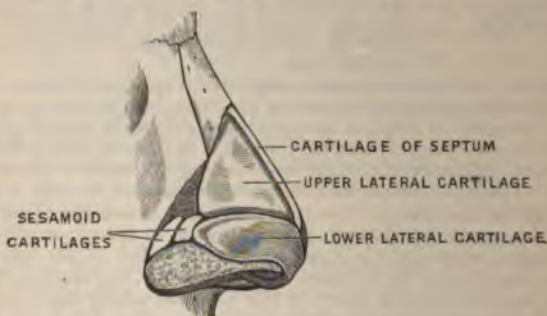


FIG. 99.—CARTILAGES OF THE NOSE.

ated bones: *inferiorly*, by the horizontal plates of the superior maxillary and palate bones; *internally*, is the smooth and flat septum formed by the perpendicular plate of the ethmoid, the ridge formed by the two nasal bones, the vomer, the septal cartilage, also by the nasal spine of the frontal, the rostrum of the sphenoid, and the crest of the superior maxillary and palate bones; *externally*, by the nasal process and the inner surface of the superior maxillary, the lachrymal, the ethmoid, the palate, the inferior turbinated bones, and the internal pterygoid plate of the sphenoid.

Meatuses of the Nose. The outer wall of each nasal cavity is divided by the turbinated bones into three compartments—*meatuses*—of unequal size; and in these are orifices leading

* This has already been done in order to dissect the sphenopalatine ganglion.

to air-cells—*sinuses*—in the sphenoid, ethmoid, frontal, and superior maxillary bones. Each of these compartments should be separately examined.

a. The *superior meatus* is the smallest of the three, and does not extend beyond the posterior half of the wall of the nose. The posterior ethmoidal and sphenoidal cells open into it. The sphenopalatine foramen is covered by the mucous membrane, and is posterior to the meatus.

b. The *middle meatus* is larger than the superior. At its anterior part a long narrow passage (*infundibulum*), nearly hidden by a fold of membrane, leads upwards to the frontal and the anterior ethmoidal cells. About the middle a small opening leads into the antrum of the superior maxilla: this opening in the dry bone is large and irregular, but in the recent state it is reduced nearly to the size of a crow-quill by mucous membrane, so that a very little swelling of the membrane is sufficient to close the orifice entirely.

Notice that the orifices of the frontal and ethmoid cells are so disposed that their secretion will pass easily into the nose. But this is not the case with the maxillary cells, to empty which the head must be inclined on one side. To see all these openings the respective turbinated bones must be raised.

c. The *inferior meatus* extends nearly along the whole length of the outer wall of the nose. By raising the lower turbinated bone, we observe, towards the front of the meatus, the termination of the nasal duct, through which the tears pass down from the lachrymal sac into the nose. This sac and duct can now be conveniently examined.

Lachrymal Sac and Nasal Duct.

The lachrymal sac and nasal duct constitute the passage through which the tears are conveyed from the canaliculi into the nose (p.

53). The *lachrymal sac* occupies the groove formed by the lachrymal bone and the nasal process of the superior maxilla. The upper end is round and closed; the lower gradually contracts into the nasal duct, and opens into the inferior meatus. The sac is composed of a strong fibrous and elastic tissue, which adheres very closely to the bone, and is lined by mucous membrane, continuous above, with that lining the canaliculi, and below, with that of the nasal duct. Its front surface is covered by the tendo oculi and the fascia proceeding from it, and by the tensor tarsi muscle.

The *nasal duct* is from half (13 mm.) to three-quarters (18 mm.) of an inch in length, and is directed downwards, backwards, and a little outwards. Its termination is rather dilated, and is guarded by a valvular fold of mucous membrane—*valve of Hasner*; consequently, when air is blown into the nasal passages while the nostrils are closed, the lachrymal sac does not become distended. The

lacrimal sac and the nasal duct are lined with ciliated epithelium, and the canaliculi with the squamous variety.

Behind the inferior turbinated bone is the opening of the Eustachian tube (p. 237). Into this, as well as into the nasal duct, we ought to practise the introduction of a probe. The chief difficulty is to prevent the probe from slipping into the cul-de-sac between the tube and the back of the pharynx.

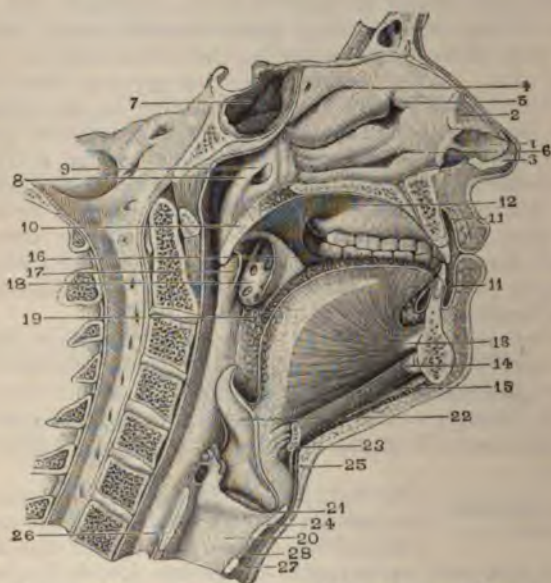


FIG. 100.—VERTICAL SECTION OF THE NASAL FOSSE AND MOUTH.

1. Left nares, 2. Labial cartilage of the nose. 3. Portion of the internal alar cartilage forming the skeleton of the lower part. 4. Superior meatus, 5. Middle meatus. 6. Inferior meatus. 7. Sphenoidal sinus, 8. External boundary of the posterior nares. 9. Internal elliptical opening of the Eustachian tube. 10. Soft palate.

Mucous or Schneiderian Membrane.

This membrane lines the cavities of the nose and the air-cells communicating with it, and adheres very firmly to the periosteum. Its continuity may be traced into the pharynx, into the orbits through the nasal ducts and canaliculi, into the various air sinuses—viz., the frontal, ethmoidal, sphenoidal sinuses, and the antra of Highmore, and into the tympana and mastoid cells through the Eustachian tubes. At the lower border of the turbinated bones it is disposed in thick and loose folds. The membrane varies in

thickness and vascularity in different parts of the nasal cavities. Upon the lower half of the septum and the inferior turbinated bones it is much thicker than elsewhere, owing to a fine plexus of arteries and veins in the submucous tissue. In the sinuses the mucous membrane is thinner, less vascular, and closely adherent to the periosteum.

The great vascularity of the mucous membrane raises the tempera-

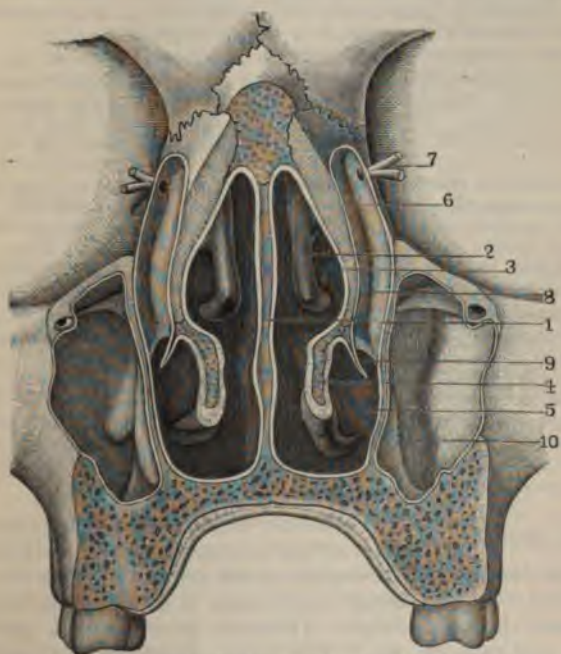


FIG. 101.—SECTION (TRANSVERSE) OF THE NASAL FOSSAE.

1. Septum between the nasal fossae. 2. Anterior extremity of the middle turbinated bone. 3. Middle meatus. 4. Section of the inferior turbinated bone, made on a level with the opening of the nasal canal. 5. Inferior meatus. 6. Lachrymal sac. 7. The two lachrymal canals uniting in one to open into the lachrymal sac by a common orifice. 8. Nasal canal. 9. Cot fold of mucous membrane of this canal, showing its continuance with that of the inferior meatus (Valve of Hasner). 10. Antrum of Highmore.

ture of the inspired air, and pours out a copious secretion which prevents the membrane from becoming too dry.

The mucous membrane of the nasal cavities is not lined throughout by the same kind of epithelium. Near the nostrils the mucous membrane is furnished with papillae, with a squamous epithelium like the skin, and a few small hairs (*vibrissae*).

In the lower part of the nose—namely, along the respiratory tract and in the sinuses—the epithelium is columnar and ciliated; but in the true olfactory region—that is, upon the superior and middle turbinated bones and the upper half of the septum—the epithelium is columnar, but not ciliated. In this region the mucous membrane is extremely vascular, thick, and studded with branched mucous glands. The columnar epithelial cells taper off at their deep ends into fine processes. Lying between these processes are fusiform cells, with central well-defined nuclei, to which the name of *olfactory cells* has been given; and it is probable that the attenuated processes which pass inwards from these cells are in direct connection with the terminal fibrils of the olfactory nerves.

The *arteries* of the nasal cavities are derived from the anterior and posterior ethmoidal branches of the ophthalmic, which supply the roof of the nose, the anterior and posterior ethmoidal cells, and the frontal sinuses; from the nasal artery of the internal maxillary, which supplies the septum, the meatuses and the turbinated bones; from the posterior dental branch of the internal maxillary, which supplies the antrum. The external nose is supplied by the nasal branch of the ophthalmic (p. 77), the *arteria lateralis nasi*, the angular, and the artery of the septum.

The *veins* of the nose correspond with the arteries, and, like them, form close plexuses beneath the mucous membrane. They communicate with the veins within the cranium, through the foramina in the cribriform plate of the ethmoid bone; also through the ophthalmic vein and the cavernous sinus. These communications explain the relief frequently afforded by hæmorrhage from the nose in cases of cerebral congestion.

The mucous membrane of the nose is supplied with sensory nerves by the fifth pair. Thus, its *roof* is supplied by filaments from the external division of the nasal branch of the ophthalmic and from the Vidian; its *outer wall*, by filaments from the superior nasal branches of the spheno-palatine ganglion, from the nasal, from the inner branch of the anterior dental, and from the inferior nasal branches of the large palatine nerve; its *septum*, by the septal branch of the nasal nerve, by the nasal branches of the spheno-palatine ganglion, by the naso-palatine, and by the Vidian; its *floor*, by the naso-palatine and the inferior nasal branches of the large palatine nerve.

Olfactory Nerves. The olfactory nerves, proceeding from each olfactory bulb, in number about twenty on each side, pass through the foramina in the cribriform plate of the ethmoid bone. In its passage each nerve is invested with a coat derived from the dura mater. They are arranged into an inner, a middle, and an outer set. The *septal*, which are the largest, traverse the grooves in the upper third of the septum. The *middle* ramify on the roof of the nose. The *outer* pass through grooves, and are divided into an anterior and a posterior group: the anterior being distributed over the superior turbinated bone, the posterior over the os planum of the ethmoid and the middle turbinated bone.

The nerves descend obliquely between the mucous membrane and the periosteum, and break up into filaments, which communicate freely with one another, and form minute plexuses with small elongated intervals. Microscopically, the filaments differ from the other cerebral nerves in containing no white substance of Schwann

and in their axis-cylinders being provided with a very distinct nucleated sheath with fewer nuclei and at longer intervals.

DISSECTION OF THE MUSCLES OF THE BACK.

Those muscles of the back—namely, the trapezius, latissimus dorsi, levator anguli scapulæ, and rhomboidei—which are concerned in the movements of the upper extremity, will be examined in the dissection of the arm. These must be reflected near to their insertions, together with the cutaneous vessels and nerves. We now proceed to examine the three muscles forming the *third layer* of muscles, named, from their appearance, *serrati postici, superior* and *inferior*, and the *splenius*. The nerves and arteries will be described after the dissection of the suboccipital triangle.

Dissection to expose the Third Layer of Muscles.

Serratus Posticus Superior. This muscle is situated beneath the rhomboidei. It is a thin flat muscle, and *arises* from the lower part of the ligamentum nuchæ,* from the spinous processes of the last cervical, and two or three upper dorsal vertebræ, by a sheet-like aponeurosis which makes up nearly half the muscle; the fibres run obliquely downwards and outwards, and are *inserted* by four fleshy slips into the second, third, fourth, and fifth ribs beyond their angles. Its action is to raise these ribs, and therefore to assist in inspiration. Is only brought into action in forced inspiration.

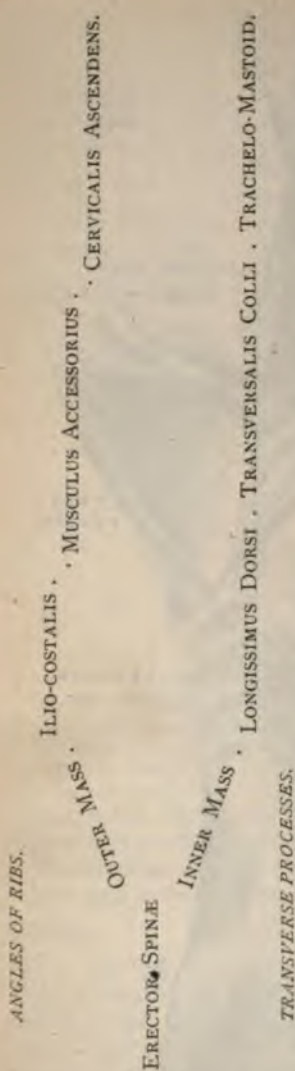
Serratus Posticus Inferior.

This muscle is situated in the upper lumbar region, beneath the latissimus dorsi. It *arises*, by means of the *lumbar aponeurosis*, from the spinous processes of the two last dorsal and two upper lumbar vertebræ and their supra-spinous ligament. It ascends obliquely outwards, and is *inserted* by four fleshy slips into the four lower ribs external to their angles. Its *action* is to pull down these ribs and therefore to assist in expiration. Is only required in forced expiration, as the ordinary expiration is performed by the elasticity of the thoracic and abdominal walls and their contents. The posterior serrati muscles are supplied, respectively, by the *external* branches of the posterior divisions of the cervical and dorsal nerves.

Vertebral Aponeurosis.

The thin aponeurosis which, in the posterior aspect of the thoracic region, separates the muscles of the upper extremity from those of the back, is called the *vertebral aponeurosis*. *Superiorly*, it is con-

* The ligamentum nuchæ is a rudiment of the great elastic ligament of quadrupeds (termed the *pack-wax*) which supports the weight of the head. It proceeds from the spine of the occiput to the spines of all the cervical vertebræ except the atlas; otherwise it would interfere with the free rotation of the head.



ARRANGEMENT OF THE ERECTOR SPINÆ AND ITS PROLONGATIONS INTO THE POSTERIOR THORACIC AND CERVICAL REGIONS.

b. The *splenius colli*, the outer of the two portions, is *inserted* by tendinous slips into the posterior tubercles of the transverse processes of the upper three cervical vertebræ. The splenius is supplied by the external branches of the posterior divisions of the cervical nerves.

The *action* of the splenius, taken as a whole, is to draw the head and the upper cervical vertebræ towards its own side; so far, it co-operates with the opposite sterno-mastoid muscle. When the splenii of opposite sides contract, they extend the cervical portion of the spine, and keep the head erect. The permanent contraction of a single splenius may occasion wry-neck. It is necessary to be aware of this, otherwise one might suppose the opposite sterno-mastoid to be affected, considering that the appearance of the distortion is alike in either case.

Dissection to expose the Fourth Layer.

To lay bare the *fourth layer* of muscles, the splenius and serratus posticus inferior are to be detached from their origins. After reflecting the vertebral aponeurosis and the lumbar fascia from its internal attachment, the erector spinæ and its prolongations are exposed.

Erector Spinæ.

The mass of muscle which occupies the vertebral groove on each side of the spine is, collectively, called *erector spinæ*, since it counteracts the tendency of the trunk to fall forwards. It is pointed at its lower tendinous extremity, where it arises from the sacral region; in the lumbar region it is broad, thick, and muscular; in the lower dorsal region it divides into two portions, which are continued upwards with additional muscles into the cervical vertebræ and the head. Observe that it is thickest and strongest at that part of the spine where it has the greatest weight to support—namely, in the lumbar region; and that its thickness gradually decreases towards the top of the spine.

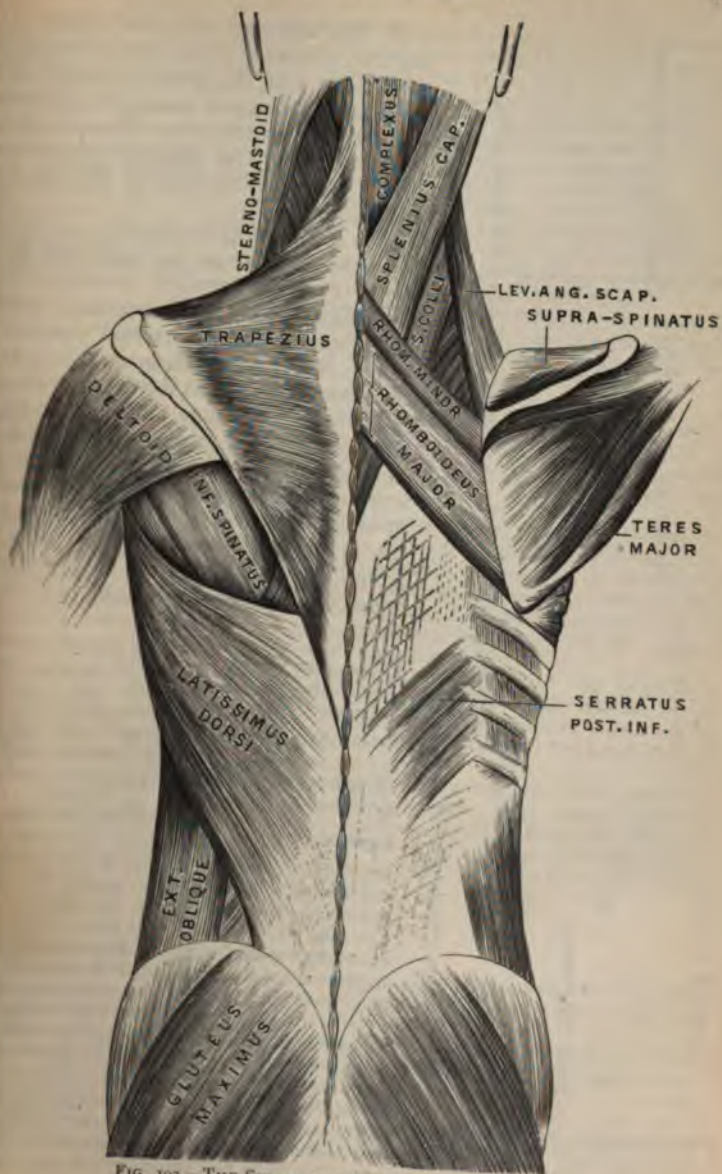


FIG. 103.—THE SUPERFICIAL MUSCLES OF THE BACK.

Spinalis Dorsi.

This is a long narrow muscle, situated close to the spines of the dorsal vertebræ, and apparently the inner part of the longissimus dorsi; it is by some considered the innermost column of the erector spineæ. It *arises* by tendinous slips from the spinous processes of the two lower dorsal and two upper lumbar vertebræ, and is *inserted* by little tendons into the spinous processes of the six or eight upper dorsal vertebræ. Beneath it is the semi-spinalis dorsi, which is closely connected with the spinalis dorsi.

Spinalis Colli.

This small, but not constant muscle corresponds in the cervical region to the spinalis dorsi in the dorsal region. It *arises* by tendinous slips from the spinous processes of the two or three lower cervical vertebræ (sometimes also from the two upper dorsal), and is inserted into the spine of the axis, and occasionally into the spinous processes of the third and fourth cervical.

The muscles of the spine hitherto examined are all longitudinal in their direction. We now come to a series which run obliquely from the transverse to the spinous processes of the vertebræ. And first of the complexus.

Complexus.

This powerful muscle *arises* by tendinous slips from the transverse processes of the three or four upper dorsal and the last cervical vertebræ, also from the articular processes of four or five cervical vertebræ and their capsular ligaments. It is *inserted* between the two curved lines of the occiput, near the vertical crest. In the centre of the muscle there is generally a transverse tendinous intersection. The muscle is perforated by the posterior branches of the second (the great occipital), third, and fourth cervical nerves. It is chiefly supplied by the great occipital nerve. Its *action* is to maintain the head erect.

Biventer Cervicis.

Is placed in the inner side of the preceding muscle and frequently forms part of it. It has an intermediate tendon, and *arises* from the transverse processes of two or three upper dorsal vertebræ, and ascends between the ligamentum nuchæ and the complexus, to be *inserted* into the innermost depression between the two curved lines of the occipital bone.

terior third of the iliac crest. It divides into two portions, the sacro-lumbalis and the longissimus dorsi.

"The former, arising from the iliac crest, or from the pleurapophysis (rib) of the first sacral vertebra, is inserted by short flat tendons into (1) the apices of the stunted lumbar ribs, close to the tendinous origins of the transversalis abdominis; (2) the angles of the eight or nine inferior dorsal ribs; (3) it is inserted, through the medium of the musculus accessorius, into the angles of the remaining superior ribs, and into the long and occasionally distinct pleurapophysial element of the seventh cervical vertebra; and (4) through the medium of the cervicalis ascendens, into the pleurapophysial elements of the third, fourth, fifth, and sixth cervical vertebræ. In other words, the muscular fibres extend from rib to rib, from the sacrum to the third cervical vertebra.

"The longissimus dorsi, situated nearer the spine than the sacro-lumbalis, is inserted (1) into the metapophysial spine of the lumbar diapophyses; (2) into the diapophyses of all the dorsal vertebræ, near the origin of the levatores costarum; (3) through the medium of the transversalis colli into the diapophyses of the second, third, fourth, fifth, and sixth cervical vertebræ; and (4) through the medium of the trachelo-mastoid into the mastoid process, or the only element of a transverse process possessed by the parietal vertebra. In other words, its fibres extend from diapophysis to diapophysis, from the sacrum, upwards, to the parietal vertebra."—*Homologies of the Human Skeleton*, by H. Coote, p. 75.

Cut transversely through the middle of the complexus, and reflect it to see the *arteria cervicalis profunda* (p. 137), and the posterior branches of the cervical nerves.

Dissection to expose the Fifth Layer. Remove the complexus, and then turn aside the erector spinæ and its prolongations, when the *fifth layer* of muscles will be seen occupying the interval between the spinous and transverse processes.

Transverso-spinalis. This is the mass of muscle which lies in the vertebral groove after the reflection of the complexus and the erector spinæ. It consists of a series of fibres which extend from the transverse and articular processes to the spinous processes of the dorsal and cervical vertebræ, and is for convenience divided into the *semispinalis dorsi* and *semispinalis colli*.

a. The *semispinalis dorsi* arises by long thin tendinous slips from the transverse process of the dorsal vertebræ, from the sixth to the tenth, and is inserted into the spinous processes of the four upper dorsal and the two or three lower cervical vertebræ. Its nerves are derived from the internal posterior branches of the dorsal nerves.

b. The *semispinalis colli* lies beneath the complexus, and arises from the transverse processes of the five or six upper dorsal vertebræ, and the articular processes of the four lower cervical, and is inserted into the spinous processes of the axis and the three or four succeeding vertebræ, that into the axis being the most fleshy fasciculus. It is supplied by the internal posterior branches of the cervical nerves.

Now reflect part of the semi-spinalis dorsi in order to expose the multifidus spinæ.

Multifidus Spinæ. This may be considered a part of the preceding muscle, since its fixed points and the direction of its fibres are the same. It consists of a series of little muscles which extend between the spinous and transverse processes of the vertebræ, from the sacrum to the second cervical vertebræ. Those in the lumbar region are the largest. In the sacral region the fibres arise from the back of the sacrum as low down as the fourth foramen, from the deep surface of the aponeurosis of the erector spinæ, from the inner part of the posterior superior iliac spine, and from the posterior sacro-iliac ligament; in the lumbar region, from the mammillary processes on the superior articular processes; in the dorsal region, from the transverse processes, and in the cervical region from the articular processes of the four lower cervical vertebræ. They all ascend obliquely, and each fasciculus is inserted into the lamina and spinous process of the vertebra above, except the atlas. It should be observed that their fibres are not of uniform length; some extend only from vertebra to vertebra, while others extend between one, two, or even three vertebræ. It is supplied by the internal posterior branches of the sacral, lumbar, dorsal, and cervical nerves.

Rotatores Spinæ. Beneath the multifidus spinæ, in the dorsal region of the spine only, are eleven flat and somewhat square muscles, called *rotatores spinæ*. They arise from the upper and back part of the transverse processes, and are inserted into the lower border of the laminae of the vertebra above. These muscles form but a part of the multifidus spinæ, and are supplied by the internal posterior branches of the dorsal nerves.

The action of the preceding muscles is not only to assist in maintaining the trunk erect, but to incline and rotate the spine to one or the other side. They are all supplied by the posterior branches of the spinal nerves.

Levatores Costarum. These small muscles, twelve in number, on each side, arise from the apices of the transverse processes of the seventh cervical and the eleventh upper dorsal vertebræ, and are inserted into the

rib below. The direction of their fibres corresponds with that of the outer layer of the intercostal muscles, and they are supplied by the internal posterior branches of the dorsal nerves. They are muscles of inspiration.

Supra-spinales. These are formed by a series of small muscular slips lying over the spinous processes of the cervical vertebrae. Their nerves are derived from the internal posterior branches of the cervical nerves.

Inter-spinales. These muscles extend between the spinous processes of the contiguous vertebrae. They are arranged in pairs, and only exist in those parts of the vertebral column which are most moveable. In the cervical region they are the most distinct and pass between the spinous processes of the six lower cervical vertebrae. In the dorsal they are found between the spinous processes of the first and second, and between those of the eleventh and twelfth dorsal vertebrae. They are also found more or less distinctly between the spinous processes of the lumbar vertebrae. They are supplied by the internal posterior branches of the spinal nerves.

Inter-transversales. These muscles extend between the transverse processes of the vertebrae. In the *cervical region* they are seven in number, and are most marked, being arranged in pairs, and extend between the anterior and posterior tubercles of contiguous vertebrae. The anterior branch of the corresponding cervical nerve separates the two fasciculi. In the *dorsal region* these muscles in the upper part are represented by small round tendons, but in the three lower dorsal vertebrae they again become muscular in structure. In the *lumbar region* the muscular fasciculi are four in number, and are also arranged in pairs between the transverse processes. Their nerve-supply is derived from the internal posterior branches of the cervical, dorsal, and lumbar nerves.

We have next to examine the muscles concerned in the movements of the head upon the first and second cervical vertebrae (Fig. 104).

Rectus Capitis Posticus Major. This is a largely developed interspinal muscle. It *arises* by a small tendon from the well-marked spinous process of the second cervical vertebra, and, expanding considerably, is *inserted* into the inferior curved ridge of the occipital bone, and into the surface of the bone below it. These recti muscles, as they ascend, one on each side, to their insertions, diverge and leave an interval between them in which are found the recti capitis postici minores.

Rectus Capitis Posticus Minor. This is an interspinal muscle, but smaller than the preceding. *Arising* from the posterior tubercle of the first vertebra, it expands as it ascends, and is *inserted* into the occipital bone between the inferior curved ridge and the foramen magnum. The *action* of the two preceding muscles is to raise the head. They are supplied with nerves from the posterior branch of the suboccipital.

Obliquus Inferior. This *arises* from the spinous process of the second cervical vertebra, and is *inserted* into the transverse process of the first. Its *action* is to rotate the first upon the second vertebra; in other words, to turn the head round to the same side. It is supplied with a nerve by the great occipital (posterior division of the second cervical), which curves up under its lower border.

Obliquus Superior. This muscle *arises* from the transverse process of the atlas, and, ascending obliquely inwards, is *inserted* in the interval between the curved ridges of the occipital bone. Its *action* is to draw the occiput towards the spine.

Suboccipital Triangle. Observe that the obliqui (superior and inferior) and the rectus capitis posticus major form what is called the *suboccipital triangle*. The outer side is formed by the obliquus superior; the

inner, by the *rectus capitis posticus major*; the lower, by the *obliquus inferior*. Within this triangle may be seen the arch of the atlas, the vertebral artery lying in a groove on its upper surface, and the posterior occipito-atloid ligament. Between the artery and the bone appears the posterior division of the suboccipital nerve, which here sends branches to the *recti postici*, the *obliqui*, and the complexus; that is to say, it supplies the muscles which form the triangle, and the complexus that covers it.

Rectus Capitis Lateralis.

This small muscle extends between the transverse process of the first vertebra and the *eminentia jugularis* of the occiput; but, since this eminence is the transverse process of the occipital vertebra, the muscle should be considered as an intertransverse one. Its nerve comes from the anterior division of the suboccipital.

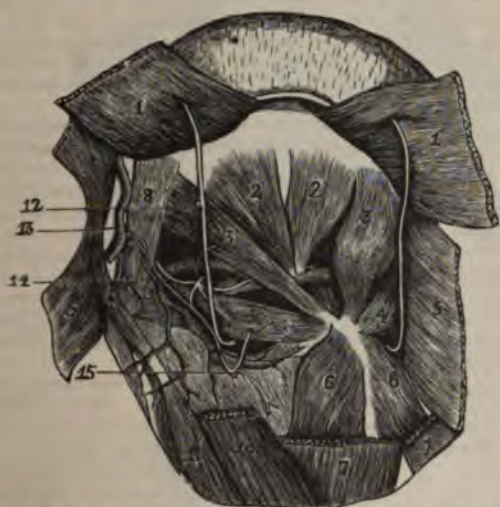


FIG. 104.—DRAWING FROM NATURE, OF THE SUBOCCIPITAL TRIANGLE.

1 and 7. Complexus. 2. Rectus cap. posticus minor. 3. Rectus cap. posticus major. 4. Obliquus inferior. 5. Sterno-mastoid. 6. Semispinalis colli. 8. Obliquus superior. 10. Splenius. 11. Trachelo-mastoid. 12. Great occipital nerve. 13. Occipital artery giving off its descending branch—the *princeps cervicis*. 14. Suboccipital nerve. 15. Third cervical nerve (posterior branch).

Nerves of the Back. The posterior branches of the spinal nerves supply the muscles and skin of the back. They pass backwards between the transverse processes of the vertebrae, and divide into *external* and *internal* branches. The general plan upon which these nerves are arranged is the same throughout the whole length of the spine; but, since there are certain peculiarities deserving of notice in particular situations, we must examine each region separately.

Cervical Region. The posterior division of the *first cervical nerve* (the suboccipital) passes between the arch of the atlas and the vertebral artery; it then enters the suboccipital triangle, and divides into branches which supply the muscles; one, which passes downwards to supply the

inferior oblique, and also sends downwards a branch to communicate with the second cervical nerve; another passes upwards to supply the recti capitis major and minor; another supplies the obliquus superior; another enters the complexus; and, lastly, a cutaneous branch is sometimes given off which accompanies the occipital artery, and is distributed to the back of the scalp.

The posterior branch (the great occipital) of the *second cervical nerve* is the largest of the series, and emerges between the arches of the atlas and axis. It turns upwards beneath the inferior oblique muscle, passes through the complexus, and runs with the occipital artery to the back of the scalp.

The posterior divisions of the six lower cervical nerves divide into *external* and *internal* branches. The *external* are small, and terminate in the splenius, and the continuation of the erector spinæ—viz., the trachelo-mastoid, the transversalis colli, and the cervicalis ascendens. The *internal*, by far the larger, proceed towards the spinous processes of the vertebrae; those of the third, fourth, and fifth lie between the complexus and the semispinalis,* and after supplying the muscles terminate in the skin over the trapezius; those of the sixth, seventh, and eighth lie between the semispinalis and the multifidus spinæ, to which they are distributed, and do not as a rule give off any cutaneous branches.

Dorsal Region.

The posterior divisions of the spinal nerves in this region come out between the transverse processes and the tendons attached to them. They soon divide into *external* and *internal* branches. The *external* pass obliquely over the levatores costarum, between the ilio-costalis and the longissimus dorsi, and successively increase in size from above downwards. The upper six terminate in the erector spinæ and the levatores costarum; the lower six, after supplying these muscles, pass through the latissimus dorsi, and become the cutaneous nerves of the back. The *internal* successively decrease in size from above downwards. They run towards the spine between the semispinalis dorsi and the multifidus spinæ. The upper six, after giving branches to the muscles, perforate the trapezius and become cutaneous nerves. The lower ones terminate in the muscles of the vertebral groove.

Lumbar Region.

The general arrangement of the nerves in this region resembles that of the dorsal. Their *external* branches, after supplying the erector spinæ, become cutaneous and terminate in the skin over the buttock. The *internal* branches supply the multifidus spinæ.

Sacral Region.

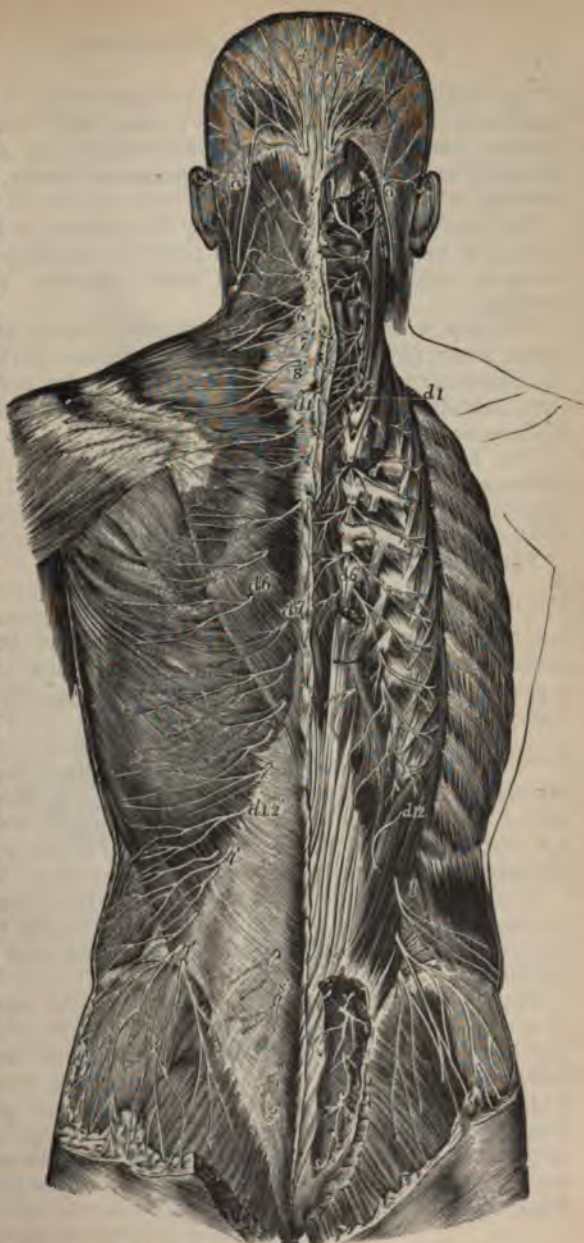
The posterior divisions of the spinal nerves in this region are small. With the exception of the last, they come out of the spinal canal through the foramina in the back of the sacrum. The upper two or three divide into *external* and *internal* branches. The *internal* terminate in the multifidus spinæ; the *external* become cutaneous and supply the skin of the gluteal region. The last two sacral nerves proceed, without dividing, to the integument.

The *coccygeal* nerve is exceedingly small, and, after joining a small branch from the last sacral, terminates in the skin over the coccyx.

The arteries which supply the back are: 1. Small branches from the occipital; 2. Small branches from the vertebral; 3. The deep cervical; 4. The posterior branches of the intercostal and lumbar arteries.

*The posterior branches of the second, third, and fourth nerves are generally connected, beneath the complexus, by branches in the form of loops. This constitutes the *posterior cervical plexus* of some anatomists.

In nerve
 plexus
 musculi
 the first
 and un-
 the
 the
 rectus
 major,
 capital
 and the
 pierce-
 is; the
 is seen
 2', the
 3, ex-
 if the
 y divi-
 nerve;
 ranch,
 nerve;
 sternal
 several
 nerves
 the ex-
 f these
 ng to
 played
 : d 1
 e to d
 scular
 poste-
 riors
 dorsal
 it side;
 sternal
 hes of
 dorsal
 t side;
 ineous
 e six
 nerves
 rnal
 sternal
 poster-
 rches of
 nerves
 pierce-
 s, the
 t over
 in; 1',
 super-
 t side;
 t side,
 ion by
 sterior
 ns of
 s; 2',
 e dis-
 kin on



105.—DIAGRAM OF THE CUTANEOUS NERVES OF THE BACK. (Quain.)

The *occipital artery* furnishes several small branches to the muscles at the back of the neck; one, larger than the rest, the *arteria princeps cervicis*, descends beneath the complexus, and generally inosculates with the deep cervical artery, and with small branches from the vertebral.

The *vertebral artery* runs along the groove in the arch of the atlas, and before perforating the posterior occipito-atloid ligament to enter the skull, distributes small branches to the adjacent muscles.

The *deep cervical artery* is the posterior branch of the first intercostal artery (from the subclavian). It passes backwards between the transverse process of the last cervical vertebra and the first rib; it then ascends between the complexus and the semispinalis colli, and anastomoses with the princeps cervicis.

The *posterior* branches of the intercostal and lumbar arteries accompany the corresponding nerves, and are in all respects similar to them in distribution. Each sends a small branch into the spinal canal (*intraspinal*), and small branches to the vertebra.

The *veins* correspond to the arteries.

Prevertebral Muscles. We have, lastly, to examine three muscles, situated in front of the spine: namely, the longus colli, the rectus capitis anticus major, and the rectus capitis anticus minor. In order to have a complete view of the two latter, a special dissection should be made, before the head is removed from the first vertebra.

Longus Colli. This muscle is situated in front of the spine, and extends from the third dorsal vertebra to the atlas. For convenience of description it is divided into three sets of fibres, of which one extends *longitudinally* from the body of one vertebra to that of another; the two others extend *obliquely* between the transverse processes and the bodies of the vertebræ.

The *longitudinal* portion of the muscle *arises* from the bodies of the three upper dorsal and the three lower cervical vertebræ, and is *inserted* into the bodies of the second, third, and fourth cervical vertebræ.

The *superior oblique* portion, *arising* from the anterior tubercles of the transverse processes of the third, fourth, and fifth cervical vertebræ, ascends inwards, and is *inserted* into the front part or body of the atlas. The *inferior oblique* portion proceeds from the bodies of the three upper dorsal vertebræ, and passing upwards and outwards, is *inserted* into the transverse processes of the fifth and sixth cervical vertebræ. The *action* of this muscle, taken as a whole, must be to bend the cervical region of the spine. Its nerves come from the lower cervical nerves.

**Rectus Capitis
Anticus Major.**

This muscle *arises* by tendinous slips from the anterior tubercles of the transverse processes of the third, fourth, fifth, and sixth cervical vertebræ, and, ascending obliquely inwards, is *inserted* into the basilar process of the occipital bone, in front of the foramen magnum.

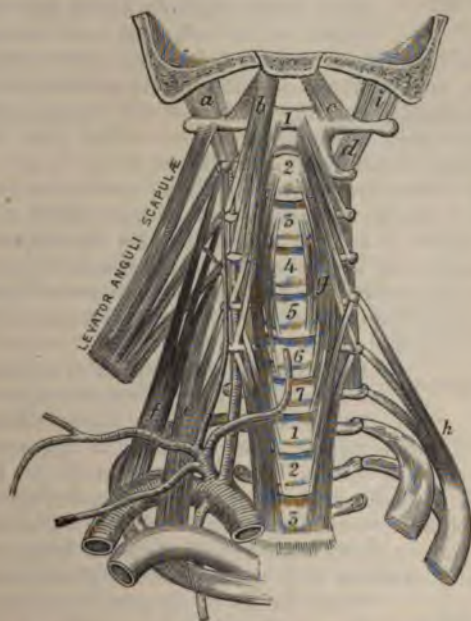

FIG. 105.—DIAGRAM OF THE PREVERTEBRAL MUSCLES.

1-7. The bodies of the cervical vertebræ: below are the bodies of the three upper dorsal vertebræ. *a.* Rectus capitis lateralis. *b.* Rectus capitis anticus major. *c.* Rectus capitis anticus minor. *d.* Intertransverse muscle. *e.* Scalenus anticus. *f.* Scalenus medius. *g.* Longus colli. *h.* Scalenus posticus.

**Rectus Capitis
Anticus Minor.**

This muscle *arises* from the front of the root of the transverse process of the atlas, and is *inserted* into the basilar process of the occipital bone, nearer to the foramen magnum than the preceding muscle. The *action* of the recti muscles is to bend the head forwards. They are supplied with nerves from the anterior division of the sub-occipital, and from the deep cervical plexus.

LIGAMENTS OF THE SPINE.

The vertebræ are connected by their intervertebral fibro-cartilages, by ligaments in front of and behind their bodies, and by ligaments which extend between their arches and their spines. Their articular processes have capsular ligaments, and synovial membranes.

Anterior Common Ligament.

This is a strong, broad band of longitudinal fibres which extends along the front of the bodies of the vertebræ from the axis to the sacrum. The ligament is broader below than above, thickest in the dorsal region, and its fibres are more firmly adherent to the intervertebral cartilages and to the borders of the vertebræ than to the middle of the bones. The fibres are not all of equal length; the more superficial extend from one vertebra to the fourth or fifth below it; those a little deeper pass from one vertebra to the second or third below it, while the deepest of all proceed from vertebra to vertebra. Above, it is attached to the axis by a pointed process, where it is connected with the longus colli, and it is thicker over the bodies of the vertebra than over the intervertebral cartilages, thus filling up the concavities of the bodies and rendering the surface more smooth and even.

Posterior Common Ligament.

This extends longitudinally, in a similar manner to the anterior common ligament, within the spinal canal, along the posterior surface of the bodies of the vertebræ, from the axis to the sacrum. It is broader above than below, and, like the anterior ligament, is thickest in the dorsal region, and is more intimately connected with the intervertebral fibro-cartilages than with the bodies of the vertebræ. It sends up a prolongation to the anterior border of the foramen magnum continuous with the apparatus ligamentosus.

Interspinous Ligaments.

These bands of ligamentous fibres fill up the intervals between the spines of the dorsal and lumbar vertebræ. They are the most marked in the lumbar region. Those fibres which connect the apices of the

Supraspinous Ligament.

spines, being stronger than the rest, are described as a separate ligament under the name of *supraspinous*. It extends from the spinous process of the seventh cervical to the spine of the sacrum, and is strongest in the lumbar region. Their use is to limit the flexion of the spine.

Ligaments between the Arches of the Vertebræ.

These are called, on account of their colour, *ligamenta subflava*. To obtain a good view of them the arches of the vertebræ should be removed with a saw, and the ligaments should be seen from within, since viewed from without they are to a large

extent hidden by the overlapping laminæ. They pass between the laminæ of the contiguous vertebræ from the axis to the sacrum; none existing between the occiput and the atlas, or between the atlas and the axis. Each ligament consists of two halves which are attached to the corresponding half laminæ above and below on each side. They are composed of yellow elastic tissue, the fibres being arranged vertically, and their strength increases with the size of the vertebræ. This elasticity answers a double purpose; it not only permits the spine to bend forwards, but materially assists in restoring it to its *curve of rest*. They economise muscular force, like the ligamentum nuchæ in animals.

Intervertebral Fibro-
cartilage.

This substance, placed between the bodies of the vertebræ, is by far the strongest bond of connection between them, and fulfils most important purposes in the mechanism of the spine. Its peculiar structure is adapted to break shocks and to render the spine flexible and resilient. To see the structure of an intervertebral fibro-cartilage, a horizontal section must be made through it. It is firm and resisting near the circumference, but soft and pulpy towards the centre. The circumferential portion is composed of concentric layers of fibro-cartilage, placed vertically. These layers are attached by their edges to the vertebræ; they gradually decrease in number from the circumference towards the centre; and the interstices between them are filled by soft pulpy tissue. The central portion is composed almost entirely of this pulpy tissue, and it bulges when no longer under pressure. Thus the bodies of the vertebræ, in their motions upon each other, revolve upon an elastic cushion tightly girt all round by bands of fibrous tissue. These motions are regulated by the articular processes.

Dissect an intervertebral substance layer after layer in front, and you will find that the circumferential fibres extend *obliquely* between the vertebræ, crossing each other like the branches of the letter X (Fig. 108).

The thickness of the intervertebral cartilages is not the same in front and behind. It is this difference in their thickness, more than that in the bodies of the vertebræ, which produces the several curves of the spine. In the lumbar and cervical regions they are thicker in front; in the dorsal region, behind.

The structure of the intervertebral cartilages explains the well-known fact that a man becomes shorter after standing for some hours, and that he regains his usual height after rest. The difference between the morning and evening stature amounts to more than half an inch (13 mm.).

It also explains the fact that a permanent lateral curvature of the spine may be produced (especially in the young) by the habitual

practice of leaning to this or that side. Experience proves that the cause of lateral curvature depends more frequently upon some alteration in the structure of the fibro-cartilages than upon the bones. From an examination of the bodies of one hundred and thirty-four individuals with crooked spines, it was concluded that, in two-thirds, the bones were perfectly healthy; that the most frequent cause of curvature resided in the intervertebral substances, these being, on the concave side of the curve, almost absorbed, and, on the convex side, preternaturally developed. As might be expected in these cases, the muscles on the convex side become lengthened, and degenerate in structure.*

Ligamentum Nuchæ. This ligament is a thin, fibrous septum, intermingled with elastic tissue, situated in the middle line, and extends from the spinous processes of the cervical vertebræ to the external occipital protuberance. It forms an intermuscular septum down the back of the neck, and may be regarded as the continuation upwards of the supraspinous ligament.

Capsular Ligaments. Each joint between the articular processes has a synovial membrane surrounded by loose ligamentous fibres, forming a capsular ligament which is longest in the cervical vertebræ, thus allowing free movement in this region. The surfaces of the bones are crusted with cartilage

Intertransverse Ligaments. These are thin bands of fibres which pass between the transverse processes of the vertebræ. They are rudimentary in the cervical region, and are sometimes absent.

Movements of the Spine. Though but little movement is permitted between any two vertebræ (the atlas and axis excepted), yet the collective motion between them all is considerable. The spine can be bent forwards, backwards, or on either side; it also admits of slight rotation. In consequence of the elasticity of the intervertebral cartilages and the ligamenta subflava, it returns spontaneously to its natural curve of rest like an elastic bow. Its mobility is greatest in the cervical region, on account of the thickness of the fibro-cartilages, the small size of the vertebræ, the oblique direction of their articulations, and, above all, the horizontal position and the shortness of their spines. In the dorsal region there is very little mobility, on account of the vertical direction of the articular processes, and the manner in which the arches and the spines overlap each other. In the lumbar region, the spine again becomes more movable, on account of the thickness of the intervertebral cartilages, and the horizontal direction of the spinous processes.

* On this subject see Hildebrandt's *Anatomie*, B. ii, s. 155.

Ligaments between
the Occipital Bone
and the Atlas.

The occiput is connected to the atlas by the following ligaments: viz., two anterior occipito-atloid, a posterior occipito-atloid, two lateral occipito-atloid, and two capsular ligaments.

The *two anterior ligaments** are composed of a superficial and a deep portion; the *superficial* part is a strong rounded cord which passes from the basilar process above, to the tubercle on the anterior arch of the atlas below; the *deep* portion is membranous, and passes from the anterior margin of the foramen magnum to the front arch of the atlas.

The *posterior ligament* extends in a similar manner from the posterior border of the foramen magnum to the posterior arch of the atlas. It is thin, and superiorly becomes blended with the dura mater, and is pierced by the vertebral artery and the suboccipital nerve.

The *two lateral ligaments* pass from the jugular eminences of the occiput downwards and outwards to the transverse processes of the atlas.

The *capsular ligaments* extend from the margin of the condyles of the occipital bone to the upper articular borders of the atlas.

The movements which take place between the occipital bone and the atlas are flexion and extension, as in nodding forwards and backwards; and lateral movement, as in inclining the head sideways.

Ligaments between
the Occipital Bone
and the Axis.

These are the most important; and to see them the spinal canal must be exposed by removing the posterior arches of the upper cervical vertebræ and the posterior common ligament, which is here very thick and strong. It ascends from the posterior surface of the axis, then passes over the odontoid and transverse ligaments, and is attached to the basilar process of the occipital bone. It is called the *occipito axial ligament*, or the *apparatus ligamentosus colli*.

Odontoid or Check
Ligaments.

The *odontoid or check ligaments* (Fig. 107) are two very strong ligaments, which proceed from the sides of the odontoid process to the tubercles on the inner sides of the condyles of the occiput. Their use is to limit the rotation of the head. A *third or middle odontoid ligament* passes from the apex of the odontoid process to the margin of the foramen magnum. It is sometimes called the *ligamentum suspensorium*.

* These ligaments are by some authors described as one. (A. H.)

Articulation between
the Atlas and the
Axis.

This joint forms a lateral ginglymus or diarthrosis rotatoria, and is maintained by the following ligaments: two anterior atlo-axial, a posterior atlo-axial, two capsular, and a transverse.

The *two anterior ligaments* consist of a superficial and a deep portion: the *superficial* is a rounded ligament passing from the tubercle of the atlas to the base of the odontoid process; the *deep* passes as a membranous layer from the anterior arch of the atlas to the body of the axis.

The *posterior ligament* extends from the posterior arch of the atlas to the upper border of the lamina of the axis.

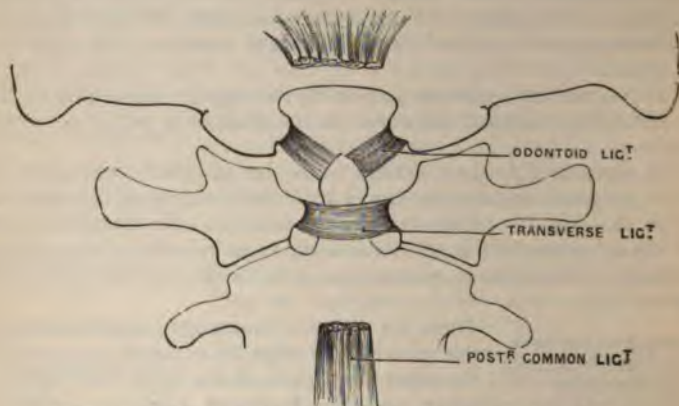


FIG. 107.—DIAGRAM OF THE ODONTOID AND TRANSVERSE LIGAMENTS.

The *capsular ligaments* are thin, loose, ligamentous sacs connecting the borders of the articular surfaces.

The *transverse ligament* (Fig. 107) passes transversely behind the odontoid process and is attached to the tubercles on the inner sides of the articular processes of the atlas. From the centre of this ligament a few fibres pass upwards, to be attached to the basilar process, and some downwards to the body of the axis, giving it a cruciform appearance. Thus it forms with the atlas a ring, into which the odontoid process is received. If this transverse ligament be divided we observe that the odontoid process is covered with cartilage in front and behind, and is provided with two synovial membranes.

The ribs articulate by their heads with the bodies of the dorsal

vertebræ ; by their necks and tubercles with the transverse processes of the vertebræ, and by their cartilages with the sternum in front.

Articulations of the Heads of the Ribs with the Bodies of the Vertebræ.

The head of each rib presents two articular surfaces, corresponding to the bodies of two vertebræ. There are two distinct articulations, each provided with a separate synovial membrane. The ligaments are—

1. An *anterior costo-central* or *stellate*, which connects the front of the head of the rib with the sides of the bodies of two vertebræ and the intervening fibro-cartilage (Fig. 108). It is composed of three fasciculi of fibres which radiate from the rib, one of which passes upwards to be attached to the body of the vertebra above ; the lower one passes to the body of the vertebra below ; while the intermediate one passes horizontally forward to the intervertebral disc.

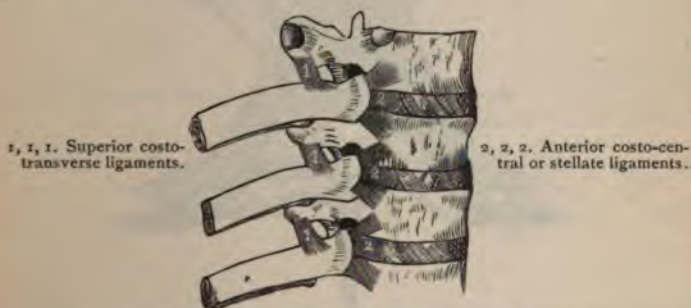

FIG. 108.—COSTO-VERTEBRAL LIGAMENTS.

In the three lower ribs the fasciculi are not separately distinguishable, although the fibres pass upwards to the vertebræ and downwards to the vertebra with which the rib articulates.

Some anatomists describe a capsular ligament surrounding the articulation ; the fibres are very thin, and form part of the costo-central ligament.

2. An *interarticular ligament* which passes across the joint from the ridge on the head of the rib to the intervertebral cartilage. It divides the articulation into two joints which do not communicate with each other. It is absent in the three lower articulations.

Articulations of the Neck and Tubercle of the Ribs with the Transverse Processes.

The ligaments connecting these bones are the capsular, the anterior, middle, and posterior costo-transverse.

The *capsular ligament* surrounds the articular surfaces of the

tubercle of the rib and the transverse process of its corresponding vertebra, and has a synovial membrane. It is absent in the eleventh and twelfth ribs.

The *anterior or superior costo-transverse ligament* ascends from the upper border of the neck of the rib to the lower border of the transverse process above it. It is continuous externally with the aponeurosis covering the external intercostal muscle. The first and twelfth ribs have no anterior costo-transverse ligament (Fig. 108).

The *middle costo-transverse ligament* is an interosseous one, and connects the adjacent surfaces of the neck of the rib, and the transverse process. It is badly developed in the eleventh and twelfth ribs (Fig. 109).

The *posterior costo-transverse ligament* passes from the apex of

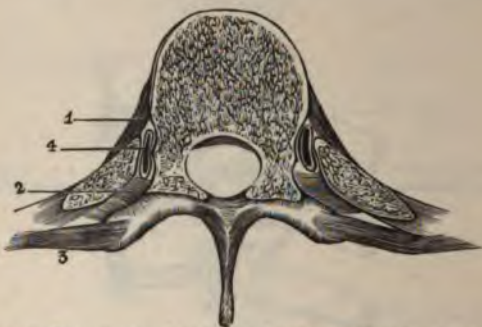

FIG. 109.—DIAGRAM SHOWING THE LIGAMENTS CONNECTING THE RIB WITH THE VERTEBRA.
1. The anterior costo-central ligament. 2. The interosseous, or middle costo-transverse ligament. 3. The posterior costo-transverse ligament. 4. The synovial membrane between the rib and the body of the vertebra.

the transverse process to the summit of the tubercle of the rib. It is wanting in the eleventh and twelfth ribs (Fig. 109).

Connection between the Cartilages of the Ribs and Sternum.

The anterior extremities of the ribs are concave, and receive the cartilages of the ribs; this junction is maintained by the periosteum.

The cartilages of all the true ribs are received into slight concavities on the side of the sternum, and are secured by *anterior, posterior, upper, and lower ligaments*. There is a synovial membrane between the cartilage of each rib and the sternum, except that of the first, and usually at each articulation the synovial membrane is separated into two by an interarticular ligament.

The *costal cartilages from the sixth to the tenth* are connected by ligamentous fibres. There are intercostal synovial membranes in

front between the adjacent borders of the sixth, seventh, eighth, and ninth costal cartilages.

**Movements of the
Ribs.**

The movements permitted between the heads of the ribs and the bodies of the vertebræ are those of elevation and depression, and those of rotation forwards and backwards; the centre of these movements being at the interarticular ligament. Between the tubercles and the transverse processes there is the movement of an arthrodial nature;

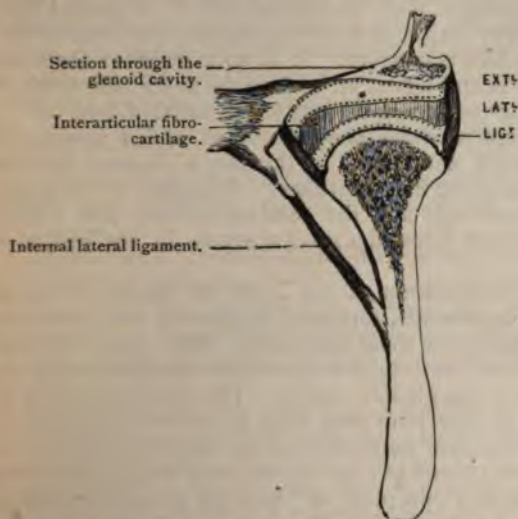


FIG. 110.—TRANSVERSE SECTION TO SHOW THE LIGAMENTS AND THE FIBRO-CARTILAGE OF THE JOINT OF THE LOWER JAW. THE DOTTED LINES REPRESENT THE TWO SYNOVIAL MEMBRANES.

and between the costal cartilages and the sternum that of elevation and depression.

The movement of the first rib is very slight; that of the second is freer; and mobility of the ribs gradually increases from above downwards.

**Articulation of the
Lower Jaw.**

The condyle of the lower jaw articulates with the glenoid cavity of the temporal bone, and forms an arthrodial joint. The joint is provided with an interarticular fibro-cartilage, with external and internal lateral and capsular ligaments, and two synovial membranes (Fig. 110).

The *external lateral ligament* extends from the zygoma and its

tubercle ; its fibres pass downwards and backwards to the outer surface and posterior border of the neck of the jaw.

The *internal lateral ligament*—a long, thin, flat band—extends from the spinous process of the sphenoid bone to the inner border of the dental foramen.

The *capsular ligament* consists of a few scattered fibres attached above to the margin of the glenoid cavity, below to the neck of the jaw.

The *interarticular fibro-cartilage* is a thin plate of an oval form, and thicker at the margin than at the centre. It is placed horizontally, and its upper surface is concavo-convex from before backwards ; its lower surface is concave. It is connected on the outer side to the external lateral ligament, and on the inner side some of the fibres of the external pterygoid muscle are inserted into it.

There are two *synovial membranes*—an upper and a lower—for the joint. The larger and looser of the two is situated between the glenoid cavity and the fibro-cartilage. The lower is interposed between the fibro-cartilage and the condyle of the jaw. They sometimes communicate through a small aperture in the centre of the fibro-cartilage.

The form of the articulation of the lower jaw admits of movement upwards and downwards, forwards, backwards, and from side to side. A combination of these movements takes place in mastication ; during this act the condyles of the jaw describe an oblique rotatory movement in the glenoid cavity. The purposes served by the fibro-cartilage in this joint are : first, it follows the condyle, and interposes a convenient socket for all its movements ; second, being elastic, it breaks shocks ; for shocks here would be almost fatal, considering what a thin plate of bone the glenoid cavity is, and that just above it is the brain. Its *nerves* are derived from the auriculo-temporal and the masseteric branches of the inferior maxillary.

The stylo-hyoid and stylo-maxillary ligaments have been previously described.

DISSECTION OF THE UPPER EXTREMITY.

The subject should be placed on its back, and, the thorax being raised by a block placed under the shoulders, the arm is to be extended to a right angle with the trunk and slightly rotated outwards. A narrow board must be placed under the arm to keep it in position, and the hand, with the palm upwards, is to be firmly encircled by string to the board.

Surface Marking. Before commencing the dissection of the arm, the student should carefully examine with the eye and the finger the various inequalities of the surface of the skin, which are caused by, or are landmarks of, important subjacent structures.

Beginning in the middle line, we notice a broad, shallow groove in front of the sternum between the sternal origins of the pectoralis major; about two inches (*5 cm.*) below the upper border of the sternum is a prominent transverse bony ridge (*angulus sterni*), which corresponds to the junction of the first and second portions of the sternum.

The clavicle may be easily traced, convex as to its sternal half, and concave in its outer half; not placed quite horizontally, but inclined upwards in the present position of the limb, and articulating externally with the prominent acromion process. Extending obliquely downwards and outwards, from the middle of the clavicle, is a groove, marking the separation between the contiguous borders of the deltoid and pectoralis major, and in which may, by deep pressure, be felt the coracoid process. Another groove, passing outwards from the sterno-clavicular joint, indicates the interval between the sternal and clavicular attachments of the pectoralis major. The upper arm below the acromion is rounded, the convexity being caused by the greater and lesser tuberosities of the humerus. In the more common forms of dislocations of the humerus, this roundness is lost, and a depression takes its place. Between the thorax and the arm there is a deep hollow—the axilla—which varies according to the position of the arm to the side. Its front border is formed by the pectoralis major, and its hinder border by the latissimus dorsi; and if the fingers be pushed up into this space, the head of the humerus can easily be felt. The free border of the pectoralis major muscle corresponds with the fifth rib, and below this can be distinguished

the lower digitations of the serratus magnus with the external oblique.

Dissection.

The student must now make three incisions through the skin; the first, along the middle of the whole length of the sternum; the second, along the lower border of the clavicle, and down along the front of the upper arm for four inches (10 cm.); the third, from the ensiform cartilage, backwards to the posterior border of the axilla.

The skin should now be taken up with the forceps at the upper and inner angle, and when the skin has been so far reflected as to enable the fingers to take it up, lay aside the forceps and use the fingers in their place. The skin should be carefully dissected from the subjacent layer of subcutaneous fascia and fat. In doing so, notice the thin, pale fibres of the broad subcutaneous muscle of the neck—*platysma myoides* (Fig. 14).

Beneath this subcutaneous fascia and fat there is the strong deep fascia which closely invests the muscles, and in the axilla it forms a dense fascia which passes from the pectoralis major to the latissimus dorsi.

Cutaneous Nerves.

The numerous nerves which run through the subcutaneous tissue to the skin and mammary gland must be carefully dissected out. They are derived from various sources; some, branches of the superficial cervical plexus, descend over the clavicle; others, branches of the intercostal nerves, come through the intercostal spaces close to the sternum, each with a small artery; a third series, also branches of the intercostal nerves, come out on the side of the chest and run forwards over the outer border of the pectoralis major.

The *supra-clavicular nerves*, which arise from the third and the fourth cervical nerves, descend over the clavicle, and are subdivided, according to their direction, into *sternal*, *clavicular*, and *acromial* branches (Fig. 32, p. 83). The *inner or sternal* cross the inner end of the clavicle to supply the skin over the upper part of the sternum. The *middle or clavicular* pass over the middle of the clavicle and supply the integument over the front of the chest and the mammary gland. The *outer or acromial* branches cross over the outer end of the clavicle and distribute their filaments to the skin of the shoulder.

Near the sternum are found the *anterior cutaneous branches* or terminal filaments of the *intercostal nerves*. After piercing the internal intercostal and pectoralis major muscles each nerve sends an inner filament to the skin over the sternum, and an outer larger one, which supplies the skin over the pectoral muscle. Those of the third and fourth intercostal supply also the mammary gland.

Branches of the internal mammary artery, for the supply of the mammary gland, accompany these nerves. During lactation they increase in size, ramifying tortuously over the surface of the gland. They are occasionally as large as the radial at the wrist.

The *lateral cutaneous branches of the intercostal nerves* come out between the digitations of the serratus magnus on the side of the chest, and divide into anterior and posterior branches. The *anterior* branches curve round the free border of the pectoralis major, and then supply the skin over that muscle and the mamma. The *posterior* branches supply the skin of the back of the chest.

Dissection. Dissect off the superficial fascia and fat with the mammary gland. Thus you will expose the strong *deep fascia*, which is closely attached to the pectoralis major and deltoid muscles. It is continuous, above, with the fascia of the neck; below, with that of the arm. At the axilla it becomes denser, where it passes from the pectoral to the latissimus dorsi muscles.

Reflect this fascia from the pectoralis major by dissecting parallel with the course of its fibres. The muscle having been fully exposed, observe its shape, the course of its fibres, their origin, and insertion.*

Pectoralis Major. The pectoralis major is the large triangular muscle in the front of the chest. It *arises* from the anterior surface of the sternal half of the clavicle, from the front of its own half of the sternum, from the cartilages of all the true ribs except the last, and from the aponeurosis of the external oblique muscle of the abdomen. From this extensive origin the fibres converge towards the arm, the upper ones passing downwards and outwards, the middle ones transversely outwards, and the lower fibres upwards and outwards; they terminate in a flat tendon, about two inches in breadth, which is *inserted* into the anterior margin of the bicipital groove of the humerus. The arrangement of its fibres, as well as the structure of its tendon, is peculiar. The lower fibres, which form the boundary of the axilla, are folded beneath the rest, and terminate upon the upper part of the tendon—*i. e.*, nearer to the shoulder-joint; the upper fibres, which arise from the clavicle and are frequently separated from the main body of the muscle by a slight interval, descend in front of the lower and terminate upon the lower part of the tendon. Consequently the upper and lower fibres of the muscles cross each other previously to their insertion (Fig. 112, p. 301).

The object of this arrangement is to enable all the fibres to act simultaneously when the arm is extended.

The upper part of the tendon sends off a fibrous prolongation, which binds down the long head of the biceps, and is attached to the great tuberosity of the humerus; another tendinous expansion is prolonged backwards to the tendon of the deltoid muscle; and a third passes downwards to be intimately connected with the fascia of the upper arm.

The chief *action* of the pectoralis major is to draw the humerus

* Sometimes we find a thin, little muscle running perpendicularly in front of the inner part of the pectoralis major. This is the *rectus sternalis* or *sternalis brutorum*. It arises inferiorly by a tendinous expansion from the rectus abdominis, and is connected above to the tendon of the sterno-mastoid.

towards the chest, as in placing the hand on the opposite shoulder, or in pulling an object towards the body. When the arm is raised and made the fixed point the muscle assists in raising the trunk, as in climbing. Thus, too, on emergency, it can act as an auxiliary muscle of inspiration.

Between the pectoralis major and the deltoid, the great muscle covering the shoulder, is an interval varying in extent in different subjects, but always more marked towards the clavicle. It contains a small artery—the *thoracica humeraria*—and the *cephalic vein*, which ascends on the outer side of the arm and empties itself into the axillary. This interval is the proper place to feel for the coracoid process. In doubtful injuries about the shoulder this point of bone is a good landmark in helping the surgeon to arrive at a correct diagnosis.

The pectoralis major is supplied with nerves by the anterior thoracic branches of the brachial plexus; with blood, by the long and short thoracic branches of the axillary artery.

Dissection. Anatomy of the Infra-clavicular Region.

Reflect the clavicular part of the pectoralis major by detaching it from the clavicle, and turn it downwards; in doing so, notice a small nerve, the external anterior thoracic, which enters the under surface of this part of the muscle. Beneath the portion thus reflected, part of the pectoralis minor will be exposed. In this triangle—bounded, above, by the clavicle; below, by the upper border of the sternal origin of the pectoralis major; and, on the outer side, by the deltoid—is an important space in which the relative position of the following objects must be carefully examined:—

Costo-coracoid Membrane.

a. A strong ligamentous expansion, called the *costo-coracoid membrane*, extends from the cartilage of the first rib to the coracoid process.

Between these points it is attached to the clavicle, and forms a complete investment for the subclavius muscle. Its lower crescent-shaped edge arches over, and protects the axillary vessels and nerves; from this edge is prolonged downwards a funnel-shaped fascia, which covers the axillary vessels, forming the anterior portion of their sheath, the posterior being formed by a prolongation of the deep cervical fascia. The front portion of this sheath is perforated by the cephalic vein, the thoracica acromialis artery and vein, the anterior thoracic nerves, and the superior thoracic artery. This fascia must be removed.

b. The subclavius muscle enclosed in its fibrous sheath.

c. The axillary vein, artery, and brachial plexus of nerves.

d. Two arteries, the superior or short thoracic and the thoracica acromialis.

e. The termination of the cephalic vein in the axillary.

f. Two nerves, the anterior thoracic, which descend from the brachial plexus below the clavicle, and cross in front of the axillary vessels to supply the pectoral muscles.

Subclavius.

This muscle lies between the clavicle and the first rib. It *arises* from the first rib by a short round tendon at the junction of the bone and cartilage in front of the costo-clavicular ligament, and is *inserted* into the groove on the under surface of the clavicle as far outwards as the coraco-clavicular ligament. Its nerve comes from the fifth and sixth cervical nerves. Its *action* is to depress the clavicle, and prevent its too great elevation (Fig. 112, p. 301).

Relative Position of the Axillary Vessels and Nerves.

In the infra-clavicular space before us are the great vessels and nerves of the axilla in the first part of their course. They lie at a great depth from the surface. They are surrounded by a sheath of fascia, which descends with them beneath the clavicle. Their relations with regard to each other are as follows: The axillary vein lies in front of the artery, and rather to its thoracic side. The brachial plexus of nerves is situated above the artery, and on a posterior plane. The plexus consists of two, or sometimes three, large cords, which result from the union of the anterior branches of the four lower cervical, and the first dorsal nerves. The course and relations of the axillary artery will be examined subsequently.

Superior Thoracic and Acromio-thoracic Arteries.

These are two branches which arise from the axillary artery in the first part of its course, above the pectoralis minor. The *superior thoracic* frequently arises in common with the acromio-thoracic, and passing along the upper border of the pectoralis minor, descends between this muscle and the pectoralis major, supplying both and anastomosing with the intercostal and internal mammary arteries. The *thoracica acromialis* is given off just above the pectoralis minor, and shortly divides into three sets of branches: viz., two or three small *thoracic branches* to the serratus magnus and pectoral muscles; the *thoracica humeraria*, which descends with the cephalic vein, in the interval between the pectoralis major and deltoid, and ramifies in both; and lastly, the *acromial branch*, which passes over the coracoid process to the under surface of the deltoid, which it supplies, and communicates with the posterior circumflex, a branch of the axillary, and the supra-scapular, a branch of the subclavian. A constant though small branch, the *clavicular*, runs along the anterior aspect of the subclavius. All these arteries are accompanied by veins, which most frequently empty themselves into the cephalic, but occasionally into the axillary vein.

Cephalic Vein. The cephalic vein is one of the principal cutaneous veins of the arm. Commencing on the back of the thumb and forefinger, it runs up the radial side of the forearm, in front of the elbow-joint; thence ascending along the outer edge of the biceps, it runs up the interval between the pectoralis major and deltoid, pierces the costo-coracoid membrane, crosses over the axillary artery, and finally empties itself into the axillary vein.*

Anterior Thoracic Nerves.

These nerves come from the brachial plexus below the clavicle to supply the pectoral muscles. There are generally two—an external and an internal—one for each pectoral muscle. The *external*, the more superficial, arises from the outer cord of the brachial plexus, passes over the axillary artery and vein, pierces the costo-coracoid membrane, and supplies the pectoralis major on its under aspect: it communicates with the next nerve by a filament which forms a loop on the inner side of the artery; the *internal*, and smaller branch, comes from the internal cord, and descends between the axillary artery and vein (occasionally through the vein) to supply the pectoralis minor on its under surface.

Difficulty of Tying the First Part of the Axillary Artery.

From this view of the relations of the axillary artery in the first part of its course, some idea may be formed of the difficulty of passing a ligature round it in this situation. In addition to its great depth from the surface, varieties sometimes occur in the position of the nerves and veins, which render the operation still more embarrassing. For instance, the anterior thoracic nerves may be more numerous than usual, and form by their mutual communication a plexus around the artery. A large nerve is often seen crossing obliquely over the artery, immediately below the clavicle, to form one of the roots of the median nerve. The cephalic vein may ascend higher than usual, and open into the subclavian; and as it receives large veins corresponding to the thoracic axis, a concurrence of veins would be met with in front of the artery. Again, it is by no means uncommon to find a deep-seated vein, the supra-scapular, crossing over the artery to join the axillary vein.

DISSECTION OF THE AXILLA.

On the under surface of the skin of the axilla, near the roots of the hairs, are numerous sebaceous glands. They are of a reddish-brown colour, and rather larger than a pin's head.

* The cephalic vein, in some cases, runs over the clavicle to join the external jugular; or there may be a communication (termed jugulo-cephalic) between these veins.

Axillary Fascia.

This dense fascia, which lies immediately beneath the skin of the axilla, is a continuation of the general fascial investment of the muscles. It closes in and forms the floor of the cavity of the axilla. Externally, it is strengthened by fibres from the tendons of the pectoralis major and latissimus dorsi, and is continuous with the fascia of the arm; internally, it is prolonged on the side of the chest, over the serratus magnus muscle; in front and behind, it divides, so as to enclose between its layers the muscles which form the boundaries of the axilla. Thus the anterior layer encloses the two pectoral muscles, and is connected with the coracoid process, the costo-coracoid ligament, and the clavicle; the posterior layer encloses the latissimus dorsi, and passes backwards to the spine.

A subcutaneous artery, sometimes of considerable size, is often found in the substance of the axillary fascia. It generally arises from the brachial, or from the lower part of the axillary artery, and runs across the floor of the axilla towards the lower edge of the pectoralis major. It is not a named branch, but should be remembered, as it would occasion much hæmorrhage if wounded in opening an abscess.

Dissection and Contents of the Axilla.

Reflect the axillary fascia, to display the boundaries and the contents of the axilla. The dissection of this space is difficult, and must be done cautiously. Bear in mind that the trunk blood-vessels and nerves run through the *upper* and *outer* part of the axilla; that the long thoracic artery runs along the *anterior* border, and the subscapular artery along the *posterior*. Commence dissecting, therefore, in the middle; break down with the handle of the scalpel the loose connective tissue, fat, and lymphatic glands, which occupy the cavity. You will soon discover some cutaneous nerves coming out between the ribs, and then crossing the axillary space. These nerves are the *posterior lateral cutaneous branches of the intercostal nerves*; they perforate the intercostal spaces between the digitations of the serratus magnus, midway between the sternum and the spine, and divide into anterior and posterior branches. The *anterior* turn over the pectoralis major, to supply the skin on the front of the chest and the mammary gland. The *posterior* pass backwards over the latissimus dorsi, and are distributed to the skin covering this muscle and the scapula.

Intercosto-humeral Nerves.

The posterior lateral branch of the second intercostal nerve requires a special description. It is larger than the others, and is called the *intercosto-humeral* because it supplies the integuments of the arm. It comes through the second intercostal space, traverses the upper part of the axilla, where it receives a branch of the lesser internal

cutaneous nerve (nerve of Wrisberg), and, piercing the fascia, terminates in filaments, which are distributed to the skin on the inner side and back of the arm, as low as the internal condyle. The corresponding branch of the third intercostal is also an *intercosto-humeral* nerve. It receives a branch from the second, and runs a similar course. The distribution of these nerves accounts for the pain down the arm which is sometimes experienced in pleurisy.

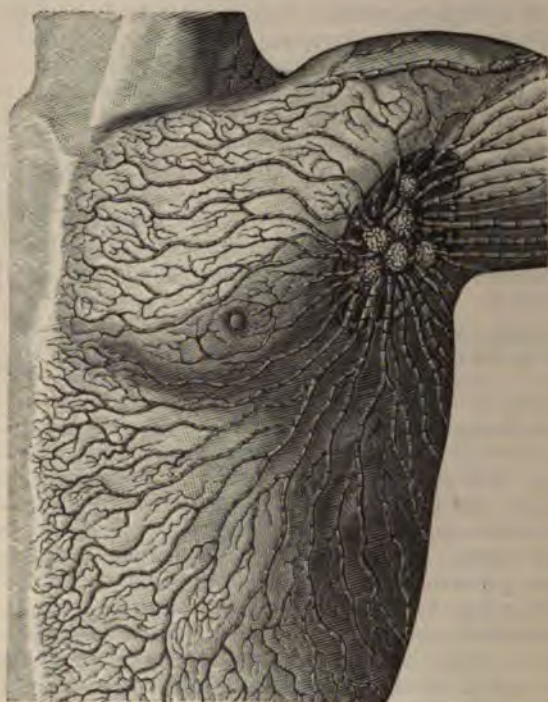


FIG. 111.—THORACIC AND BRACHIAL LYMPHATIC VESSELS EMPTING INTO THE AXILLARY LYMPHATIC GLANDS.

Boundaries of the Axilla.

The axilla is a conical space, of which the *apex* is beneath the clavicle, and the *base* between the pectoralis major and the latissimus dorsi. Obviously it varies in capacity according to the position of the arm to the side. On the *inner* side, it is bounded by the four upper ribs, with their corresponding intercostal muscles and the serratus magnus; on the *outer*, by the humerus, covered by the coraco-

brachialis and biceps; *in front*, by the pectoralis major and minor; *behind*, by the latissimus dorsi, teres major, and subscapularis. Its anterior and posterior boundaries converge from the chest, so that the axilla becomes narrower towards the arm. With a full view of the axilla before you, bear in mind that pus may burrow under the pectoral muscles, or under the scapula, or that it may run up beneath the clavicle and point in the neck, if the abscess be allowed to remain unopened (Fig. 112).

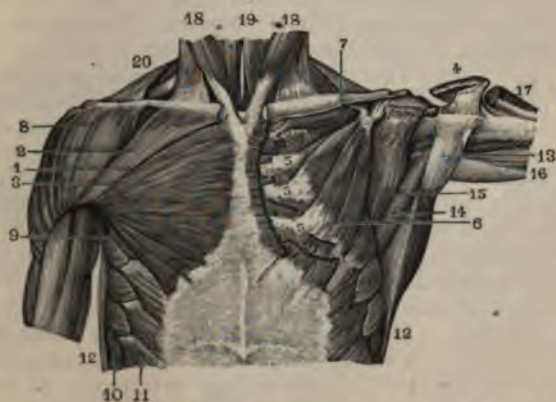


FIG. 112.—MUSCLES OF THE ANTERIOR PART OF THE THORAX.

1. Pectoralis major. 2. Its clavicular portion. 3. Its sternal portion. 4. Cut portion of the whole muscle deflected to show the long head of the biceps, showing also the turning of the fibres of the muscle before their insertion. 5. Muscular fasciculi by which the turning of the pectoralis major arises from the costal cartilages. 6. Pectoralis minor m. 7. Subclavius m. 8. Deltoid m., separated from the superior border of the pectoralis major by a wedge-shaped cellular interspace, the base being above. 9. Inferior border of the pectoralis minor. 10. Digitations of the serratus magnus m. 11. Digitations of the external oblique m. 12. Border of the latissimus dorsi m. 13. Tendon of this muscle passing around the teres major m. to be attached to the inner lip of the bicipital groove of the humerus. 14. Teres major m. 15. Subscapularis m. 16. Long head of the triceps m. 17. Margin of deltoid m. 18. Sterno-cleido-mastoid m. 19. Origin of sterno-hyoideus m. 20. Trapezius m.

Axillary Lymphatic Glands.

The axillary glands form a continuous chain, beneath the clavicle, with the cervical glands. They are from ten to twelve in number, of a reddish-brown colour, and variable size. Most of them lie near the axillary vessels; others are embedded in the loose tissue of the axilla; sometimes one or two small ones are observed along the lower border of the pectoralis major. They are supplied with blood by a branch—*thoracica alaris*—of the axillary artery, and by branches from the thoracic and subscapular arteries (Fig. 111).

These glands receive the lymphatics from the arm, from the

front and side of the chest, and from the outer half of the mammary gland. It is these glands which frequently become enlarged in cancer of the mammary gland. From these glands the efferent lymphatics pass along with the subclavian artery and terminate, on the right side, in the right lymphatic duct; and, on the left side, in the thoracic duct.

Dissection.

Now cut through the pectoralis major, about the middle, and turn the inner part of the muscle towards the sternum, and the outer part towards the arm. The pectoralis minor is thus exposed, together with the ramifications of the short and long thoracic arteries. Preserve the arteries, as far as possible, in connection with the main trunks.

Pectoralis Minor.

This triangular muscle *arises* from the third, fourth, and fifth ribs, near the costal cartilages, and from the thick fascia over the intercostal spaces. The fibres run obliquely upwards and outwards, and converge to a strong tendon, which is *inserted* into the anterior surface of the coracoid process. The tendon is connected to that of the coraco-brachialis and biceps by a strong fascia, which forms a protection for the subjacent axillary vessels and nerves. The action of this muscle is to draw the scapula downwards and forwards. Its nerve is derived from the internal anterior thoracic.

Dissection.

Having examined the muscles which form the anterior boundary of the axilla, we pass now to the course and relations of the axillary artery and its branches. To have a clear view, reflect the subclavius from its insertion, and cut the pectoralis minor through its middle.

Axillary Artery, its Course and Relations.

This artery, the continuation of the subclavian, takes the name of *axillary* at the outer border of the first rib. It then passes downwards and outwards, through the upper part of the axilla, beneath the two pectoral muscles, and along the inner border of the coraco-brachialis as far as the lower border of the tendon of the teres major, beyond which it is continued under the name of the brachial. Its course is divided for convenience of description into three parts: the first lies above the pectoralis minor; the second behind that muscle; and the third below it.

In the *first part* of its course the artery is *covered* by the pectoralis major and the costo-coracoid membrane, the subclavius, and is crossed by the cephalic and acromio-thoracic veins. On its *inner side*, and slightly in front, is the axillary vein; on its *outer side* is the brachial plexus of nerves; *behind* it are the first intercostal space, the second digitation of the serratus magnus, and the posterior thoracic nerve (external respiratory of Bell).

In the *second part* of its course it lies *behind* the pectoralis

major and minor; on its *inner side* is the axillary vein, still slightly anterior, but separated from the artery by the inner cord of the brachial plexus; on its *outer side* is the outer cord of the brachial plexus; and *behind* it is the posterior cord of the plexus, and also

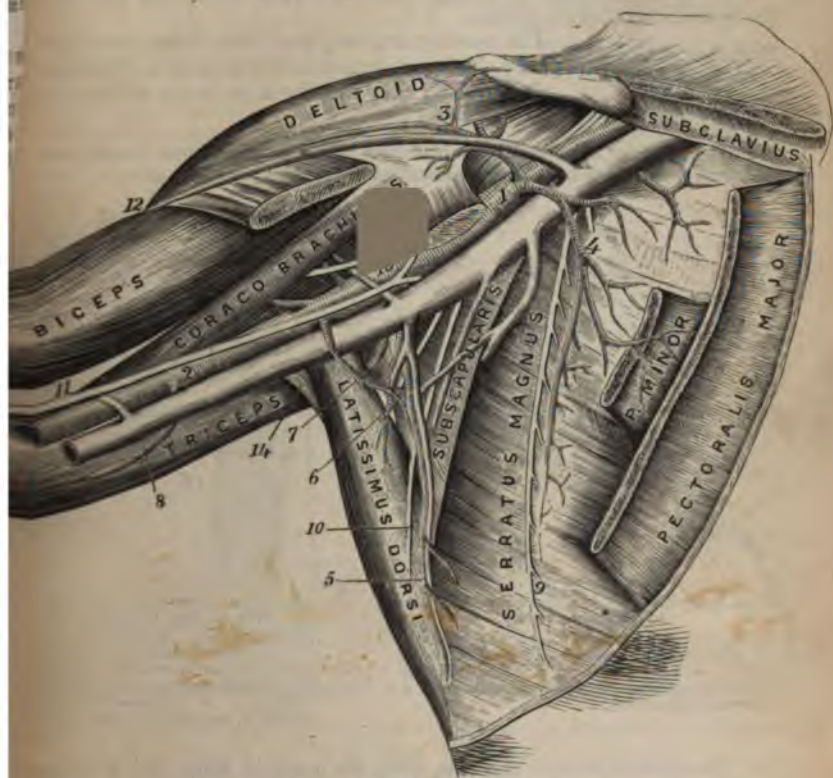


FIG. 113.—DIAGRAM OF AXILLA.

1. Axillary artery. 2. Brachial artery. 3. Thoracica humeralia artery. 4. Superior thoracic artery. 5. Subscapular artery. 6. Dorsalis scapulae artery. 7. Posterior circumflex artery. 8. Superior profunda artery. 9. Posterior thoracic nerve. 10. Long subscapular nerve. 11. Median nerve. 12. Cephalic vein. 13. Musculo-cutaneous nerve. 14. Teres major.

a quantity of loose connective tissue which separates it from the subscapularis muscle. The inner head of the median nerve is often in front of the artery in this part of its course.

In the *third part*, in front of the artery, are the pectoralis major, the two roots of the median nerve, converging like the letter V,

and lower down is the skin and the fascia of the arm; on the *outer side* are the coraco-brachialis, the musculo-cutaneous, and median nerves; on the *inner side* are the axillary vein, the ulnar, and the two internal cutaneous nerves; *behind* it are, in succession, the subscapularis, the latissimus dorsi, the teres major, and the musculo-spiral and circumflex nerves.

Branches of the Axillary Artery.

The number and origin of these branches often vary, but their general course is in most cases similar, and they usually arise in the following order:—

a. The *superior thoracic* arises above the pectoralis minor, and divides into branches, which have been already described (p. 297).

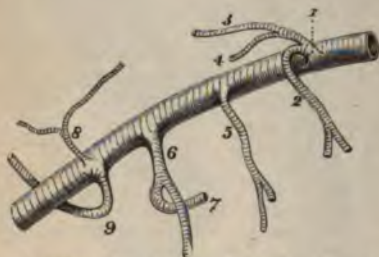

FIG. 114.—PLAN OF THE BRANCHES OF THE AXILLARY ARTERY.

1. Thoracic axis, giving off. 2. Short thoracic.
3. Thoracica acromialis. 4. Thoracica humeraria. 5. Long thoracic. 6. Subscapular. 7. Dorsalis scapulae. 8. Anterior circumflex. 9. Posterior circumflex.

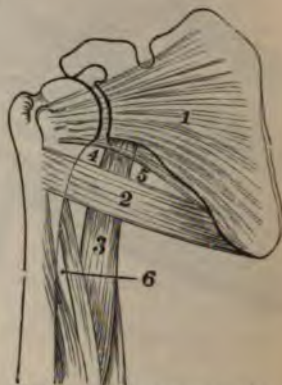

FIG. 115.—DIAGRAM OF THE ORIGINS OF THE TRICEPS.

1. Subscapularis. 2. Teres major.
3. Long head of triceps. 4. Square space for post. circumflex a. and n. 5. Triangular space for dorsalis scapulae a. 6. Space for musculo-spiral n., and superior profunda a.

b. The *acromial thoracic* also rises above the pectoralis minor, and gives off numerous branches already described (p. 297).

c. The *alar thoracic*, variable in its origin, supplies the lymphatic glands and the connective tissue of the axilla.

d. The *inferior or long thoracic artery* (external mammary) runs along the lower border of the pectoralis minor to the side of the chest. It supplies the mammary gland, the serratus magnus and pectoral muscles, and maintains a free anastomosis with the short thoracic, internal mammary, and intercostal arteries.

e. The *subscapularis* is the largest branch of the axillary; it arises opposite the lower border of the subscapularis, and, after running a short course of about an inch and a half (3.8 cm.), divides into an anterior and posterior branch.

The *anterior branch* runs along the anterior edge of the subscapularis towards the lower angle of the scapula. Its numerous branches supply the subscapularis,

latissimus dorsi, serratus magnus, and teres major, and anastomose with the intercostal and thoracic arteries, and with the posterior scapular (a branch of the subclavian).

The *posterior branch* (dorsalis scapulæ) runs to the back of the scapula, through a triangular space, bounded in front by the long head of the triceps; below, by the teres major; and, above, by the subscapularis and teres minor (Fig. 115). It gives off a small branch which enters the subscapular fossa beneath the subscapularis, supplying it, and anastomosing with the suprascapular and posterior scapular arteries. On the back of the scapula it divides into two branches: one runs in the groove on the axillary border of the scapula, lying beneath the teres minor, and ramifies in the infraspinous fossa between the bone and the infraspinatus; the other runs down between the teres minor and major on their dorsal aspects, and passes to the inferior angle of the scapula, anastomosing with the posterior and suprascapular arteries. The subscapular vein empties itself into the axillary vein.

f. The *posterior circumflex artery* arises from the back of the axillary artery, and is as large as the subscapular, close to which it is given off; or both may arise by a common trunk from the axillary. It passes backwards, with its corresponding veins and nerve, through a quadrilateral space, bounded above by the subscapularis and teres minor, below by the teres major, externally by the neck of the humerus, and internally by the long head of the triceps (Fig. 115). It then winds round the back of the neck of the humerus, and is chiefly distributed to the under surface of the deltoid.

Besides the deltoid, the posterior circumflex artery supplies the long head of the triceps, the head of the humerus, and the shoulder-joint. It inosculates above with the acromio-thoracic and suprascapular arteries, below with the ascending branch of the superior profunda (a branch of the brachial), and in front with the anterior circumflex artery. Should you not find the posterior circumflex artery in its normal position, look for it (as a branch of the brachial) below the tendon of the teres major.

g. The *anterior circumflex artery*, much smaller than the posterior, runs in front of the neck of the humerus, above the tendon of the latissimus dorsi. It passes directly outwards beneath the coraco-brachialis and short head of the biceps, close to the bone, and terminates in the under surface of the deltoid, where it inosculates with the posterior circumflex.

The anterior circumflex artery sends a small branch which runs with the long tendon of the biceps up the groove of the humerus, and is called, on that account, the *bicipital artery*. It supplies the shoulder-joint and the neck of the humerus.

If the axillary were tied below the pectoralis minor the collateral circulation would be established by the suprascapular, and its branches anastomosing with the subscapular, the dorsalis scapulæ, and the posterior circumflex; the posterior scapular with the dorsalis scapulæ and subscapular arteries.*

Axillary Vein. The *axillary vein* is formed by the continuation upwards of the basilic vein, and extends from the lower border of the teres major to the outer border of the first rib. It receives the venæ comites of the brachial artery near

* The axillary artery varies much as to the branches it gives off; occasionally (1 in 33) it gives off the radial artery; more rarely (1 in 72) it gives off the ulnar; and more rarely still (1 in 506) it gives off the interosseous artery.

the lower border of the subscapularis. It receives the subscapular and the other veins corresponding to the branches of the axillary artery, with the exception of the circumflex, which usually join either the subscapular or one of the venæ comites. The axillary near its termination also receives the cephalic vein.

The axillary vein in the upper part of its course lies in front of the artery, and close to its sternal side; in the lower two-thirds of its course the vein lies still to the sternal side of the artery, but is separated from it by some of the nerves of the brachial plexus.*



FIG. 116.—THE BRACHIAL PLEXUS OF NERVES.

- C 4-8. The five lower cervical nerves. D 1. The first dorsal nerve. 9. The rhomboid nerve—to rhomboidei major and minor. 10. The supra-scapular nerve—to supra and infra spinati. 11. The nerve to the subclavius. 12. Outer anterior thoracic nerve—to pectoralis major. 13. Inner anterior thoracic nerve—to pectoralis minor. 14, 15, 16. The subscapular nerves—to subscapularis, latissimus dorsi, and teres major. 17. Lesser internal cutaneous nerve. 18. Musculo-cutaneous nerve. 19. Musculo-spiral nerve. 20. Median nerve. 21. Circumflex nerve—to deltoid and teres minor. 22. Ulnar nerve. 23. Internal cutaneous nerve. 24. External respiratory nerve of Bell, or posterior thoracic nerve. *

Axillary or Brachial Plexus of Nerves.

This plexus is formed by the anterior trunks of the four lower cervical and first dorsal nerves, and receives also a small communicating branch from the fourth cervical nerve. The plexus is broad at the lower

* It must be remembered that the size of the axillary vein compared with the brachial is very much larger, consequently the greater danger in mistaking it for the axillary artery and from puncture when the axilla has to be opened. (A. H.)

part of the neck, where it emerges between the anterior and middle scalene muscles; but it gradually contracts as it descends beneath the clavicle into the axilla, and on a level with the coracoid process distributes its large branches to the upper limb.

The arrangement of the cervical nerves in the formation of the plexus is variable, often not alike on both sides.* The most frequent disposition is this—the fifth and sixth cervical unite at the outer border of the scalenus medius to form an upper cord; the eighth and the first dorsal form between the scaleni muscles a lower cord; the seventh cervical runs alone, as a middle cord, for a short distance. Each of these nerves divides, just external to the outer border of the scalenus medius, into an anterior and a posterior branch; the anterior branches given off from the fifth, sixth, and seventh cervical form the *outer cord* of the plexus; the anterior branches given off from the eighth cervical and the first dorsal form the *inner cord*; while the posterior branches of all the nerves—viz., the fifth, sixth, seventh, eighth cervical, and the first dorsal—unite to form the *posterior cord*.

At first these cords are placed on the outer side of the axillary artery, but behind the pectoralis minor they are situated one on the outer side of, one on the inner side of, and one behind, the axillary artery.

The brachial plexus gives off some branches above the clavicle, which were dissected with the neck (p. 140). Below the clavicle, it gives off the following:—

From the *outer cord* proceed an anterior thoracic branch, the musculo-cutaneous, and the outer head of the median; from the *inner cord* proceed the inner anterior thoracic nerve, the inner head of the median, the ulnar, the internal cutaneous, and the lesser internal cutaneous; from the *posterior cord* proceed the three subscapular nerves, the circumflex, and the musculo-spiral.

The *anterior thoracic* nerves have been described (p. 298).

Subscapular Nerves. The *three subscapular* nerves are found on the surface of the subscapularis. They come from the posterior cord of the brachial plexus, and supply, respectively, the latissimus dorsi, teres major, and subscapularis. The nerve to the latissimus dorsi (*long subscapular nerve*) runs with the anterior branch of the subscapular artery to the lower border and inner surface of the muscle.

The *nerve to the teres major* is either a branch of the preceding, or comes separately from the posterior cord. It lies nearer to the humerus than the long subscapular. It gives off also a small branch to the anterior border of the subscapularis.

* Frequently the second dorsal nerve sends upwards a communicating filament to the first dorsal nerve. (*Journal of Anatomy*, vol. xi, p. 539.)

The *nerve to the subscapularis* arises from the posterior cord, higher than the others, and enters the muscle not far from its upper border in company with a small artery.

Circumflex Nerve. The circumflex nerve accompanies the *posterior circumflex artery*. This large nerve comes from the posterior cord, and, after giving a small filament to the shoulder-joint, passes, with its companion artery, through the quadrilateral space (p. 305) to the under surface of the deltoid. Here the nerve divides into an upper and a lower branch. The *upper* supplies the anterior part of the deltoid and the skin over it; the *lower* supplies the back part of the deltoid, and gives the nerve to the *teres minor*,* upon which nerve sometimes a little gangliform swelling can be seen: it enters the under aspect of the middle of this muscle. After furnishing these muscular branches, the nerve turns round the posterior border of the deltoid, and diverges in filaments which supply the skin over the back of this muscle and over the long head of the triceps.

Latissimus Dorsi. This broad, flat muscle forms the posterior margin of the axilla. It arises from the external lip of the crest of the ilium, from an aponeurosis attached to the spinous processes of the six lower dorsal, of all the lumbar, and of the sacral vertebræ and their supraspinous ligament, and by fleshy digitations from the three or four lower ribs, interdigitating with those of the external oblique; in some cases, as it passes over the inferior angle of the scapula, it has an additional origin from the angle. Its fibres converge from this large origin, and the muscle is *inserted* into the bottom of the bicipital groove of the humerus by a broad flat tendon, which curves round the lower border of the *teres major*. The axillary vessels and nerves lie upon the tendon close to its insertion. Its nerve is the long subscapular branch from the posterior cord of the brachial plexus, and it enters the muscle close to its anterior border, in company with a large branch of the subscapular artery (Fig. 117).

Teres Major. This muscle lies behind, and to the inner side of the latissimus dorsi, is closely connected with it, and assists in forming the posterior boundary of the axilla. It *arises* from the oval surface on the dorsal aspect of the lower angle of the scapula, and from the fibrous septa between it and the *teres minor* and *infraspinatus*, and is *inserted* by a broad flat tendon, about two inches (5 cm.) in length, behind the latissimus dorsi, into the posterior margin of the bicipital groove of the humerus. The tendon extends below that of the latissimus dorsi, and a bursa or sac, lubricated with serum, intervenes between the two tendons.

* This branch to the *teres minor* is said to be constant in all mammalia that have been examined in reference to this point.

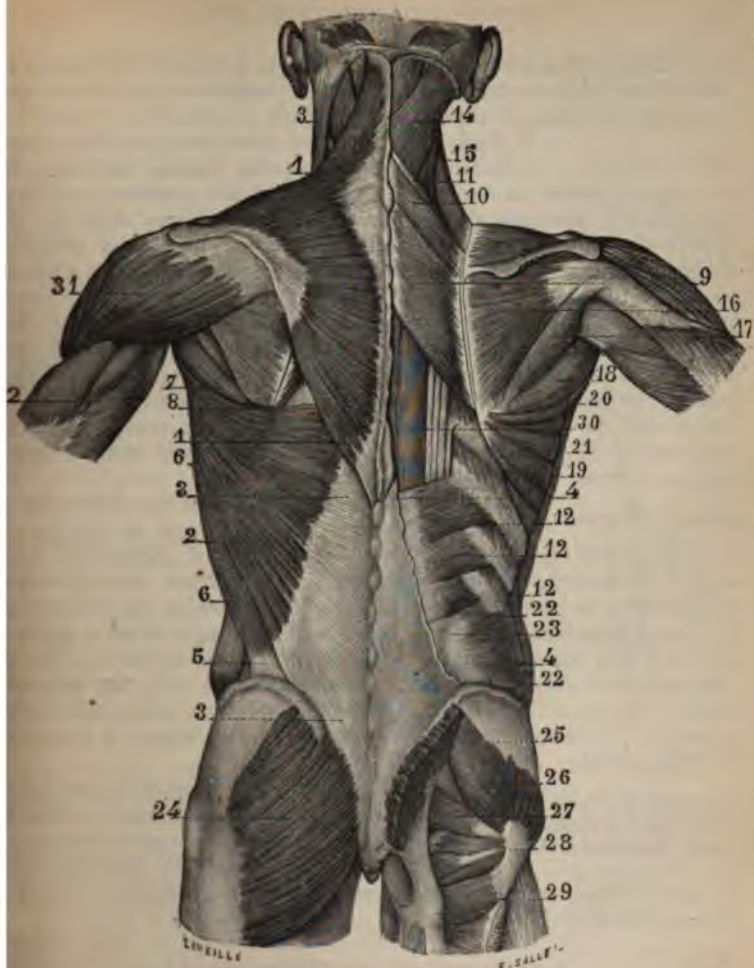


FIG. 117.—MUSCLES OF THE BACK (SUPERFICIAL).

1. Trapezius. 2. Latissimus dorsi. 3, 3. Sacro-lumbar aponeurosis. 4. Portion of the fascia anterior to the latissimus dorsi. 5. Fasciculus by which this muscle is attached to the crest of the ilium. 6. External border of the same. 7. Teres major. 8. Superior border of the latissimus dorsi passing over the teres major. 9. Rhomboid major. 10. Rhomboid minor. 11. Superior border of the serratus post. superior. 12, 12, 12. The three fasciculi of the serratus post. inferior. 13. Sterno-cleido-mastoid. 14. Splenius. 15. Levator anguli scapulae. 16. Infra-spinatus. 17. Teres minor. 18. Teres major. 19. Cut latissimus dorsi. 20. Scapular attachment of the latissimus dorsi. 21. Inferior portion of the serratus magnus. 22, 22. Posterior part of the internal oblique. 23. Posterior aponeurosis of this muscle uniting with that of the serratus posticus inferior and the latissimus dorsi, forming the sacro-lumbar aponeurosis. 24. Gluteus maximus. 25. Cut origin of this muscle. 26. Gluteus medius. 27. Pyramidalis. 28. The tendon of the obturator internus and the superior and inferior gemelli. 29. Quadratus femoris. 30. Sacro-lumbalis and longissimus dorsi. 31. Deltoid. 32. Triceps.

The action of this and the preceding muscle is to draw the humerus inwards and backwards. Its nerve is the middle subscapular, and lies along the dorsalis scapulæ artery (Figs. 112, 117).

Subscapularis.

This muscle *arises* from the posterior two-thirds of the subscapular fossa of the scapula, with the exception of the angles, neck, and the posterior border, and from the intermuscular septa attached to the bony ridges. Its fibres converge to a strong tendon, which passes under the axillary vessels and nerves, over the inner side of the shoulder-joint, and is *inserted* into the lesser tuberosity of the humerus, and into the neck of the humerus for an inch (2.5 cm.) below it. The tendon of the muscle is intimately connected with the capsular ligament of the shoulder-joint, and between the base of the coracoid process and the tendon is a bursa, which communicates with the joint. Its action is to rotate the humerus inwards, and when the arm is raised to draw it to the side. Its nerves come from the upper and middle subscapular nerves.

Serratus Magnus.

This muscle covers the side of the chest like a girth. It *arises* from the front of the outer surfaces of the eight upper ribs by nine slips or digitations, the second rib having two. Its fibres converge, and are *inserted* into the posterior border of the scapula in the following manner: the first two digitations are attached into the upper angle of the scapula; the third and fourth digitations along nearly the whole length of the posterior border; the remainder are inserted into the inferior angle. Its action is to draw the scapula forwards; but of this more hereafter. It is supplied by the following nerve, which is seen on its outer surface.

Posterior Thoracic or External Respiratory Nerve of Bell.

This nerve supplies the serratus magnus only. It comes from the fifth and sixth cervical nerves; and, after passing through the scalenus medius, runs behind the axillary vessels, along the outer surface of the serratus magnus, each digitation receiving a separate filament.*

DISSECTION OF THE UPPER ARM.

In front of the upper arm may be distinguished the long prominence of the biceps muscle, and lower down at the bend of the elbow its tendon may be easily felt. The bend of the elbow, in muscular subjects, presents a triangular depression, with its boundaries formed on the inner side by

* It may be asked why this nerve is called the external respiratory. It was so named by Sir C. Bell, who considered the serratus magnus as the external respiratory muscle, co-operating with the diaphragm or internal respiratory muscle.

the pronator teres, and on the outer side by the supinator longus. Superficially in this space the subcutaneous veins can be recognised, of which a fuller description will be entered into later on. On the inner side of the elbow, the internal condyle of the humerus is very prominent, and behind this is the olecranon; between these is a hollow in which may be felt the ulnar nerve. The olecranon is situated nearer the internal than the external condyle, which is visible on the outer side; below this, is a dimple which corresponds with the head of the radius.

Dissection. Continue the incision down the inner side of the arm as far as two inches (5 cm.) below the elbow, and then make a transverse incision from the inner to the outer side of the forearm. Reflect the skin, and trace out the cutaneous nerves and the numerous veins in front of the elbow.

Cutaneous Nerves. On the inner side of the arm are the intercosto-humeral, the internal cutaneous branch of the musculo-spiral, the internal cutaneous, and the lesser internal cutaneous (nerve of Wrisberg) nerves; on the outer side are the cutaneous branches of the circumflex, the external cutaneous branches of the musculo-spiral, and lower down is the musculo-cutaneous nerve.

The filaments of the *intercosto-humeral nerves* (p. 299) descend along the inner and posterior part of the arm as far as the olecranon, and communicate with the internal cutaneous branch of the musculo-spiral nerve.

The *internal cutaneous nerve* perforates the fascia, with the basilic vein, about the middle of the arm, and divides into an anterior and a posterior branch; the *anterior* passes down in front of the arm (as a rule beneath the median basilic vein), and supplies the skin as far as the wrist, communicating with a cutaneous branch of the ulnar nerve; the *posterior* winds round to the back of the forearm behind the internal condyle as far as the wrist, and communicates above the elbow with the nerve of Wrisberg, and above the wrist with the dorsal branch of the ulnar nerve.

The *lesser internal cutaneous (nerve of Wrisberg)* perforates the fascia about the lower third of the arm, and supplies the skin over the internal condyle and the olecranon. This nerve, as it lies close to the axillary vein, communicates with the first or second intercosto-humeral nerve.

The *internal cutaneous branch of the musculo-spiral nerve* pierces the fascia

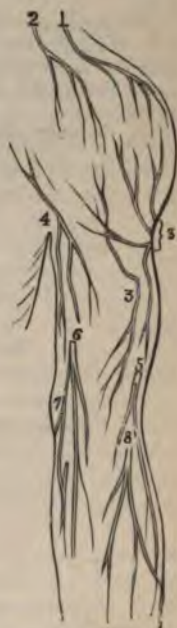

FIG. 118.—DISTRIBUTION OF CUTANEOUS NERVES TO THE FRONT OF THE SHOULDER AND ARM.

1. Acromial branches of the superficial cervical plexus.
2. Clavicular branches of the superficial cervical plexus.
3. Cutaneous branches of the circumflex nerve.
4. Branches of the internal cutaneous nerve.
5. External cutaneous branch of the musculo-spiral nerve.
6. Internal cutaneous nerve.
7. Its posterior cutaneous branch.
8. The cutaneous branch of the musculo-cutaneous nerve.

The action of this and the preceding muscle is to draw the humerus forwards and backwards. Its nerve is the middle subscapular, and lies along the dorsalis scapulae artery (Figs. 112, 117).

Subscapularis.

This muscle arises from the posterior two-thirds of the subscapular fossa of the scapula, with the exception of the angles, neck, and the posterior border, and from the intermuscular septa attached to the bony ridges. Its fibres converge to a strong tendon, which passes under the axillary vessels and nerves, over the inner side of the shoulder-joint, and is inserted into the lesser tuberosity of the humerus, and into the neck of the humerus for an inch (2.5 cm.) below it. The tendon of the muscle is intimately connected with the capsular ligament of the shoulder-joint, and between the base of the coracoid process and the tendon is a bursa, which communicates with the joint. Its action is to rotate the humerus inwards, and when the arm is raised to draw it to the side. Its nerves come from the upper and middle subscapular nerves.

Serratus Magnus.

This muscle covers the side of the chest like a girth. It arises from the front of the outer surfaces of the eight upper ribs by nine slips or digitations, the second rib having two. Its fibres converge, and are inserted into the posterior border of the scapula in the following manner: the first two digitations are attached into the upper angle of the scapula; the third and fourth digitations along nearly the whole length of the posterior border; the remainder are inserted into the inferior angle. Its action is to draw the scapula forwards; but of this more hereafter. It is supplied by the following nerve, which is seen on its outer surface.

Posterior Thoracic or External Respiratory Nerve of Bell.

This nerve supplies the serratus magnus only. It comes from the fifth and sixth cervical nerves; and, after passing through the scalenus medius, runs behind the axillary vessels, along the outer surface of the serratus magnus, each digitation receiving a separate filament.*

DISSECTION OF THE UPPER ARM.

In front of the upper arm may be distinguished the long prominence of the biceps muscle, and lower of the bend of the elbow, and the angular depression, with its

* It may be asked why the nerve is named by Sir C. Bell, who discovered the respiratory muscle, co-operating

the pronator teres, and on the outer side by the supinator longus. Superficially in this space the subcutaneous veins can be recognised, of which a fuller description will be entered into later on. On the inner side of the elbow, the internal condyle of the humerus is very prominent, and behind this is the olecranon; between these is a hollow in which may be felt the ulnar nerve. The olecranon is situated nearer the internal than the external condyle, which is visible on the outer side; below this, is a dimple which corresponds with the head of the radius.

Dissection.

Continue the incision down the inner side of the arm as far as two inches (5 cm.) below the elbow, and then make a transverse incision from the inner to the outer side of the forearm. Reflect the skin, and trace out the cutaneous nerves and the numerous veins in front of the elbow.

Cutaneous Nerves.

On the inner side of the arm are the intercosto-humeral, the internal cutaneous branch of the musculo-spiral, the internal cutaneous, and the lesser internal cutaneous (nerve of Wrisberg) nerves; on the outer side are the cutaneous branches of the circumflex, the external cutaneous branches of the musculo-spiral, and lower down is the musculo-cutaneous nerve.

The filaments of the *intercosto-humeral nerves* (p. 299) descend along the inner and posterior part of the arm as far as the olecranon, and communicate with the internal cutaneous branch of the musculo-spiral nerve.

The *internal cutaneous nerve* perforates the fascia, with the basilic vein, about the middle of the arm, and divides into an anterior and a posterior branch; the *anterior* passes down in front of the arm (as a rule beneath the median basilic vein), and supplies the skin as far as the wrist, communicating with a cutaneous branch of the ulnar nerve; the *posterior* winds round to the back of the forearm behind the internal condyle as far as the wrist, and communicates above the elbow with the nerve of Wrisberg above the wrist with the *internal branch* of the ulnar

The *lesser internal cutaneous nerve of Wrisberg* perforates the fascia above the internal condyle (third of the arm) and supplies the skin of the internal condyle and communicates with the ulnar nerve to the ulnar and intercosto-humeral nerves.

The *internal cutaneous nerve of the arm* perforates the fascia

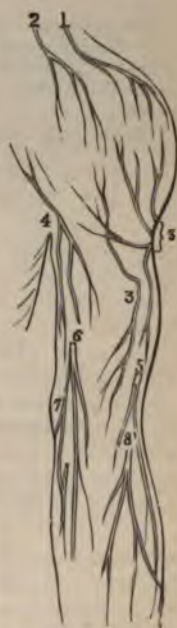

FIG. 118.—DISTRIBUTION OF CUTANEOUS NERVES TO THE FRONT OF THE SHOULDER AND ARM.

1. Acromial branches of the superficial cervical plexus.
2. Clavicular branches of the superficial cervical plexus.
3. Cutaneous branches of the circumflex nerve.
4. Branches of the internal cutaneous nerve.
5. External cutaneous branch of the musculo-spiral nerve.
6. Internal cutaneous nerve.
7. Its posterior cutaneous branch.
8. The sensory branch of the musculo-cutaneous nerve.

perforates the fascia

and supplies the skin of the inner and posterior aspect of the middle of the arm as far as the olecranon.

The *cutaneous branches of the circumflex nerve* pierce the fascia over the insertion of the deltoid, and supply the skin of the upper half of the arm on its outer side.

The *external cutaneous branches of the musculo-spiral nerve* are two in number: the *upper* and smaller accompanies the cephalic vein in the lower half of the arm; the *lower* may be traced down the outer and back part of the forearm nearly as far as the wrist, where it joins the posterior branch of the musculo-cutaneous nerve.

On the outer side of the tendon of the biceps the *cutaneous branch of the*

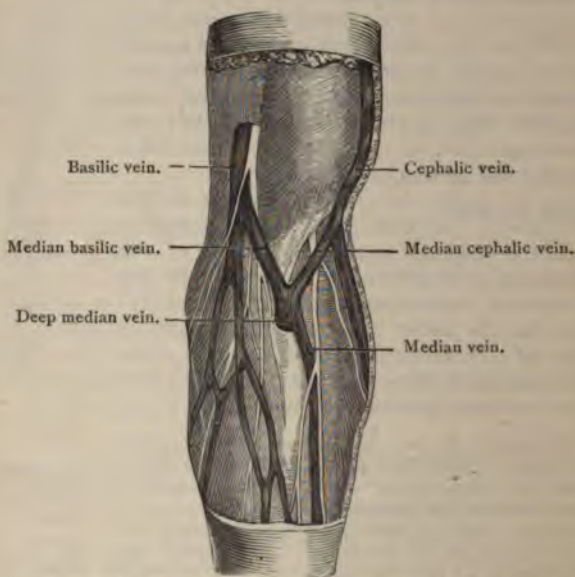

FIG. 119.—SUPERFICIAL VEINS AND NERVES AT THE END OF THE LEFT ELBOW.

musculo-cutaneous nerve perforates the fascia, and divides into many filaments, which supply the skin of the outer part of the forearm.

Disposition of Veins in Front of the Elbow.

Attention should now be directed to the disposition of the veins in front of the elbow. In cleaning these veins, take care not to divide the branches of the internal and external cutaneous nerves which pass over and under them.

The following is the ordinary arrangement of the superficial veins at the bend of the elbow (Fig. 119). On the outer side is

the *radial*; on the inner side is the *ulnar vein*, formed by the junction of the anterior and posterior ulnar cutaneous veins; in the centre is the median, which divides into two branches, the external of which, uniting with the radial to form the cephalic vein, is called the *median cephalic*; the internal, uniting with the ulnar to form the basilic, is named the *median basilic*. Near its bifurcation, the median vein communicates by a branch (*mediana profunda*) with the deep veins which accompany the arteries of the forearm.

Trace the *cephalic vein* up the arm. It runs along the outer border of the biceps to the groove between the pectoralis major and the deltoid, and dipping down between these two muscles, terminates in the axillary vein immediately above the pectoralis minor.

The *basilic vein*, the largest of the veins of the upper arm, ascends along the inner side of the arm with the internal cutaneous nerve. Near the middle of the arm, it perforates the fascia, and empties itself either into the internal vena comes of the brachial artery, or into the axillary vein.

Relation of the Cutaneous Nerves and Veins at the Elbow. The principal branches of the cutaneous nerves pass beneath the veins: that is to say, as a rule, the internal cutaneous passes behind the median basilic vein, and the external cutaneous behind the median cephalic: but it should be remem-

bered that many small filaments cross in front which are exposed to injury in venesection (Fig. 119).

Relation of Median Basilic Vein to Brachial Artery. Since the median basilic vein is larger than the median cephalic, and, on account of the strong fascia beneath, more easily compressible, it is usually chosen for venesection; its position,

therefore, in reference to the brachial artery, becomes important. The vein is only separated from the artery by the *semilunar fascia*, derived from the tendon of the biceps. This fascia is in some subjects remarkably thin. Sometimes the artery lies above the fascia, in contact with the vein. In choosing, therefore, this vein for venesection, there is a risk of wounding the artery; hence the practical rule, to bleed either from the median cephalic, or from the median basilic above the situation where it crosses the brachial artery.

Lymphatic Glands. Immediately above the internal condyle, in the neighbourhood of the basilic vein, we find one or two small *lymphatic glands*. Others may be found higher up along the inner side of the arm. A gland is occasionally met with at the bend of the elbow; but never below this joint. These little glands are the first which are liable to become tender and enlarged after a poisoned wound of the hand.

Muscular Fascia and its Connections.

The fascia which invests the muscles of the upper arm is a continuation of the fascia of the trunk and the axilla. This membrane varies in density: thus it is thin over the biceps, stronger on the inner side of the arm, to protect the brachial vessels and nerves, and strongest over the triceps. At the upper part of the arm it is connected with the coracoid process and the clavicle; it is strengthened at the axilla by an expansion from the tendons of the pectoralis major and latissimus dorsi; posteriorly, it is attached to the spine of the scapula. The fascia surrounds the brachial vessels with a sheath, and furnishes partitions which separate the muscles from each other. Of these partitions, the most marked are, the *external* and *internal intermuscular septa*, which divide the muscles on the anterior from those on the posterior surface of the upper arm. These septa are attached to the condyloid ridges of the humerus and to the condyles. The *internal intermuscular septum*, the stronger of the two, begins at the insertion of the teres major, and is connected with the tendinous insertion of the coraco-brachialis; it separates the triceps extensor from the brachialis anticus, to both of which it affords attachment to their muscular fibres. It is pierced by the ulnar nerve and the inferior profunda and anastomotic arteries. The *external intermuscular septum* commences from the insertion of the deltoid, and separates the brachialis anticus, the supinator longus, and the extensor carpi radialis longior in front, from the triceps extensor behind, to all of which muscles it affords attachment. It is pierced by the musculo-spiral nerve and the superior profunda artery.

At the lower part of the upper arm the fascia is remarkably strong, especially where it covers the brachialis anticus and the brachial vessels, and is continued over the muscles on the inner side of the forearm. At the back of the elbow the fascia is attached to the tendon of the triceps and the olecranon.

Dissection.

Now remove the fascia corresponding to the incisions through the skin, in order to see the muscles on the front of the arm—namely, the biceps, the coraco-brachialis, and the brachialis anticus. The long, rounded muscle in front is the biceps; the muscle attached with it to the coracoid process is the coraco-brachialis; and the broad flat muscle covering the lower end of the humerus is the brachialis anticus.

Biceps.

The *biceps*, as its name implies, arises by two heads—a long and a short. The *short head* arises from the tip of the coracoid process of the scapula, by a thick, flat tendon in common with a slender muscle on its inner side, called the coraco-brachialis. The *long head* arises from the upper border of the glenoid fossa of the scapula and the glenoid ligament,

by a long, rounded tendon, which, traversing the shoulder-joint, passes over the head of the humerus; there pierces the capsular ligament, and descends in the groove between the two tuberosities. The tendon is retained in the groove by a fibrous bridge derived from the capsule of the joint, and connected with the tendon of the pectoralis major. Divide this bridge, and see that the synovial membrane of the joint is reflected round the tendon and accompanies it for about two inches down the groove, thus forming a synovial fold. The object of this is to facilitate the play of the tendon and to carry little arteries (from the anterior circumflex) for its supply. The two heads unite about the middle of the arm and form a single muscle, which terminates on a strong flat tendon of considerable length; this dips down into the triangular space at the bend of the elbow, and, after a slight twist upon itself, is inserted into the posterior part of the tubercle of the radius. The anterior part of the tubercle, over which the tendon plays, is crusted with cartilage, and a bursa intervenes to diminish friction. The most internal fibres of the muscle are inserted into a strong, broad aponeurosis, which is prolonged from the inner border of the tendon to the fascia on the inner side of the forearm. This aponeurosis, called the *semilunar fascia of the biceps*, protects the brachial vessels and the median nerve at the bend of the elbow (Fig. 120).

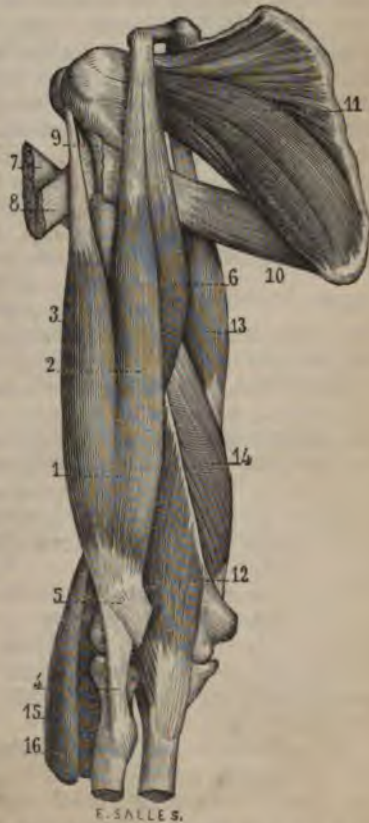

FIG. 120.—ANTERIOR MUSCLES OF THE ARM.

1. Biceps. 2. Short-head of the biceps. 3. Long-head of the same. 4. Tendon attached to the tuberosity of the radius. 5. Semilunar fascial aponeurosis of the biceps. 6. Coracobrachialis. 7, 8. The two portions of the pectoralis major forming a groove with its concavity above. 9. Attachment of the latissimus dorsi. 10. Teres major. 11. Subscapularis. 12. Brachialis anticus. 13. Long head of the triceps. 14. Internal head of the triceps. 15. Supinator longus or brachio-radialis. 16. Extensor carpi radialis longior.

The *action* of the biceps is twofold. 1. It is a flexor of the forearm. 2. It is a powerful supinator of the forearm in consequence of its insertion into the *posterior* part of the tubercle of the radius. Its power of supination is greatest when the forearm is half bent, because its tendon is then inserted at a right angle. Why does the long tendon pass through the shoulder-joint? It acts like a strap and confines the head of the humerus in its proper centre of motion.* But for this tendon the head of the bone, when the deltoid acts, would be pulled directly upwards and strike against the under surface of the acromion. When the tendon is ruptured, or dislocated from its groove, a man can move his arm backwards and forwards, but he cannot raise the smallest weight. The biceps is supplied with blood by a branch from the brachial, which runs into the middle of its inner side, and divides into ascending and descending branches. Its nerve comes from the musculo-cutaneous.

Coraco-brachialis. This thin muscle is situated at the upper part of the arm, and runs parallel to the inner border of the short head of the biceps. It *arises* by fleshy fibres from the point of the coracoid process, in common with the short head of the biceps, and from a fibrous septum which lies between them. The muscle descends backwards and outwards, and terminates on a flat tendon, which is *inserted* into the inner side of the middle of the humerus, between the brachialis anticus and the inner head of the triceps. Its action is to draw the humerus forwards and inwards—*e.g.*, in bringing the gun up to the shoulder. It is supplied by a branch from the musculo-cutaneous nerve which pierces it (Fig. 120).

Concerning the coraco-brachialis, remember: 1. That the musculo-cutaneous nerve runs through it; 2. That its inner fleshy border is the guide to the axillary artery in the last part of its course; 3. That the brachial artery lies upon its flat tendon of insertion, and can here be effectually compressed by the finger or the tourniquet.

The coraco-brachialis and biceps are covered at their upper part by the deltoid and pectoralis major. The head of the humerus rolls beneath the coraco-brachialis and short origin of the biceps; and a large *bursa* is interposed between these muscles and the tendon of the subscapularis, which covers the head of the bone.

Brachialis Anticus. This broad muscle covers the lower half of the humerus, and is partially concealed by the

* Another action of the long tendon of the triceps would seem to be that of an internal rotator of the humerus when that bone is rotated externally. The marked prominence of the internal tuberosity and the groove on its outer aspect would favour this view.

biceps. Between the two muscles is the musculo-cutaneous nerve, which supplies them both.

It *arises* from the humerus by a fleshy digitation on either side of the tendon of the deltoid; from the lower half of the front and inner surfaces of the bone, and from the intermuscular septa. The muscle, becoming thicker and broader, covers the front of the capsule of the elbow-joint, to which it is more or less attached, and terminates on a tendon, which is *inserted* in a pointed manner into the anterior surface of the coronoid process of the ulna. Its *action* is to bend the forearm. Its nerves come from the musculo-cutaneous, and it usually receives in addition a small branch from the musculo-spiral (Fig. 120).

Now examine the course and relations of the brachial vessels and nerves.

Course and Relations of the Brachial Artery.

The *brachial artery*—the continuation of the axillary—takes its name at the lower border of the *teres major*. It runs down the anterior and the inner side of the arm, along the *inner border of the coraco-brachialis and biceps*, to about an inch (2.5 cm.) below the elbow, where it divides, near the coronoid process of the ulna, into the radial and ulnar arteries.

Thus its direction corresponds with a line drawn from the deepest part of the axilla to the middle point between the condyles of the humerus.

In the upper part of its course it *lies on* the long and inner heads of the triceps (from the long head it is separated by the musculo-spiral nerve and superior profunda artery); in the middle, it lies on the tendon of the coraco-brachialis; in the lower part, on the brachialis anticus.

In *front* of the artery are the internal cutaneous nerve, the median basilic and basilic veins; the median nerve, which crosses obliquely over the artery, being on its outer side near the axilla, and on its inner side near the elbow; and lastly, the artery is more or less overlapped, in the first part of its course, by the coraco-brachialis, lower down by the fleshy belly of the biceps; the inner borders of these muscles, in their respective situations, being the best guides to the artery.

On the *outer side* of the artery are, the median nerve, the coraco-brachialis, and biceps.

On the *inner side* are, at first, the ulnar nerve, the internal cutaneous nerves; and, below, the median nerve.

The artery is accompanied by two veins (*venæ comites*) and the median nerve, all of which are invested in a common sheath of fascia.

The *ulnar nerve* runs along the inner side of the artery as far

as the middle of the arm. Below this point, the nerve leaves the artery, and passes through the internal intermuscular septum to get behind the internal condyle.

About the middle of the humerus, the artery lies for nearly two inches (5 cm.) on the tendon of the coraco-brachialis, and is so close to the bone that it can be effectually compressed, provided the pressure be made in the proper direction—namely, outwards. Here, too, it is crossed by the median nerve.

At the bend of the elbow the artery is crossed by the semilunar fascia from the biceps. It enters a triangular space, bounded by the pronator radii teres internally, and by the supinator radii longus externally. It sinks into this space, with the tendon of the biceps to its outer side, and the median nerve to its inner; all three rest upon the brachialis anticus. To compress the artery here, pressure should be made directly backwards. Opposite the coronoid process of the ulna it divides into the radial and ulnar arteries.

Two veins, of which the internal is the larger, lie in close contact with the brachial artery, and communicate at frequent intervals by transverse branches. Near the axilla they join and form the axillary vein.

Branches of Brachial Artery.

The brachial artery gives off four branches, all from its inner side: namely, the superior profunda, the inferior profunda, the nutrient artery, and the anastomotica magna. It also distributes muscular branches to the coraco-brachialis and biceps, which are given off from its outer side.

a The *profunda superior* arises from the inner and back part of the brachial artery, immediately below the tendon of the *teres major*.* It winds round the back of the humerus, between the outer and inner heads of the triceps, accompanied by the musculo-spiral nerve, and, a little above the middle of the arm, divides into two branches, which run for some distance on either side of the nerve. One of these runs in the substance of the triceps muscle, with the nerve to the anconeus, as far as the olecranon, and anastomoses with the posterior ulnar recurrent, the interosseous recurrent, and anastomotica magna arteries; the other branch accompanies the musculo-spiral nerve to the outer side of the arm, where it perforates the external intermuscular septum. It then descends deep in the interval between the brachialis anticus and supinator radii longus, and terminates in numerous ramifications, some of which pass in front of the external condyle, others behind it, to inosculate with the radial and interosseous recurrent arteries.

Before its division, the superior profunda sends several branches to the deltoid, coraco-brachialis, and the triceps, some of which inosculate with the circumflex. These assist in establishing a collateral circulation when the brachial artery is ligatured above the origin of the profunda.

b. The *profunda inferior* arises from the brachial, opposite to the insertion of

* If the profunda be not in its usual place, look for it above the tendon of the latissimus dorsi, where it will probably be given off from a common trunk with the posterior circumflex.

the coraco-brachialis, or sometimes by a common trunk with the superior profunda. It runs with the ulnar nerve on the inner head of the triceps (which it supplies), passes through the internal intermuscular septum, and then descends to the interval between the internal condyle and the olecranon, inosculating with the posterior ulnar recurrent and anastomotica magna arteries. It also sends a small branch down in front of the internal condyle to anastomose with the anterior ulnar recurrent.

c. The *nutrient artery* of the humerus arises sometimes from the brachial,

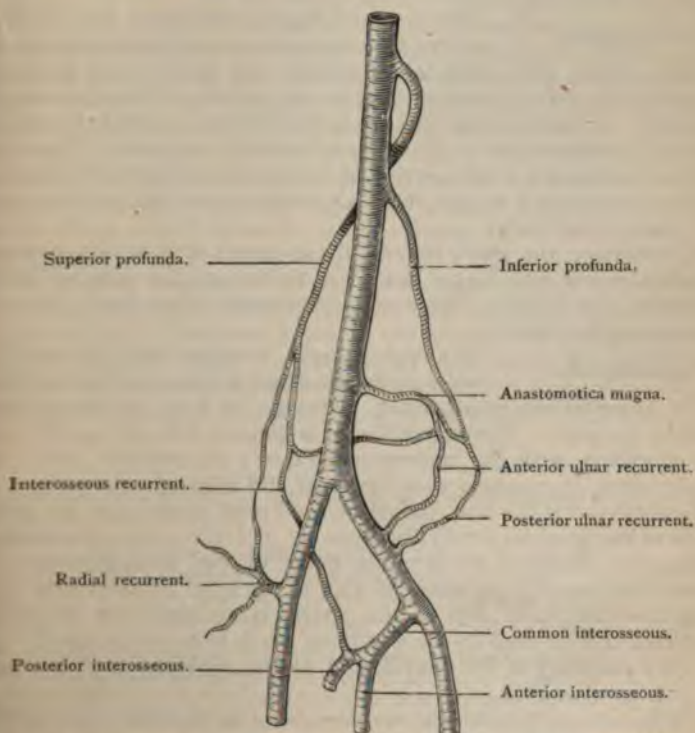


FIG. 181.—PLAN OF THE CHIEF BRANCHES OF THE BRACHIAL ARTERY AND THE ARTERIAL INOSCULATIONS ABOUT THE RIGHT ELBOW-JOINT.

sometimes from the inferior profunda. It pierces the tendon of the coraco-brachialis, runs obliquely downwards through the bone, and in the medullary canal divides into ascending and descending branches, which anastomose with the nutrient vessels of the bone derived from the periosteum.

d. The *anastomotica magna* arises from the inner side of the brachial, about two inches (5 cm.) above the elbow, runs tortuously inwards, transversely across the brachialis anticus, and divides into branches, some of which pass in front of

the internal condyle, anastomosing with the anterior ulnar recurrent artery; another passes behind the internal condyle by piercing the internal intermuscular septum, and anastomoses with the inferior profunda and posterior ulnar recurrent arteries; and one branch forms an arch, above the olecranon fossa, with the superior profunda.

e. Numerous *muscular branches* arise from the outer side of the brachial artery; one of these, the bicipital, more constant than the rest, supplies the biceps; another runs transversely beneath the coraco-brachialis and biceps, over the insertion of the deltoid, supplying this muscle and the brachialis anticus.

Venæ Comites.

The two veins which accompany the brachial artery are continuations of the deep radial and ulnar veins. The internal is usually the larger, and generally receives the veins corresponding to the principal branches of the artery. In their course they are connected at intervals by transverse branches either in front of, or behind the artery. Near the subscapularis, the *vena comes externa* crosses obliquely in front of the axillary artery to join the *vena comes interna*, which then takes the name of axillary.

Now trace the great nerves of the upper arm, which proceed from the brachial plexus near the tendon of the subscapularis; namely, the median, the musculo-cutaneous, the ulnar, and the musculo-spiral nerves.

Median Nerve.

The *median nerve*, so called from the course it takes along the front of the arm and the forearm, arises by two roots, which converge in front of the axillary artery (p. 307). The external root is derived from the outer cord, in common with the musculo-cutaneous; the internal from the inner cord, in common with the ulnar and internal cutaneous. In its course down the arm, the nerve is situated at first on the outer side of the brachial artery, between it and the coraco-brachialis; about the middle of the arm the nerve crosses obliquely over (in some cases under) the vessel, so that at the bend of the elbow it is found on the inner side of the artery, lying upon the brachialis anticus, and covered by the semilunar fascia from the biceps.*

As a summary of the distribution of the median nerve, we may

* I have observed the following *varieties* relating to the median nerve, and its course in regard to the artery:—

a. The roots may be increased in number by one on either side of the artery; or the internal root may be deficient.

b. They may vary in their position with regard to the artery; both may be situated behind the vessel; or one behind, and the other in front of it.

c. The nerve, formed in the usual manner, may be joined lower down by a large branch from the external cutaneous; such a case presents a junction of two large nerves in front of the brachial artery, in the middle of the arm.

d. The nerve in many cases crosses under, instead of over the artery.

e. The nerve sometimes runs parallel and external to the artery; or it may run parallel to, and in front of, the artery.

say that it supplies the two pronators and all the flexors of the forearm (except the flexor carpi ulnaris and the ulnar half of the flexor profundus digitorum); the muscles of the ball of the thumb, the two radial lumbricales, both sides of the thumb, fore and middle fingers, and the radial side of the ring finger, on their palmar aspect (Fig. 123).

Musculo-cutaneous Nerve.

This nerve (often called the external cutaneous or perforans Casserii) arises in common with the external root of the median from the external cord of the brachial plexus behind the pectoralis minor, and is situated on the outer side of the axillary artery. It perforates the coraco-brachialis obliquely, and then runs down between the biceps and the brachialis anticus to the outer side of the arm. A little above the elbow-joint, between the tendon of the biceps and the supinator radii longus, the nerve pierces the deep fascia and becomes subcutaneous; then, passing under the median cephalic vein, it divides into an anterior and a posterior branch, for the supply of the integuments of the forearm (Figs. 122, 123).

The musculo-cutaneous nerve, in the upper part of its course, sends branches to the coraco-brachialis and the short head of the biceps, and, as it descends between the biceps and the brachialis anticus, it supplies both. Consequently, if the nerve were divided in the axilla, the result would be inability to bend the arm.* This nerve also sends small filaments to supply the elbow-joint.

In one hundred arms the relative position of the nerve to the artery in its course down the arm was as follows:—

- In 72, the nerve took the ordinary course.
- “ 20, the nerve crossed obliquely under the artery.
- “ 5, the nerve ran parallel and superficial to the artery.
- “ 3, the nerve ran parallel and external to the artery.

These varieties of the median nerve are of practical importance, for this reason: whenever in the operation of tying the brachial artery, we do not find the nerve in its normal position, we may expect to find some irregular distribution of the arteries—*e. g.*, a high division of the brachial, or even, which I have often seen, a ‘*vas aberrans*’ coming from the upper part of the brachial, and joining either the radial or ulnar arteries.

* In some instances the musculo-cutaneous nerve descends on the inner side of the coraco-brachialis without perforating the muscle; in these cases it often sends a larger branch than usual to the median nerve.

The trunk of the musculo-cutaneous nerve may come from the median at any point between the axilla and the middle of the arm. In some subjects the nerve is absent; all its branches are then supplied by the median, which is larger than usual. Such anomalies are easily explained by the fact of the two nerves having a common origin.

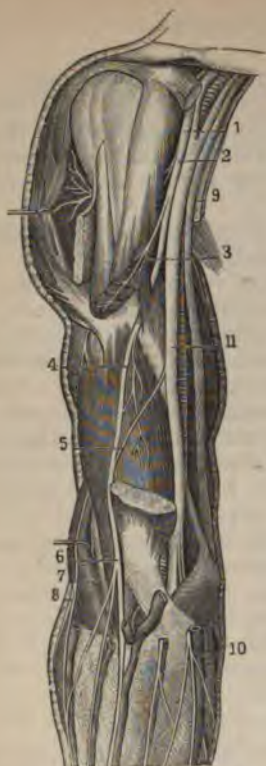

FIG. 122.—BRACHIAL PORTION OF MUSCULO-CUTANEOUS MEDIAN AND ULNAR NERVES.

1. Musculo-cutaneous.
2. Branch of the same to the coraco-brachialis muscle.
3. Branch which supplies the biceps.
4. Branch to brachialis anticus muscle.
5. Anastomosing branch which it receives from the median.
6. Branch of the nerve at the point where it pierces the aponeurosis of the arm.
7. Radial nerve as it passes between the brachialis anticus and supinator longus, or brachio-radialis.
8. External cutaneous branch from the radial.
9. Divided trunk of the internal cutaneous.
10. Anterior or ulnar branch of the internal cutaneous.
11. Brachial portions of the median and ulnar nerves.

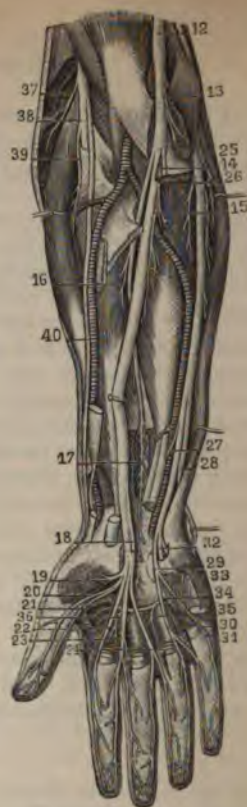

FIG. 123.—TERMINAL PORTION OF THE MEDIAN AND ULNAR NERVES.

12. Forearm, palmar, and digital portions of these nerves.
13. Branch to the pronator radii teres muscle.
14. Anterior muscular branches divided and removed.
15. Branch to the flexor profundus digitorum.
16. Branch to the flexor longus pollicis.
17. Branch to the interosseous membrane.
18. Palmar (cutaneous) branch divided below its origin.
19. To the thenar eminence.
20. External lateral branch of the thumb.
21. Internal lateral branch of the same.
22. External digital branch to the index finger.
23. Common trunk to the index and middle fingers.
24. Digital branches from the median to the middle finger and the thumb side of the ring finger.
25. Ulnar nerve.
26. Branch of the same nerve to the flexor profundus digitorum.
27. Cutaneous and anastomosing filament from the ulnar.
28. Dorsal branch of this nerve.
29. Superficial palmar branch.
30. Common trunk for the ring and little fingers.
31. Digital branch to the internal side of the little finger.
32. Deep palmar branch.
33. Branches from the preceding to the hypothenar eminence.
34. Branches to the fourth interosseous and fourth lumbricals.
35. Branches to the same in the third.
36. Branches to the adductor pollicis and the muscles of the first and second interosseous spaces.
- 37, 38, 39, 40. Branches of radial.

DISSECTION OF THE FRONT OF THE FOREARM.

The front of the forearm presents, at the bend of the elbow, a triangular depression, from which there extends down to the wrist a groove which corresponds to the radial artery; on the inner side is another groove, increasing in depth towards the wrist, indicating the course of the ulnar artery. The head of the radius can be easily felt on the outer side, below the external condyle of the humerus, and in the lower third the bone becomes again defined, terminating below in the styloid process, beyond which is the prominence of the tubercle of the scaphoid. The border of the ulna can be felt on the inner side of the forearm, in the lower half, and it ends at the wrist in an ill-defined styloid process, which does not descend as low as the corresponding process of the radius. The lower part of the forearm presents, an inch (2.5 cm.) beyond the wrist-joint, a transverse furrow, which corresponds with the border of the annular ligament.

Dissection. Prolong the incision down to the wrist, and, at its termination, make another transversely. Reflect the skin, and dissect the subcutaneous veins and nerves.

Cutaneous Veins. On the inner side is the *anterior ulnar vein*, which commences on the front of the wrist, and is then continued upwards on the inner side of the forearm as far as the elbow, where it is joined by the posterior ulnar vein to form the common ulnar vein. This vein communicates with the median vein by numerous branches (p. 312).

The veins on the back of the hand commence at the extremities of the fingers, run up *between* the knuckles, and unite on the back of the hand, forming an arch with its concavity upwards. The *posterior ulnar vein* arises from this arch by a branch (*vena salvatella*) situated over the fourth interosseous space, and runs up on the back of the forearm, towards the inner condyle, to join the anterior ulnar vein.

The *radial vein*, situated on the outer side of the forearm, commences on the back of the hand from the venous arch, runs up the radial side of the front of the forearm to the elbow, where, after receiving the median cephalic, it becomes the cephalic vein.

Running up in front of the middle of the forearm is the *median vein*; it communicates in the forearm with the radial and anterior ulnar veins, and near the bend of the elbow it is joined by a deep branch—*mediana profunda*—after which it divides into two branches, an outer or *median cephalic*, which joins the cephalic, and an inner or *median basilic*, which joins the basilic (Fig. 119).

Cutaneous Nerves. On the radial side of the forearm, as low down as the wrist, are found the terminal filaments

**Triceps Extensor
Cubiti.**

This muscle has three distinct origins, named, from their position, the *external*, the *internal*, and the *middle* or *long* heads. The *middle* or *long* head *arises* by a flat tendon from the inferior border of the scapula, close to the glenoid cavity, and in connection with the glenoid and capsular ligaments. The *external* head *arises* from the humerus, beginning in a pointed form immediately below the insertion of the teres minor, from the posterior surface between this and the musculo-spiral groove, and from the external intermuscular septum. The *internal* head *arises* from the humerus below the insertion of the teres major, from the posterior surface of the bone below the musculo-spiral groove and from the internal intermuscular septum. The three heads unite, near the middle of the arm, to form a single fleshy mass, which covers the posterior part of the elbow-joint, and is *inserted* by a thick tendon into the summit and sides of the olecranon. There is a bursa between the tendon and the olecranon, which is sometimes multilocular. Each head is supplied by a separate branch from the musculo-spiral nerve.*

**Musculo-spiral
Nerve.**

This, the largest of the brachial nerves, arises, in common with the circumflex, from the posterior cord of the axillary plexus (p. 306). It descends at first behind the axillary artery, and then behind the brachial artery; it subsequently winds obliquely round the posterior part of the humerus, between the external and internal heads of the triceps, in company with the superior profunda artery. About the lower third of the outer side of the arm the nerve perforates the external intermuscular septum, and then runs deeply embedded between the brachialis anticus and the supinator radii longus.

The nerve gives off branches on the *inner* side of the humerus, to the inner and long heads of the triceps, and the internal cutaneous branch; on the *back* of the humerus, to the external head of the triceps and the anconeus; on the *outer* side of the humerus, to the supinator radii longus, the extensor carpi radialis longior, and the brachialis anticus (usually); lastly, after perforating the septum, it gives off the upper and lower external cutaneous branches.

A little above the elbow-joint the nerve divides into two principal branches—the *radial*, which accompanies the radial artery along the forearm, and the *posterior interosseous*, which perforates the supinator *brevis*, and supplies the muscles on the back of the forearm.

To sum up the muscular distribution of this nerve, we may say that it supplies *all* the extensors of the forearm, wrist, thumb, and fingers; and *all* the supinators except one—namely, the biceps (supplied by the musculo-cutaneous nerve).

* The *subanconeus*, a small muscle situated beneath the triceps, will be described later on.

DISSECTION OF THE FRONT OF THE FOREARM.

The front of the forearm presents, at the bend of the elbow, a triangular depression, from which there extends down to the wrist a groove which corresponds to the radial artery; on the inner side is another groove, increasing in depth towards the wrist, indicating the course of the ulnar artery. The head of the radius can be easily felt on the outer side, below the external condyle of the humerus, and in the lower third the bone becomes again defined, terminating below in the styloid process, beyond which is the prominence of the tubercle of the scaphoid. The border of the ulna can be felt on the inner side of the forearm, in the lower half, and it ends at the wrist in an ill-defined styloid process, which does not descend as low as the corresponding process of the radius. The lower part of the forearm presents, an inch (2.5 cm.) beyond the wrist-joint, a transverse furrow, which corresponds with the border of the annular ligament.

Dissection. Prolong the incision down to the wrist, and, at its termination, make another transversely. Reflect the skin, and dissect the subcutaneous veins and nerves.

Cutaneous Veins. On the inner side is the *anterior ulnar vein*, which commences on the front of the wrist, and is then continued upwards on the inner side of the forearm as far as the elbow, where it is joined by the posterior ulnar vein to form the common ulnar vein. This vein communicates with the median vein by numerous branches (p. 312).

The veins on the back of the hand commence at the extremities of the fingers, run up *between* the knuckles, and unite on the back of the hand, forming an arch with its concavity upwards. The *posterior ulnar vein* arises from this arch by a branch (*vena salvatella*) situated over the fourth interosseous space, and runs up on the back of the forearm, towards the inner condyle, to join the anterior ulnar vein.

The *radial vein*, situated on the outer side of the forearm, commences on the back of the hand from the venous arch, runs up the radial side of the front of the forearm to the elbow, where, after receiving the median cephalic, it becomes the cephalic vein.

Running up in front of the middle of the forearm is the *median vein*; it communicates in the forearm with the radial and anterior ulnar veins, and near the bend of the elbow it is joined by a deep branch—*mediana profunda*—after which it divides into two branches, an outer or *median cephalic*, which joins the cephalic, and an inner or *median basilic*, which joins the basilic (Fig. 119).

Cutaneous Nerves. On the radial side of the forearm, as low down as the wrist, are found the terminal filaments

of the *anterior branch* of the musculo-cutaneous nerve, which, about the middle of the forearm, sends a *posterior branch* backwards to supply the posterior and lower part of the forearm as low as the wrist, communicating with the radial and external cutaneous branch of the musculo-spiral. At the lower part of the front of the forearm, one or more of these filaments are situated over the radial artery, and one branch passes to the palm to supply the skin over the muscles of the ball of the thumb; it communicates with the palmar branch of the median and with the radial nerve.

In front of the upper part of the forearm are some filaments of the *external cutaneous branch* of the musculo-spiral nerve; on the outer and back part of the forearm, near the elbow, the lower *external cutaneous branch* of the musculo-spiral runs down as far as the wrist to supply the skin.

At the lower third of the radial side of the forearm, the *radial nerve* becomes superficial, and turns over the radius to supply the back of the hand and fingers.

On the ulnar side the *anterior division* of the internal cutaneous nerve descends as far as the wrist, its *posterior branch* passing the back of the forearm to supply it as far as the middle. Near the styloid process of the ulna, the *dorsal branch* of the ulnar nerve perforates the fascia to reach the back of the hand.

Deep Fascia of the Forearm. The muscles of the forearm are enveloped by a dense shining aponeurosis, continuous with that of the arm. Its thickness increases towards the wrist, that the tendons, in this situation, may be kept in their position. It is composed of fibres which cross each other obliquely, and is attached, above, to the condyles of the humerus and olecranon; internally, to the ridge on the posterior part of the ulna. At the back of the wrist it forms the posterior annular ligament, and in front it is continuous with the anterior annular ligament. Above, the fascia is strengthened by fibres from the tendons of the biceps and brachialis anticus. The aponeurotic expansion from the inner edge of the tendon of the biceps is exceedingly strong. It braces the muscles on the inner side of the forearm, and interlaces at right angles with the fibres of the fascia attached to the internal condyle. The under surface of the fascia gives origin to the muscular fibres in the upper part of the forearm, and furnishes septa which separate the muscles, and form surfaces for their origin. The fascia is perforated at various parts for the passage of the cutaneous vessels and nerves of the forearm.

Dissection. Remove the fascia from the muscles by incisions corresponding to those for reflecting the skin, taking care of the cutaneous branches of the median and ulnar nerves close to the wrist.

Triangle at the Elbow.

At the bend of the elbow is a triangular space, with its base towards the humerus; on the inner side this space is bounded by the pronator teres; on the outer, by the supinator radii longus or brachio-radialis. In it are the following objects which must be carefully dissected: 1. In the centre is the brachial artery (with its companion veins) dividing into the radial as its outer, and into the ulnar as its inner branch; 2, on the outer side of the artery is the tendon of the biceps; 3, on the inner side is the median nerve; 4, the musculo spiral nerve on the outer side is partly concealed by the supinator longus; 5, the radial recurrent artery; 6, the anterior ulnar recurrent; 7, the common interosseous branch of the ulnar artery; 8, the vena mediana profunda.

Muscles of the Forearm.

The muscles of the forearm are arranged in two groups: one, consisting of supinators and extensors, is attached to the outer condyloid ridge and condyle; the other, consisting of pronator and flexors, is attached to the inner condyle. The inner group should be examined first. They arise by a common tendon, and are arranged in the following order: pronator teres; flexor carpi radialis; palmaris longus; flexor sublimis digitorum, and flexor carpi ulnaris.

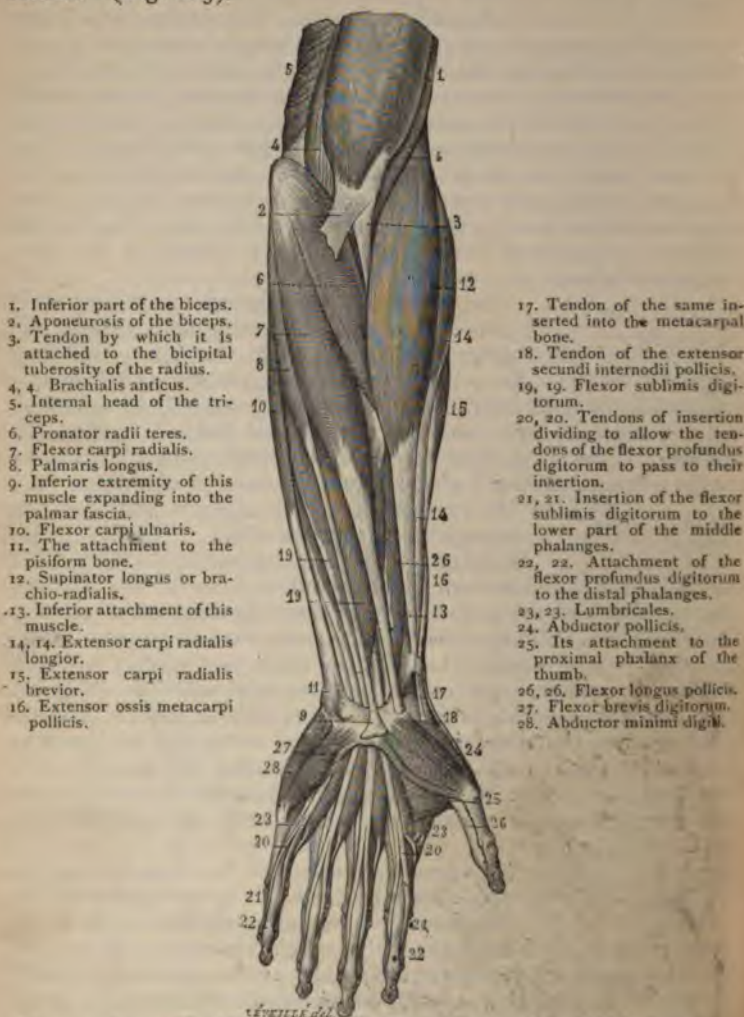
Pronator Radii Teres.

This muscle forms the inner boundary of the triangular space at the elbow. It *arises* by two heads; one, from the anterior surface of the internal condyle, from the common tendon, from the fascia of the forearm, and from the septum between it and the flexor carpi radialis; the other, by a small tendinous origin from the inner border of the coronoid process of the ulna. From these two origins, between which the median nerve passes, the muscle proceeds obliquely downwards and outwards across the forearm, and is *inserted* by a flat tendon into a rough surface on the outer and back part of the middle third of the radius. In amputating the forearm it is very desirable to save the insertion of this muscle, that the stump may have a pronator. Its nerve comes from the median (Fig. 125).

Flexor Carpi Radialis.

This muscle, situated on the ulnar side of the preceding muscle, *arises* by the common tendon from the internal condyle, from the intermuscular septa, and from the fascia of the forearm. The fleshy fibres terminate a little above the middle of the forearm, in a flat tendon, which runs in a separate sheath outside the anterior annular ligament of the wrist, passes through a groove in the os trapezium, bridged over by fibrous tissue and lined by a synovial membrane, and is *inserted* into the base of the metacarpal bone of the index finger. The outer border of its tendon is the guide to the radial

artery in the lower half of the forearm. Its nerve comes from the median* (Fig. 125).



1. Inferior part of the biceps.
2. Aponeurosis of the biceps.
3. Tendon by which it is attached to the bicipital tuberosity of the radius.
4. 4. Brachialis anticus.
5. Internal head of the triceps.
6. Pronator radii teres.
7. Flexor carpi radialis.
8. Palmaris longus.
9. Inferior extremity of this muscle expanding into the palmar fascia.
10. Flexor carpi ulnaris.
11. The attachment to the pisiform bone.
12. Supinator longus or brachio-radialis.
13. Inferior attachment of this muscle.
- 14, 14. Extensor carpi radialis longior.
15. Extensor carpi radialis brevis.
16. Extensor ossis metacarpi pollicis.

17. Tendon of the same inserted into the metacarpal bone.
18. Tendon of the extensor secundi internodii pollicis.
- 19, 19. Flexor sublimis digitorum.
- 20, 20. Tendons of insertion dividing to allow the tendons of the flexor profundus digitorum to pass to their insertion.
- 21, 21. Insertion of the flexor sublimis digitorum to the lower part of the middle phalanges.
- 22, 22. Attachment of the flexor profundus digitorum to the distal phalanges.
- 23, 23. Lumbricales.
24. Abductor pollicis.
25. Its attachment to the proximal phalanx of the thumb.
- 26, 26. Flexor longus pollicis.
27. Flexor brevis digitorum.
28. Abductor minimi digiti.

FIG. 125.—SUPERFICIAL MUSCLES ON THE ANTERIOR SURFACE OF THE LEFT FOREARM.

* A muscle is not infrequently found beneath this muscle, called by Mr. Wood the flexor carpi radialis brevis, or profundus. It arises from the front of the radius above the pronator quadratus, and is inserted into the base of the metacarpal bone of the middle finger. (*Journ. of Anat. and Phys.*, p. 55, Nov. 1866.)

Palmaris Longus. This slender muscle *arises* from the common tendon at the internal condyle, from the intermuscular septa, and from the fascia of the forearm. About the middle of the forearm it terminates in a flat tendon, which descends along the middle of the forearm to the wrist, lying upon the flexor sublimis digitorum; it then passes over the anterior annular ligament, and is continued into the palmar fascia. This muscle is a tensor of the palmar fascia.* Its nerve comes from the median (Fig. 125).

Flexor Carpi Ulnaris. This muscle *arises* by two heads: one from the internal condyle, the common tendon, and the intermuscular septum; the other from the inner edge of the olecranon: these two origins form an arch, under which the ulnar nerve and the posterior ulnar recurrent artery pass. It also *arises* from the upper two-thirds of the posterior edge of the ulna, through the medium of the aponeurosis, which is common to this muscle, the flexor profundus digitorum, and the extensor carpi ulnaris. The tendon appears on the radial side of the muscle, about the lower third of the forearm, and receives fleshy fibres on its ulnar side as low as the wrist. It is *inserted* into the pisiform bone, and thence by a strong tendon into the unciform and the base of the fifth metacarpal bone. Its nerve comes from the ulnar (Fig. 125).

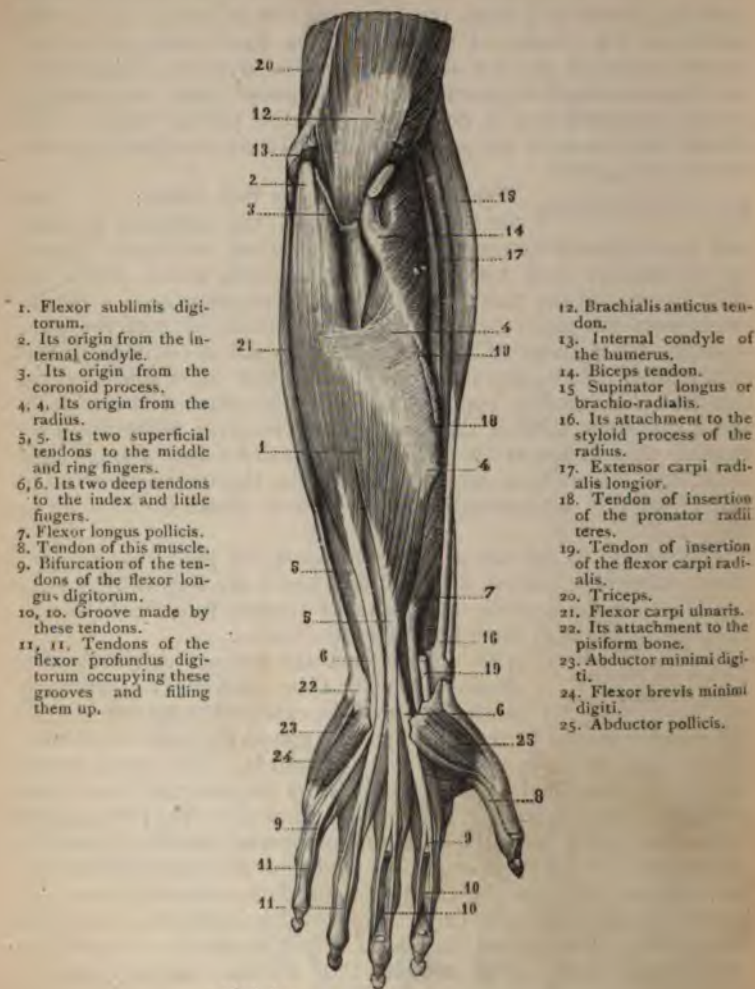The tendon of the flexor carpi ulnaris is the guide to the ulnar artery, which lies close to its radial side, and is *overlapped* by it. As it passes over the annular ligament, the tendon furnishes a fibrous expansion to protect the ulnar artery and nerve.

**Flexor Sublimis
Digitorum.**

This muscle has three distinct origins, and is situated beneath those previously mentioned, so that, in order to expose it fully, the preceding muscles should be reflected by cutting them through the middle, and turning the ends upwards and downwards. The longer *origin* takes place from the internal condyle, from the internal lateral ligament, the common tendon, and the intermuscular septa; the second *origin* takes place from the coronoid process of the ulna above the pronator teres; the third *origin*, by tendinous and fleshy fibres from the oblique ridge on the front of the radius, extending from the tubercle to about an inch (2.5 cm.) below the insertion of the pronator teres. This, called its *radial origin*, is partly concealed by the pronator teres. The muscle, thus formed, passes down the

* The palmaris longus is absent in about one out of ten subjects. The situation of its muscular portion is subject to variation, sometimes occupying the middle, sometimes the lower third of the forearm. The tendon is in some instances wholly inserted into the anterior annular ligament.

middle of the forearm, and divides into four distinct muscular slips ;



LÉVILLÉ DEL. VERRÉ SC.
 FIG. 126.—FLEXOR MUSCLES OF THE FINGERS.

from these, four tendons arise, which pass beneath the annular ligament, arranged in two pairs, the tendons of the middle and

ring fingers being placed over those of the fore and little fingers. The tendons pass through the palm to the fingers, where they diverge and split to allow the passage of the deep flexor tendons, and are *inserted* into the sides of the second phalanges where they will be subsequently traced. Its *action* is, therefore, to bend the second joint of the fingers (Fig. 124).

The muscles described as arising from the internal condyle are all supplied by the median nerve, except the flexor carpi ulnaris, which is supplied by the ulnar.

Having finished the superficial muscles on the inner side of the forearm, notice one of those on the outer side, named supinator radii longus, before tracing the vessels and nerves of the forearm.

Supinator Radii Longus, or Brachio-radialis. This muscle forms the external boundary of the triangular space at the bend of the elbow. It *arises* by fleshy fibres from the upper two-thirds of the external condyloid ridge of the humerus, commencing a little below the insertion of the deltoid, and from the external intermuscular septum. The muscular fibres terminate about the middle of the forearm in a flat tendon, which is *inserted* into the outer side of the base of the styloid process of the radius. The inner border of the muscle is the guide to the radial artery, which lies between this muscle and the flexor carpi radialis. It supinates the hand, but acts much more powerfully as a flexor of the forearm. It is supplied by the musculo spiral nerve (Fig. 124).

Radial Artery. The radial artery, the smaller division of the brachial, runs down the radial side of the forearm to the wrist, where it turns over the external lateral ligament of the carpus, beneath the extensor tendons of the thumb, and sinks into the angle between the first and second metacarpal bones to form the deep palmar arch. Thus, its course corresponds with a line drawn from the middle of the bend of the elbow to the front of the styloid process of the radius.

In the upper third of the forearm, the artery lies deep between the pronator teres on the inner and the supinator longus on the outer side; the fleshy border of the latter overlaps it in muscular subjects. In the lower two-thirds of the forearm the artery is more superficial, and is placed between the tendons of the supinator longus on the outer and the flexor carpi radialis on the inner side. In its course, it lies successively on the following: first, upon the tendon of the biceps; secondly, upon the supinator radii brevis; thirdly, upon the insertion of the pronator teres; fourthly, upon the radial origin of the flexor sublimis; fifthly, upon the flexor longus pollicis; sixthly, upon the pronator quadratus, and lastly, upon the lower end of the radius. The artery then turns

round the outer side of the wrist-joint, lying upon the external lateral ligament, and covered by the tendons of the extensores ossi metacarpi and primi internodii pollicis, some cutaneous veins, and branches of the radial nerve; next, it lies upon the trapezium; it is then crossed by the extensor secundi internodii pollicis; and, lastly, passing between the two heads of the first dorsal interosseous muscle, it enters the palm to form the deep palmar arch. It is accompanied by two veins, which communicate at frequent intervals, and join the venæ comites of the brachial artery at the bend of the elbow (Fig. 121).

In the middle third of its course the artery is accompanied by the radial nerve (a branch of the musculo-spiral), which lies to its outer side. Below this point, the nerve leaves the artery and passes, under the tendon of the supinator longus, to the back of the hand.

Thus, in the situation where the pulse is usually felt, the radial nerve no longer accompanies the artery; nevertheless, the vessel is accompanied by a branch of the musculo-cutaneous (or external cutaneous), which lies superficially to it.

The radial artery sends off in the forearm the following branches, besides offsets, which supply the muscles on the outer side of the forearm—

a. The *radial recurrent* is given off just below the elbow; it ascends upon the supinator brevis, between the supinator longus and the brachialis anticus, to supply the long and short supinators and the two radial extensors. It runs up with the musculo-spiral nerve, and forms a delicate inosculation with the superior profunda (p. 319).

b. The *muscular branches* which are given off to the muscles on the outer side of the forearm.

c. The *arteria superficialis volæ* arises from the radial, about half an inch (13 mm.) or more above the lower end of the radius; it runs over the anterior annular ligament, above or through the origin of the muscles of the ball of the thumb, into the palm of the hand, where it sometimes inosculates with the superficial branch of the ulnar, and completes the superficial palmar arch.*

d. The *anterior carpal* artery is a small branch of the radial, which arises close to the lower border of the pronator quadratus, and then runs beneath the tendons, and supplies the anterior surface of the synovial membrane and bones of the carpus, anastomosing with the anterior interosseous, the anterior carpal branch of the ulnar, and the recurrent carpal branch of the deep palmar arch.

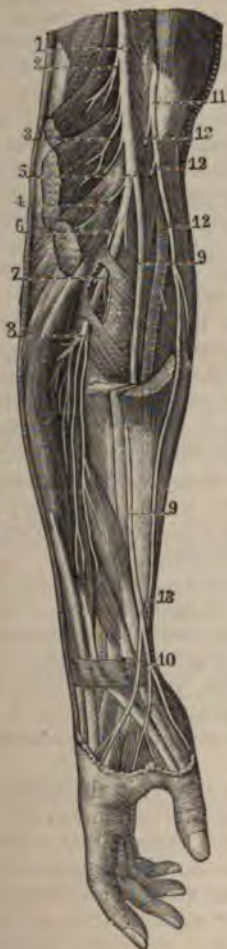At the wrist it gives off—

e. The *posterior carpal* artery, which runs beneath the extensor tendons, and joins the corresponding branch of the ulnar to form an arch; it also anastomoses with the anterior interosseous artery on the back of the wrist.

*There is great variety in the size and origin of the superficialis volæ; sometimes it is very large, arises higher than usual, and runs to the wrist parallel with the radial; sometimes it is very small, terminating in the muscles of the thumb; or it may be absent.

Radial Nerve.

The *radial nerve*, a branch of the musculo-spiral, is given off above the bend of the elbow, deep between the supinator radii longus and brachialis anticus; it



- 1. Trunk of the radial nerve.
- 2. Its branch to supinator longus or brachio-radialis.
- 3. Its branch to extensor carpi radialis longior.
- 4. Its branch to extensor carpi radialis brevior.
- 5. Bifurcation of the trunk.
- 6. Posterior or muscular branch.
- 7. The same branch traversing the supinator brevis and supplying it.

- 8. Terminal filaments of this division.
- 9, 9. Anterior or cutaneous branch of this nerve.
- 10. Termination of this branch.
- 11. Musculo-cutaneous n.
- 12. Its terminal divisions.
- 13. Anastomosing branch with the cutaneous division of the radial.

FIG. 127.—TERMINAL BRANCHES OF THE RADIAL NERVE.

descends on the outer side of the radial artery, covered by the supinator radii longus. In the *upper* third of the forearm, the

nerve is at some distance from the artery; in the *middle* third, it approaches nearer to it, lying to its outer side; but in the *lower* third, the nerve leaves the artery, passes underneath the tendon of the supinator longus, perforates the deep fascia on the outer side of the forearm, and becomes subcutaneous. It then divides into two branches: an *outer*, the smaller, which supplies the skin of the ball of the thumb, and communicates with the anterior branch of the musculo-cutaneous nerve; and an *inner*, which generally supplies both sides of the dorsal aspects of the thumb, of the index and middle fingers, and of the radial side of the ring finger.

Ulnar Artery. This artery, the larger of the two divisions of the brachial, comes off below the elbow, runs obliquely inwards along the ulnar side of the forearm to the wrist, passes over the annular ligament near the pisiform bone, and, entering the palm, forms the superficial palmar arch, by inosculating with the superficialis volæ (Fig. 121).

In the upper half of its course the artery describes a gentle curve with the concavity towards the radius, and lies deep beneath the superficial layer of muscles, namely, the pronator teres, flexor carpi radialis, palmaris longus, and flexor sublimis digitorum. It is also crossed in its upper part by the median nerve. In the lower part of its course it comes nearer the surface, and descends between the flexor sublimis and flexor carpi ulnaris, of which the tendon partially overlaps it at the wrist. The artery lies for a short distance on the brachialis anticus; in the remainder of its course it lies on the flexor profundus digitorum.

The ulnar nerve is at first separated from the artery by a considerable interval; about the middle of the forearm it joins the artery, and accompanies it in the rest of its course, lying close to its inner side. Both pass over the anterior annular ligament of the carpus, lying close to the pisiform bone,—the nerve being nearer to the ulnar side and a little behind the artery. A strong expansion from the tendon of the flexor carpi ulnaris protects them in this exposed situation.

Observe that the ulnar artery, in the lower third of its course, lies under the radial border of the tendon of the flexor carpi ulnaris, which is the *surgical guide* to the vessel. The artery is accompanied by two veins, which join the venæ comites of the brachial.

The ulnar artery gives off the following branches in the forearm:—

a. The *anterior and posterior ulnar recurrent arteries* arise immediately below the elbow-joint—sometimes by a common trunk. The *anterior* passes upwards between the brachialis anticus and the pronator teres, and inosculates with the inferior profunda and anastomotica magna. The *posterior*, the larger, ascends between the flexor sublimis and the flexor profundus digitorum, to the space

between the internal condyle and the olecranon : it then passes up between the two heads of the flexor carpi ulnaris, where it inosculates with the inferior profunda, the anastomotica magna, and, above the olecranon, with the posterior interosseous recurrent (p. 319).

b. The *common interosseous artery* is about half an inch long. It arises from the ulnar, just below the tubercle of the radius, and soon divides into the anterior and posterior interosseous, which we shall examine presently.

c. The *muscular branches*, which supply the muscles on the ulnar side of the forearm.

d. The *carpal branches* are given off just above the pisiform bone ; the *posterior carpal* runs beneath the tendon of the flexor carpi ulnaris and the extensor tendons, and forms, with the corresponding branch of the radial artery, an arch, from which are usually given off the second and third dorsal interosseous arteries : these anastomose with the perforating arteries. The *anterior carpal* runs in front of the carpus, beneath the flexor tendons, supplies the synovial membrane and the ligaments, and anastomoses with the anterior carpal from the radial.

Ulnar Nerve.

This nerve runs behind the internal condyle, between two origins of the flexor carpi ulnaris.

In its course down the ulnar side of the upper part of the forearm, the nerve is still covered by this muscle, and lies upon the flexor profundus digitorum. About the middle of the forearm, the nerve joins the ulnar artery, and runs along its inner side over the anterior annular ligament into the palm (Fig. 123).

The ulnar nerve gives off the following branches :—

a. The *articular branches* to the joint are given off to it, immediately behind the elbow.

b. The *muscular branches* are distributed to the flexor carpi ulnaris and the ulnar half of the flexor profundus digitorum, and are given off from the ulnar a short distance below the elbow.

c. A *cutaneous branch* is given off about the middle of the forearm, one filament of which, called the *palmar cutaneous branch*, accompanies the ulnar artery to the palm, and communicates with branches from the median nerve.

d. The *dorsal cutaneous branch*, of considerable size, is given off from the ulnar about two inches above the styloid process of the ulna to pass to the back of the hand. It crosses under the tendon of the flexor carpi ulnaris, pierces the deep fascia, and, immediately below the styloid process of the ulna, appears on the back of the hand, where it divides into branches which supply the back of the little finger and half the ring ; here also it sends a branch which communicates with the corresponding branch of the radial nerve.

e. *Articular branches* are also distributed to the wrist-joint.

Median Nerve.

This nerve, at the bend of the elbow, lies on the inner side of the brachial artery and beneath

the bicipital fascia. It then passes between the two heads of origin of the pronator teres, and descends along the middle of the forearm, between the flexor sublimis and the flexor profundus digitorum. At the lower part of the forearm, it becomes more superficial, lying above the wrist between the outer tendon of the flexor sublimis and the inner border of the tendon of the flexor carpi radialis ; beneath, or to the ulnar side of the palmaris longus,

and having in front of it the skin and deep fascia; it then enters the palm beneath the anterior annular ligament, and divides into five branches for the supply of the thumb, both sides of the fore and middle fingers, and the radial side of the ring finger (Fig. 123).

Immediately below the elbow, the median nerve sends off:—

a. The *muscular branches* to the pronator teres, and to all the flexor muscles of the forearm, except the flexor carpi ulnaris and the ulnar half of the flexor profundus, which are supplied by the ulnar nerve.

b. The *anterior interosseous nerve*, also a branch of the median, runs with the anterior interosseous artery on the interosseous membrane, lying on its radial side, between the flexor longus pollicis and flexor profundus digitorum; it supplies both these muscles and the pronator quadratus.

c. The *palmar cutaneous branch* is given off from the median before it passes beneath the annular ligament. This branch passes over the ligament and divides into numerous filaments to supply the skin of the palm and the ball of the thumb, communicating with the cutaneous palmar branches of the ulnar, the external cutaneous, and the radial nerves.

Dissection.

Now reflect the superficial layer of muscles to see those more deeply seated. Preserve the principal vessels and nerves.

The deep-seated muscles are, on the ulnar side, the flexor digitorum profundus; and, on the radial side, the flexor longus pollicis; beneath both, near the wrist, lies a transverse muscle, the pronator quadratus. On the interosseous membrane, between the first two named muscles, run the anterior interosseous artery and nerve.

Flexor Profundus Digitorum.

This is the thickest muscle of the forearm. It *arises* from the upper two-thirds of the anterior surface of the ulna, surrounding the insertion of the brachialis anticus above, from the same extent of its internal surface, from the aponeurosis attached to the posterior edge of the ulna, and from the ulnar two-thirds of the interosseous membrane. About the middle of the forearm the muscle is *inserted* into four flat tendons, of which only that which goes to the index finger is separate from the others above the wrist. These tendons lie upon the same plane, and pass beneath the annular ligament, under those of the superficial flexor, into the palm, where they diverge to pass to their respective fingers. On the first phalanx of the fingers the tendons of the deep flexor perforate those of the superficial, and are *inserted* into the bases of the third or ungual phalanges. It derives its nerves from the interosseous branch of the median and from the ulnar (Fig. 128).

Flexor Longus Pollicis.

This muscle is situated on the front surface of the radius, outside the preceding. It *arises* from the front surface of the radius, between the tubercle and the oblique ridge above, and the pronator quad-

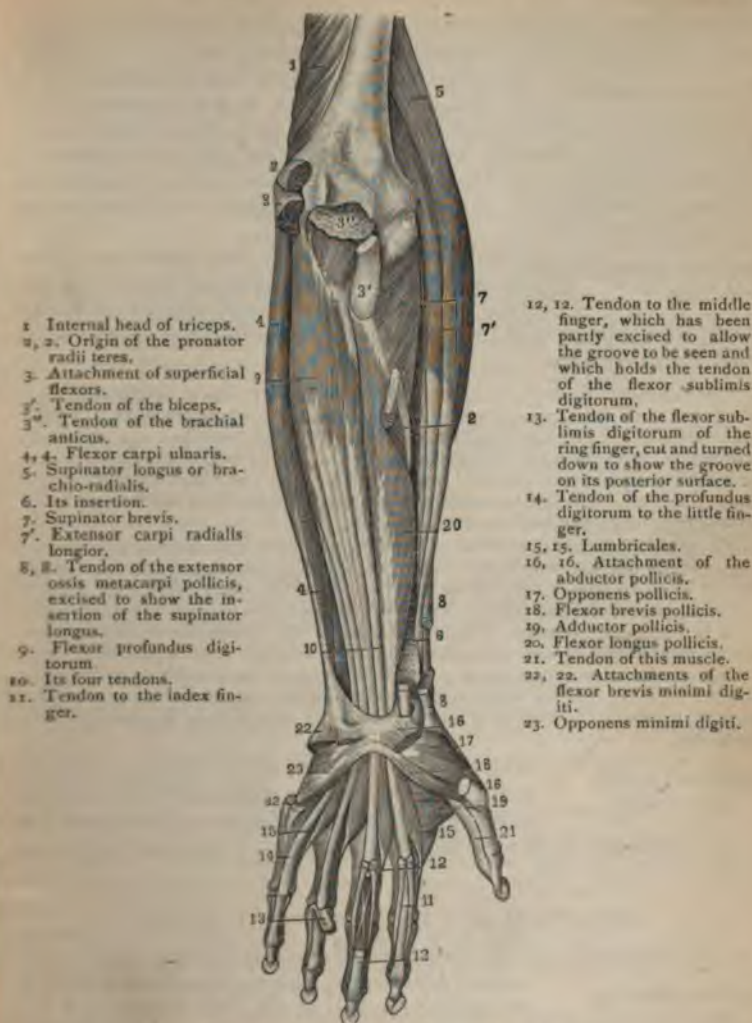


FIG. 128.—DEEP FLEXOR OF THE FINGERS.

ratus below, and from the interosseous membrane.* Its tendon, which begins on the ulnar side of the muscle, proceeds beneath the

* Sometimes by a slip from the coronoid process.

annular ligament to the base of the last phalanx of the thumb. Its nerve comes from the interosseous branch of the median (Fig. 128).

Pronator Quadratus. This square muscle *arises* from the lower fourth of the ulna and from a strong aponeurosis which covers its anterior surface; its fibres pass, some transversely, some obliquely outwards, and are *inserted* into the lower fourth of the anterior surface and the outer border of the radius. It pronates the radius on the ulna. Its nerve proceeds from the interosseous branch of the median.

Anterior Interosseous Artery. Nearly on a level with the insertion of the biceps the ulnar artery gives off from its outer side the *common interosseous*, which runs backwards for about an inch (2.5 cm.), and divides into the *anterior* and *posterior interosseous*.

The *anterior interosseous artery* runs down on the interosseous membrane, lying deeply between the flexor profundus digitorum and flexor longus pollicis. At the upper edge of the pronator quadratus it divides into two branches, one of which, the smaller, passes beneath the muscle, supplies it and the front of the carpal bones, communicating with the anterior carpal arteries from the radial and ulnar; the other, the more important, perforates the interosseous membrane and helps to supply the muscles on the back of the forearm.

A branch, the *arteria comens nervi mediani*, proceeds from the anterior interosseous. It lies in close contact with the nerve, sometimes in its very centre; though usually of small size, it may be as large as the ulnar artery itself, and, in such cases, it passes under the annular ligament with the nerve to join the palmar arch. This is interesting, because it helps to explain the recurrence of hæmorrhage from a wound in the palm, even after the radial and ulnar arteries have been tied.

The anterior interosseous artery gives off branches to the muscles on each side; also the *nutrient arteries* which enter the radius and ulna, near the centre of the forearm, to supply the medullary membrane; these arteries pass upwards towards the elbow.

Anterior Interosseous Nerve.

This nerve is a branch of the median; it generally runs close to the radial side of the artery, and supplies the flexor longus pollicis, half the flexor profundus digitorum, and the pronator quadratus (Fig. 123, p. 322).

DISSECTION OF THE PALM OF THE HAND.

On the ulnar side of the palm of the hand is a round, long eminence, *hypothenar*, which corresponds with the muscles of the ball of the little finger; and on

Surface Marking.

the radial side, placed obliquely over the metacarpal bone of the thumb, is another eminence, *thenar*, which is caused by the muscles of the ball of the thumb. Between the two eminences, at the wrist, is a slight depression, corresponding with the middle of the annular ligament, and which broadens out towards the fingers. The palm of the hand, about an inch (2.5 cm.) from the clefts of the fingers,

presents a transverse furrow, which corresponds with the metacarpophalangeal articulations, with the distal limit of the synovial sheaths of the flexor tendons, with the divisions of the palmar fascia into its four processes, and with the transverse metacarpal ligament. The superficial palmar arch may be indicated by a line drawn from the cleft of the extended thumb across the palm; the deep palmar arch lies half an inch (*13 mm.*) nearer the annular ligament.

Dissection. Make a vertical incision along the centre of the palm, and a transverse one along the bases of the fingers; from this transverse cut continue vertical incisions along the front of the fingers, and reflect the skin; taking care not to remove a small cutaneous muscle—the *palmaris brevis*—situated over the ball of the little finger, and also two small cutaneous branches of the median and ulnar nerves, which are found in the fat of the palm.

Observe how closely, in the centre of the palm, the skin adheres to the palmar fascia beneath it. On the ball of the little finger and the distal ends of the metacarpal bones the subcutaneous structure is composed of a dense filamentous tissue, which contains numerous pellets of fat, forming an elastic pad. A similar padding protects the palmar surfaces of the fingers. These cushions on the ends of the fingers defend them in the powerful actions of the hand; they are also useful in subservience to the nerves of touch.

The palm is supplied with nerves by three small branches—the *palmar branch* of the median passes in front of the anterior annular ligament to the centre of the palm; the *palmar branch* of the ulnar supplies the inner aspect of the hand; and the *anterior branch* of the musculo-cutaneous nerve is distributed to the skin over the thenar eminence. The terminal branches of these cutaneous nerves communicate with each other.

Palmaris Brevis. This small cutaneous muscle is situated on the inner side of the palm. It *arises* from the inner edge of the central palmar fascia and the annular ligament, and is *inserted* into the skin on the ulnar border of the palm. Its use is to support the pad on the inner edge of the palm: it acts powerfully as we grasp; it raises the inner edge of the palm, and deepens the hollow of it, forming the so-called "cup of Diogenes." It is supplied by the ulnar nerve.

Palmar Fascia. This fascia has a silvery lustre, and in the centre of the palm is remarkably dense and strong. It is divided into three portions: a *central*, by far the strongest; an *external*, covering the muscles of the thumb; and an *internal*, covering the muscles of the little finger. From the deep surface of the fascia two septa dip down and divide the palm into three separate compartments; one for the ball of the thumb, a

second for that of the little finger, and a third for the centre of the palm.

The fascia is formed by a prolongation from the anterior annular ligament. It is also strengthened by the expanded tendon of the palmaris longus.

The central portion of the fascia is triangular, with the apex at the wrist. About the middle of the palm it splits into four portions, which are connected by transverse tendinous fibres, extending completely across the palm, and corresponding pretty nearly to the transverse furrow of skin in this situation.

Examine any one of these four portions of the fascia, and you will find that it splits into two strips which embrace the corresponding flexor tendons, and are intimately connected with the transverse metacarpal ligament. The effect of this is that the flexor tendons of each finger are kept in place in the palm by a fibrous ring. Between the four divisions of the palmar fascia the digital vessels and nerves emerge, and descend in a line with the clefts between the fingers.

In the hands of mechanics, in whom the palmar fascia is usually very strong, we find that slips of it are lost in the skin at the lower part of the palm, and also for a short distance along the sides of the fingers.

The chief use of the palmar fascia is to protect the vessels and nerves from pressure when anything is grasped in the hand. It also confines the flexor tendons in their proper place.

Beneath the interdigital folds of the skin there are aponeurotic fibres to strengthen them, constituting what are called the *transverse ligaments* of the fingers. They form a continuous ligament across the lower part of the palm, in front of the digital vessels and nerves.

Dissection.

Cut through the palmar fascia at its attachment to the anterior annular ligament, and reflect it towards the fingers, so as to expose the vessels, nerves, and tendons in the palm. The vessels lie above the nerves, and the tendons still deeper. There is an abundance of loose connective tissue to allow the free play of the tendons. When suppuration takes place in the palm it is seated in this tissue. Reflect for a moment what mischief is likely to ensue. The pus cannot come to the surface through the dense palmar fascia or on the back of the hand; it will, therefore, run up into the carpal bursa under the annular ligament, and make its way deep amongst the tendons of the forearm.

Superficial Palmar Arch.

The ulnar artery, having passed over the annular ligament, near the pisiform bone, describes a curve across the upper part of the palm, beneath the palmar fascia, towards the thumb, and, gradu-

ally diminishing in size, inosculates with the superficialis volæ, and very commonly with a branch from the arteria radialis indicis, to form the *superficial palmar arch*. The curve of the arch is directed towards the fingers, its greatest convexity descending as low as a

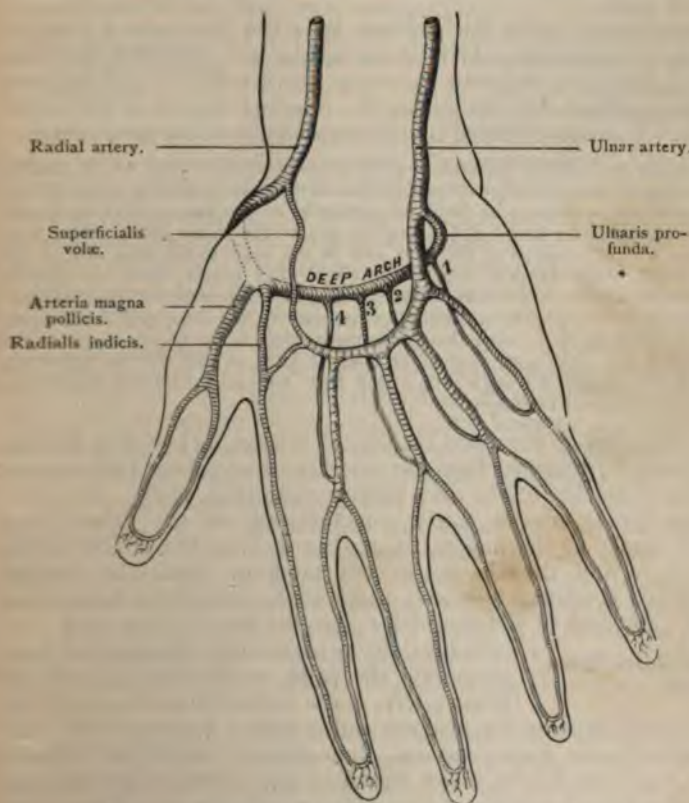


FIG. 129.—DIAGRAM OF THE SUPERFICIAL AND PALMAR ARCHES.
1, 2, 3, 4. Interosseous branches.

horizontal line drawn across the junction of the upper with the middle third of the palm.

In its passage over the annular ligament the artery lies in the furrow, between the pisiform and unciform bones, and is protected by an expansion from the tendon of the flexor carpi ulnaris to the

palmaris longus. The ulnar nerve lies close to the inner side of the artery, both being covered by the palmaris brevis. In the palm the artery rests for a short distance upon the muscles of the little finger, then it lies upon the superficial flexor tendons and the divisions of the ulnar and median nerves, and is covered by the palmar fascia.

Immediately below the pisiform bone the ulnar artery gives off the *ulnaris profunda*, which sinks deeply into the palm, between the origins of the abductor and flexor brevis minimi digiti, to form the deep palmar arch, by joining the terminal branch of the radial artery. It is accompanied by the deep branch of the ulnar nerve.

From the concavity of the arch small *recurrent branches* ascend to the carpus, and inosculate with the other carpal branches of the radial and ulnar arteries.

Four digital arteries arise from the convexity of the arch. They supply all the digits, except the thumb and the radial side of the index finger. The *first* descends over the muscles on the inner side of the palm, to the ulnar side of the little finger, along which it runs to the apex. The *second, third, and fourth* descend nearly vertically between the tendons, *in a line with the clefts* between the fingers, and, about half an inch (13 mm.) above the clefts, each divides into two branches, which proceed along the opposite sides of the fingers nearly to the end of the last phalanges, where they unite to form an arch with the convexity towards the end of the finger; from this arch numerous branches supply the papillæ at the tip of the finger.

In the palm of the hand the digital arteries, before they divide, are joined by branches from the corresponding palmar interosseous arteries (branches of the deep palmar arch) (Fig. 129).

The digital arteries freely communicate, on the palmar and dorsal aspect of the fingers, by transverse branches, which supply the joints and the sheaths of the tendons. Near the ungual phalanx, a considerable branch passes to the back of the finger, and forms a network of vessels which supply the matrix of the nail.

Ulnar Nerve in the Palm. The *ulnar nerve* passes over the annular ligament into the palm, on the inner side of the ulnar artery, and a little behind it. It lies in the groove between the pisiform and unciform bones, so that it is perfectly secure from pressure. Immediately below the pisiform bone, the nerve divides into a superficial and a deep palmar branch. The *deep* branch supplies the muscles forming the ball of the little finger, and accompanies the *ulnaris profunda* artery into the palm, to supply *all* the interosseous muscles, the two ulnar lumbricales, and it ends in branches which are distributed to the first dorsal interosseous, the adductor pollicis, and the inner head of the flexor brevis pollicis; it, moreover, sends filaments which ascend to supply the wrist-joint, and others which descend to the metacarpo-phalangeal joints. The *superficial* branch sends filaments to the palmaris brevis, to the skin on the inner side of the palm, and then divides into two

digital nerves, one for the supply of the ulnar side of the little finger, the other for the contiguous sides of the little and ring fingers. This branch also communicates with the median nerve behind the superficial palmar arch. All the digital branches run along the sides of the fingers to their extremities superficial to their corresponding arteries (Figs. 122, 123, p. 322).

Anterior Annular Ligament of the Carpus.

This exceedingly strong and thick ligament confines the flexor tendons of the fingers and thumb, and fastens together the bones of the carpus. It is attached, externally, to the tuberosity of the scaphoid and the ridge on the trapezium; internally, to the pisiform and unciform. Its upper border is continuous with the aponeurosis in front of the wrist; its lower is connected with the palmar fascia; its anterior surface receives the expanded tendon of the palmaris longus, and gives origin to most of the muscles of the ball of the thumb and little finger (Fig. 125, p. 323).

Now proceed to the muscles composing the ball of the thumb and the little finger. The dissection of them requires considerable care.

Muscles of the Ball of the Thumb.

The great strength of the muscles of the ball of the thumb is one of the distinguishing features of the human hand. This strength is necessary in order to oppose that of all the fingers. In addition to its strength, the thumb enjoys perfect mobility. It has no less than eight muscles—namely, an abductor, an opponens, two flexors, three extensors, and an adductor.

Abductor Pollicis.

This is the most superficial. It is a thin, flat muscle, and *arises* from the ridge of the os trapezium and the annular ligament. It passes forwards and outwards, and is *inserted* by a flat tendon into the radial side of the base of the first phalanx of the thumb. Its *action* is to draw the thumb away from the fingers. Its nerve comes from the median. Reflect it from its insertion to expose the following (Fig. 125, No. 24, p. 323):—

Opponens Pollicis.

This muscle *arises* from the front of the os trapezium beneath the abductor, and from the annular ligament, and, passing forwards and outwards, is *inserted* into the whole length of the radial side of the metacarpal bone of the thumb. The *action* of this powerful muscle is to oppose the thumb to all the fingers. Its nerve comes from the median. Reflect it from its insertion, to expose the following (Fig. 128, No. 17, p. 337):—

Flexor Brevis Pollicis.

This muscle has two origins, between which runs the tendon of the flexor longus pollicis: one, the superficial, from the annular ligament and trapezium; the

other, the deep, from the trapezoid, os magnum, the bases of the second and third metacarpal bones, and the sheath of the tendon of the flexor carpi radialis. It is *inserted* by two strong tendons into the base of the first phalanx of the thumb; the superficial tendon being connected with the abductor pollicis, and the deep one with the adductor pollicis. A sesamoid bone is found in each of the tendons. The tendons of insertion of this muscle are separated by the long flexor tendon of the thumb and the arteria magna pollicis. Its *action* is to bend the first phalanx of the thumb. The superficial portion is supplied by the median nerve; the deep, by the ulnar (Fig. 128, No. 18, p. 337).

Adductor Pollicis. This triangular muscle *arises* from the palmar aspect of the shaft of the metacarpal bone of the middle finger; its fibres converge and are *inserted*, along with the deep or inner portion of the flexor brevis pollicis, into the base of the first phalanx of the thumb and the internal sesamoid bone. Its *action* is to draw the thumb towards the palm, as when we bring the tips of the thumb and little finger into contact. It is supplied by the deep branch of the ulnar nerve, which also supplies the deep head of the flexor brevis pollicis. The other muscles of the ball of the thumb are supplied by the median nerve (Fig. 128, No. 19, p. 337).

Muscles of the Ball of the Little Finger. The muscles of the little finger correspond in some measure with those of the thumb. Thus there is an abductor, a flexor brevis, and an opponens minimi digiti. All derive their nerves from the deep branch of the ulnar.

Abductor Minimi Digiti. This, the most superficial of the muscles of the little finger, *arises* from the pisiform bone, and from the tendinous expansion of the flexor carpi ulnaris: it is *inserted* by a flat tendon into the inner side of the base of the first phalanx of the little finger. Its *action* is to draw this finger from the others. Its nerve comes from the deep branch of the ulnar.

Flexor Brevis Minimi Digiti. This slender muscle may be considered as a portion of the preceding, to the radial side of which it is situated. It *arises* from the apex of the unciform bone and annular ligament, and is *inserted* with the tendon of the abductor into the base of the first phalanx of the little finger. Its *action* is similar to that of the abductor. Nerve from deep branch of ulnar. Between the origins of the abductor and flexor brevis minimi digiti, the deep branch of the ulnar artery and nerve sinks down to form the deep palmar arch (Fig. 126, No. 23, p. 330).

**Opponens Minimi
Digiti.**

The last two muscles must be reflected from their insertion, to expose the *opponens minimi digiti*. It arises from the unciform process and the annular ligament, and is inserted along the ulnar side of the shaft of the metacarpal bone of the little finger. Its action is to draw this bone, the most moveable of all the metacarpal bones of the fingers, towards the thumb. Thus it greatly strengthens the grasp of the palm. Nerve from deep branch of ulnar (Fig. 128, No. 23, p. 337).

Dissection.

Cut vertically through the anterior annular ligament, and observe that, with the carpal bones, it forms an elliptical canal, with the broad diameter transversely. This canal is lined by a synovial membrane which is reflected loosely over the tendons. Superficial to the ligament pass the palmaris longus, the ulnar artery and nerve, the fibrous expansion from the flexor carpi ulnaris covering these vessels and nerve, and the palmar branch of the median and ulnar nerves; beneath it pass the superficial and deep flexor tendons of the fingers, the long flexor tendon of the thumb, and the median nerve. The tendon of the flexor carpi radialis does not run with the other tendons, but is contained in a distinct sheath, lined by a separate synovial membrane, formed, partly by the annular ligament, and partly by the groove in the trapezium.

**Median Nerve in the
Palm.**

In its passage under the annular ligament, the median nerve is enveloped in a fold of synovial membrane, and lies upon the flexor tendons. Here it becomes enlarged and flattened, and of a pinkish colour, and divides into two nearly equal parts: the *external* gives a recurrent branch to the muscles of the ball of the thumb—namely, to the abductor pollicis, the opponens pollicis, and the outer head of the flexor brevis pollicis, and then terminates in three digital nerves, two of which are distributed to the thumb, and the third to the radial side of the index finger; the *internal* gives digital branches which supply the ulnar side of the forefinger, both sides of the middle finger, and the radial side of the ring finger (Fig. 123, p. 322).

The *two* nerves to the thumb proceed, one on each side of the long flexor tendon, to the last phalanx: the outer one being connected with a terminal filament of the radial.

The *third* digital nerve runs along the radial side of the index finger. The *fourth* descends towards the cleft between the index and middle fingers, and subdivides into two branches, which supply their opposite sides. The *fifth* is joined by a filament from one of the ulnar digital nerves, and then subdivides above the cleft between the middle and ring fingers, to supply their opposite sides.

Two small branches are given off from the third and fourth digital nerves to supply the two radial lumbricales, the two ulnar being supplied by the ulnar nerve.

About an inch and a quarter (3.1 cm.) above the clefts between the fingers, each

other, the deep, from the trapezoid, os magnum, the bases of the second and third metacarpal bones, and the sheath of the tendon of the flexor carpi radialis. It is *inserted* by two strong tendons into the base of the first phalanx of the thumb; the superficial tendon being connected with the abductor pollicis, and the deep one with the adductor pollicis. A sesamoid bone is found in each of the tendons. The tendons of insertion of this muscle are separated by the long flexor tendon of the thumb and the arteria magna pollicis. Its *action* is to bend the first phalanx of the thumb. The superficial portion is supplied by the median nerve; the deep, by the ulnar (Fig. 128, No. 18, p. 337).

Adductor Pollicis. This triangular muscle *arises* from the palmar aspect of the shaft of the metacarpal bone of the middle finger; its fibres converge and are *inserted*, along with the deep or inner portion of the flexor brevis pollicis, into the base of the first phalanx of the thumb and the internal sesamoid bone. Its *action* is to draw the thumb towards the palm, as when we bring the tips of the thumb and little finger into contact. It is supplied by the deep branch of the ulnar nerve, which also supplies the deep head of the flexor brevis pollicis. The other muscles of the ball of the thumb are supplied by the median nerve (Fig. 128, No. 19, p. 337).

Muscles of the Ball of the Little Finger. The muscles of the little finger correspond in some measure with those of the thumb. Thus there is an abductor, a flexor brevis, and an opponens minimi digiti. All derive their nerves from the deep branch of the ulnar.

Abductor Minimi Digiti. This, the most superficial of the muscles of the little finger, *arises* from the pisiform bone, and from the tendinous expansion of the flexor carpi ulnaris: it is *inserted* by a flat tendon into the inner side of the base of the first phalanx of the little finger. Its *action* is to draw this finger from the others. Its nerve comes from the deep branch of the ulnar.

Flexor Brevis Minimi Digiti. This slender muscle may be considered as a portion of the preceding, to the radial side of which it is situated. It *arises* from the apex of the unciform bone and annular ligament, and is *inserted* with the tendon of the abductor into the base of the first phalanx of the little finger. Its *action* is similar to that of the abductor. Nerve from deep branch of ulnar. Between the origins of the abductor and flexor brevis minimi digiti, the deep branch of the ulnar artery and nerve sinks down to form the deep palmar arch (Fig. 126, No. 23, p. 330).

**Opponens Minimi
Digiti.**

The last two muscles must be reflected from their insertion, to expose the *opponens minimi digiti*. It *arises* from the unciform process and the annular ligament, and is *inserted* along the ulnar side of the shaft of the metacarpal bone of the little finger. Its *action* is to draw this bone, the most moveable of all the metacarpal bones of the fingers, towards the thumb. Thus it greatly strengthens the grasp of the palm. Nerve from deep branch of ulnar (Fig. 128, No. 23, p. 337).

Dissection.

Cut vertically through the anterior annular ligament, and observe that, with the carpal bones, it forms an elliptical canal, with the broad diameter transversely. This canal is lined by a synovial membrane which is reflected loosely over the tendons. Superficial to the ligament pass the palmaris longus, the ulnar artery and nerve, the fibrous expansion from the flexor carpi ulnaris covering these vessels and nerve, and the palmar branch of the median and ulnar nerves; beneath it pass the superficial and deep flexor tendons of the fingers, the long flexor tendon of the thumb, and the median nerve. The tendon of the flexor carpi radialis does not run with the other tendons, but is contained in a distinct sheath, lined by a separate synovial membrane, formed, partly by the annular ligament, and partly by the groove in the trapezium.

**Median Nerve in the
Palm.**

In its passage under the annular ligament, the median nerve is enveloped in a fold of synovial membrane, and lies upon the flexor tendons. Here it becomes enlarged and flattened, and of a pinkish colour, and divides into two nearly equal parts: the *external* gives a recurrent branch to the muscles of the ball of the thumb—namely, to the abductor pollicis, the opponens pollicis, and the outer head of the flexor brevis pollicis, and then terminates in three digital nerves, two of which are distributed to the thumb, and the third to the radial side of the index finger; the *internal* gives digital branches which supply the ulnar side of the forefinger, both sides of the middle finger, and the radial side of the ring finger (Fig. 123, p. 322).

The *two* nerves to the thumb proceed, one on each side of the long flexor tendon, to the last phalanx: the outer one being connected with a terminal filament of the radial.

The *third* digital nerve runs along the radial side of the index finger. The *fourth* descends towards the cleft between the index and middle fingers, and subdivides into two branches, which supply their opposite sides. The *fifth* is joined by a filament from one of the ulnar digital nerves, and then subdivides above the cleft between the middle and ring fingers, to supply their opposite sides.

Two small branches are given off from the third and fourth digital nerves to supply the two radial lumbricales, the two ulnar being supplied by the ulnar nerve.

About an inch and a quarter (*3.1 cm.*) above the clefts between the fingers, each

digital nerve subdivides into two branches, between which the digital artery passes and bifurcates lower down: therefore a vertical incision down the cleft would divide the artery before the nerve.

In their course along the fingers and thumb, the nerves lie superficial to the arteries, and nearer to the flexor tendons. About the base of the first phalanx each nerve sends a *dorsal branch*, which runs along the back of the finger nearly to the extremity, communicating with the dorsal branches derived from the radial and ulnar nerves. Near the unguis phalanx another dorsal or unguis branch is distributed to the skin around and beneath the matrix of the nail. Each digital nerve terminates in the cushion at the end of the finger in a brush of filaments, with their points directed into the papillæ of the skin.

Flexor Tendons and their Sheaths. Immediately below the annular ligament the tendons separate from each other: near the metacarpal joints they pass in pairs, through strong fibrous rings (p. 340) formed by the divisions of the palmar fascia. Below the metacarpal joint the two tendons for each finger enter the sheath, *theca*, which confines them in their course along the phalanges. It is formed by a strong fibrous membrane, which is attached to the ridges on the phalanges, and converts the groove in front of these bones into a complete canal, exactly large enough to contain the tendons. The density of the sheath varies in particular situations, otherwise there would be an obstacle to the easy flexion of the fingers. To ascertain this, cut open one of the sheaths along its entire length; you will then see that it is much stronger between the joints than over the joints themselves. Through these sheaths inflammation, commencing in the integuments of the finger, may readily extend to the synovial membrane of the tendon.

In cases of whitlow, when pus forms in the theca, the incision should be made deep enough to lay open this fibro-osseous canal, without which the incision will be of no use. It is obvious that the incision should be made down the *centre* of the finger, to avoid the digital nerves and arteries. If this opening be not timely made, the flexor tendons are likely to slough, and the finger becomes stiff.*

* On closer inspection it will be observed that the sheath is composed of bands of fibres, which take different directions, and have received distinct names. The strongest are called the *ligamenta vaginalia*. They constitute the sheath over the body of the phalanx, and extend transversely from one side of the bone to the other. The *ligamenta cruciata* are two slips, which cross obliquely over the tendons. The *ligamenta annularia* are situated immediately in front of the joints, and may be considered as thin continuations of the ligamenta vaginalia. They consist of fibres, which are attached on either side to the lateral ligaments of the joints, and pass transversely over the tendons.

But what protects the joints of the fingers where the flexor tendons play over them? Look into an open sheath and you will see that in front of the joints the tendons glide over a smooth fibro-cartilaginous structure called the *palmar* ligament.

To facilitate the play of the tendons the interior of the sheath, as well as the tendons, is lined by a synovial membrane, of the extent of which it is important to have a correct knowledge. With a probe you may ascertain that the synovial membrane is reflected from the sheath upon the tendons, a little above the metacarpal joints of the fingers—that is, nearly in a line with the transverse fold in the skin in the lower third of the palm. Towards the distal end of the finger the synovial sheath stops short of the last joint, so that it is not injured in amputation of the ungual phalanx.

And now notice how the tendons are adapted to each other in their course along the finger. The superficial flexor, near the root of the finger, becomes slightly grooved to receive the deep flexor; about the middle of the first phalanx it splits into two portions, through which the deep flexor passes. The two portions reunite below the deep tendon so as to embrace it, and then divide a second time into two slips, which interlace with each other, and are inserted into the sides of the second phalanx. The *deep* flexor, having passed through the opening of the superficial one, is inserted into the base of the last phalanx (Fig. 128, Nos. 12, 13, P. 337).

In what way are the tendons supplied with blood? Raise and separate the tendons, and you will see that slender but very vascular folds of synovial membrane (*vincula tendinum*) run up from the phalanges and convey blood-vessels to the tendons.

The *tendon of the flexor longus pollicis* lies on the radial side of the other tendons beneath the annular ligament. It passes between the two portions of the flexor brevis pollicis and the two sesamoid bones of the thumb, enters its proper sheath, and is *inserted* into the base of the last phalanx. Its synovial sheath is prolonged from the large bursa of the flexor tendons beneath the annular ligament, and accompanies the tendon down to the last joint of the thumb; consequently the sheath is injured in amputation of the last phalanx.

**Bursal Sac of the
Carpus.**

A large and loose synovial sac (bursa of the carpus) facilitates the play of the tendons beneath the anterior annular ligament. It lines the under surface of the ligament and the groove of the carpus, and is reflected in loose folds over the tendons. It is prolonged up the tendons for an inch and a half or two inches (*3.8 to 5 cm.*), and forms a cul-de-sac above the ligament. Below the ligament the bursa extends into the palm, and sends off prolongations for each

of the flexor tendons, which accompany them down to the middle of the hand. You will understand that when the bursa is inflamed and distended by fluid, there will be a bulging above the annular ligament and another in the palm, with perceptible fluctuation between them, the unyielding ligament causing a constriction in the centre.

Lumbricales.

These four slender muscles, one for each finger, are attached to the deep flexor tendons in the palm. All of them *arise* by fleshy fibres from the radial side and palmar surface of the deep tendon of their corresponding finger; the third and fourth also arise from the adjacent sides of two tendons. Each terminates in a broad, thin tendon, which passes over the radial side of the first joint of the finger and is *inserted*, by a broad expanded aponeurosis, into the extensor tendon on the dorsal aspect of the first phalanx of the finger. Their *action* is to bend the metacarpo-phalangeal joint of the fingers. Being inserted near the centre of motion, they can move the fingers with great rapidity. As they produce the quick motions of the musician's fingers, they were called by the old anatomists *fidicinales* (Fig. 128, No. 15, p. 337).

The two ulnar lumbricales are supplied by the deep branch of the ulnar nerve; the two radial by the third and fourth digital branches of the median nerve.

Dissection.

Now cut through all the flexor tendons, and remove the deep fascia of the palm, to see the deep arch of arteries and its branches.*

Branches of the Radial Artery in the Palm.

The radial artery, sinking into the space between the first and second metacarpal bones, and between the two heads of the abductor indicis, enters the palm between the inner head of the flexor brevis and the adductor pollicis, and gives off three branches—the *arteria princeps pollicis*, the *radialis indicis*, and the *palmaris profunda*, which unites with the deep ulnar artery to form the deep arch.

The *arteria princeps pollicis* runs behind the deep head of the flexor brevis pollicis and in front of the abductor indicis (first dorsal interosseous), close along the metacarpal bone of the thumb; in the interval between the lower portions of the flexor brevis pollicis, the artery divides into two digital branches, which proceed one on either side of the thumb, and inosculate at the apex of the last phalanx. Their distribution and mode of termination are like those of the other digital arteries.

The *arteria radialis indicis* runs between the abductor indicis and adductor pollicis, along the radial side of the index finger to the end, where it forms an

* The course and relations of the radial artery as it winds round the wrist will be described in the dissection of the back of the hand.

arch with the other digital artery, a branch of the ulnar. Near the lower margin of the abductor pollicis, the *radialis indicis* generally receives a branch from the *princeps pollicis*, and gives a branch to the superficial palmar arch.

The *palmaris profunda* may be considered as the continuation of the radial artery. It enters the palm between the inner head of the flexor brevis and the adductor pollicis, and, running upon the bases of the metacarpal bones, inosculates with the deep branch of the ulnar artery, thus completing the *deep palmar arch*. From the concavity of the arch small recurrent branches ascend to supply the bones and joints of the carpus, inosculating with the other carpal arteries.

From the convexity of the arch three or four small branches, called *palmar interosseous* (Fig. 129, p. 341), descend to supply the interosseous muscles, and near the clefts of the fingers communicate with the digital arteries. These palmar interosseous branches are sometimes of considerable size, and take the place of one or more of the digital arteries, ordinarily derived from the superficial palmar arch. Three branches, called *perforating*, pass between the upper ends of the metacarpal bones to the back of the hand, and communicate with the carpal branches of the radial and ulnar.

Deep Branch of the Ulnar Nerve.

This nerve sinks into the palm with the ulnaris profunda artery, between the abductor and flexor brevis minimi digiti. It then runs with the deep palmar arch towards the radial side of the palm, and terminates in the adductor pollicis, in the inner or deep head of the flexor brevis pollicis, and in the first dorsal interosseous. Between the pisiform and unciform bones, the nerve gives a branch to each of the muscles of the little finger. Subsequently it sends branches to each interosseous muscle and to the two inner lumbricales (Fig. 123, No. 32, p. 322).

The tendon of the flexor carpi radialis in the palm must now be followed to its insertion into the base of the second metacarpal bone.

The dissection of the remaining muscles of the palm, called, from their position, *interossei*, must be, for the present, postponed.

MUSCLES OF THE BACK CONNECTED WITH THE ARM.

Make an incision down the middle of the spine from the occiput to the sacrum; another, from the last dorsal vertebra upwards and outwards to the acromion; and a third from the sacrum along the crest of the ilium; then reflect the skin outwards from the dense subcutaneous tissue, in which will be found the following cutaneous nerves:—

Cutaneous Nerves of the Back.

These are derived from the posterior divisions of the spinal nerves, and correspond, generally, to the number of the vertebræ. The posterior primary branches, much smaller than the anterior, divide, between the transverse processes, into *external*

and *internal* branches, with the exception of the suboccipital, the fourth and fifth sacral, and the coccygeal nerves.

**Posterior Branches
of the Cervical
Nerves.**

The *posterior primary branches of the cervical nerves* (except the first*) divide into external and internal branches: the *external* are distributed solely to some of the muscles of the neck, and which will be dissected later on; the *internal*, larger than the external, are distributed in the following manner: the *second*, or the *great occipital nerve*, perforates the complexus and ramifies on the back of the scalp with the occipital artery; the *third*, *fourth*, and *fifth* nerves, after sending branches to the multifidus spinæ, semi-spinalis, and the complexus, emerge through the trapezius close to the spinous processes, and there pass transversely across that muscle to supply the skin over it; the branch of the *third cervical nerve* sometimes sends a branch to the back of the scalp; † the branches of the *sixth*, *seventh*, and *eighth* are small, and are situated beneath the semi-spinalis, to which they are distributed.

**Posterior Branches
of the Dorsal
Nerves.**

The *external branches* become superficial between the longissimus dorsi and the ilio-costalis, and supply these muscles and the other divisions of the erector spinæ; the six lower supply cutaneous nerves in the line of the angles of the ribs. The *internal branches*, as to the upper six dorsal, emerge between the multifidus spinæ and semi-spinalis, and, passing horizontally outwards, end in branches to the skin close to the spinous processes; that from the second ramifies over the spine of the scapula; the six lower do not become cutaneous, but terminate in the multifidus spinæ.

**Posterior Branches
of the Lumbar
Nerves.**

The *external branches* from the first, second, and third lumbar nerves perforate the ilio-costalis and the latissimus dorsi, and then descend over the crest of the ilium, supplying cutaneous branches to the gluteal region; the fourth supplies the erector spinæ without becoming cutaneous; the fifth sends down a branch to communicate with the first sacral nerve. The *internal branches* are small, and end in the multifidus spinæ.

**Posterior Branches
of the Sacral
Nerves.**

The *external branches* of the upper three sacral nerves form a series of loops with themselves, and also with the last lumbar above and the fourth sacral below; they pass to the superficial surface of the great sacro-sciatic ligament, where they form another series of loops, from which filaments are distributed to the skin after piercing the gluteus maximus. The *internal branches* of the three upper sacral nerves are distributed to the multifidus spinæ. The posterior branches of the fourth and fifth sacral nerves do not divide into external and internal branches, but form a loop, the lower one being joined with the coccygeal nerve.

Coccygeal Nerve.

The posterior division of this nerve, after being joined by a branch from the last sacral, is distributed to the posterior aspect of the coccyx.

Dissection.

The trapezius and latissimus dorsi, which form the first layer of muscles, must now be cleaned by putting them on the stretch and reflecting the connective tissue

* This nerve has already been described in the dissection of the suboccipital triangle (p. 279).

† The internal branches of the first, second, and third cervical nerves form a communication beneath the complexus, which is called by Cruveilhier the *posterior cervical plexus*.

a, a, Small occipital nerve from the cervical plexus; *1*, external muscular branches of the first cervical nerve and union by a loop with the second; *2*, the rectus capitis posticus major, with the great occipital nerve passing round the short muscles and piercing the complexus; the external branch is seen to the outside; *3*, the great occipital; *3*, external branch of the posterior primary division of the third nerve; *3'*, its internal branch, or third occipital nerve; *4, 5, 6, 7, 8*, internal branches of the several corresponding nerves on the left side; the external branches of these nerves proceeding to muscles are displayed on the right side: *d 1* to *d 6*, and thence to *d 12*, external muscular branches of the posterior primary divisions of the twelve dorsal nerves on the right side; *d 1'*, to *d 6'*, the internal cutaneous branches of the six upper dorsal nerves on the left side; *d 7*, to *d 12'*, cutaneous branches of the six lower dorsal nerves from the external branches; *l, l*, external branches of the posterior primary branches of several lumbar nerves on the right side piercing the muscles, the lower descending over the gluteal region; *l', l'*, the same more superficially on the left side; *s, s*, on the right side, the issue and union by loops of the posterior primary divisions of four sacral nerves; *s', s'*, some of these distributed to the skin on the left side.

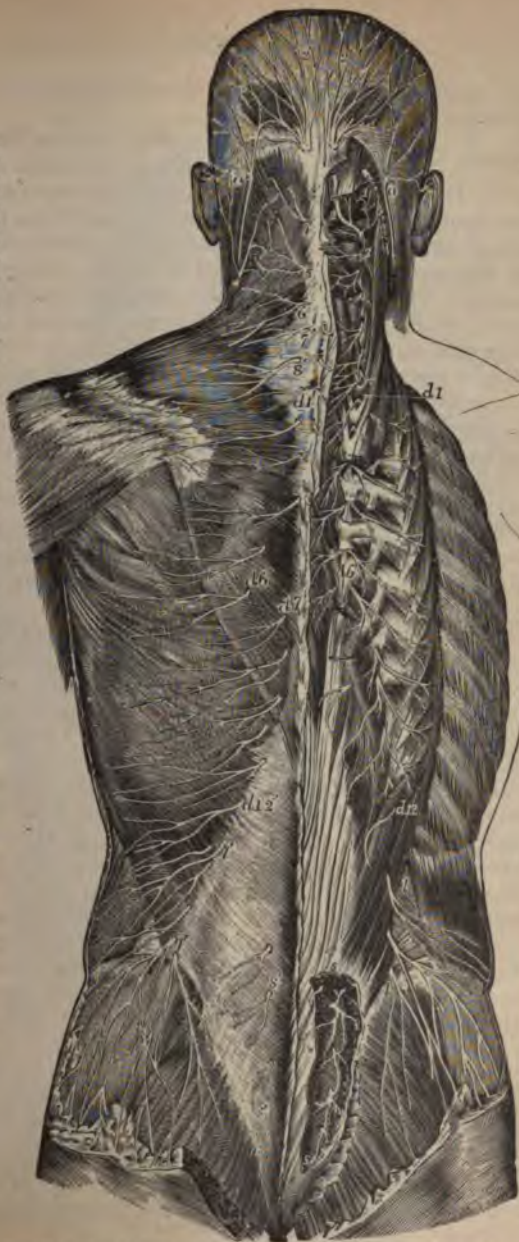

FIG. 130.—DIAGRAM OF THE CUTANEOUS NERVES OF THE BACK. (Quain.)

which covers them ; they should then be dissected in the course of their fibres.

Trapezius.

Alone, this muscle is triangular ; with its fellow, it presents a trapezoid form. It *arises* from the inner fourth, more or less, of the superior curved line of the occiput, from the ligamentum nuchæ,* from the spinous processes of the seventh cervical, and all the dorsal vertebræ, and from their supraspinous ligament. The fibres converge towards the shoulder. The upper pass downwards and outwards, and are *inserted* by fleshy fibres into the external third of the clavicle ; the middle pass transversely outwards into the inner border of the acromion and the superior lip of the spine of the scapula ; the lower pass upwards and outwards, and terminate in a thin tendon, which plays over the triangular surface at the back of the scapula, and is *inserted* into the beginning of the spine. The insertion of the trapezius exactly corresponds to the origin of the deltoid, and the two muscles are connected by a thin aponeurosis over the spine and acromion. If both the trapezius muscles be exposed, observe that, between the sixth cervical and the third dorsal vertebræ, their origin presents an aponeurotic space of an elliptical form (Fig. 131, p. 353).

The structures covered by the trapezius are: the splenius, the complexus, the levator anguli scapulæ, the rhomboidei minor and major, the supraspinatus, a small part of the infraspinatus, the serratus posticus superior, the vertebral aponeurosis, the latissimus dorsi, the ilio-costalis, the spinal accessory nerve, and the superficialis colli artery.

The fixed point of the muscle being at the vertebral column, all its fibres tend to raise the shoulder. The deltoid cannot raise the humerus beyond an angle of ninety degrees: beyond this, the elevation of the arm is principally effected by the rotatory movement of the scapula. The trapezius is in strong action when a weight is borne upon the shoulders; again, its middle and inferior fibres act powerfully in drawing the scapula backwards, as in preparing to strike a blow. If both muscles act, they draw the head backwards; if one only acts, it draws the head to the same side. It is supplied by the nervus accessorius and the deep branches of the cervical plexus, and by the superficialis colli artery.

* The ligamentum nuchæ is, in man, only a rudiment of the great elastic ligament which supports the weight of the head in quadrupeds. It extends from the spine of the occiput to the spines of all the cervical vertebræ, except the atlas; otherwise it would impede the free rotation of the head. In the giraffe this ligament is six feet long and as thick as a man's forearm. Professor Quekett states that when divided it shrinks at least two feet.

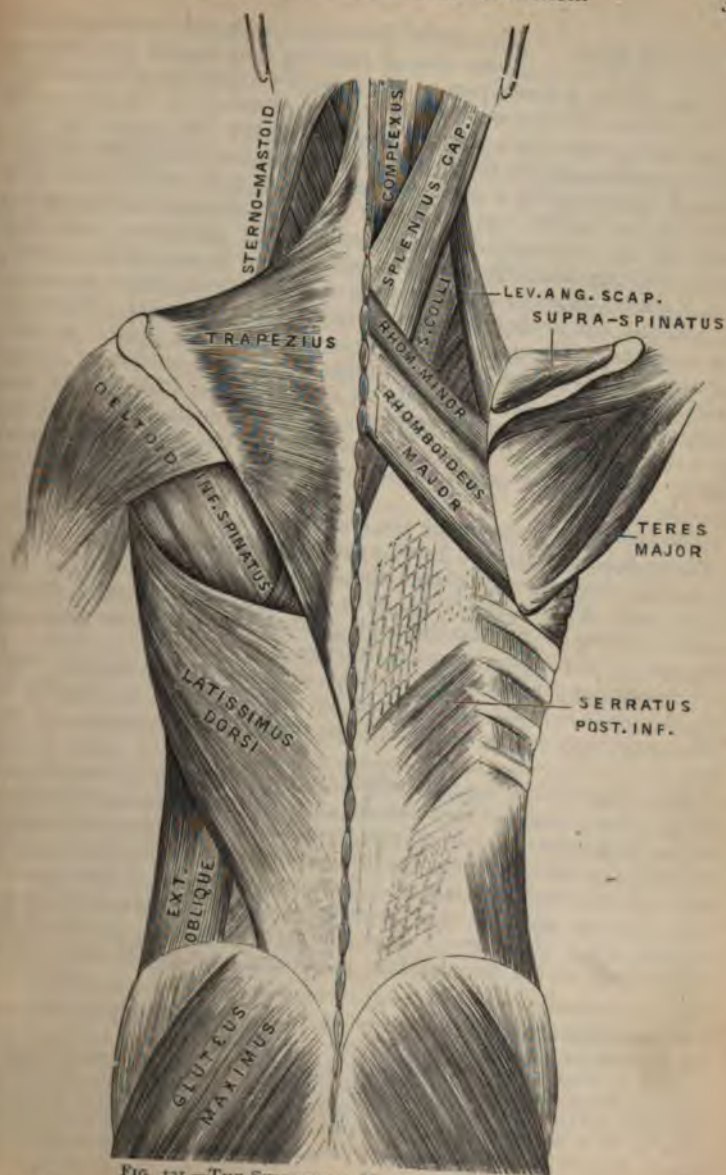


FIG. 131.—THE SUPERFICIAL MUSCLES OF THE BACK.

Latissimus Dorsi. This broad flat muscle occupies the lumbar and lower dorsal regions, and thence extends to the arm, where it forms part of the posterior boundary of the axilla. It *arises* from the posterior third of the external lip of the crest of the ilium, from the spinous processes of the two upper sacral, all the lumbar and the six lower dorsal vertebræ, and their supraspinous ligament, by a strong aponeurosis; and, lastly, from the three or four lower ribs by fleshy slips, which interdigitate with those of the external oblique muscle of the abdomen. All the fibres converge towards the axilla, where they form a thick muscle, which curves over the inferior angle of the scapula, and is *inserted* by a broad, flat tendon into the bottom of the bicipital groove of the humerus. The upper fibres are inserted into the lowest of the groove, the lower fibres into the upper part. The tendon is about two inches broad, and lies in front of and higher than that of the pectoralis major and of the teres major, from which it is separated by a large *bursa*.* It is supplied mainly by the long subscapular nerve, also by the posterior branches of the dorsal and lumbar nerves.

The latissimus dorsi draws the humerus inwards and backwards, rotating it also inwards. It co-operates with the pectoralis major in pulling any object towards the body; if the humerus be the fixed point, it raises the body, as in climbing. The object of the muscle arising so high up the back is, that the transverse fibres of the muscle may strap down the inferior angle of the scapula. It sometimes happens that the scapula slips above the muscle; this displacement is readily recognised by the unnatural projection of the lower angle of the bone, and the impaired movements of the arm.†

The muscle covering the latissimus dorsi is the trapezius above; those lying beneath it are, a small part of the rhomboideus major, of the infraspinatus, and of the teres major, the serratus posticus inferior, the spinalis dorsi, the longissimus dorsi, the ilio-costalis, and the external intercostals. Between the base of the scapula, the trapezius, and the upper border of the latissimus dorsi, a triangular space is observed when the arm is raised, in which the lower fibres of the rhomboideus major and part of the sixth inter-

* The latissimus dorsi frequently receives a distinct accessory slip from the inferior angle of the scapula.

† We have seen several instances of this displacement. There is great projection of the inferior angle of the scapula, especially when the patient attempts to raise the arm. He cannot raise the arm beyond a right angle, unless firm pressure is made on the lower angle of the scapula, so as to supply the place of the muscular strap. Whether the scapula can be replaced or not, a firm bandage should be applied round the chest.

costal space are exposed. Immediately above the crest of the ilium, between the free margins of the latissimus dorsi and external oblique, there is, also, an interval in which a little of the internal oblique can be seen.

Lumbar or Vertebral Aponeurosis.

This dense shining aponeurosis of the back (sometimes termed the aponeurosis of the latissimus dorsi) forms the posterior part of the sheath of the erector spinæ. It is pointed above, where it is continuous with the deep cervical fascia, broader and stronger below. It consists of tendinous fibres, which are attached internally to the spines of the dorsal, all the lumbar and sacral vertebræ; externally, to the angles of the ribs; and inferiorly it is blended with the tendons of the serratus posticus inferior and latissimus dorsi. When suppuration takes place in the loins, constituting a lumbar abscess in connection with spinal disease, the pus is seated beneath this aponeurosis, and is therefore tardy in coming to the surface.

Dissection.

Reflect the trapezius from its insertion. On its under surface see the ramifications of its nutrient artery, the *superficialis colli*, a branch of the posterior scapular. A large nerve, the *spinal accessory*, enters its under surface near the clavicle, and divides into filaments, which, reinforced by filaments from the third and fourth cervical nerves, are distributed to the muscle as far as its lower border.

Spinal Accessory Nerve.

This nerve, the eleventh cerebral nerve, arises by two roots—the accessory and the spinal portions: the former from the medulla oblongata, the latter from the spinal cord. The *accessory portion*, the smaller, arises by four or five filaments from a grey nucleus in the floor of the fourth ventricle, below the origin of the pneumogastric nerve; the *spinal portion* arises from the lateral part of the cervical portion of the spinal cord by several filaments, some of which arise as low as the sixth cervical vertebra, and which may be traced into the grey matter of the anterior horn. Formed by the union of these roots, the nerve enters the skull through the foramen magnum, and leaves it again, with the accessory portion, through the foramen jugulare. These portions communicate external to the skull; but while the accessory root joins the vagus, the spinal portion, in the main, runs behind the internal jugular vein, traverses obliquely the upper third of the sterno-mastoid muscle, and crosses the posterior angle of the neck to the trapezius, which it supplies (p. 91). In front of the trapezius it is joined by branches from the third, fourth, and fifth cervical nerves, together with which it communicates with the posterior branches of the spinal nerves.

The trapezius should now be cut through the middle, and the

inner half turned inwards towards the spine, the outer half over the clavicle and the spine of the scapula.

Beneath the trapezius we have to examine the second layer, consisting of three muscles connected with the scapula; namely, the levator anguli scapulæ, the rhomboideus major and minor. The scapula should be adjusted so as to stretch their fibres.

**Levator Anguli
Scapulæ.**

This muscle is situated at the back and side of the neck. It *arises* by four tendons from the posterior tubercles of the transverse processes of the four upper cervical vertebræ. The muscular slips to which the tendons give rise form a single muscle, which descends outwards along the side of the neck, and is *inserted* into the posterior border of the scapula between its spine and superior angle. Its *action* is to raise the posterior angle of the scapula; as, for instance, in shrugging the shoulders. Its nerve comes from the fifth cervical, and by filaments from the external series of the deep cervical plexus, which come from the third and fourth cervical nerves.

**Rhomboideus Major
and Minor.**

These flat muscles extend from the spinous processes of the vertebræ to the base of the scapula. They often appear like a single muscle. The rhomboideus minor, the higher of the two, *arises* by a thin aponeurosis from the spinous processes of the last cervical and the first dorsal vertebræ, and is *inserted* into the base of the scapula opposite its spine. The rhomboideus major *arises* by tendinous fibres from the spinous processes of the four or five upper dorsal vertebræ and the supraspinous ligament, and is *inserted* by fleshy fibres into the base of the scapula between its spine and inferior angle, the larger number of the fibres being inserted into a tendinous arch, which is chiefly attached to the inferior angle. The *action* of these muscles is to draw the scapula upwards and backwards. They are the antagonists of the serratus magnus.

The *nerve of the rhomboid muscles* (posterior scapular) is a branch of the fifth cervical. It passes outwards beneath the lower part of the levator anguli scapulæ, to which it sends a branch, and is lost in the under surface of the rhomboidei.

Omo-hyoideus.

This muscle extends from the scapula to the os hyoides, and consists of two long narrow muscular portions, connected by an intermediate tendon beneath the sterno-mastoid. The posterior portion only can be seen in the present dissection. It *arises* from the upper border of the scapula, close behind the notch, and from the transverse ligament above the notch. Thence the slender muscle passes forwards across the lower part of the neck, beneath the sterno-mastoid, where it changes its direction and ascends nearly vertically, to be attached to the os hyoides at the junction of the body with the greater cornu (Fig. 37, p. 97).

Thus the two portions of the muscle form, beneath the sterno-mastoid, an obtuse angle, of which the apex is tendinous, and of which the angular direction is maintained by a layer of fascia, proceeding from the tendon to the first rib and the clavicle. Its *action* is to depress the os hyoides. Its nerve comes from the *descendens noni* and the *communicantes noni* (p. 125).

Subscapular Artery. This artery (*transversalis humeri*), a branch of the thyroïd axis (Fig. 49, No. 12, p. 134), runs behind and parallel with the clavicle, over the lower end of the scalenus anticus and subclavian artery, and beneath the sterno-mastoid and omo-hyoid muscles, to the upper border of the scapula, where it usually passes above the ligament bridging over the notch. It ramifies in the supraspinous fossa, supplying the supraspinatus, and then passes under the acromion to the infraspinous fossa, where it inosculates freely with the *dorsalis scapulæ*, a branch of the subscapular. It sends off:—

a, The *inferior sterno-mastoid* artery to the sterno-mastoid and contiguous muscles; *b*, the *supra-acromial* branch, which ramifies upon the acromion, anastomosing with the other acromial arteries derived from branches of the axillary; *c*, a small *subscapular* branch to the fossa of the same name; *d*, *articular* arteries to the shoulder-joint; and, lastly, *e*, the *infraspinous* branch, which anastomoses with the *dorsalis scapulæ*. The suprascapular vein terminates either in the subclavian or in the external jugular.

The *suprascapular nerve*, a branch of the fifth and sixth cervical nerves, runs with the corresponding artery, and, after passing through the suprascapular notch, is distributed to the supraspinatus and infraspinatus. In the supraspinous fossa, this nerve sends a small *articular* branch to the shoulder-joint; in the infraspinous fossa it gives off two branches to the infraspinatus, and some to the shoulder-joint.

Posterior Scapular Artery.

This artery is one of the divisions of the *transversalis colli*, but comes very frequently from the subclavian in the third part of its course (p. 136). It runs across the lower part of the neck, above, or between the nerves of the brachial plexus, towards the posterior superior angle of the scapula. Here it pursues its course along the posterior border of the scapula beneath the *levator anguli scapulæ* and the *rhomboidei*, anastomosing with branches of the *suprascapular* and *subscapular* arteries, and with branches from the *intercostal* arteries. The corresponding vein joins the external jugular or the subclavian.

Dissection.

Divide the rhomboid muscles near their insertion, and trace the artery to the inferior angle of the scapula, where it terminates in the *rhomboidei*, *serratus magnus*, and *latissimus dorsi*.

Numerous muscular branches arise from the posterior scapular. The *superficialis colli* (the other division of the *transversalis colli*)

is given off near the upper angle of the scapula for the supply of the trapezius, which it enters together with the spinal accessory nerve.

Divide and reflect the latissimus dorsi below the inferior angle of the scapula, and draw the scapula forcibly outwards, to have a more perfect view of the extent of the serratus magnus than was seen in the axilla. The abundance of connective tissue in this situation is necessary for the play of the scapula on the chest.

Serratus Magnus. This broad, thin, flat muscle intervenes between the scapula and the ribs. It *arises* by nine fleshy digitations from the eight upper ribs, each rib giving origin to one, and the second to two, and from the fascia covering the corresponding intercostal spaces. The four lower digitations correspond with those of the external oblique muscle of the abdomen. The fibres pass backwards and outwards and are arranged in three fasciculi; the upper portion *arises* from the first and second ribs and the fascia between them, and is *inserted* into the triangular surface in front of the upper angle of the scapula; the middle portion *arises* from the second, third, and fourth ribs, and is *inserted* into the inner lip of the vertebral border between the first and third portions; the third portion *arises* from the fifth, sixth, seventh, and eighth ribs, and is *inserted* into the smooth surface in front of the inferior angle; this last portion consists of four serrations, and are those which interdigitate with the external oblique.

This is the most important of the muscles which regulate the movements of the scapula. It draws the scapula forwards, and thus gives additional reach to the arm; it counteracts all forces which tend to push the scapula backwards; for instance, when a man falls forwards upon his hands, the serratus magnus sustains the shock and prevents the scapula from being driven back to the spine. Supposing the fixed point to be at the scapula, some anatomists ascribe to it the power of raising the ribs; hence Sir Charles Bell called it the external respiratory muscle, the internal respiratory muscle being the diaphragm.

The nerve which supplies it is a branch of the fifth and sixth cervical nerve; it descends along its outer surface, distributing a filament to each digitation of the muscle (p. 140).

Dissection. Divide the serratus magnus near the scapula, and remove the arm by sawing through the middle of the clavicle, cutting through the axillary vessels and nerves. These should be tied to the coracoid process. After the removal of the arm examine the precise insertions of the preceding muscles.

DISSECTION OF THE MUSCLES OF THE SHOULDER.

The remainder of the skin over the shoulder is to be reflected, and in the subcutaneous tissue are found the cutaneous vessels and nerves. Some pass down over

the shoulder, others ascend over the deltoid, emerging from beneath its lower border.

The *acromial branches* come from the third and fourth cervical nerves, and descend over the acromion (Fig. 132) in front of and behind the deltoid. The *cutaneous branch* of the *circumflex* nerve comes out beneath the posterior border of the deltoid and supplies the skin over the posterior and outer two-thirds of the muscle; others perforate the muscle, each accompanied by a small artery.

Notice the strong layer of fascia upon the surface of the deltoid, which extends from the aponeurosis covering the muscles on the back of the scapula, and is continuous with the fascia of the arm. It dips down between the fibres of the muscle, dividing it into large bundles. This fascia is to be removed by putting the deltoid on the stretch and reflecting it in the direction of its fibres, beginning from the front. The fascia will be seen to be continuous in front with the fascia covering the pectoralis major; above, it is attached to the clavicle and spine of the scapula; behind, it is continuous with that over the infraspinatus.

Deltoid.

The large muscle which covers the shoulder-joint is named deltoid from its resemblance to the Greek Δ reversed. It *arises* from the external third of the anterior border of the clavicle, from the apex and outer border of the acromion, and from the lower border of the spine of the scapula down to the triangular surface at its root. This origin, which corresponds to the insertion of the trapezius, is tendinous and fleshy everywhere, except at the commencement of the spine of the scapula, where it is simply tendinous, and connected with the infraspinous aponeurosis. The muscular fibres descend, the anterior backwards, the posterior forwards, the middle perpendicularly; all converge

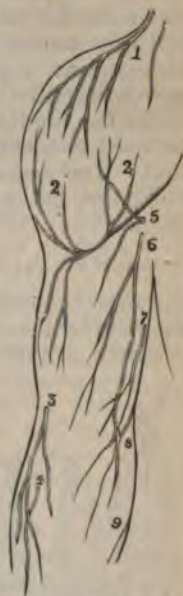

FIG. 132.—CUTANEOUS NERVES OF THE LEFT SHOULDER AND ARM (POSTERIOR VIEW).

1. Supra-acromial br. of the cervical nerves.
2. Ascending and descending brs. of the circumflex n.
- 3, 4. Cutaneous brs. of the musculocutaneous n.
5. Internal cutaneous br. of musculospiral n.
6. Intercosto-humeral brs.
7. Filaments of the lesser internal cutaneous n.
8. Posterior cutaneous br. of internal cutaneous n.
9. Branch of internal cutaneous n.

to a tendon which is *inserted* into a rough surface on the outer side of the humerus, a little above the middle of the shaft (Figs. 117 and 124, pp. 309, 323). The insertion of the tendon extends one inch and a half (3.8 cm.) along the humerus, and terminates in a V-shaped form, the origin of the brachialis anticus embracing it on either side. Sometimes a few fibres of the pectoralis major are connected with its front border.

The muscular bundles composing the deltoid have a peculiar arrangement, a peculiarity arising from its broad origin and its narrow insertion. It consists in the interposition of tendons between the bundles for the attachment of the muscular fibres. The annexed woodcut shows this arrangement better than any description. The action of the muscle is not only concentrated upon one point, but its power is also greatly increased by this arrangement.

Action of the Deltoid. It raises the arm; but it cannot do so beyond an angle of ninety degrees. The elevation of the arm beyond this angle is effected through the raising of the shoulder by the trapezius and serratus magnus. Its anterior fibres draw the arm forwards; its posterior, backwards.



FIG. 133.—ANALYSIS OF THE DELTOID.

This powerful muscle is supplied with blood by the anterior and posterior circumflex, the thoracica humeraria, the thoracica acromialis, all from the axillary artery; also by the deltoid branch of the brachial. Its nerve is the circumflex.

The rotundity of the shoulder is due not so much to the deltoid as to the upper end of the humerus. When the head of the humerus is dislocated into the axilla, the fibres of the muscle run vertically to their insertion; hence the flattening of the deltoid and the greater prominence of the acromion.

It is below the deltoid that an ununited fracture of the humerus is most commonly met with,

owing to the muscle displacing the upper fragment.

Dissection. Reflect the deltoid from its origin, and turn it downwards. Observe the ramifications of the circumflex nerve and the anterior and posterior circumflex arteries

on its under surface ; notice also the large bursa between it and the tendons inserted into the great tuberosity of the humerus.

Parts Covered by the Deltoid. The structures seen on reflecting the deltoid are as follows: the bursa already alluded to, the coracoid process, the coraco-acromial ligament, the origins of the biceps, and coraco-brachialis, the insertions of the pectoralis minor and major, the long head of the biceps, the insertions of the supra-spinatus, infraspinatus, and teres minor, the long and external heads of the triceps, the circumflex vessels and nerve, and the neck and upper part of the humerus.

Bursa under the Deltoid, or Sub-acromial. The large bursa under the deltoid extends for some distance beneath the acromion and the coraco-acromial ligament, and covers the tendons attached to the great tuberosity of the humerus. It communicates, very rarely, with the shoulder-joint. Its use is to facilitate the movements of the head of the bone under the acromial arch.

Posterior Circumflex Artery. This artery is given off from the axillary in the third part of its course ; it runs behind the surgical neck of the humerus, through a quadrilateral opening, bounded above by the subscapularis and teres minor ; below, by the teres major ; externally, by the neck of the humerus ; and internally, by the long head of the triceps (p. 305). Its branches terminate on the under surface of the deltoid, anastomosing with the anterior circumflex, acromial thoracic, and supra-scapular arteries.

From the posterior circumflex a branch descends in the substance of the long head of the triceps, to inosculate with the superior profunda ; this is one of the channels through which the circulation would be carried on if the axillary were tied in the last part of its course.

Circumflex Nerve. This nerve, a branch of the posterior cord of the axillary plexus, runs with the posterior circumflex artery through the same quadrilateral space, and then divides into two branches—an upper and a lower. The *upper branch* winds round the neck of the humerus and supplies the anterior part of the deltoid, and gives off cutaneous branches to supply the skin over its lower part. The *lower branch* sends a filament to the teres minor, one or two to the integuments over the shoulder at its posterior part, and terminates in the substance of the deltoid. It also distributes an *articular* filament, which enters the shoulder-joint in front, below the subscapularis.

The proximity of this nerve to the head of the humerus explains the occasional paralysis of the deltoid, after dislocation or

fracture of the humerus. The nerve is liable to be injured, actually lacerated, by the pressure of the bone.

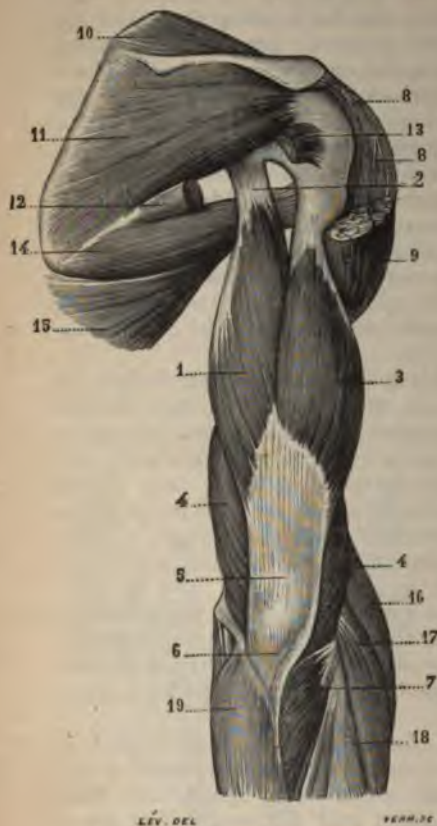

FIG. 134.—TRICEPS MUSCLE.

1. Triceps. 2. Long head of the triceps. 3. Outer head. 4. Inner head. 5. Tendon of the triceps. 6. Its attachment to the olecranon. 7. Anconeus, the fibres of which follow those of the outer head of the triceps. 8, 8. Superior part of the deltoid; the posterior half has been excised. 9. Its inferior part. 10. Supra-spinatus. 11. Infra-spinatus. 12. Origin of the teres minor. 13. Insertion of the teres minor. 14. Teres major. 15. Superior extremity of the latissimus dorsi. 16. Supinator longus or brachio-radialis. 17. Extensor carpi radialis longior. 18. Extensor carpi ulnaris. 19. Flexor carpi ulnaris.

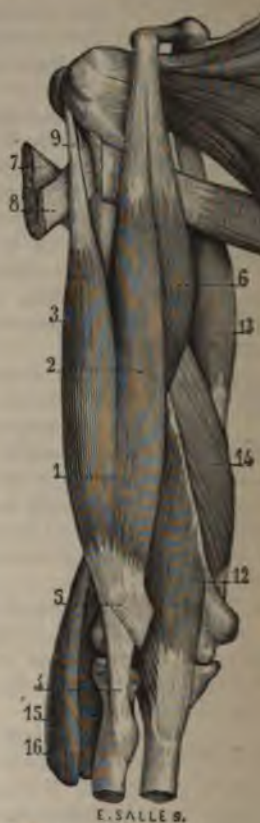

FIG. 135.—ANTERIOR MUSCLES.

1. Biceps. 2. Short-head of biceps. 3. Long-head of the same. 4. Tuberosity of the radius. 5. Fascial aponeurosis of the biceps brachialis. 6. Brachialis major. 7, 8. The two portions of the brachialis major forming a groove above. 9. Attachment of the biceps to the radial tuberosity. 10. Teres major. 11. Brachialis minor. 12. Brachialis anticus. 13. Coracoid process. 14. Internal head of the biceps. 15. Supinator longus or brachio-radialis. 16. Extensor carpi radialis longior.

A strong aponeurosis covers the muscles of the dorsum of the scapula, and is firmly attached to the spine and borders of the bone. At the posterior edge of the deltoid it divides into two layers, one of which passes over, the other under, the muscle. Remove the aponeurosis, so far as it can be done without injury to the muscular fibres which arise from its under surface.

Infra-spinatus. This triangular muscle *arises* by fleshy fibers from the posterior two-thirds of the infraspinous fossa, by tendinous fibres from the ridges on the fossa, and from the aponeurosis which covers it. The fibres converge to a tendon, which is at first contained in the substance of the muscle, and then proceeds over the capsular ligament of the shoulder-joint, to be *inserted* into the middle depression on the greater tuberosity of the humerus. Its nerve comes from the suprascapular.

Teres Minor. This long, narrow muscle is situated below the infraspinatus, along the inferior border of the scapula. It *arises* from the dorsum of the scapula close to the inferior border, and from the intermuscular septa between it and the infraspinatus above and the teres major below. The fibres ascend outwards parallel with those of the infraspinatus, and terminate in a tendon, which passes over the capsular ligament of the shoulder-joint, and is *inserted* into the lowest depression on the great tuberosity of the humerus, and by muscular fibres into the bone below it. It is supplied by a branch of the circumflex nerve, which enters the muscle at its lower border, and it has (usually) a small ganglion-like enlargement upon it.

The *action* of the infraspinatus and teres minor is to rotate the humerus outwards, and when the arm is raised it draws the humerus downwards and backwards.

Teres Major. This muscle is closely connected with the latissimus dorsi, and extends from the inferior angle of the scapula to the humerus, contributing to form the posterior boundary of the axilla. It *arises* from the flat surface on the dorsal aspect of the inferior angle of the back of the scapula, from its inferior border, and the intermuscular septa, and terminates upon a flat tendon, nearly two inches (5 cm.) in breadth, which is *inserted* into the inner edge of the bicipital groove of the humerus, behind and a little lower than the tendon of the latissimus dorsi. Its *action* is to draw the humerus backwards and downwards when the arm is raised, and to rotate it slightly inwards. It is supplied by the middle subscapular nerve, which enters it on its axillary aspect.

A bursa is found in front of, and another behind, the tendon of the teres major; the former separates it from the latissimus dorsi, the latter from the bone.

Supra-spinatus. This muscle *arises* from the posterior two-thirds of the supraspinous fossa, and from its aponeurotic covering. It passes under the acromion, over the capsular ligament of the shoulder-joint, and is *inserted* by a strong tendon into the superior depression on the greater tuberosity of the humerus. To see its insertion, the acromion should be sawn off near the neck of the scapula. Its *action* is to assist the deltoid in raising the arm. It is supplied by two branches derived from the suprascapular nerve.

Subscapularis. This triangular fleshy muscle occupies the subscapular fossa. It *arises* from the posterior three-fourths of the fossa, except the posterior border and angles which give attachment to the serratus magnus, and from three or four tendinous septa attached to the oblique bony ridges on its surface. The fibres, passing upwards and outwards, converge towards the neck of the scapula, where they terminate upon three or four tendons, which are concealed amongst the muscular fibres, and are *inserted* into the lesser tuberosity of the humerus and into the bone for an inch below the tuberosity. Its broad insertion is closely connected with the capsule of the shoulder-joint, which it completely protects upon its inner side. Its *action* is to rotate the humerus inwards, and, when the arm is raised, draws it downwards. The nerves which supply it come from the long and middle subscapular nerves.

The coracoid process, with the coraco-brachialis and short head of the biceps, forms an arch, under which the tendon of the subscapularis plays. There are several *bursæ* about the tendon. One, of considerable size, on the upper surface of the tendon, facilitates its motion beneath the coracoid process and the coraco-brachialis; this sometimes communicates with the large bursa under the deltoid. Another is situated between the tendon and the capsule of the joint, and almost invariably communicates with it.

Dissection. Now reflect the muscles from the surfaces of the scapula, to trace the arteries which ramify upon it.

This artery, a branch of the thyroid axis, runs under and parallel with the clavicle, and passes above the notch of the scapula into the supraspinous fossa; it sends a branch to the supraspinatus, another to the shoulder-joint, and then descends behind the neck of the scapula into the fossa below the spine, where it inosculates directly with the dorsalis scapulæ. Its branches ramify upon the bone, and supply the infraspinatus and teres minor (Fig. 136).

The suprascapular nerve passes most frequently through the

notch of the scapula, accompanies the corresponding artery, supplies two branches to the supraspinatus and one to the shoulder-joint; it then enters the infraspinous fossa, to terminate in the infraspinatus.

**Dorsalis Scapulæ
Artery.**

This artery, after passing through the triangular space (p. 304), curves round the inferior border of the scapula, which it grooves, to the infraspinous fossa, where it ascends close to the bone, and anas-

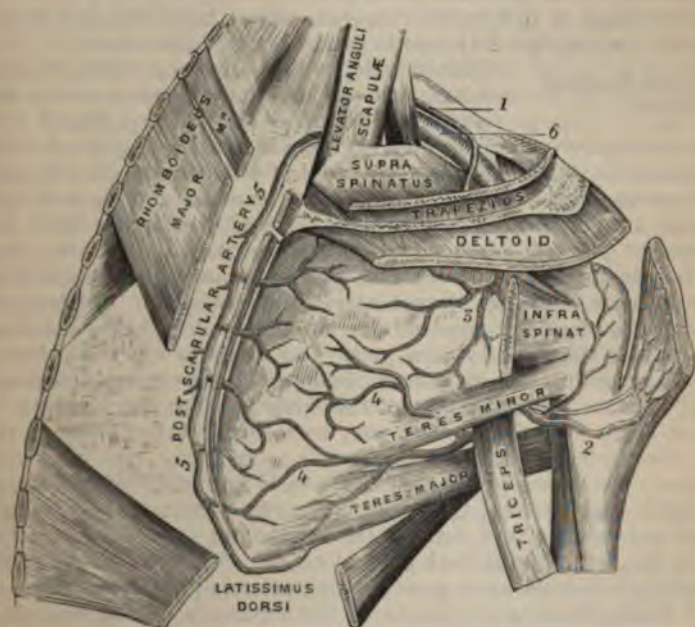


FIG. 136.—DIAGRAM OF ARTERIES OF SCAPULA.

1. Suprascapular artery. 2. Posterior circumflex a. 3. Infraspinous br. of suprascapular a.
4. Dorsalis scapulæ a. 5. Posterior scapular a. 6. Subclavian a.

tomoses with the supra- and posterior scapular arteries. Another branch of the subscapular artery runs between the teres minor and major towards the inferior angle of the scapula, where it anastomoses with the posterior scapular artery (Fig. 136).

The several communications above the scapula, between the branches of the subclavian and axillary arteries, would furnish a large collateral supply of blood to the arm, if the subclavian were tied above the clavicle (p. 137).

Dissection.

If the skin has not been reflected from the back of the arm it should now be done. In the subcutaneous tissue will be seen the *internal cutaneous branch* of the *musculo-spiral* nerve, which supplies the skin as low down as the olecranon. On the inner side of this branch is the *intercosto-humeral nerve*, supplying the skin as far as the lower third of the arm. The *nerve of Wrisberg* also supplies the lower third of the arm; and on the outer side for the same distance is the *external cutaneous branch* of the *musculo-spiral* nerve.

The fascia is now to be removed, when the triceps will be exposed, forming the only muscle on the back of the arm.

**Triceps Extensor
Cubiti.**

This muscle, which arises by three distinct heads, and was only partially seen in the dissection of the upper arm (p. 323), should now be thoroughly examined (Fig. 134, p. 362). The *long head* arises immediately below the glenoid cavity of the scapula, by a strong, flat tendon, which is connected with the capsular and glenoid ligaments of the shoulder-joint. The *external head* arises from the posterior part of the humerus, below the insertion of the *teres minor*, as far as the musculo-spiral groove, from the outer border of the humerus, and the external intermuscular septum. The *internal head* arises from the posterior part of the humerus, below the *teres major* and the musculo-spiral groove, as far as the olecranon fossa; it has an additional origin from the internal intermuscular septum, and from the internal border of the humerus. The precise origin of these heads from the humerus may be ascertained by following the superior profunda artery and musculo-spiral nerve, which separate them. The three portions of the muscle terminate upon a broad tendon, which covers the back of the elbow-joint, and is inserted into the summit and sides of the olecranon; it is also connected with the fascia on the back of the forearm. The effect of this connection is that the same muscle which extends the forearm tightens the fascia which gives origin to the extensors of the wrist and fingers. The same holds good in the case of the biceps, and its semilunar expansion in the fascia of the forearm.

Between the tendon and the olecranon is a *bursa*, commonly of small size, but sometimes so large as to extend upwards behind the capsule of the joint. This bursa must not be mistaken for the subcutaneous one, which is situated between the skin and the olecranon, and is so often injured by a fall on the elbow.

Dissection.

By dividing the triceps transversely a little above the elbow, and turning down the lower portion, it will be seen that some of the muscular fibres terminate upon the capsular ligament of the joint. They have been described as a distinct muscle, under the name of the *subanconeus*; their

use is to draw up the capsule so that it may not be injured during extension of the arm. The subanconeus is, in this respect, analogous to the subcrureus muscle of the thigh. Observe the *bursa* under the tendon, and the arterial arch formed upon the back part of the capsule by the superior profunda and the anastomotica magna (Fig. 139, p. 376).

Trace the continuation of the superior profunda artery (p. 318) and musculo-spiral nerve round the posterior part of the humerus. They lie in a slight groove on the bone,* between the external and internal heads of the triceps, and are protected by an aponeurotic arch thrown over them by the external head of the triceps. After supplying the muscles, the artery continues its course along the outer side of the arm between the brachialis anticus and supinator radii longus, and inosculates with the radial recurrent. It gives off a branch, which runs down between the triceps and the bone, and inosculates, at the back of the elbow, with the anastomotica magna and posterior interosseous recurrent. The musculo-spiral nerve which accompanies the artery sends branches to supply the three portions of the triceps, the supinator radii longus or brachio-radialis, and extensor carpi radialis longior.† It then divides into the posterior interosseous and radial nerves. The small nerve must be made out which runs down in the substance of the triceps, accompanied by a branch from the superior profunda artery, to supply the anconeus. The cutaneous branches of the musculo-spiral nerve have been already dissected (p. 312).

DISSECTION OF THE BACK OF THE FOREARM.

Remove the skin from the back of the forearm, hand, and fingers, and make out the subcutaneous *bursa* over the olecranon. It is of considerable size, and, if distended, would appear nearly as large as a walnut. Another *bursa* is sometimes found a little lower down upon the ulna. A subcutaneous *bursa* is generally placed over the internal condyle, another over the external. A *bursa* is also situated over the styloid process of the ulna; this sometimes communicates with the sheath of the extensor carpi ulnaris. Small *bursæ* are sometimes developed in the cellular tissue over each of the knuckles.

The cutaneous veins from the back of the hand and forearm join the venous plexus at the bend of the elbow (see p. 312).

*It is worth remembering that the nerve may be injured by a fracture of the humerus in this situation, and even by too tight bandaging; the result being paralysis of the extensor muscles of the forearm.

†The brachialis anticus usually receives a branch from the musculo-spiral nerve.

Cutaneous Nerves of the Back of the Forearm. The cutaneous nerves of the back of the forearm are derived from the external cutaneous branches of the musculo-spiral, from branches of the internal cutaneous, and of the external

cutaneous nerves. The greater number of these nerves may be traced down to the back of the wrist.

Nerves on the Back of the Hand and Fingers.

The skin on the back of the hand is united to the subjacent tendons by an abundance of loose connective tissue, in which are large veins, and branches of the radial and ulnar nerves. The *dorsal branch* of the ulnar nerve passes beneath the tendon of the flexor carpi ulnaris, pierces the fascia just above the wrist-joint, runs over the posterior annular ligament of the wrist, and divides upon the back of the hand into filaments, which supply both sides of the back of the little finger, the ring finger, and the ulnar side of the middle finger. The *radial nerve* passes obliquely beneath the tendon of the supinator longus, perforates the fascia about two inches (5 cm.) above the wrist-joint, and subdivides into filaments, which supply both sides of the back of the thumb and forefinger, and the radial side of the middle finger.* (Fig. 127, p. 353).

The radial nerve commonly gives off, on the back of the hand, a branch which joins the nearest branch of the ulnar.

Fascia on Back of Forearm.

The fascia on the back of the forearm is composed of fibres interlacing and stronger than that upon the front of the forearm. It is attached to the condyles of the humerus and to the olecranon, and is strengthened by an expansion from the tendon of the triceps. Along the forearm it is attached to the ridge on the posterior part of the ulna. Its upper third gives origin to the fibres of the muscles beneath it, and divides them by septa, to which their fibres are also attached.

Posterior Annular Ligament.

This ligament should be considered as a part of the fascia of the forearm, specially strengthened by oblique aponeurotic fibres on the back of the wrist, to confine the extensor tendons. These fibres are attached to the outer margin of the radius, and thence pass obliquely inwards to the inner side of the wrist, where they are connected with the pisiform and cuneiform bones. They pass below the

* The relative share which the radial and ulnar nerves take in supplying the fingers varies. Under any arrangement the thumb and each finger has two dorsal nerves, one on either side, of which the terminal branches reach the root of the nail. They supply filaments to the skin on the back of the finger, and have frequent communications with the palmar digital nerves. In some instances one or more of the dorsal nerves do not extend beyond the first phalanx; their place is then supplied by a branch from the palmar nerve.

styloid process of the ulna, to which they are in no way attached, otherwise the rotation of the radius would be impeded.

**Separate Sheaths
for Extensor
Tendons.**

From the deep surface of the posterior annular ligament, processes are attached to the ridges on the back of the radius, so as to form six distinct fibro-osseous sheaths for the passage of the extensor tendons. Commencing from the radius, the first sheath contains the tendons of the extensor ossis metacarpi and the extensor primi internodii pollicis; the second, the tendons of the extensor carpi radialis longior and brevior; the third, the tendon of the extensor secundi internodii pollicis; the fourth, the tendons of the extensor indicis and the extensor communis digitorum; the fifth, the tendon of the extensor minimi digiti; and the sixth, the tendon of the extensor carpi ulnaris. All the sheaths are lined by synovial membranes, which extend nearly to the insertions of their tendons. Occasionally, but not often, one or more of them communicate with the wrist-joint.

The *fascia of the metacarpus* consists of a thin fibrous layer continued from the posterior annular ligament. It separates the extensor tendons from the subcutaneous veins and nerves, and is attached to the radial side of the second metacarpal bone, and the ulnar side of the fifth.

Dissection.

The fascia must be removed from the muscles, without injuring the muscular fibres which arise from its under surface. Preserve the posterior annular ligament. The following superficial muscles are now exposed, and should be examined in the order in which they are placed, proceeding from the radial to the ulnar side: 1. The supinator radii longus

**Superficial Muscles
on the Back of the
Forearm.**

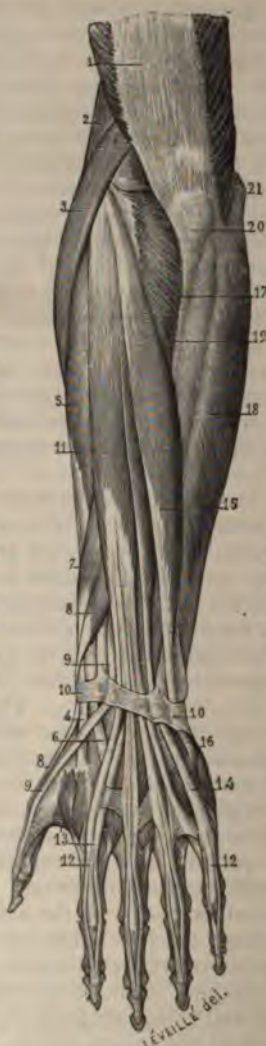(already described, p. 331). 2. The extensor carpi radialis longior. 3. The extensor carpi radialis brevior. 4. The extensor communis digitorum. 5. The extensor minimi digiti. 6. The extensor carpi ulnaris. 7. The anconeus.

A little below the middle of the forearm, the extensors of the wrist and fingers diverge from each other, leaving an interval, in which are seen the three extensors of the thumb—namely, the extensor ossis metacarpi pollicis, the extensor primi internodii pollicis, and the extensor secundi internodii pollicis. The two former cross obliquely over the radial extensors of the wrist, and pass over the lower third of the radius; the latter emerges from under the radial border of the extensor communis digitorum, and then passes over the insertions of the tendons of the radial extensors of the wrist.

Between the second and third extensors of the thumb, we observe a part of the lower end of the radius, which is not covered either by muscle or tendon. This subcutaneous portion of the bone is

immediately above the prominent tubercle in the middle of its lower extremity, and, since it can be easily felt through the skin, it

1. Tendon of the triceps.
2. Origin of the supinator longus or brachio-radialis.
3. Extensor carpi radialis longior.
4. Insertion of this muscle.
5. Extensor radialis brevior.
6. Insertion of this muscle.
7. Extensor ossis metacarpi pollicis.
8. Extensor primi internodii pollicis.
9. Extensor secundi internodii pollicis.
10. 10. Posterior annular ligament.
11. Extensor communis digitorum.
- 12, 12. Attachments of the



- tendons of this muscle to the middle and distal phalanges of the four fingers.
13. Tendons of the extensor indicis uniting with the tendon of the communis digitorum indicis.
14. Tendon of the extensor minimi digiti mingling posteriorly with the tendon of the communis to the little finger.
15. Extensor carpi ulnaris.
16. Its insertion into the metacarpal bone.
17. Anconeus.
18. Flexor carpi ulnaris attached to the posterior border of the ulna by the aponeurosis.

FIG. 137.—SUPERFICIAL EXTENSORS OF THE FOREARM.

presents a convenient place for examination in doubtful cases of fracture.

**Extensor Carpi
Radialis Longior.**

This muscle is partly covered by the supinator radii longus. It *arises* from the lower third of the ridge leading to the external condyle of the humerus, and from the intermuscular septum. It descends along the outer side of the forearm, and terminates about the middle, in a flat tendon, which passes beneath the extensor ossis metacarpi and primi internodii pollicis, traverses a groove on the outer and back part of the radius, lined by a synovial membrane, and is *inserted* into the radial side of the carpal end of the metacarpal bone of the index finger. Previous to its insertion, the tendon is crossed by the extensor secundi internodii pollicis. It is supplied by a branch from the musculo-spiral nerve (Fig. 135, No. 3, p. 362).

**Extensor Carpi
Radialis Brevior.**

This muscle *arises* from the external condyle by the tendon common to it and the other extensors, from the intermuscular septa, from the external lateral ligament of the elbow-joint and the aponeurosis covering the muscle. The muscular fibres terminate near the lower third of the forearm, upon the under surface of a flat tendon, which descends, covered by that of the extensor carpi radialis longior, beneath the three extensors of the thumb. The tendon traverses a groove on the back of the radius, on the same plane with that of the long radial extensor, but lined by a separate synovial membrane, and is *inserted* into the radial side of the base of the metacarpal bone of the middle finger. A bursa is generally found between the tendon and the bone. Its nerve comes from the posterior interosseous (Fig. 137, No. 5, p. 370).

**Extensor Communis
Digitorum.**

This muscle *arises* from the common tendon attached to the external condyle, from the septa between it and the contiguous muscles, and from its strong fascial covering. A little below the middle of the forearm, the muscle divides into three tendons, which pass, together with the extensor indicis, beneath the posterior annular ligament, through a groove on the back of the radius lined by synovial membrane. On the back of the hand the tendons become broader and flatter, and diverge from each other towards the metacarpal joints of the fingers, where they become thicker and narrower, and give off, on each side, a fibrous expansion, which covers the sides of the joint. Over the first phalanx of the finger, each tendon again spreads out, receives the expanded tendons of the lumbricales and interossei muscles, and divides at the second phalanx into three portions, of which the middle is *inserted* into the upper end of the second phalanx; the two lateral, reuniting over the lower end of the second phalanx, are *inserted* into the upper

end of the third.* Its nerve comes from the posterior interosseous. (Fig. 137, No. 11, p. 370.)

The oblique aponeurotic slips which connect the tendons on the back of the hand are subject to great variety. The tendon of the index finger is commonly free; it is situated on the radial side of the proper indicator tendon, and becomes united with it at the metacarpal joint.

The tendon of the middle finger usually receives a slip from that of the ring. The tendon of the ring finger generally sends a slip to the tendons on either side of it, and, in some cases, entirely furnishes the tendon of the little finger. Thus the ring finger does not admit of independent extension.†

The muscle is not only a general extensor of the fingers, but can extend some of the phalanges independently of the rest: *e. g.* it can extend the first phalanges while the second and third are flexed; or it can extend the second and third phalanges during flexion of the first.

**Extensor Minimi
Digiti, or Auri-
cularis.**

This long slender muscle, situated on the ulnar side of the common extensor, *arises* from the common tendon from the external condyle, and from the septa between it and the contiguous muscles. Its slender tendon runs separately beneath the annular ligament immediately behind the joint between the radius and ulna, in a special sheath lined by synovial membrane. On emerging from the annular ligament, the tendon splits into two, which pass obliquely to the little finger. At the first joint of the little finger, the outer tendon is joined by that of the common extensor, and both expand upon the first and second phalanges, terminating in the same manner as the extensor tendons of the other fingers. Its nerve comes from the posterior interosseous. (Fig. 137, No. 14, p. 370.)

**Extensor Carpi
Ulnaris.**

This muscle *arises* from the common tendon from the external condyle, from the septum between it and the extensor minimi digiti, from the fascia of the forearm, and from the aponeurosis attached to the posterior ridge of the ulna common to this muscle, the flexor carpi ulnaris, and the flexor profundus digitorum. The fibres ter-

*The extensor tendons are inserted into the periosteum; but the flexor tendons are inserted into the substance of the bone. This accounts for the facility with which the former will tear off the bones in cases of necrosis, while the latter will adhere so tightly as to require cutting before the phalanx can be removed. It probably also explains the great liability to necrosis which is so frequently observed in cases of thecal abscess.

† Hence, subcutaneous tenotomy of the web uniting these extensor tendons greatly facilitates the piano and flute players, without impairing the strength of their extensile power. (A. H.)

minate upon a strong, broad tendon, which traverses a distinct groove on the back of the ulna, close to the styloid process, and is *inserted* into the posterior aspect of the carpal end of the metacarpal bone of the little finger. Below the styloid process of the ulna, the tendon passes beneath the posterior annular ligament, over the back of the wrist, and is confined in a very strong fibrous canal, which is attached to the back of the cuneiform, pisiform, and unciform bones, and is lined by a continuation from the synovial membrane in the groove of the ulna. The *action* of this muscle is to extend the hand, and incline it towards the ulnar side. It is supplied by the posterior interosseous nerve. (Fig. 137, No. 15, p. 370.)

In pronation of the forearm the lower articular end of the ulna projects between the tendons of the extensor carpi ulnaris and the extensor minimi digiti. A subcutaneous *bursa* is sometimes found above the bone in this situation.

Anconeus. This small triangular muscle is situated at the outer and back part of the elbow. It is covered by a strong layer of fascia, derived from the tendon of the triceps, and appears like a continuation of that muscle. It *arises* by a tendon from the posterior part of the external condyle of the humerus, and is *inserted* into the triangular surface on the upper fourth of the outer part of the ulna. Part of the under surface of the muscle is in contact with the capsule of the elbow-joint. Its *action* is to assist in extending the forearm. Its nerve comes from the musculospiral (Fig. 138, No. 3, p. 375).

Dissection. To expose the deep layer of muscles detach from the external condyle the extensor carpi radialis brevis, the extensor communis digitorum, the extensor minimi digiti, and the extensor carpi ulnaris; and, after noticing the vessels and nerves which enter their under surface, turn them down. The deep-seated muscles, with the posterior interosseous artery and nerve, must be dissected. The muscles exposed are: 1.

Deep-seated Muscles on the Back of the Forearm. The extensor ossis metacarpi pollicis. 2. Extensor primi internodii pollicis. 3. Extensor secundi internodii pollicis. 4. Extensor indicis or indicator. 5. The supinator radii brevis. They are all supplied by branches from the posterior interosseous nerve.

Extensor Ossis Metacarpi Pollicis. This muscle lies immediately below the supinator brevis, and *arises* from the posterior surface of the ulna below the supinator brevis, from the posterior surface of the middle third of the radius, and from the interosseous membrane. The muscle passes obliquely downwards and outwards, crosses the radial extensors of the wrist

about three inches (7.5 cm.) above the carpus, and terminates in a tendon, which passes along a common groove with the extensor *primi internodii pollicis*, lined by synovial membrane, on the outer part of the lower end of the radius, and is *inserted* into the base of the metacarpal bone of the thumb, and frequently also by a tendinous slip into the trapezium (Fig. 138, No. 12, p. 375).

Extensor Primi Internodii Pollicis.

This, the smallest of the deep muscles, *arises* from the posterior surface of the radius, below the preceding, and from the interosseous membrane. It descends obliquely in company with the preceding muscle, turns over the radial extensors of the wrist, and terminates upon a tendon which passes beneath the annular ligament, through the groove on the outer part of the radius, and is *inserted* into the radial side of the base of the first phalanx of the thumb (Fig. 138, No. 13, p. 375).

Extensor Secundi Internodii Pollicis.

This muscle covers part of the origin of the preceding muscle, and *arises* from the posterior surface of the ulna, below the extensor *ossis metacarpi pollicis*, and from the interosseous membrane. The tendon receives fleshy fibres as low as the wrist, passes beneath the annular ligament in a distinct groove on the back of the radius, crosses the tendons of the radial extensors of the wrist, proceeds over the metacarpal bone and the first phalanx of the thumb, and is *inserted* into the base of the last phalanx (Fig. 138, No. 14, p. 375.)

The tendons of the three extensors of the thumb may be easily distinguished in one's own hand. The extensor *ossis metacarpi* and *primi internodii pollicis* cross obliquely over the radial artery, where it lies on the external lateral ligament of the carpus; the extensor *secundi internodii pollicis* crosses the artery just before it sinks into the palm, between the first and second metacarpal bones, and is a good guide to the vessel. The *action* of the three extensors of the thumb is implied by their names.

Extensor Indicis, or Indicator.

This muscle *arises* from the posterior surface of the ulna, below the extensor *secundi internodii pollicis*, and slightly from the interosseous membrane. The tendon passes beneath the posterior annular ligament, in the same groove, on the back of the radius, with the tendons of the extensor *digitorum communis*. It then proceeds over the back of the hand to the first phalanx of the index finger, where it is united to the ulnar border of the common extensor tendon. By the *action* of this muscle the index finger can be extended independently of the others (Fig. 138, No. 15, p. 375).

Dissection.

Reflect the anconeus from its origin to expose the following muscle:—

Radii

This muscle embraces the upper third of the radius. It *arises* from the external condyle of the humerus, from the external lateral ligament

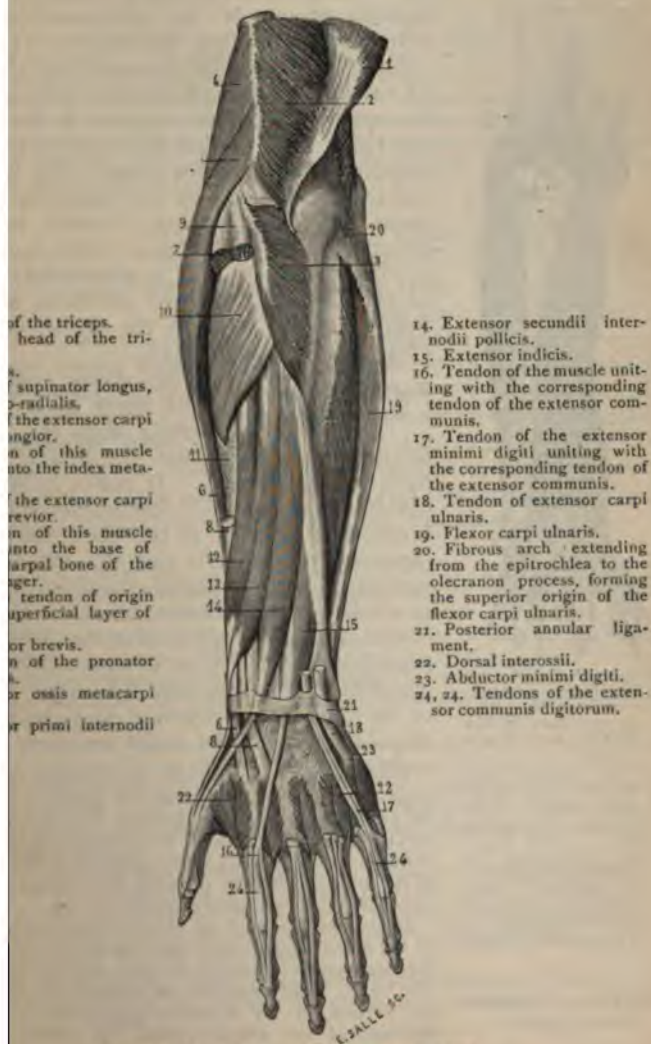


FIG 138.—DEEP EXTENSORS OF THE FOREARM.

of the elbow-joint, from the orbicular ligament surrounding the head of the radius, from an oblique ridge on the outer surface of the ulna below the



FIG. 139.—DIAGRAM SHOWING THE ANASTOMOSES OF ARTERIES AT THE BACK OF THE ELBOW AND WRIST JOINTS.

1. The superior profunda.
2. The anastomotica magna.
3. The posterior ulnar recurrent.
4. The posterior interosseous, its ascending and descending branches.
5. The termination of the anterior interosseous.
6. The posterior carpal arch.

Posterior Interosseous Nerve.

through the supinator radii brevis, and descends, lying on the lower fibres of this

insertion of the anconeus, by fleshy fibres from the triangular excavation below the lesser sigmoid notch of the ulna, and from the aponeurosis covering the muscle. The muscular fibres turn over the neck and upper part of the shaft of the radius, and are inserted into the upper third of this bone as far forwards as the ridge leading from the tubercle to the insertion of the pronator teres. The muscle is traversed obliquely by the posterior interosseous nerve, which sends a branch to it, and its upper part is in contact with the capsule of the elbow-joint. It is a powerful supinator of the forearm, some of its fibres acting at nearly a right angle to the axis of the radius (Fig. 138, No. 10, p. 375).

Posterior Interosseous Artery.

This artery comes from the ulnar by a common trunk with the anterior interosseous and supplies the muscles on the back of the forearm. It passes between the oblique ligament and the interosseous membrane, and appears, at the back, between the supinator radii brevis and the extensor ossis metacarpi pollicis. After supplying branches to all the muscles in this situation, the artery descends, much diminished in size, between the superficial and deep layer of muscles to the wrist, where it inosculates with the carpal branches of the anterior interosseous and the posterior carpal branches of the radial and ulnar arteries.

The largest branch of this artery is the *interosseous recurrent*. It ascends beneath the supinator brevis and the anconeus to the space between the external condyle and the olecranon, where it inosculates with the branch of the superior profunda which descends in the substance of the triceps, with the posterior ulnar recurrent artery, and with the anastomotica magna.

In the lower part of the back of the forearm a branch of the anterior interosseous artery is seen passing through the interosseous membrane to reach the back of the wrist. The nerve which supplies the muscles on the back of the forearm is the *posterior interosseous*, one of the divisions of the musculo-spiral. It passes obliquely

muscle, the *extensores ossis metacarpi* and *primi internodii pollicis*, and beneath the superficial extensors. It then, much diminished in size, passes under the *extensor secundi internodii pollicis*, on the interosseous membrane, as far as the posterior annular ligament, where it presents a gangliform enlargement. Between the superficial and deep layer of muscles it sends to each a filament, generally in company with a branch of the posterior interosseous artery. It sends a branch to the *extensor carpi radialis brevis*, and supplies the *supinator brevis* in passing through its substance. The *supinator radii longus* and the *extensor carpi radialis longior* are supplied by distinct branches from the musculo-spiral nerve.

After the posterior interosseous nerve descends beneath the *extensor secundi internodii pollicis* it lies in the interosseous membrane, beneath the *extensor digitorum communis* and the indicator. At the back of the wrist, beneath the annular ligament, it forms the gangliform enlargement from which filaments are sent to the carpal and metacarpal joints.

Dissection.
Radial Artery on the
Back of the Wrist.

The radial artery is continued over the external lateral ligament of the carpus, beneath some filaments of the radial nerve, cutaneous veins, and the extensor tendons of the thumb, to the proximal part of the interval between the first and second metacarpal bones, where it dips down between the two origins of the *abductor indicis*, and, entering the palm, forms the deep palmar arch. In this part of its course it is accompanied by a filament of the musculo-cutaneous nerve; observe also that the tendon of the *extensor secundi internodii pollicis* passes over it immediately before it sinks into the palm. It supplies in this part of its course the following small branches to the back of the hand:—

a. Posterior carpal artery.—This branch passes across the carpal bones, beneath the extensor tendons. It inosculates with the termination of the anterior interosseous artery, and forms an arch beneath the extensor tendons, with a corresponding branch from the ulnar artery. The carpal arch sends off small branches, called the *dorsal interosseous*, which descend along the third and fourth interosseous spaces from the arch just mentioned, beneath the extensor tendons, and inosculate near the carpal ends of the metacarpal bones with the perforating branches of the deep palmar arch.

b. The first dorsal interosseous artery is generally larger than the others. It passes forwards, beneath the extensors of the thumb, on the second interosseous space to the cleft between the index and middle fingers, communicating here with the perforating branch of the deep palmar arch, and terminates in small branches, of which proceed along the back of the fingers, others inosculate with the palmar digital arteries.

c. The dorsalis indicis, a branch of variable size, passes over the first interosseous muscle along the radial side of the back of the index finger.

d. The dorsales pollicis are two small branches which arise from the radial opposite the head of the first metacarpal bone, and run along the back of the thumb, one on either side. They are often absent.

These dorsal interosseous arteries supply the extensor tendons and their sheaths, the interosseous muscles, and the skin on the back of the hand and the first phalanges of the fingers.

Dissection. Remove the tendons from the back and from the palm of the hand; observe the deep palmar fascia which covers the interosseous muscles. It is attached to the ridges of the metacarpal bones, forms a distinct sheath for each interosseous muscle, and is continuous inferiorly with the transverse metacarpal ligament. On the back of the hand the interosseous muscles are covered by a thin fascia, which is attached to the adjacent borders of the metacarpal bones.

Transverse Metacarpal Ligament. This consists of strong bands of ligamentous fibres, which pass transversely between the distal extremities of the metacarpal bones. These bands are intimately united to the fibro-cartilaginous ligament of the metacarpal joints, and are of sufficient length to admit of a certain degree of movement between the ends of the metacarpal bones.

Dissection. Remove the fascia which covers the interosseous muscles, and separate the metacarpal bones by dividing the transverse metacarpal ligament. A *bursa* is frequently developed between their digital extremities.

Interosseous Muscles. These muscles, so named from their position, extend from the sides of the metacarpal bones to the bases of the first phalanges and the extensor tendons of the fingers. In each interosseous space (except the first, in which there is only an abductor) there are two muscles, one of which is an abductor, the other an adductor, of a finger. Thus there are *seven* in all, four of which, situated on the back of the hand, are called dorsal; the remainder, seen only in the palm, are called palmar.* They are all supplied by the ulnar nerve.

Dorsal Interossei. Each dorsal interosseous is a bipenniform muscle, and *arises* from the opposite sides of two contiguous metacarpal bones (Figs. 138 and 140). From this double origin the fibres converge to a tendon, which passes between the metacarpal joints of the finger, and is *inserted* into the side of the base of the first phalanx, and by a broad expansion into the extensor tendon on the back of the same finger.

The *first dorsal interosseous* muscle (*abductor indicis*) is larger than the others, and occupies the interval between the thumb and forefinger. It *arises* from the proximal half of the ulnar side of the first metacarpal bone, and from the entire length of the radial side of the second: between the two origins, the radial artery passes into the palm. Its fibres converge on either side to a tendon,

* If we consider the adductor pollicis as a palmar interosseous muscle, there would be four palmar and four dorsal—all supplied by the ulnar nerve.

which is *inserted* into the *radial* side of the first phalanx of the index finger and its extensor tendon.

The *second dorsal interosseous* muscle occupies the second metacarpal space. It is *inserted* into the radial side of the first phalanx of the middle finger and its extensor tendon.

The *third* and *fourth*, occupying the corresponding metacarpal spaces, are *inserted*, the one into the ulnar side of the middle, the other into the ulnar side of the ring finger (Fig. 138, No. 22, p. 375).

If a line be drawn longitudinally through the middle finger, as represented by the dotted line in Fig. 140, we find that all the



FIG. 140.—DIAGRAM OF THE FOUR DORSAL INTEROSSEI, DRAWING FROM THE MIDDLE LINE.

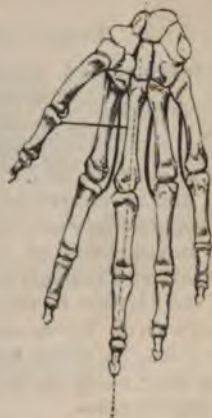

FIG. 141.—DIAGRAM OF THE THREE PALMAR INTEROSSEI, AND THE ADDUCTOR POLLICIS, DRAWING TOWARDS THE MIDDLE LINE.

dorsal interosseous muscles are abductors from that line; consequently, they separate the fingers from each other.

Palmar Interosseous. It requires a careful examination to distinguish this set of muscles, because the dorsal muscles protrude with them into the palm. They are smaller than the dorsal, and each *arises* from the lateral surface of only one metacarpal bone—that, namely, connected with the finger into which the muscle is inserted (Fig. 141). They terminate in small tendons, which pass between the metacarpal joints of the fingers, and are *inserted*, like those of the dorsal muscles, into the sides of the first phalanges and the extensor tendons on the back of the fingers.

The *first palmar interosseous* muscle arises from the ulnar side of the second metacarpal bone, and is inserted into the ulnar side of the index finger. The *second* and *third* arise, the one from the radial side of the fourth, the other from the radial side of the fifth metacarpal bone, and are inserted into the same sides of the ring and little fingers.

The palmar interosseous muscles are all adductors to a line drawn through the middle finger (Fig. 141). They are, therefore, the opponents of the dorsal interosseous, and move the fingers towards each other.*

The palmar and dorsal interossei are supplied by filaments from the deep branch of the ulnar nerve (Fig. 123, No. 36, p. 322).

DISSECTION OF THE LIGAMENTS.

The inner end of the clavicle articulates with the comparatively small and shallow excavation on the upper and outer part of the sternum, and is an arthrodial joint. The security of the joint depends upon the great strength of its ligaments. There are two synovial membranes, and an intervening fibro-cartilage.

The *anterior sterno-clavicular ligament* (Fig. 142) consists of a strong broad band of ligamentous fibres, which pass obliquely downwards and inwards over the front of the joint, from the inner end of the clavicle to the anterior surface of the sternum.

The *posterior sterno-clavicular ligament* extends over the back of the joint, its fibres passing downwards and forwards from the back of the clavicle to the back of the sternum in a similar manner to the anterior.

The *interclavicular ligament* connects the clavicles directly.

* The interossei, probably, also assist the flexors of the fingers when the latter are slightly flexed at their metacarpo-phalangeal joints. M. Duchenne believes that, in addition to their usually ascribed function of abduction, adduction, and supplemental flexion at the metacarpo-phalangeal articulation, the interossei act as extensors of the second and third phalanges; the common extensor tendons acting only as extensors of the first phalanges. (*Physiologie des Mouvements, &c.*, 1867). The action of the lumbricales in extending the second and third phalanges (even if they are not the chief factors of this movement) must not be lost sight of, for in a case, recorded in *St. Bartholomew's Hospital Reports*, 1881, in which the ulnar nerve had been divided a short distance above the wrist-joint, the first phalanges of the ring and little fingers were bent (extended) upon their articulating metacarpal bones, the second and third phalanges being flexed at obtuse angles upon their proximal phalanges; the index and middle fingers being normal. I attribute this condition to paralysis of the two ulnar lumbricales and not to loss of power of the interossei. I have seen about a dozen instances of division of the ulnar nerve, and in all of them the same condition of the little and ring fingers has existed.

extends transversely along the notch of the sternum, and has a broad attachment to the upper border of each clavicle. Between the clavicles it is more or less attached to the sternum, so that it forms a curve with the concavity upwards.

The three ligaments just described are so closely connected together, collectively, they form for the joint a complete fibrous capsule of such strength that dislocation of it is rare.

The *costo-clavicular* or *rhomboid ligament* connects the clavicle to the cartilage of the first rib. It ascends obliquely outwards and backwards from the cartilage of the rib to a rough surface beneath the sternal end of the clavicle. Its use is to limit the elevation of the clavicle. There is such constant movement between the clavicle and the cartilage of the first rib that a well-marked *bursa* is commonly found between them.

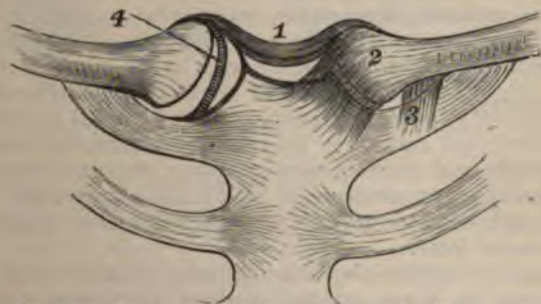

FIG. 142.—DIAGRAM OF THE STERNO-CLAVICULAR LIGAMENTS.

1. Anterior sternoclavicular ligament. 2. Posterior sternoclavicular ligament. 3. Costo-clavicular ligament. 4. Interarticular fibro-cartilage.

Interarticular fibro-cartilage.—To see this, cut through the ligament, the anterior and posterior ligaments of the joint, and the clavicle. It is nearly circular in form, and thicker at the circumference than the centre, in which there is sometimes a notch, and divides the articulation into two cavities. It is attached to the cartilage of the first rib, close to the sternum superiorly, to the upper part of the clavicle and the sternoclavicular ligament. Its circumference is inseparably connected with the anterior and posterior ligaments.*

Interarticular fibro-cartilages (menisci) also exist in the following joints: the temporomaxillary, knee, and wrist joints. Professor Humphreys states that interarticular cartilages augment the variety of movements permitted, as for instance that of rotation in the knee-joint, in addition to flexion and extension, and flexion, which otherwise would be the only possible ones.

The *first palmar interosseous* muscle arises from the ulnar side of the second metacarpal bone, and is inserted into the ulnar side of the index finger. The *second* and *third* arise, the one from the radial side of the fourth, the other from the radial side of the fifth metacarpal bone, and are inserted into the same sides of the ring and little fingers.

The palmar interosseous muscles are all adductors to a line drawn through the middle finger (Fig. 141). They are, therefore, the opponents of the dorsal interosseous, and move the fingers towards each other.*

The palmar and dorsal interossei are supplied by filaments from the deep branch of the ulnar nerve (Fig. 123, No. 36, p. 322).

DISSECTION OF THE LIGAMENTS.

The inner end of the clavicle articulates with the comparatively small and shallow excavation on the upper and outer part of the sternum, and is an arthrodial joint. The security of the joint depends upon the great strength of its ligaments. There are two synovial membranes, and an intervening fibro-cartilage.

The *anterior sterno-clavicular ligament* (Fig. 142) consists of a strong broad band of ligamentous fibres, which pass obliquely downwards and inwards over the front of the joint, from the inner end of the clavicle to the anterior surface of the sternum.

The *posterior sterno-clavicular ligament* extends over the back of the joint, its fibres passing downwards and forwards from the back of the clavicle to the back of the sternum in a similar manner to the anterior.

The *interclavicular ligament* connects the clavicles directly.

* The interossei, probably, also assist the flexors of the fingers when the latter are slightly flexed at their metacarpo-phalangeal joints. M. Duchenne believes that, in addition to their usually ascribed function of abduction, adduction, and supplemental flexion at the metacarpo-phalangeal articulation, the interossei act as extensors of the second and third phalanges; the common extensor tendons acting only as extensors of the first phalanges. (*Physiologie des Mouvements, &c.*, 1867). The action of the lumbricales in extending the second and third phalanges (even if they are not the chief factors of this movement) must not be lost sight of, for in a case, recorded in *St. Bartholomew's Hospital Reports*, 1881, in which the ulnar nerve had been divided a short distance above the wrist-joint, the first phalanges of the ring and little fingers were bent (extended) upon their articulating metacarpal bones, the second and third phalanges being flexed at obtuse angles upon their proximal phalanges; the index and middle fingers being normal. I attribute this condition to paralysis of the two ulnar lumbricales and not to loss of power of the interossei. I have seen about a dozen instances of division of the ulnar nerve, and in all of them the same condition of the little and ring fingers has existed.

It extends transversely along the notch of the sternum, and has a broad attachment to the upper border of each clavicle. Between the clavicles it is more or less attached to the sternum, so that it forms a curve with the concavity upwards.

The three ligaments just described are so closely connected that, collectively, they form for the joint a complete fibrous capsule of such strength that dislocation of it is rare.

The *costo-clavicular* or *rhomboid ligament* connects the clavicle to the cartilage of the first rib. It ascends obliquely outwards and backwards from the cartilage of the rib to a rough surface beneath the sternal end of the clavicle. Its use is to limit the elevation of the clavicle. There is such constant movement between the clavicle and the cartilage of the first rib that a well-marked *bursa* is commonly found between them.

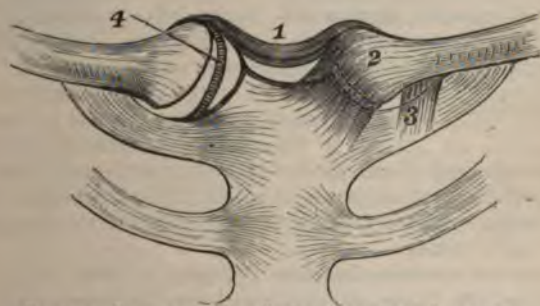

FIG. 142.—DIAGRAM OF THE STERNO-CLAVICULAR LIGAMENTS.

1. Interclavicular ligament. 2. Anterior sternoclavicular ligament. 3. Costo-clavicular ligament. 4. Interarticular fibro-cartilage.

Interarticular fibro-cartilage.—To see this, cut through the rhomboid, the anterior and posterior ligaments of the joint, and raise the clavicle. It is nearly circular in form, and thicker at the circumference than the centre, in which there is sometimes a perforation, and divides the articulation into two cavities. Inferiorly, it is attached to the cartilage of the first rib, close to the sternum; superiorly, to the upper part of the clavicle and the interclavicular ligament. Its circumference is inseparably connected with the anterior and posterior ligaments.*

* Interarticular fibro-cartilages (menisci) also exist in the following joints: acromio-clavicular, temporo-maxillary, knee, and wrist joints. Professor Humphry has shown that interarticular cartilages augment the variety of movements in a joint, permitting for instance that of rotation in the knee-joint, in addition to that of extension and flexion, which otherwise would be the only possible ones.

The joint is provided with *two synovial membranes*: one between the articular surface of the sternum and the inner surface of the fibro-cartilage; the other between the articular surface of the clavicle and the outer surface of the fibro-cartilage.

This interarticular fibro-cartilage is a structure highly elastic, without admitting of any stretching. It equalizes pressure, breaks shocks, and also acts as a ligament, tending to prevent the clavicle from being driven inwards towards the mesial line.

Observe the relative form of the cartilaginous surfaces of the bones: that of the sternum is slightly concave in the transverse, and convex in the antero-posterior direction; that of the clavicle is the reverse.

The form of the articular surfaces and the ligaments of a joint being known, it is easy to understand the movements of which it is capable. The clavicle can be moved upon the sternum in a direction either upwards, downwards, backwards, or forwards; it also admits of circumduction. These movements, though limited at the sternum, are considerable at the apex of the shoulder.*

The outer end of the clavicle articulates with the acromion, and is connected by strong ligaments to the coracoid process of the scapula.

The clavicle and the acromion articulate with each other by two flat oval cartilaginous surfaces, of which the planes slant inwards, and the longer diameters are in the antero-posterior direction. It is an arthrodial joint.

The *superior acromio-clavicular ligament*, a broad band of parallel ligamentous fibres, strengthened by the aponeurosis of the trapezius, extends from the upper surface of the acromion to the upper surface of the clavicle.

The *inferior acromio-clavicular ligament*, of less strength, extends along the under surface of the joint from bone to bone.†

An *interarticular fibro-cartilage* is sometimes found in this joint:

* Prof. Humphry, in describing the movements of this joint, in his valuable work, "On the Human Skeleton," says, "The movements attendant on elevation and depression of the shoulder take place between the clavicle and the interarticular ligament, the bone rotating upon the ligament on an axis drawn from before backwards through its own articular facet. When the shoulder is moved forwards and backwards, the clavicle, with the interarticular ligament, rolls to and fro on the articular surface of the sternum, revolving, with a slightly sliding movement, round an axis drawn nearly vertically through the sternum. In the circumduction of the shoulder, which is compounded of these two movements, the clavicle revolves upon the interarticular cartilage, and the latter, with the clavicle, rolls upon the sternum."

† The superior and inferior ligaments practically make a capsular ligament, and are described as such by some authors.

but it is incomplete, and seldom extends lower than the upper half. There is only one synovial membrane.

Coraco-clavicular ligament.—The clavicle is connected to the coracoid process of the scapula by two strong ligaments—the *conoid* and *trapezoid*, which, being continuous with each other, should be considered as one. The *trapezoid* ligament is the more anterior and external. Quadrilateral in shape, it arises from the

back of the upper surface of the coracoid process, and ascends obliquely backwards and outwards to the oblique line on the under aspect of the clavicle, near its outer end. The *conoid* ligament, triangular in form, is situated behind the trapezoid ligament to the posterior border of which it is attached. It is fixed at its apex to the root of the coracoid process, ascends nearly vertically, and is attached by its base to the clavicle. The coraco-clavicular ligaments fix the scapula to the clavicle, and prevent undue rotation of the scapula. When the clavicle is fractured in the line of the attachment of the coraco-clavicular ligament, there is little or

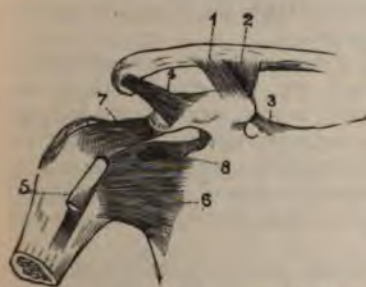

FIG. 143.—ANTERIOR VIEW OF THE SCAPULO-CLAVICULAR LIGAMENTS, AND OF THE SHOULDER-JOINT.

1. Trapezoid portions of the coraco-clavicular ligament.
2. Conoid portions of the coraco-clavicular ligament.
3. Suprascapular or transverse ligament.
4. Coraco-acromial ligament.
5. Tendon of biceps.
6. Capsular ligament of the shoulder-joint.
7. Coraco-humeral ligament.
8. Foramen in the capsular ligament for the subscapularis tendon.

no displacement of the fractured ends, these being kept in place by the ligament.

Ligaments of the Scapula.

These are two: the *coraco-acromial* or *triangular* ligament, attached by its apex to the tip of the acromion process, and by its base to the outer border of the coracoid process; it is separated from the upper part of the capsule of the shoulder-joint by a large bursa; and the *transverse* or *coracoid* ligament, which passes across the suprascapular notch, converting it into a foramen. The suprascapular vessels pass over the foramen, the suprascapular nerve through it.

Shoulder-joint.

The articular surface of the head of the humerus, forming rather more than one-third of a sphere, moves upon the shallow glenoid cavity of the scapula, which is of an oval form, with the broader end downwards and the long diameter nearly vertical. The security of the joint depends not upon any mechanical contrivance of the bones, but upon the great strength and number of the ligaments and tendons which surround and are

intimately connected with it. It is an enarthrodial, or ball-and-socket joint.

To admit the free motion of the head of the humerus upon the glenoid cavity it is requisite that the *capsular ligament* of the joint be loose and capacious. Accordingly, the head of the bone, when detached from its muscular connections, may be separated from the glenoid cavity to the extent of an inch (2.5 cm.) or more, without laceration of the capsule. This explains the elongation of the arm observed in some cases in which effusion takes place into the joint; also in cases of paralysis of the deltoid.

The *capsular ligament* is attached above, round the circumference of the glenoid cavity; below, round the anatomical neck of the humerus. It is strongest on its upper aspect, weakest and longest on its lower. It is strengthened on its upper and posterior part by the tendons of the supraspinatus, infraspinatus, and teres minor; its inner part is strengthened by the broad tendon of the subscapularis and the coraco-humeral ligament; its lower part by the long head of the triceps.

Thus the circumference of the capsule is surrounded by tendons on every side, excepting a small space towards the axilla. If the humerus be raised, it will be found that the head of the bone rests upon this unprotected portion of the capsule, between the tendons of the subscapularis and the long head of the triceps; through this part of the capsule the head of the bone is first protruded in dislocations into the axilla.

At the upper and inner side of the joint, a small opening is observable in the capsular ligament, through which the tendon of the subscapularis passes, so that the synovial membrane of the joint communicates with the bursa under the tendon of this muscle. A second opening exists in the lower part of the front of the capsular ligament, where the tendon of the biceps emerges from the joint. A third opening occasionally exists between the joint, and a bursa under the tendon of the infraspinatus muscle.

The upper and inner surface of the capsule is strengthened by a strong band of ligamentous fibres, called the *coraco-humeral* or *accessory ligament*. It is attached to the root of the coracoid process, expands over the upper surface of the capsule, with which it is inseparably united, and, passing downwards and outwards, is attached to the greater tuberosity of the humerus.

Open the capsule to see the *tendon of the long head of the biceps*. It arises by a rounded tendon from the upper margin of the glenoid cavity, and is continuous with the glenoid ligament; becoming slightly flattened, it passes over the head of the humerus, descends through the groove between the two tuberosities, and, after piercing the capsular ligament of the shoulder-joint, it passes along the

bicipital groove, being retained in situ by an aponeurotic prolongation from the tendon of the pectoralis major. It is loose and moveable within the joint. It acts like a strap, keeping down the head of the bone when the arm is raised by the deltoid, and then might be considered as taking the part of a ligament of the joint.

The tendon of the biceps, strictly speaking, does not perforate the synovial membrane of the joint. It is enclosed in a tubular sheath, which is reflected over it at its attachment to the glenoid cavity, and accompanies it for two inches (5 *cm.*) down the groove of the humerus. During the earlier part of foetal life, it is connected to the capsule by a fold of synovial membrane, which subsequently disappears.

The margin of the glenoid cavity of the scapula is surrounded by a fibro-cartilaginous band of considerable thickness, called the *glenoid ligament*. This not only enlarges, but deepens the cavity. Superiorly, it is continuous on either side with the tendon of the biceps; inferiorly, with the tendon of the triceps; in the rest of its circumference it is attached to the edge of the cavity.

The cartilage covering the head of the humerus is thicker at the centre than at the circumference. The reverse is the case in the glenoid cavity.

The *synovial membrane* lining the under surface of the capsule is reflected around the tendon of the biceps, and passes with it in the form of a cul-de-sac down the bicipital groove. On the inner side of the joint it always communicates with the bursa beneath the tendon of the subscapularis.

There is also a large bursa situated between the capsule and the deltoid muscle, which does not communicate with the joint.

The muscles in relation with the joint are: above, the supraspinatus; behind, the infraspinatus and teres minor; below, the long head of the triceps; internally, the subscapularis; and, inside the joint, the long head of the biceps.

The shoulder-joint is an enarthrodial joint, and has a more extensive range of motion than any other joint in the body; it is what mechanics call a universal joint. It is capable of motion forwards and backwards, of adduction, abduction, circumduction, and rotation. The various movements are limited chiefly by the surrounding muscles and by atmospheric pressure, for the capsule is so lax as to offer no obstacle to the freedom of movement in any direction. The amount of rotation which the head of the humerus is capable of, is to the extent of a quarter of a circle.

The movements of which the shoulder-joint is capable are effected by the following muscles: thus—

Extension is effected by the posterior fibres of the deltoid, latis-

simus dorsi, teres major, and (when the arm is raised) by the infraspinatus and teres minor.

Flexion, by the anterior fibres of the deltoid, coraco-brachialis, and the pectoralis major (slightly).

Abduction, by the deltoid and the supraspinatus.

Adduction, by the pectoralis major, latissimus dorsi, teres major, coraco-brachialis; and (when the arm is raised) by the subscapularis.

Rotation inwards, by the subscapularis, latissimus dorsi, and teres major.

Rotation outwards, by the infraspinatus and the teres minor.*

Elbow-joint.

The elbow-joint is a ginglymus or hinge-joint. The larger sigmoid cavity of the ulna is adapted to the trochlea upon the lower end of the humerus, admitting only

of flexion and extension; while the shallow excavation upon the head of the radius admits not only of flexion and extension, but of central rotation, upon the rounded articular eminence (*capitellum*) of the humerus, and of peripheral rotation at the superior radio-ulnar articulation.

The joint is secured in front and behind by anterior and posterior ligaments, and laterally by two strong lateral ligaments. No ligament is attached to the head of the radius, otherwise its rotatory movement would be impeded. The head is simply surrounded by a ligamentous collar, called the annular ligament, within which it freely rolls in pronation and supination of the hand.

The *anterior ligament* consists of broad, thin ligamentous fibres, attached above to the front of the humerus, above the coronoid fossa, below to the coronoid process of the ulna and to the orbicular ligament, and continuous on each side with the lateral ligaments. Some of the fibres cross each other at right angles.

The *posterior ligament* is composed of thin loose fibres attached above to the margin of the olecranon fossa, below to the border of the olecranon, and spread over the posterior aspect of the joint.

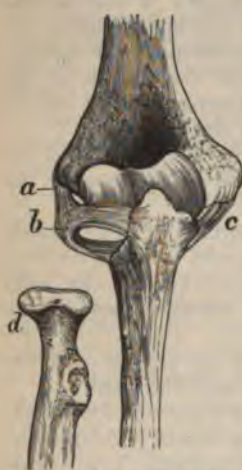

FIG. 144.—LIGAMENTS OF THE ELBOW-JOINT.

- a. External lateral ligament.
 b. Orbicular or annular ligament.
 c. Part of internal lateral ligament.
 d. Radius, removed from the annular ligament.

* With the humerus vertical the supraspinatus will act as an external rotator. It should also be borne in mind that the joint depends more for its strength upon the muscles and their tendons which surround it than upon the ligaments. (A. H.)

The *internal lateral ligament* is triangular, and is divided into two portions, an anterior and a posterior. Its *anterior part* is attached to the front of the internal condyle of the humerus; from this point the fibres radiate, and are inserted along the inner margin of the coronoid process of the ulna. The *posterior part* is also triangular, and passes from the back part of the internal condyle to the inner border of the olecranon.

A band of fibres extends transversely from the olecranon to the coronoid process, across a notch observable on the inner side of the sigmoid cavity; through this notch small vessels pass into the joint.

The *external lateral ligament* is attached to the external condyle of the humerus, and is in intimate connection with the common tendon of the extensors. The fibres spread out as they descend, and are interwoven with the annular ligament surrounding the head of the radius.

The preceding ligaments, collectively, form a continuous capsule for the joint.

Superior Radio-ulnar Articulation. The *orbicular or annular ligament of the radius* forms about three-fourths of a ring. Its ends are attached to the anterior and posterior borders of the lesser sigmoid cavity of the ulna, and is broader in the middle than at either end. Its lower border is straight; its upper border is convex, and connected with the anterior and external lateral ligaments. With this sigmoid cavity it forms a complete collar, which encircles the head, and part of the neck, of the radius. The lower part of the ring is narrower than the upper, the better to clasp the neck of the radius, and maintain it more accurately in position.

Synovial membrane of the elbow-joint.—Open the joint by a transverse incision in front, and observe the relative adaptation of the cartilaginous surfaces of the bones. The synovial membrane lines the interior of the capsule, and forms a cul-de-sac between the head of the radius and its annular ligament. It is widest and loosest under the tendon of the triceps. Where the membrane is reflected from the bones upon the ligaments, there is more or less adipose tissue, particularly in the fossæ on the front and back part of the lower end of the humerus.

The only movements permitted between the humerus and the ulna are those of flexion and extension, both of which are limited by the ligaments and tendons in front of and behind the joint, and probably not by the coronoid and olecranon processes. The head of the radius is most in contact with the capitellum of the humerus during semiflexion and semipronation; and it is kept, by the strong orbicular ligament which surrounds the neck of the radius, from being dislocated forwards by the biceps. The movement at the

superior radio-ulnar articulation is that of rotation in the lesser sigmoid cavity of the ulna, forming an example of a lateral ginglymus or diarthrosis rotatoria. It is by this rotation of the head of the radius that the hand is carried through an extensive range of pronation and supination; for it is articulated only to the lower end of the radius, the ulna being excluded by the interarticular fibro-cartilage from taking any share in the movement at the wrist-joint.

Interosseous Membrane.

This is an aponeurotic septum, stretched between the interosseous ridges of the radius and ulna, of which the chief purpose is to afford an increase of surface for the attachment of muscles. The septum is deficient above, beginning about an inch (2.5 cm.) below the tubercle of the radius, and thus permits free rotation of that bone. Its fibres extend obliquely downwards from the radius to the ulna. It is perforated in its lower third by the anterior interosseous vessels.

The name of *round* or *oblique ligament* is given to a thin band of fibres, which extends obliquely between the bones of the forearm in a direction contrary to those of the interosseous membrane. It is attached, superiorly, to the front surface of the ulna, near the outer side of the coronoid process; inferiorly, to the radius immediately below the tubercle. Between this ligament and the upper border of the interosseous membrane is a triangular interval through which the posterior interosseous artery passes to the back of the forearm. A *bursa* intervenes between the oblique ligament and the insertion of the tendon of the biceps. The use of this ligament is to limit supination of the radius.

Inferior Radio-ulnar Articulation.

This joint is a lateral ginglymus, and is formed by the inner concave surface of the lower end of the radius rotating upon the convex head of the ulna; which mechanism is essential to the pronation and supination of the hand. These corresponding surfaces are encrusted with a thin layer of cartilage, and are provided with a very loose synovial membrane. The surfaces are maintained in position by an anterior and a posterior radio-ulnar ligament, and a triangular fibro-cartilage.

The *anterior radio-ulnar ligament* is a thin fasciculus extending obliquely inwards from the anterior border of the sigmoid cavity of the radius to the head of the ulna.

The *posterior radio-ulnar ligament* passes from the posterior border of the sigmoid cavity to the posterior surface of the styloid process of the ulna.

The *triangular fibro-cartilage* between the radius and ulna is the principal uniting medium between the bones. To see it, slw

h the bones of the forearm, and separate them by cutting h the interosseous membrane, and opening the synovial rane of the joint between the lower ends. Thus a good view ined of the fibro-cartilage which connects them (Fig. 145). riangular, and placed transversely at the lower end of the illing up the interval caused by the greater length of the

Its base is attached to the lower end of the radius; its o a depression at the root of the styloid process of the ulna. in at the base and centre, r at the apex and sides. per surface is in contact he ulna, and covered by noval membrane of the in-radio-ulnar joint; its lower e, forming a part of the oint, is contiguous with neiform bone. Its borders onnected with the anterior osterior ligaments of the

In some instances there perture in the centre.

en, from accident or dis- this fibro-cartilage gets ed from the radius, the uence is an abnormal pro of the lower end of the

synovial membrane of this s distinct from that of the except in the case of a tion through the fibro- ge. On account of its ooseness, necessary for the station of the radius, it is *membrana sacciformis*.

movement between the lower ends of the radius and ulna to the rotation of the radius round the articular head of the and is confined to rotation forwards or *pronation*, and to n backwards or *supination*: the extent of movement being l by the anterior and posterior ligaments.

carpal or t-joint.

This is an arthrodial joint, and is formed: above, by the lower end of the radius and the distal surface of the triangular fibro-cartilage; by the scaphoid, semilunar and cuneiform bones; the o articulate with the two facets on the radius, the latter with

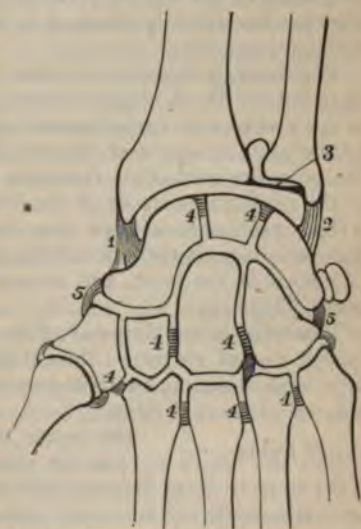


FIG. 145.—DIAGRAM OF THE LIGAMENTS AND SYNOVIAL MEMBRANES OF THE WRIST-JOINT.

1. External lateral ligament. 2. Internal lateral ligament. 3. Interarticular fibro-cartilage between radius and ulna. 4. Interosseous ligaments. 5. Lateral ligaments of the intercarpal joint.

the fibro-cartilage. The three carpal bones form a convex surface which is received into the concavity formed by the radius and the cartilage. The joint is secured by an anterior, a posterior and two lateral ligaments.

The *external lateral ligament* extends from the tip of the styloid process of the radius to the outer side of the scaphoid bone, to the anterior annular ligament, and to the trapezium.

The *internal lateral ligament* is round, and proceeds from the extremity of the styloid process of the ulna to the cuneiform bone. Another fasciculus is attached to the pisiform bone and the anterior annular ligament.

The *anterior ligament* consists of two or more broad bands of ligamentous fibres, which extend from the lower end of the radius to the first row of carpal bones, except the pisiform.

The *posterior ligament*, weaker than the preceding, proceeds from the posterior surface of the lower end of the radius, and is attached to the posterior surfaces of the first row of carpal bones.

The *synovial membrane* lines the under surface of the triangular fibro-cartilage at the end of the ulna, is reflected over the several ligaments of the joint, and thence upon the first row of the carpal bones (Fig. 145).

This articulation allows of all the movements of enarthrodial joints, except that of rotation: thus, it allows of flexion, extension, abduction, adduction, and circumduction, so that it is, strictly speaking, only an arthrodial joint.

Carpal Joints. The bones of the carpus are arranged in two rows, an upper and a lower, adapted to each other so as to form between them a joint. The articulations may be best arranged in three sets: those between the carpal bones of the first row; between those of the second row; and the articulation of the two rows with each other: they are all examples of arthrodial joints.

a. The *first row of carpal bones* are connected together by two palmar, two dorsal, and two interosseous ligaments.

The *dorsal and palmar transverse ligaments* proceed, on the dorsal and palmar aspects, from the scaphoid to the semilunar bone, and from the semilunar to the cuneiform bone: the dorsal being the stronger; the *interosseous* ligaments connect the semilunar with the bones on each side of it (Fig. 145).

The *pisiform bone* is articulated to the palmar surface of the cuneiform bone, to which it is united by a fibrous capsule. Inferiorly, it is attached by two strong ligaments, the one to the unciform bone, the other to the carpal end of the fifth metacarpal bone. This articulation has a distinct synovial membrane.

b. The *second row of carpal bones* is connected by three dorsal, three palmar, and two interosseous ligaments.

The *dorsal* and *palmar ligaments* pass transversely from one to the other. There are usually *two interosseous ligaments*, one on either side of the os magnum; sometimes there is a third, between the trapezium and trapezoid bones; they are thicker and stronger than those of the upper row, and unite the bones more firmly together.

c. The first row of carpal bones is arranged in the form of an arch, so as to receive the corresponding surfaces of the os magnum and unciforme. External to the os magnum, the trapezium and trapezoid bones present a slightly concave surface, which articulates with the scaphoid. In this way a joint, admitting of flexion and extension only, is formed between the upper and lower row.

The *two rows of carpal bones* are connected together by palmar and dorsal ligaments, and by an external and an internal lateral ligament.

The *palmar ligaments* consist of strong ligamentous fibres, which pass obliquely from the bones of the first to those of the second row.

The *dorsal ligaments* consist of oblique and transverse fibres which connect the dorsal surfaces of the bones of the upper with the lower row.

The *external lateral ligament*, very distinct, passes from the scaphoid to the trapezium: the *internal lateral ligament* from the cuneiform to the unciform.

Divide the ligaments to see the manner in which the carpal bones articulate with one another. Their surfaces are crusted with cartilage, and have a *common synovial membrane* which is very extensive and lines the distal surfaces of the scaphoid, semilunar, and cuneiform bones; it then passes forwards between the trapezium and trapezoid, the trapezoid and os magnum, the os magnum and the cuneiform to the articulations between the second row of carpal bones and the metacarpal bones of the four fingers (Fig. 145).

Joints between
Trapezium and
the First Meta-
carpal Bone.

The trapezium presents a cartilaginous surface, convex in the transverse, and concave in the antero-posterior direction (*i.e.* saddle-shaped), which articulates with the cartilaginous surface on the metacarpal bone of the thumb, concave and convex in the opposite directions. This peculiar adaptation of the two surfaces permits the several movements of the thumb—viz., flexion, extension, abduction, and adduction; consequently circumduction. It is an arthrodial joint, but permits of such extensive movement, that it is described by some anatomists as one by "reciprocal reception." Thus we are enabled to oppose

*the thumb to all the fingers, which is one of the great characteristics of the human hand. The joint is surrounded by a *capsular ligament* sufficiently loose to admit free motion, and stronger on the dorsal than on the palmar aspect. The security of the joint is increased by the muscles which surround it. It has a *separate synovial membrane*.

Carpo-metacarpal Joints.

The metacarpal bones of the fingers are connected to the second row of the carpal bones by ligaments upon their *palmar* and *dorsal* surfaces, and by interosseous ligaments.

The *dorsal* ligaments are the stronger. The metacarpal bone of the forefinger has two: one from the trapezium, the other from the trapezoid bone. That of the middle finger has also two, proceeding from the os magnum and the os trapezoides. That of the ring finger has also two, proceeding from the os magnum and the unciform bone. That of the little finger has one only, from the unciform bone.

The *palmar* ligaments are arranged nearly upon a similar plan. The metacarpal bone of the forefinger has one from the trapezoid bone. That of the middle finger has three, proceeding from the trapezium, the os magnum, and the unciform bone. Those of the ring and little fingers have each one, from the unciform bone.

Besides the preceding ligaments, there are some of considerable strength, called the *interosseous*. They proceed from the adjacent sides of the os magnum and the os unciforme, descend vertically, and are fixed into the radial side of the metacarpal bone of the middle and ring fingers (Fig. 145). This ligament occasionally isolates the synovial membrane of the two inner metacarpal bones from the common synovial membrane of the carpus.

Separate the metacarpal bones from the carpus, and observe the relative form of their contiguous surfaces. The metacarpal bones of the fore and middle fingers are adapted to the carpus in such an angular manner as to be almost immovable. The metacarpal bone of the ring finger, having a plane articular surface with the unciform bone, admits of more motion. Still greater motion is permitted between the unciform and the metacarpal bone of the little finger, the articular surface of each being slightly concave and convex in opposite directions. The greater freedom of motion of the metacarpal bone of the little finger is essential to the expansion and contraction of the palm.

The *carpal extremities of the metacarpal bones of the fingers* are connected with each other by *palmar* and *dorsal transverse ligaments*. They are also connected by *interosseous* ligaments, which extend between the bones, immediately below their contiguous cartilaginous surfaces.

The *distal extremities* of these bones are loosely connected on their palmar aspect by the *transverse metacarpal* ligament.

Synovial Membranes of the Wrist.

There are five, sometimes six, distinct synovial membranes, proper to the lower end of the radius, and the several bones of the carpus (Fig. 145, p. 389) as follows:—

- a. One between the lower end of the radius and the ulna.
- b. One between the radius and the first row of carpal bones.
- c. One between the trapezium and the metacarpal bone of the thumb.
- d. One between the cuneiform and pisiform bones.
- e. One between the first and second rows of carpal bones (the intercarpal joint). This extends to the metacarpal bones of the four inner fingers.

The interosseous ligament between the os magnum and ring finger occasionally shuts off the synovial membrane between the unciform and two inner metacarpal bones from the large intercarpal sac; thus making the sixth distinct synovial membrane.

First Joint of the Fingers.

The first phalanx of the finger presents a shallow oval cavity, crusted with cartilage, with the broad diameter in the transverse direction, to articulate with the round cartilaginous head of the metacarpal bone, of which the articular surface is elongated in the antero-posterior direction, and of greater extent on its palmar than its dorsal aspect. This formation of parts permits flexion of the finger to a greater degree than extension; and also a slight lateral movement.

Each joint is provided with two strong *lateral* ligaments, and an anterior or *palmar* ligament.

The *lateral ligaments* arise from the tubercles on either side of each metacarpal bone, and, inclining slightly forward, are inserted into the sides of the base of the first phalanx of the finger.

The *anterior (glenoid) ligament* is a thick, compact, fibrous structure, which extends over the palmar surface of the joint between the lateral ligaments. Its distal end is firmly attached to the base of the first phalanx of the finger; its proximal end is loosely adherent to the rough surface above the head of the metacarpal bone. On either side it is inseparably connected with the lateral ligaments, so that with them it forms a strong capsule over the front and sides of the joint. Its superficial surface, firmly connected with the transverse ligament, is slightly grooved for the play of the flexor tendons; its deep surface is adapted to cover the head of the metacarpal bone. Two sesamoid bones are found in the palmar ligament belonging to the joint between the metacarpal bone and the first phalanx of the thumb.

The palmar ligaments have a surgical importance for the follow-

- ing reason: In dislocation of the fingers, the facility of reduction mainly depends upon the extent to which the glenoid ligament is injured. If it be much torn, there is but little difficulty: if entire, the reduction may require much manipulation.

These joints are secured on their dorsal aspect by the extensor tendon, and the expansion proceeding from it on either side. Their synovial membranes are loose, especially beneath the extensor tendons.

**Second and Last
Joint of the
Fingers.**

The corresponding articular surfaces of the phalanges of the fingers and thumb are so shaped as to form a hinge-joint, and, therefore, incapable of lateral movement. The ligaments connecting them are similar in every respect to those between the metacarpal bones and the first phalanges. The palmar ligament of the last joint of the thumb generally contains a sesamoid bone.

The wrist-joint is a complex articulation, in which the seat of movement is partly in the radio-carpal, and partly in the inter-carpal articulation. Thus the hand at the radio-carpal joint is capable of extension (dorsi-flexion) and flexion, the latter being the most free; it is also capable of adduction (ulnar flexion) and of abduction (radial flexion) to a lesser extent. Between the carpal bones and carpo-metacarpal bones, the movement which takes place when the hand is pressed down so as to support the weight of the body, is that of separation of the anterior part of their apposed surfaces; undue separation being prevented by the interosseous and palmar ligaments. The articulation between the unciform and fourth and fifth metacarpals is not so firm as that between the other carpo-metacarpal bones, consequently there is greater freedom of motion forwards, seen in deepening the palm and in shutting the hand. The movements at the metacarpo-phalangeal articulation are those of extension and flexion, of adduction and abduction, the two latter being most marked in extension of the finger. Between the thumb and trapezium all the movements of an enarthrodial joint exist, except that of rotation; a little rotation probably takes place when the metacarpal bone is flexed. In the interphalangeal and phalangeal joints, the only movements permitted are those of extension and flexion.

DISSECTION OF THE ABDOMEN.

The body should be sufficiently raised by placing blocks beneath the buttocks and the shoulders, care being taken to have the chest higher than the pelvis.

Surface Marking.

In the middle line, extending from the ensiform cartilage to the symphysis pubis, is a groove caused by the linea alba, the line of union of the aponeuroses of the abdominal muscles. In this middle line, nearer the os pubis than the ensiform cartilage, is the umbilicus, which corresponds as a rule with the body of the third lumbar vertebra. The recti muscles can be distinguished on each side of the middle line, and in well-developed subjects, with little fat, the lineæ transversæ may be recognized, the lowest one being at the umbilicus, the highest on a level with the ensiform cartilage, and the third one midway between the two. On the outer border of the rectus, about three inches (7.5 cm.) from the middle line, is a concave line, the linea semilunaris, corresponding to the separation of the aponeurosis of the abdominal muscles to form the sheath of the rectus. Above, and external to the spine of the os pubis, the external abdominal ring can be easily felt, the outer pillar being the stronger; on it rests the spermatic cord passing to the testis. Passing from the spine of the os pubis to the anterior superior spine of the ilium is a crescentic groove which indicates the line of Poupart's ligament, and which can be felt as a firm and slightly curved cord; at about half an inch (13 mm.) above the middle of the ligament is situated the internal abdominal ring, which cannot, however, be felt.

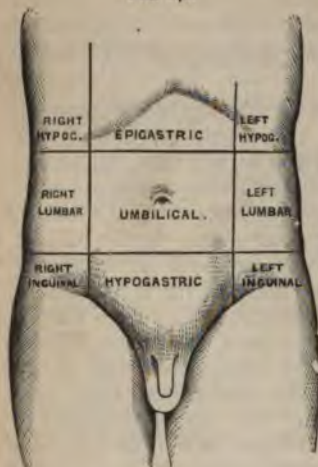
Arbitrary Division into Regions.

The abdomen is divided into arbitrary regions, that the situation of the viscera contained in it may be more easily described. For this purpose we draw the following lines: one horizontally across the abdomen on a level with the cartilages of the ninth ribs; another on a level with the anterior superior spines of the ilia. These lines form the boundaries of three spaces, each of which is subdivided into three regions by a vertical line drawn on each side from the cartilage of the eighth rib to the middle of Poupart's ligament.* Thus, there are a central and two lateral regions in each space. The cen-

* As there are at present fourteen methods of outlining the abdominal superficies, the one herein noted being so universally accepted, the American editor wishes to remind the student that the differences are but trivial. (A. H.)

tral region of the upper space is termed the *epigastric*; the central one of the middle space is called the *umbilical* region; and the central of the inferior space, the *hypogastric* region. The lateral regions of the spaces from above downwards are termed the right and left *hypochondriac*, the right and left *lumbar*, and the right and left *inguinal* or *iliac* regions, respectively.

FIG. 146.



The viscera contained in these respective regions are as follows:—

In the *epigastric region* are, the left lobe of the liver, the round ligament of the liver, a small part of the right lobe, the middle and pyloric end of the stomach, the lobulus Spigelii, the pancreas, and the upper border of the transverse colon.

In the *umbilical region* are, the transverse colon, the great omentum and mesentery, the round ligament of the liver, the transverse portion of the duodenum, and part of the jejunum and ileum.

In the *hypogastric region* are, the small intestines, the urachus, the two obliterated hypogastric arteries, the bladder naturally in early life, and in the adult if distended; and, lastly, the uterus in pregnancy.

In the *right hypochondrium* are, the right lobe of the liver, the base of the gall-bladder, the descending duodenum, the hepatic flexure of the colon, pancreas, supra-renal capsule, and the upper part of the right kidney.

In the *left hypochondrium* are, the cardiac end of the stomach, the greater part of the spleen, the tail of the pancreas, the splenic flexure of the colon, the supra-renal capsule, and the upper part of the left kidney.

In the *right lumbar region* are, the ascending colon, the lower part of the right kidney, and small intestines.

In the *left lumbar region* are, the descending colon, the lower part of the left kidney, omentum, and small intestines.

In the *right inguinal region* are, the cæcum and appendix vermiformis.

In the *left inguinal region* is the sigmoid flexure of the colon.

The abdomen should at this stage be distended with air by means of a blow-pipe inserted into the abdominal cavity through

the umbilicus, which, on the removal of the blow-pipe, should be tied with a string to prevent escape of the air.

Dissection.

An incision is to be made from the ensiform cartilage to the os pubis, another from the anterior superior spine of the ilium to a point midway between the umbilicus and os pubis, and a third from the ensiform cartilage, transversely outwards towards the axilla as far as the angles of the ribs. The skin should then be dissected from the subjacent adipose and connective tissue, called the superficial fascia.

Superficial Fascia. The subcutaneous tissue of the abdomen has the same general characters as that of other parts, and varies in thickness in different persons, according to the amount of fat. At the lower part of the abdomen, it admits of separation into two layers, between which are found the subcutaneous blood-vessels, the lymphatic glands, the ilio-inguinal nerve, and the hypogastric branch of the ilio-hypogastric nerve.

Respecting the superficial layer, observe that it contains the fat, and is continuous with the superficial fascia of the thigh, the scrotum, and the perineum. The deeper layer is intimately connected with Poupart's ligament and the linea alba; but it is very loosely continued over the spermatic cord and the scrotum, and becomes identified with the deep layer of the superficial fascia of the perineum. These points deserve attention, since they explain how urine, extravasated into the perineum and scrotum, readily makes its way over the spermatic cord on to the surface of the abdomen; but from this it cannot travel down the thigh on account of the connection of the fascia with Poupart's ligament.

Superficial Blood-vessels and Lymphatic Glands. Between the layers of the superficial fascia in the groin and upper part of the thigh are several lymphatic glands and small blood-vessels (Fig. 147). The glands are named, according to their situation, inguinal or femoral. The *inguinal*, from three to four in number, are often small, and escape observation. They are of an oval form, with their long axis corresponding to the line of the crural arch (represented by the dark line in Fig. 147). They receive the superficial lymphatics from the lower part of the wall of the abdomen, from the integument of the scrotum, penis, perineum, anus, and gluteal region, and are therefore generally affected in venereal disease. The lymphatics from the upper part of the abdominal parietes terminate in the lumbar glands.

The *superficial arteries* in the neighbourhood arise from the femoral. One, the *superficial epigastric*, ascends over Poupart's ligament and ramifies over the lower part of the abdomen, as high as the umbilicus, inosculating with the deep epigastric and internal mammary arteries; another, the *superficial external pudic*,

crosses the spermatic cord, and is distributed to the skin of the penis and scrotum, anastomosing with branches of the internal pudic; a third, the *superficial circumflexa ilii*, ramifies towards the spine of the ilium, and communicates with the deep circumflex iliac, the gluteal and external circumflex arteries. These subcutaneous arteries, the pudic especially, often occasion a free hæmorrhage in the operation for strangulated inguinal and femoral hernia.

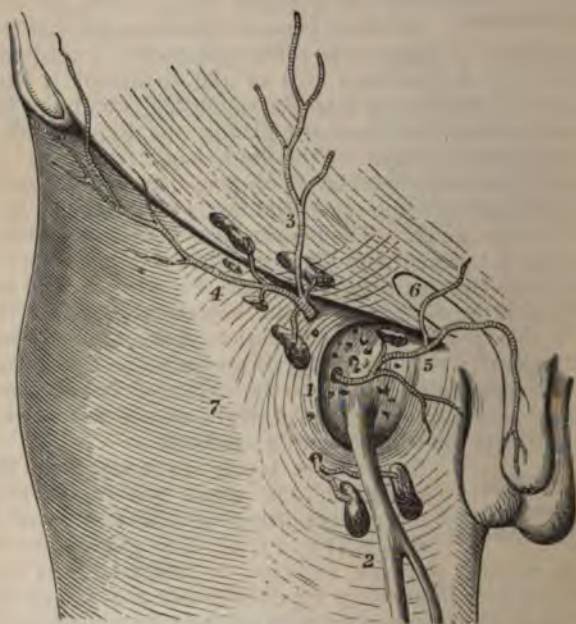


FIG. 147.—SUPERFICIAL VESSELS AND GLANDS OF THE GROIN.

1. Saphenous opening of the fascia lata. 2. Saphena vein. 3. Superficial epigastric a. 4. Superficial circumflexa ilii a. 5. Superficial external pudic a. 6. External abdominal ring.
7. Fascia lata of the thigh.

The corresponding *veins* join the internal saphena vein of the thigh. Under ordinary circumstances they do not appear in the living subject; but when any obstruction occurs in the inferior vena cava, they become enlarged and tortuous, and constitute the chief channels through which the blood would be returned from the lower limbs.

Cutaneous Nerves. The skin of the abdomen is supplied with nerves after the same plan as the chest—namely, by lateral and anterior branches derived from the five or lower intercostal nerves, as follows:—

The *lateral cutaneous nerves* come out between the digitations of the external oblique muscle, in company with small arteries, and divide, except the *5th dorsal nerve*, into anterior and posterior branches; the *anterior* pass forwards as far as the rectus, and are distributed to the skin as far as its outer border, and to the

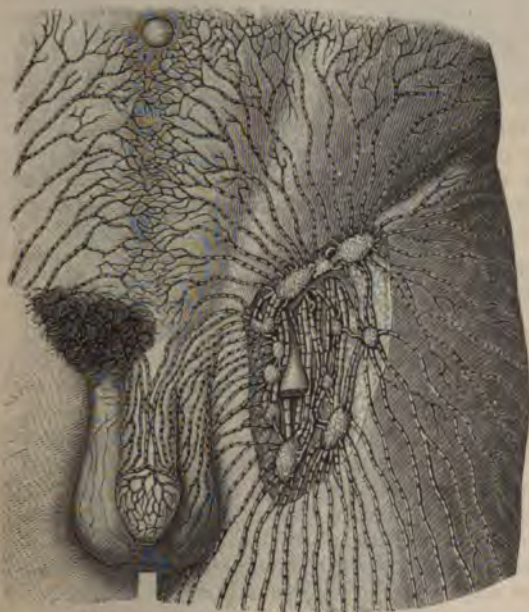

FIG. 148.—LYMPHATIC VESSELS AND GLANDS OF THE GROIN.

digitations of the obliquus externus muscle; the *posterior*, small in size, run backwards, and supply the skin over the latissimus dorsi. The *lateral branch* of the *5th dorsal nerve* is larger than the others, and, piercing both the oblique muscles, passes over the crest of the ilium to the skin of the buttock, without doing like the other nerves. The corresponding branch of the *first lumbar* has similar distribution.

The *anterior cutaneous nerves* emerge with small arteries through the sheath of the rectus. They are not only smaller than the lateral nerves, but their number and place of exit is less regular.

The *ilio-hypogastric nerve* comes from the first lumbar nerve, pierces the sheath of the external oblique at the iliac crest, and then divides into an iliac and hypogastric branch.

The *iliac branch* comes through both oblique muscles, and runs over the crest of the ilium, behind the last dorsal nerve, supplying the integument over the gluteal muscles.

The *hypogastric branch* lies at first between the transversalis and internal oblique; then, piercing the latter, it runs forwards and comes through the aponeurosis of the external oblique, just above the external abdominal ring, and is distributed to the skin in the neighborhood.

d. The *ilio inguinal nerve*, a branch also of the first lumbar nerve, is placed below the preceding nerve, with which it is connected near the crest of the ilium. It pierces the transversalis and internal oblique, runs down in the inguinal canal in front of the cord, and comes out through the external abdominal ring to be distributed to the skin of the inner part of the groin, to the scrotum and penis in the male, and to the labium pudendi in the female.

Dissection.

The deep layer of the superficial fascia should now be removed from the external oblique, by commencing at the fleshy portion of the muscle, and working in the course of its fibres. Care must be taken not to remove any of its silvery aponeurosis, which is very thin, especially above. The digitations of this muscle with the serratus magnus and latissimus dorsi must also be made out.

Muscles of the Abdominal Wall.

The abdominal muscles, three on each side, are arranged in strata, named, after the direction of their fibres, the external oblique, internal oblique, and transversalis. They terminate in front in strong aponeuroses, arranged so as to form a sheath for a broad muscle, called the rectus, which extends perpendicularly on each side the linea alba from the sternum to the os pubis.

External Oblique.

This muscle *arises* from the outer and lower surfaces of the eight or nine lower ribs, by as many pointed bundles, called *digitations*.* The upper five of these interdigitate with similar bundles of the serratus magnus; the three lower correspond in like manner with the origin of the latissimus dorsi; but they cannot be seen unless the body be turned on the side. The upper part of this muscle descends obliquely forwards, and terminates in the aponeurosis of the abdomen; the lower proceeds almost perpendicularly from the last ribs, and is *inserted* into the anterior half of the outer lip of the crest of the ilium.†

The *aponeurosis* of the external oblique increases in strength, breadth, and thickness, as it approaches the lower margin of the abdomen, this being the situation where the greater pressure of

* The upper digitations are attached to the ribs close to their cartilages; the lower ones to the ribs some distance from the cartilages; the last to the apex of the twelfth rib.

† From its position and the direction of its fibres, it is manifest that the external oblique represents, in the abdomen, the external intercostal muscles of the chest.

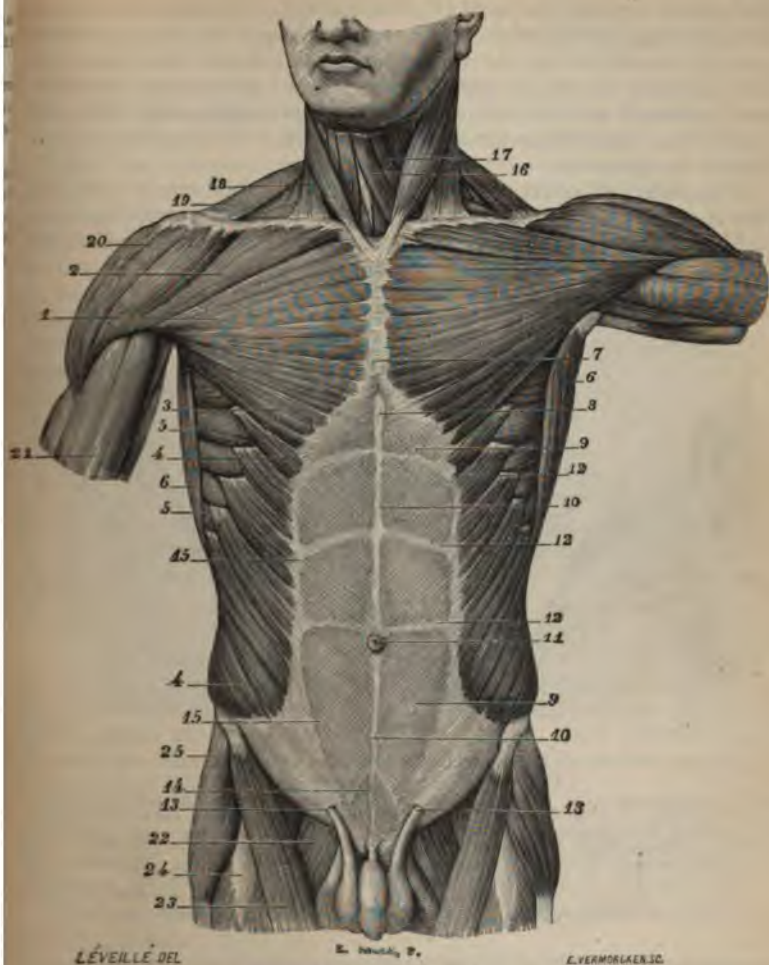


FIG. 149.—MUSCLES OF ANTERIOR PART OF THE TRUNK.

1. Pectoralis major. 2. Its clavicular portion. 3. Fasciculus which is attached to the abdominal aponeurosis. 4, 4. External oblique. 5, 5. Serratus magnus. 6, 6. Anterior border of the latissimus dorsi. 7. Fibrous lamina formed by the interlacing of pectoralis major. 8. Xiphoid appendix. 9, 9. Abdominal aponeurosis. 10, 10. Linea alba. 11. Umbilicus. 12, 12, 12. Linea transversæ. 13, 13. External inguinal opening transmitting the spermatic cord. 14. Pyramidalis abdominis. 15, 15. Border of the rectus abdominis. 16. Sterno-hyoid. 17. Omo-hyoid. 18. Sterno-cleido mastoid. 19. Cervical portion of the trapezius. 20. Deltoid. 21. Biceps. 22. Pectineus. 23. Sartorius. 24. Rectus femoris. 25. Tensor vaginae femoris.

the viscera requires the most effective support. Its tendinous fibres take the same direction as the muscle, and form by their decussation in the middle line the *linea alba*, which extends from the ensiform cartilage to the os pubis. Above, the aponeurosis becomes much thinner, and is continued on to the pectoralis major and the ribs. The lowest fibres are strong, and form a thick border, called Poupart's ligament.

The posterior border of this muscle is fleshy and nearly vertical, and is overlapped in its upper half by the latissimus dorsi.

The aponeurosis is perforated by numerous cutaneous vessels and

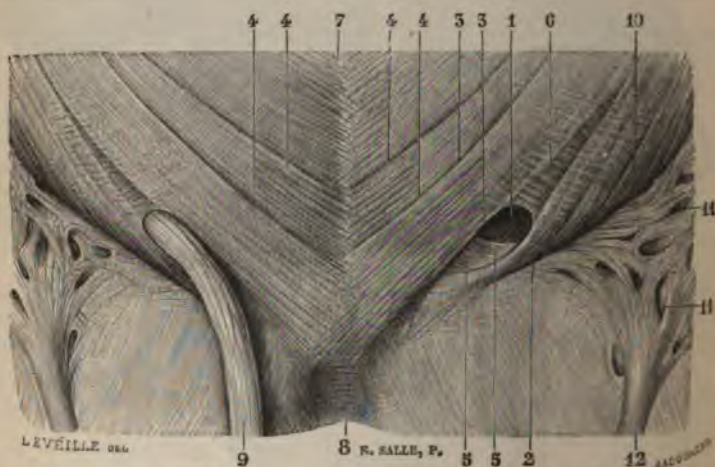


FIG. 150.—POUPART'S LIGAMENT, THE APONEUROSIS OF THE EXTERNAL OBLIQUE AND THE EXTERNAL ABDOMINAL RING.

1. External abdominal ring. 2. Its inferior or external pillar, curvilinear, attached to the spine of the pubis. 3. 3. Its superior or internal straight pillar, prolonged to the median line attached to the symphysis pubis, and interlacing with the one of the opposite side. 4. 4. Ligament of Colles, situated behind the preceding pillar and interlacing with it, attached to the crest of the pubis of the opposite side, thus forming an internal pillar. 5. 5. Attachment of Colles' ligament. 6. Arched fibres connecting the internal and external pillars, forming the external boundary of the ring. 7. Linea alba. 8. Symphysis pubis. 9. Spermatic cord. 10. Poupart's ligament. 11. 11. Cribriform fascia. 12. Internal saphenous vein.

nerves for the supply of the skin and subjacent tissues; at its lower and inner aspect, close to the spine of the os pubis, there is a large oval opening called the external abdominal ring, transmitting in the male the spermatic cord, and in the female the round ligament.

Poupart's Ligament, or Crural Arch. Along the line of junction of the abdomen with the thigh, the aponeurosis extends from the anterior superior spine of the ilium to the spine of the os pubis, and forms an arch over the intermediate bony

ion (Fig. 150). This, which is termed the *crural arch*, or, commonly, *Poupart's ligament*, transmits the great vessels of the thigh, with muscles and nerves.

The *external oblique ligament*, when not separated from its fascial connections, runs straight from the spine of the ilium to that of the os pubis, but is slightly curved, with its convexity towards the thigh, and somewhat to the outer side of the spine of the os pubis, and an opening in the aponeurosis, called the *external abdominal ring*. In the male it is a triangular opening about an inch long, with its base at the os pubis, and will admit the passage of a finger; it transmits the spermatic cord. In the female it is smaller, and transmits the round ligament of the uterus. Its position is downwards and inwards, and it is bounded below by the spine of the os pubis, above by some arched fibres which give rise to the apex of the opening, and on each side by the free ends of the aponeurosis which are termed its columns or pillars. The *inner or upper pillar* (No. 3) is thin, and is attached to the spine of the os pubis, decussating with its fellow of the opposite side at the symphysis. The *outer or lower pillar* is thicker and stronger, and has three attachments: one, into the spine of the os pubis, *Poupart's ligament* (No. 10); another, for three-quarters of an inch (18 mm.) along the linea ilio-pectinea—*Gimbernat's ligament*—the third—*Colles' or triangular ligament*—consists of a few fibres which pass obliquely upwards and inwards beneath the spermatic cord and the inner pillar as far as the linea alba, where they pass into a triangular fascia in front of the conjoined tendon, continuous with the aponeurosis of the opposite side. At the upper part of the aponeurosis of the external oblique, there are some arched fibres called *intercolumnar fibres*, which are strongest at the external ring. Their use is to strengthen the opening and prevent the ring from enlarging.

Attached to the pillars of the external ring is a thin fascia, the *transversalis or external spermatic fascia*, which is prolonged over the spermatic cord and testis, and thus forms one of the coverings of the organ.

The spermatic cord in its passage through the ring rests upon the inner pillar.

The external oblique should now be detached from the ribs and the crest of the ilium, and carried forwards as far as this can be done without injuring its origin or the crural arch. In detaching this muscle from the ribs it should be taken not to reflect with it the upper fibres of the external oblique, and as the dissection is carried forwards, the student should avoid injuring the thin aponeurosis of the internal oblique.

The second muscular stratum will thus be exposed and

recognized by the difference in the direction of its fibres, which run upwards and inwards.

Internal Oblique.

This is thinner than the last-named muscle, and arises by fleshy fibres from the outer half or more of Poupart's ligament, from the anterior two-thirds of the middle lip of the crest of the ilium, and from the posterior aponeurosis of the transversalis muscle (fascia lumborum). The fibres radiate from their origin, the anterior ones passing transversely forwards, the posterior ones ascending nearly vertically. The fibres

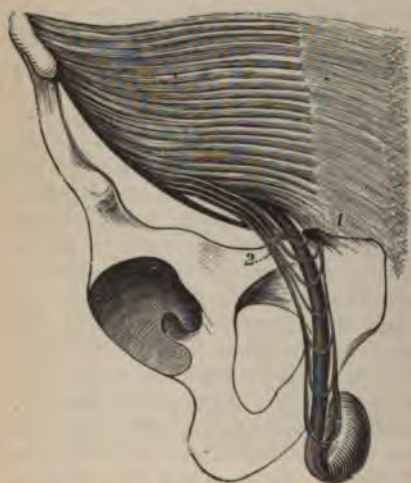

FIG. 151.—DIAGRAM OF THE LOWER FIBRES OF THE INTERNAL OBLIQUE AND TRANSVERSALIS, WITH THE CREMASTER MUSCLE.

1. Conjoined tendon of internal oblique and transversalis. 2. Cremaster muscle passing down in loops over the cord.

are inserted in the following manner: the anterior fibres (which arise from Poupart's ligament) pass inwards, and arch over the spermatic cord, descending somewhat to be inserted, in common with the tendon of the transversalis muscle, into the crest of the os pubis, and for a short distance into the linea ilipectinea immediately behind the external ring; the middle fibres (which arise from the anterior iliac spine and front of its crest) are directed transversely inwards, to be attached to an aponeurosis which passes to the linea alba; the posterior fibres ascend nearly vertically to be attached into the cartilages of the four lower ribs, and are

continuous with the internal intercostal muscles, which they represent in the abdomen.

The aponeurosis of the internal oblique is the broad expanded tendinous tissue into which the muscle is anteriorly attached, and is continued to the middle line, where its fibres join those of the opposite side at the linea alba. It extends from the chest to the os pubis, and its fibres run in the same direction as the muscle. At the outer border of the rectus it splits into two layers—an anterior, which passes in front of the rectus in conjunction with the aponeurosis of the external oblique; and a posterior, which, in common with the aponeurosis of the transversalis, passes behind the rectus.

The point of division of the aponeurosis presents a semilunar line extending from the os pubis to the cartilage of the eighth rib. This is called the *linea semilunaris*, through which a hernia occasionally protrudes. The two layers thus form a sheath for the rectus, which, except at the lower fourth behind, is complete. Midway

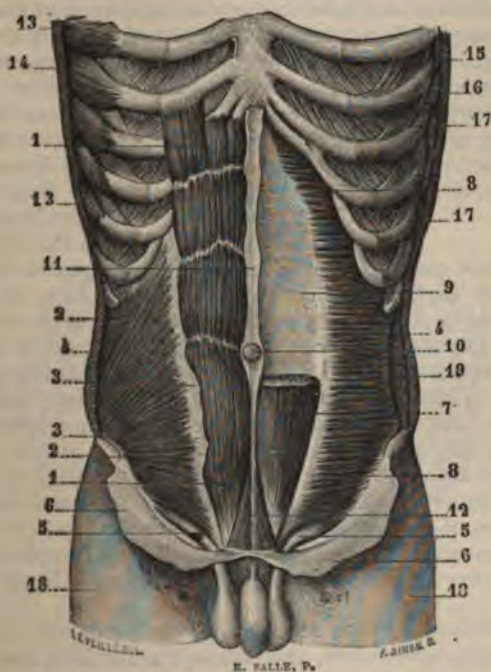


FIG. 152.—DEEP MUSCLES OF THE ABDOMINAL WALL.

1. Rectus abdominis. 2, 2. Internal oblique. 3, 3. Anterior leaflet of the aponeurosis of the internal oblique. 4, 4. Cut external oblique. 5, 5. Spermatic cord. 6, 6. Inferior part of the external oblique aponeurosis turned back on the thigh. 7. Rectus abdominis: the upper part has been excised to show the aponeurosis of the transversalis. 8, 8. Flemy portion of this muscle. 9. Its aponeurosis. 10. Umbilicus. 11. Linea alba above umbilicus. 12. Infra-umbilical linea alba separating below the two pyramidales. 13, 13. Serratus magnus. 14. Cut right latissimus dorsi. 15. Cut left latissimus dorsi. 16. Cut serratus magnus. 17. External intercostals. 18, 18. Femoral aponeurosis. 19. Cut internal oblique.

between the umbilicus and the os pubis, the aponeurosis of all the three muscles pass in front of the rectus, so that posteriorly in this situation it has no sheath. The lower free border of the posterior part of the sheath—the *semilunar fold of Douglas*—marks the situation where the deep epigastric artery enters the substance of the rectus.

Cremaster Muscle. The *cremaster* is a thin, pale muscle, or the reverse, according to the condition of the subject. It is best to regard it as a detachment of the lowest fibres of the internal oblique, which arise from the middle of Poupart's ligament. Passing along the outer side of the spermatic cord, the fibres descend with it through the external ring, and then arch up again in front of the cord to the spine and crest of the os pubis, forming loops of different lengths, some reaching only as low as the external ring, others lower still, whilst the lowest spread out over the tunica vaginalis of the testis. The muscular fibres are frayed out, being connected by loose cellular tissue, and form a covering for the testis, called the *cremasteric fascia*. This muscle is absent in the female. Its nerve comes from the genital branch of the genito-crural, and its artery (*cremasteric*) from the deep epigastric.

Dissection.

The student should not now further dissect the structures on the left side, so that they may be left till a future period for the complete demonstration of the parts concerned in inguinal hernia. On the right side, the internal oblique should be detached from the ribs and the crest of the ilium, and turned forwards, without disturbing that portion of it connected with the crural arch. To avoid cutting away any part of the transversalis in reflecting the internal oblique, dissect near the crest of the ilium, and search for an artery which runs between these muscles, and may be followed as a guide. This artery, called the *deep circumflexa ilii*, is a branch of the external iliac, and supplies the abdominal muscles. Beneath the internal oblique the continuations of the intercostal nerves and vessels are brought into view, as are also the last dorsal, the ilio-hypogastric, and ilio-inguinal nerves near the crest of the ilium. These should be preserved.

The internal oblique is in relation, on its deeper surface with the transversalis abdominis, the fascia transversalis, and with the spermatic cord near Poupart's ligament; on its inner side, at the division of its aponeurosis, with the outer border of the rectus; below, it forms the upper arched boundary of the inguinal canal.

Transversalis Abdominis.

This muscle *arises* by fleshy fibres from the outer third of Poupart's ligament, from the anterior two-thirds of the inner lip of the crest of the ilium, from a strong fascia attached to the transverse processes of the lumbar vertebræ, and, lastly, from the inner surfaces of the six or seven lower costal cartilages, by digitations which correspond with those of the diaphragm. From this origin the fibres pass horizontally forwards, and terminate anteriorly in a broad aponeurosis attached to its fellow at the linea alba. Some of its lower fibres arch downwards, and are inserted with some fibres

of the internal oblique by means of a conjoined tendon into the crest of the os pubis and the linea ilio-pectinea.

The aponeurosis into which the fibres are inserted is broader below than above, and forms a part of the posterior sheath of the rectus, excepting in the lower fourth, where it passes entirely in front.

In the dissection of the back we have fully described the lumbar fascia, showing that it divides into three layers: the posterior layer, attached to the tips of the spinous processes, gives attachment to the internal oblique, and is continuous with the aponeurosis of the serratus posticus inferior and latissimus dorsi; the middle layer attached to the tips of the transverse processes, and the anterior layer—very thin—attached to the anterior aspect of the bases of

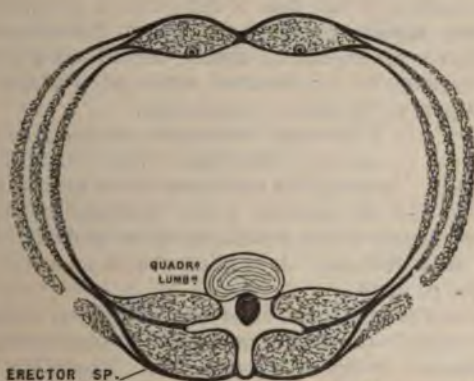

FIG. 153.—TRANSVERSE SECTION THROUGH THE ABDOMINAL MUSCLES TO SHOW THE FORMATION OF THE SHEATH OF THE RECTUS, THE QUADRATUS LUMBORUM, AND THE ERECTOR SPINAE.

the transverse processes. Between the anterior and middle layer is the quadratus lumborum; between the middle and posterior, the erector spinae.

Rectus Abdominis. This long muscle is situated vertically in front of the abdomen, and is enclosed in a sheath formed by the aponeuroses of the lateral muscles of the abdomen, and separated from its fellow by the linea alba. To expose it, therefore, slit up the middle of the sheath, and reflect the two halves. It *arises* by two tendons, the *inner* and *smaller* of which is attached to the front of the symphysis, the *outer* to the crest of the os pubis. As the fibres pass up, the muscle becomes broader and thinner, and is inserted into the fifth, sixth, and seventh costal

cartilages. Notice the tendinous intersections across the muscle called *linea transversæ*, which are incomplete repetitions of the ribs in the wall of the abdomen.* Their number varies from three to five, but there are always more above than below the umbilicus. These tendinous intersections adhere closely to the sheath in front, but not behind; consequently, pus formed between the front of the rectus and its sheath would be confined by two intersections; not so on the back of the muscle, where pus might travel down the entire length of it. There is one intersection on a level with the umbilicus, one on a level with the ensiform cartilage, and an intermediate one between these two.

The *sheath of the rectus* consists in front of the aponeurosis of the external oblique, and half the thickness of that of the internal oblique; while the back of the sheath comprises the aponeurosis of the transversalis, and half that of the internal oblique (Fig. 153). This, however, applies only to the upper three-fourths of the muscle; the lower fourth has no sheath behind, since all the aponeuroses pass in front of it; the only structure in contact with the muscle in this part is the fascia transversalis.

Pyramidalis. This small triangular muscle is situated near the os pubis, close to the linea alba, and has a sheath of its own. It *arises* by tendinous fibres from the front part of the os pubis and the anterior pubic ligament in front of the rectus, and terminates in the linea alba about midway between the os pubis and the umbilicus. It is often absent on one or even both sides (Fig. 152, p. 405).

Linea alba.—The aponeuroses of the abdominal muscles decussate along the middle line and form a white fibrous band, extending from the ensiform cartilage to the os pubis. This is the *linea alba*: it is the fibrous continuation of the sternum, and is broader above than below. A little lower than the middle is a large aperture in it—the *umbilicus*—through which a hernial protrusion not infrequently takes place. It is in relation behind with the fascia transversalis, the urachus, and the bladder when distended.

The linea alba, being the thinnest part of the abdomen, and free from large blood-vessels, is chosen as a safe line for tapping in dropsy, for puncturing the bladder in retention of urine, and for abdominal sections.

Linea semilunares.—These are the two slightly curved lines, on the front of the abdomen, corresponding with the outer margins of the two recti muscles. They are formed by the junction of the aponeurosis of the lateral muscles.

The abdominal muscles serve many important purposes:—

* Some animals, *e.g.*, the crocodile, have bony abdominal ribs.

Functions of the Abdominal Muscles. 1st. *In tranquil expiration* they push the diaphragm upwards by gentle pressure on the abdominal viscera.

In forcible expiration the same process takes place, but with greater energy. This is variously exemplified in coughing, sneezing, and laughing.

2d. *In vomiting*, the diaphragm being fixed* by the closure of the glottis, the abdominal muscles contract, and assist the stomach to expel its contents.

3d. In conjunction with the contracted diaphragm, they assist the muscular walls of the bladder and rectum in the expulsion of urine and fæces, and the action of the uterus in parturition. They exercise a gentle pressure and support on the abdominal viscera, and shield them from injury by strongly contracting when a blow is anticipated.

4th. They are movers of the trunk in various ways. For example, the right external oblique acting with the left internal oblique will rotate the chest towards the left side, as in mowing, and *vice versâ*.

The rectus is chiefly concerned in raising the body from the horizontal position, as anyone may ascertain by placing his hand on the abdomen while rising from the ground. The pyramidalis makes the *linea alba tense*.

Dissection.

By dividing the rectus transversely near the umbilicus, and raising it from its position, we have a complete view of the manner in which the sheath is formed: we observe, too, that this is absent behind the lower fourth of the muscle. Ramifying in the substance of the muscle is a large artery, called the *deep epigastric*, a branch of the external iliac; also the continuation of the internal mammary, which descends from the subclavian.

Nerves of the Abdominal Wall.

These nerves are the anterior divisions of the six lower intercostal nerves, and of the first lumbar. They have the same general course and distribution, and are accompanied by small arteries derived from the intercostal and first lumbar arteries.

The *intercostal* or *abdominal* nerves come forward beneath the anterior extremities of the intercostal spaces, and then run between the internal oblique and transversalis, towards the edge of the rectus, which they enter, small twigs coming through it at the middle line to supply the skin. Each gives off a *lateral cutaneous branch*, which perforates the external intercostal and external oblique muscles, and divides, into an *anterior* branch, distributed

* By the term "fixed," it is meant that the diaphragm forms a resisting surface.

to the skin and superficial fascia as far as the rectus, and into a *posterior* branch, smaller than the anterior, which supplies the skin over the latissimus dorsi.

The *last dorsal nerve*, larger than the other intercostals, is continued forwards beneath the last rib, lying on the quadratus lumborum, and then, piercing the transversalis aponeurosis, runs between this muscle and the internal oblique, and is finally distributed like the preceding nerves. Its *lateral cutaneous branch* is very large, and descends over the crest of the ilium.

The *ilio-hypogastric nerve*, a branch of the first lumbar, emerges from the outer border of the psoas, and then runs obliquely across the quadratus lumborum as far as the iliac crest, where it perforates the transversalis muscle and divides into an iliac and an hypogastric branch (p. 399).*

The *ilio-inguinal nerve*, smaller than the former, and, like it, a branch of the first lumbar, runs along the iliac crest after piercing the psoas, and is here connected with the ilio-hypogastric. It comes through the transversalis near the front of the ilium, and, after piercing the internal oblique, runs in front of the cord in the inguinal canal. Its cutaneous distribution has been described (p. 400).

Dissection.

The transversalis muscle must now be reflected with the rectus by incisions similar to those for the reflection of the external oblique, when a thin delicate fascia behind, the *fascia transversalis*, will be exposed. The dissection should take place from below upwards, as the muscle is less intimately connected with the fascia below than it is higher up.

Fascia Transversalis. This fascia separates the transversalis muscle from the peritoneum, and is so called because it lies in contact with the posterior surface of the muscle. It is comparatively thin, superiorly, where it is continuous with the fascia on the under surface of the diaphragm. Inferiorly, it is thick and strong, and is attached to the crest of the ilium and to Poupart's ligament, where it is strengthened by fibres from the aponeurosis of the transversalis; it becomes continuous with the fascia covering the iliacus muscle (iliac fascia), and below with the pelvic fascia. About the middle of Poupart's ligament it sends a funnel-shaped prolongation downwards into the thigh, forming the anterior part of the sheath of the femoral vessels. Internally, it is connected with the margin of the rectus, to the lower margin of the con-

* The ilio-hypogastric and ilio-inguinal nerves form important landmarks in operating upon the kidney, as the former crosses the perinephritic fat obliquely from within outwards and appears in the wound before the organ is reached. The latter nerve crosses the kidney lower than the former. (A. H.)

joined tendon, to the os pubis, and to the pectineal line. This fascia is strongest just behind the external abdominal ring, and, but for it and the conjoined tendon, there would be a direct opening into the abdominal cavity through the external ring. The outer half of the fascia is very firmly connected to Poupart's ligament and to the fascia iliaca; but the inner half is loosely connected with the crural arch, and passes down under it, as before stated, over the femoral vessels into the thigh, and forms the front of what is termed the crural sheath.

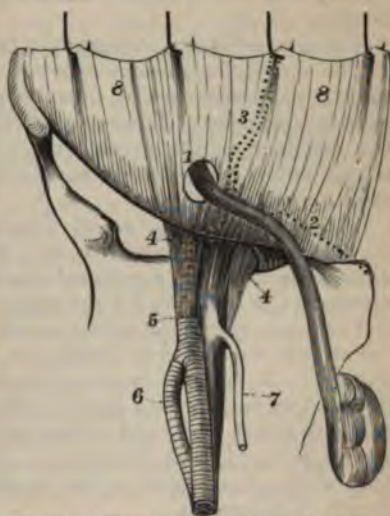

FIG. 154.—DIAGRAM OF THE FASCIA TRANSVERSALIS, SEEN FROM THE FRONT.

1. Internal abdominal ring. 2. Position of the external abdominal ring in dotted outline. 3. Epigastric a. in dotted outline. 4, 4. Sheath of the femoral vessels, continued from the fascia transversalis. 5. Femoral a. 6. Profunda a. 7. Saphena v. 8, 8. Fascia transversalis.

The opening in the fascia transversalis through which the spermatic cord passes is called the *internal abdominal ring* (or the inner aperture of the inguinal canal). It corresponds to a point midway between the anterior superior spine of the ilium and the spine of the os pubis, and about half an inch (13 mm.) above Poupart's ligament. It is oval with the long diameter nearly vertical; it is bounded above by the arched fibres of the transversalis muscle, and on the inner side by the deep epigastric vessels. Its margin is well defined on the inner, but not on the outer side, and from its border is continued forwards a funnel-shaped prolongation over the spermatic cord, which passes through the ring. This covering, thin and delicate, is termed the *infundibuliform fascia*. (This is not seen in the diagram.) Close by the inner border of the internal ring, the deep epigastric artery ascends to enter the substance of the rectus.

Arteries of the Abdominal Walls.

The abdominal walls are supplied with blood derived from the intercostal, lumbar, and deep circumflex iliac arteries, and in front also, from the internal mammary and deep epigastric arteries.

The *intercostal arteries* come from the descending thoracic aorta,

and, like their accompanying nerves, enter the abdominal wall between the transversalis and internal oblique muscles. They anastomose with the internal mammary, deep epigastric, and lumbar arteries.

The *lumbar artery* accompanies the last dorsal nerve.

The *internal mammary artery* divides, between the cartilages of the sixth and seventh ribs, into the musculo-phrenic and the superior epigastric arteries. The superior epigastric artery descends behind the cartilage of the seventh rib, and, piercing the sheath of the rectus, enters that muscle, supplying it and anastomosing with the deep epigastric.

The *musculo-phrenic artery* descends obliquely outwards behind the cartilages of the false ribs, and pierces the diaphragm about the ninth rib; it is then continued along the last intercostal space, and terminates in branches for the supply of the abdominal walls.

The *deep epigastric artery* arises from the external iliac, just before this vessel passes under the crural arch to take the name of femoral. It ascends inwards between the fascia transversalis and the peritoneum, forms a gentle curve on the *inner side* of the internal abdominal ring, and consequently on the inner side of the spermatic cord, and then enters the rectus muscle just below the fold of Douglas, which is the lower arched edge of the posterior sheath of the rectus.

The artery runs in the substance of the rectus parallel with the linea alba, and inosculates with the superior epigastric branch of the internal mammary artery. It is accompanied by two veins, of which the larger is on its inner side; these terminate in a single trunk in the external iliac vein.

The deep epigastric gives off the following branches:—

The *pubic* is the most important branch. It runs inwards, behind the crural arch, towards the os pubis, behind which it anastomoses with the pubic branch of the obturator. Sometimes the obturator artery is absent or small, in which case the pubic branch of the epigastric enlarges and takes the place of the absent vessel. It derives its chief practical interest from the fact that it is liable to be wounded in dividing the stricture in femoral hernia. But its size varies in different subjects, and is sometimes so small as to escape observation. The second branch is the *cremasteric*. It supplies the coverings of the cord, but chiefly the cremaster muscle. After giving off other unnamed *muscular branches*, some of which perforate the muscle to supply the skin, the main trunk terminates in the rectus by inosculations with the internal mammary.

Deep Circumflex Ilii. The *deep circumflex ilii* artery is a branch of the external iliac, just above the crural arch; it runs upwards and outwards, behind and parallel with Poupart's ligament, and at the middle of the crest of the ilium pierces the transversalis muscle, and, running in the same direction, lies between the transversalis and internal oblique. It anastomoses with

the ilio-lumbar artery, and sends small muscular branches, which run upwards, and communicate with the epigastric and the lumbar arteries.

The circumflex iliac veins join to form a single *vein*, which crosses the external iliac artery, and opens into the external iliac vein.

Dissection.

To see that part of the peritoneum concerned in inguinal hernia, the fascia transversalis must be removed by incisions similar to those recommended before. The fascia is easily separable from the peritoneum, which is situated immediately behind it, owing to the presence of more or less fat—*subperitoneal fat*. The peritoneum at the inner ring presents a well-marked depression, which varies, however, considerably, in some being scarcely visible, in others being continued downwards into the inguinal canal, in the form of a pouch. In some instances, a communication is found between the general cavity of the peritoneum and the tunica vaginalis testis.

Inguinal Canal.

Having examined the several strata through which the spermatic cord passes, replace them in their natural position, and examine the inguinal canal as a whole. Its direction is obliquely downwards and inwards. Its length in a well-formed adult male is from one and a half to two inches (*3.8 to 5 cm.*). It commences at the inner ring, and terminates at the external abdominal ring. It is bounded *in front* by skin, superficial and deep fasciæ, by the aponeurosis of the external oblique, and externally by a small portion of the internal oblique; *behind*, by the fascia transversalis, by the conjoined tendon of the internal oblique and transversalis, and by the triangular ligament; *above*, by the lower fleshy fibres of the internal oblique and transversalis; *below*, by the junction of the fascia transversalis with the crural arch.

Spermatic Cord.

This round cord extends from the testis to the internal abdominal ring, and consists of numerous structures, connected together by delicate areolar tissue, and is surrounded by the different strata from the abdominal muscles, which are pushed down in the descent of the testis into the scrotum in foetal life. The cord lies in the inguinal canal; at the outer ring it rests on the outer pillar, and at the inner ring the different constituents of the cord separate from each other.

The *arteries of the cord* are derived from the spermatic artery from the abdominal aorta, the deferential artery from the superior vesical, and the cremasteric branch from the deep epigastric.

The *veins of the cord* are chiefly the spermatic; they form on the cord a plexus of veins—the *pampiniform plexus*—and, passing up in front of the cord, open on the right side into the inferior vena cava; and on the left side, into the left renal vein.

The *lymphatics* pass into the lumbar glands.

The *nerves* are derived from the renal, aortic, and hypogastric plexuses. In front of the cord is the ilio-inguinal nerve, and behind it is the genital branch of the genito-crural nerve.

The cord, as will presently be described, receives coverings from the external oblique, from the internal oblique and transversalis, and from the fascia transversalis.

The *vas deferens*, the excretory duct of the testis, passes through the inguinal canal, being placed behind the other constituents of the cord, and after passing through the inner ring, curves round the epigastric artery in its descent into the pelvis.

Round Ligament. In the female there is a round cord occupying the inguinal canal—the *round ligament*—which is lost, external to the outer ring, in the subcutaneous tissues of the labium majus. Its coverings are the same as those of the male, excepting the cremasteric fascia.

Deep Crural Arch. This structure, which is apparently a thickening of the fascia transversalis, has more to do with femoral hernia, and its description will, therefore, be deferred until this form of hernia is considered in the dissection of the thigh.

DISSECTION OF THE PARTS CONCERNED IN INGUINAL HERNIA.

Dissection. The student has now completed the dissection on the right side, and, having mastered the general anatomy of this region, he may pass on to the special consideration of the anatomy of inguinal hernia. If the instructions before given have been duly observed, the left side is available for this purpose; and although it may be well that the dissector (especially for the first time) should have the advantage of the parts being made clear by his demonstrator, there is no real difficulty in making out the different layers which constitute the coverings of a hernia, or the various parts through which a hernia travels.

It will be remembered that on the left side the dissection has been carried as far as the exposure of the internal oblique and cremaster. An incision must now be made through the *external oblique*, from a point midway between the umbilicus and the os pubis, transversely outwards to the anterior superior iliac spine, and another from the same point downwards in the middle line through the linea alba as far as the symphysis pubis. When this flap has been turned downwards, the dissector will see that it is aponeurotic, and he can take the opportunity of making out the external abdo-

minal ring and the external spermatic fascia which is prolonged downwards from the pillars of the ring, as also the intercolumnar bands which strengthen the upper part of the ring.

The *internal oblique* now comes into view, and its origin from Poupart's ligament must be carefully made out, together with the cremaster muscle, which loops in front of the cord, and which can be seen coming under the arched fibres of this muscle. Next, the internal oblique should be reflected from Poupart's ligament and the iliac crest by a transverse incision to the extent of that through the external oblique. The flap should then be reflected inwards, care being taken not to reflect with it the subjacent muscle (*transversalis*); this may be prevented by looking for a branch of the deep circumflex iliac artery, which runs along the crest of the ilium between these muscles. The turning back of this muscle exposes the *transversalis*, which in its turn will be reflected inwards in the same manner. The inner parts of both these muscles are intimately connected by a common tendon, called the *conjoined tendon*, inserted in front of the rectus into the crest of the os pubis and the pectineal line. Observe that this tendon lies immediately behind the external abdominal ring, and that it varies in thickness in different subjects. The arching over of the lower fibres of the internal oblique and *transversalis*, so as to form the upper boundary of the inguinal canal, are now well seen.

Reflect the *transversalis* exactly in the same way as the internal oblique, when the fascia *transversalis* comes into view, presenting the funnel-shaped prolongation of fascia—*infundibuliform*—which is continued over the cord and testis.

The *transversalis fascia* should now be detached from the subjacent peritoneum, in front of which is more or less fat (*subperitoneal*), and turned down, when the internal abdominal ring becomes apparent, with its well-defined inner margin.

During the reflection of these successive muscles, the student will have been enabled to recognize the strata which are prolonged from them: viz., from the external oblique is derived the *spermatic fascia*; from the internal oblique and *transversalis* is derived the *cremasteric fascia*; and from the fascia *transversalis* is prolonged the *transversalis fascia*, which here takes the name of the *infundibuliform fascia*.

The extent and boundaries of the inguinal canal and the relation of the epigastric artery to the inner ring can now be clearly defined; and if the dissector passes his little finger into the internal abdominal ring, down the canal and out through the external ring, he will easily see that it carries before it the three strata previously described, which constitute not only the coverings

of the cord, but likewise the coverings* of an oblique hernia, when this exists.

Practical Application. The testis, originally formed in the abdomen, passes, about the eighth month of foetal life, from the abdomen into the scrotum, through an oblique opening in the wall of the abdomen, called the inguinal canal. A portion of the peritoneum is pouched out before the descending testis, and constitutes the tunica vaginalis testis. The blood-vessels, nerves, and vas deferens are drawn down with the testis, and constitute the spermatic cord. The inguinal canal runs obliquely through the abdominal wall, that it may the better resist the pressure of the intestine.

The wall of the abdomen, as previously stated, is composed of various strata, and the testis and cord in their passage through the inguinal canal derive from each a covering similar in structure to the stratum itself. Of these strata there are three: the first, proceeding from within outwards, is the *fascial stratum* derived from the fascia transversalis; the second is the *muscular stratum* derived from the external oblique muscle; the third is the *aponeurotic stratum* from the external oblique aponeurosis.

The passage of the testis through the lower part of the inguinal parietes (inguinal canal) occasions, at this part of the abdomen, a natural weakness which, associated with other conditions, gives rise to the protrusion of intestine in this situation.

A protrusion of intestine through any part of the inguinal canal is called an *inguinal hernia*: of which two chief varieties are the *indirect or oblique*, and the *direct*; the former protrudes through the outer side of the deep epigastric artery; the latter comes out through the inner side of the artery.

**Oblique Inguinal
Hernia.**

The most common form of inguinal hernia is that in which a portion of intestine protrudes first through the internal ring, then, through the inguinal canal, emerges through the external ring, and may descend into the scrotum. This variety is called an *inguinal hernia*.† If the intestine stops within the inguinal canal it is called an *incomplete inguinal hernia*; if, however, the protrusion has emerged through the external ring, it is called an *inguinal hernia*; and, lastly, if it descends into the scrotum it is called a *scrotal hernia*.

* In the case of a hernia there is necessarily in addition a covering of peritoneal fat, and of peritoneum which forms the sac.

† A hernia is sometimes called *external or internal*, according to the position of the protrusion to the deep epigastric artery: thus, an oblique inguinal hernia which first protrudes through the inner ring is called an *external* hernia, and vice versa.

Coverings of an Oblique Inguinal Hernia. A complete oblique inguinal hernia, passing as it does through the same structures as the testis did in foetal life, receives the same coverings as

that gland; they are:—

1. The *skin* and the *superficial fascia*.
2. The *intercolumnar fascia* derived from the external oblique.
3. The *cremaster*, derived from the internal oblique and transversalis.*
4. The *infundibuliform fascia*, derived from the fascia transversalis.
5. The *subperitoneal fat* and the *peritoneum* which constitutes the sac.

An *incomplete* oblique inguinal hernia is covered by—

1. The *skin* and *superficial fascia*.
2. The *aponeurosis* of the *external oblique*.
3. The *cremaster*.
4. The *infundibuliform fascia*.
5. The *subperitoneal fat* and the *peritoneum*.

Direct Inguinal Hernia.

The intestine, however, does not always escape through the internal ring. Sometimes it protrudes *internal* to the deep epigastric artery through a triangular weak place, *Hesselbach's triangle*, bounded on the inner side by the rectus, on the outer side by the deep epigastric artery, and below by Poupart's ligament. This space is relatively weak, having in front of it only the fascia transversalis and the conjoined tendon of the internal oblique and transversalis; moreover, it is situated immediately behind the external abdominal ring. A portion of intestine protruding through this triangle comes directly forwards through the external ring, and the hernia is then called a *direct inguinal hernia*.

Coverings of a Direct Inguinal Hernia.

A *direct* inguinal hernia protrudes immediately on the inner side of the epigastric artery through the external ring; and its course forwards is mainly prevented by the resistance of the conjoined tendon. † This hernia is covered by—

1. The *skin* and *superficial fascia*.
2. The *intercolumnar fascia*. ‡
3. The *conjoined tendon* of the internal oblique and transversalis.

* The cremaster muscle is absent in the female.

† In our experience the weakness of the conjoined tendon is, anatomically speaking, the determining cause of this form of hernia.

‡ As the cremasteric fascia or muscle is already present outside the external abdominal ring, it should be enumerated as one of the coverings in direct hernia as well as in oblique. (A. H.)

4. The *fascia transversalis*.
5. The *subperitoneal fat* and the *peritoneum*.

A direct hernia, as has been said, emerges through Hesselbach's triangle, and if this triangle be viewed from its deeper aspect, it will be seen that, usually, the obliterated hypogastric artery corresponds in its course to the deep epigastric artery. Occasionally, however, it is placed further inwards, so that it divides the triangle into two smaller ones, in both of which there is a shallow pouching of peritoneum. Now, if a direct hernia protrudes through the outer of these two smaller triangles, it descends through the inguinal canal, and thus will have all the coverings of an ordinary oblique inguinal hernia.

In almost all cases, the immediate investment of the intestine is the parietal layer of the peritoneum. This constitutes the *sac* of

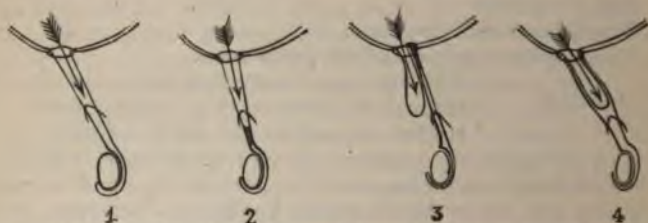


FIG. 155.—VARIETIES OF CONGENITAL INGUINAL HERNIÆ, CONSEQUENT UPON SOME DEFECT IN THE DEVELOPMENT OF THE SPERMATIC PORTION OF THE TUNICA VAGINALIS. THE ARROWS MARK THE PROTRUSION.

1. Hernia in the tunica vaginalis testis.
2. Hernia in the funicular portion of the tunica vaginalis.
3. Infantile hernia.
4. Encysted hernia.

the hernia. The opening of the sac, communicating with the abdomen, is called its *mouth*; then comes the narrow, constricted portion, or *neck*; and lastly, the *body*, or expanded part of the sac.

Congenital Hernia. Owing to the comparatively late descent of the testis in foetal life, it frequently happens that either no closure, or only a partial closure, takes place in the vaginal portion of the tunica vaginalis. Under these conditions, when a protrusion takes place, the intestine does not push forwards a sac derived from the parietal layer of the peritoneum, but it lies in a sac formed by the tunica vaginalis, which still communicates with the peritoneal cavity. These herniæ are always oblique, and are termed *congenital*.* There are four varieties, all of which are the

* The term *congenital* applied to this form of hernia is apt to suggest the idea that it occurs at birth. But this is not of necessity so. Although the state of parts favorable to its occurrence exists at birth, the hernia itself may not take place till many years afterwards—in fact, at any period of life.

result of, or associated with, some congenital defect. They are as follows:—

1. *Hernia in the tunica vaginalis testis*.—This occurs when a protrusion of intestine takes place through the narrow canal which persists between the general cavity of the peritoneum and the tunica vaginalis testis, in consequence of the non-obliteration of the original communication between them. In this case the intestine surrounds the testis, and the sac is formed by the tunica vaginalis testis (Fig. 155, 1).

2. *Hernia in the funicular portion of the tunica vaginalis* occurs when an incomplete closure of the tunica vaginalis takes place immediately above the testis; the canal above it being still unclosed and communicating with the peritoneal cavity. The sac is formed by the original pouch of the peritoneum in the descent of the testis, although shut off from the tunica vaginalis testis by a thin septum (Fig. 155, 2).

3. *Infantile hernia* is rare, and occurs when the original peritoneal canal is occluded at the inner ring, so that the tunica vaginalis testis reaches up as high as the canal, or even as far as the internal ring. The intestine in this variety protrudes a sac through the inner ring, but behind this abnormal extension of the tunica vaginalis; so that in front of the hernia there are three layers of peritoneum: two formed by the tunica vaginalis, the third by the sac (Fig. 155, 3).

4. *Encysted hernia* is still rarer than the preceding, and may occur in those cases in which the closing septum at the internal ring is so thin that an advancing hernia pushes before it this thin stratum (which forms its sac) as a diverticulum into an unclosed tunica vaginalis (Fig. 155, 4).

Position of Spermatic Cord. The spermatic cord is generally situated behind and to the outer side of a hernial sac. In some cases, however, the hernia separates the constituents of the cord, so that one or the other of these comes to lie in front of the protrusion.

Seat of Stricture. The stricture may be seated either at the external ring, the internal ring, at any intermediate part between these, or at the neck of the sac. Sometimes there is a double stricture, one at the external ring, the other at the internal.

As stated, the stricture may be caused by the neck of the sac, independently of the parts outside it; for the peritoneum may become thickened and indurated, and sufficiently unyielding to strangulate the protruded intestine. The strangulation in a congenital hernia is nearly always caused by the neck of the sac itself.

In dividing the stricture, the surgeon should, in all cases, adhere to the golden rule laid down by Sir Astley Cooper—namely, to divide it directly upwards. In this direction there is the least likelihood of wounding the deep epigastric artery.

Changes produced by an Old and Large Hernia. Whoever has the opportunity of dissecting an old hernia of some size, will observe that the obliquity of the inguinal canal is destroyed.

The constant dragging of the protruded viscera upon the inner margin of the internal ring gradually approximates

the internal ring to the external, so that at last the one gets quite behind the other, and there is a direct opening into the abdomen. But the position of the deep epigastric artery with regard to the sac remains unaltered. It is still on the *inner side* of the neck of the sac.

In a hernia of long standing all its coverings undergo a change. They become thickened and hypertrophied, and so altered from what they once were that they scarcely look like the same parts.

Umbilical Hernia. This is a hernia which protrudes through the umbilical opening in the middle line at the umbilicus, and is most commonly met with in infant life, and in the female sex in advanced life, especially in obese subjects. The hernia is frequently large, and, in its enlargement, it increases in an upward direction, so that the aperture, through which it comes, is not in the centre of the hernia.

Its coverings are skin, subcutaneous fat and connective tissue, a thin fascia which covers the umbilical aperture, fascia transversalis, subperitoneal fat, and peritoneum.

The seat of strangulation in this variety of hernia is the fibrous margin of the umbilical aperture. This must be divided, and, as there are no vessels or other structures of importance near it, the margin may be divided at any part most convenient to the operator. Owing to the size which umbilical herniæ frequently attain, it is not always easy to divide the constricting margin, and great care is needed to prevent the intestines being injured during the operation.

Ventral Herniæ. This term is applied to those forms of hernia which protrude through the abdominal walls in situations not included in the inguinal and umbilical varieties. The most common variety is that which comes through the linea alba, usually above the umbilicus. They are small and mushroom-shaped, with narrow pedicles, and are commonly irreducible. In some cases these protrusions are masses of subperitoneal fat, emerging through foramina in the linea alba, growing after they protrude; so that these are not herniæ in the strict sense of the term. Ventral herniæ occasionally come through the linea semilunaris; others come through the triangular interval between the latissimus dorsi and posterior free border of the external oblique, and are termed *lumbar herniæ*. There is, in fact, no part of the abdominal walls through which a hernia may not protrude.

Dissection. Expose the contents of the abdomen, by an incision from the ensiform cartilage to the os pubis a little to the left side of the linea alba, so as to preserve a ligament, *ligamentum teres*, which passes from the umbilicus to the liver, and also a cord, the *urachus*, which ascends in the middle

line from the bladder to the umbilicus; then make another incision transversely on a level with the umbilicus, and turn the flaps outwards.

Urachus.

Behind the linea alba, the peritoneum is raised into a fold by a fibrous cord, passing from the bladder to the umbilicus; this is the *urachus*, which in foetal life is a tube connecting the bladder with the allantois. On either side of the urachus are two other folds, enclosing cords which ascend obliquely towards the umbilicus: these are the impervious remains of the *hypogastric arteries*.

On opening the cavity of the peritoneum, there are seen, in connection with the fibrous cords just mentioned, two fossæ in the neighbourhood of Poupart's ligament—one on the inner side, the other on the outer side of the obliterated hypogastric artery. The depth of these fossæ depends upon the tension of this cord; so that, while sometimes they are scarcely visible, at others they are deep and well-marked. They are of importance, since they correspond with the internal and external abdominal rings; hence, the greater depth of one or other hollow may determine the locality of the protrusion of a hernia. Occasionally the deep epigastric artery lies nearer the middle line than it normally does, so that we may have three pouches instead of two, through either of which a hernia may emerge.

The abdominal cavity is seen to be composed of two divisions—an upper or abdomen proper, and a lower or the pelvis. It is the upper division that we are about to describe.

Take now a survey of the viscera before they are disturbed from their relative positions.

What is seen on opening the Abdomen. In the right hypochondrium, the right lobe of the liver is seen projecting more or less below the cartilages of the ribs, and the fundus of the gall-bladder below the edge of the liver, near the end of the ninth costal cartilage. In the left hypochondrium is seen more or less of the stomach according to its distension. Across the umbilical region extends a broad fold of the peritoneum containing fat, the great omentum, which descends from the lower curvature of the stomach, forming a curtain over the convolutions of the small intestine. The breadth of this fold varies; sometimes being so shrunk and crumpled as to be scarcely visible. The lower part of the abdomen and part of the pelvis are occupied by the small intestine. The urinary bladder is not apparent, unless distended sufficiently to rise out of the pelvis. In the right iliac fossa is the caput coli, the commencement of the large intestine; but the ascending part of the large intestine in the right lumbar region, and the descending part of it in the left, are not visible unless distended; they lie con-

tracted at the back of the abdomen. Such are the viscera usually seen on opening the abdomen; but a certain latitude is to be allowed, as sometimes more of one organ is seen and less of another, according as this or that is distended or hypertrophied. Much also depends upon the amount of pressure which the ribs have undergone during life.

**Particular Position
of each Viscus.**

The position of each viscus should now be examined separately, and first that of the stomach.

The Stomach.

The *stomach* is irregularly conical in shape. It is placed obliquely, the smaller or pyloric end being the lower; its great end is situated in the left hypochondrium; its narrow or pyloric end extends obliquely across the epigastrium into the right hypochondrium, where it is overlapped by the liver.

The left or cardiac end is situated behind the ribs, and in contact with the concavity of the spleen, to which it is connected by a fold of peritoneum. In front it has the abdominal wall, above it has the liver and the diaphragm, and below it is the transverse colon; the right or pyloric end extends to the gall-bladder, and is in contact with the under aspect of the liver, where it is continuous with the duodenum; posteriorly, it rests on the pancreas, the aorta, and the two crura of the diaphragm. The stomach is connected with other viscera by the following peritoneal folds: (1) the great omentum, attached to its lower convex border, forms a curtain of fat, more or less thick, in front of the transverse colon and small intestines; (2) the gastro-hepatic or lesser omentum, which connects the lesser curve of the stomach with the transverse fissure of the liver; and (3) the gastro-splenic omentum, which connects the cardiac end of the stomach with the hilum of the spleen. The relative position and size of the stomach vary according to the amount of distention: when much distended, the anterior surface, owing to the greater mobility of the great curve and the pyloric end of the stomach, is turned upwards, and the lower border forwards.*

Duodenum.

The first part of the intestinal canal is termed *intestinum duodenum*, because it is about the breadth of twelve fingers. Commencing at the pyloric end of the stomach, the duodenum ascends as high as the neck of the gall-bladder; then turning downwards it passes in front of the right kidney; lastly, making another bend, it crosses the spine obliquely towards the left side of the second lumbar vertebra. Here the

* Lesshaft states that the position of the stomach is *vertical*, and that when distended it does not alter its position, but that it is affected equally in all directions. (*Lancet*, March 11, 1882.) This opinion is not, however, generally entertained by anatomists.

stinum jejunum begins, and this part of the canal may be seen raising the transverse colon. Thus the duodenum describes a U of horse-shoe curve, of which the concavity is towards the left and embraces the large end or head of the pancreas. For convenience of description the duodenum is divided into an ascending, a descending, and a transverse portion. The first is completely surrounded by a peritoneal covering; the second and third are only covered by peritoneum in front, and are fixed to the back of the abdomen. The relative anatomy of the duodenum will be more fully seen hereafter (p. 442).

Jejunum and Ileum. Pursuing its course from the left side of the second lumbar vertebra, the intestinal canal describes a number of convolutions, occupying the lower regions of the abdomen, and which are loosely connected to the spine by a broad peritoneal fold termed the *mesentery*. Of these convolutions, the upper two-fifths constitute the *intestinum jejunum*; the lower three-fifths, the *intestinum ileum*. This is an arbitrary division. There is no definite limit; the character of the bowel gradually changes—that is, it becomes less vascular, has fewer folds of the mucous membrane, and its coats are therefore less substantial to the

Commencement of the Large Intestine. In the right iliac fossa, the small intestine opens into the left side of the cæcum, which is easily recognized by its sacculated appearance; here the large intestine begins, and it is guarded by the ileo-cæcal valve (Fig. 156). Immediately below the junction the large intestine is expanded into a blind pouch, about two and a half inches (6.3 cm.) in length and breadth, called the *cæcum* or *caput coli*. * Into the back part of this pouch opens a little tube, closed at the other end, called the *appendix vermiformis*. This tube varies in length from three to six (7.5 to 11 cm.) inches in length, † is about as thick as a large earthworm, and is either coiled up behind the cæcum, ‡ or lies below it, having a separate mesentery attached to the abdominal wall posteriorly, which allows the apex to be loose in the abdomen. It is hollow, and its opening into the cæcum is usually guarded by a valve of mucous membrane.

Out of seventy-four cases observed by the editor the colon occupied the iliac fossa in fifty-six; occupying the ventre and extending into the true pelvis in eighteen; attached to abdominal viscera in two. (*Amer. Jour. Med. Sc.*, Aug. 1857.) (A. H.)

Average length of vermiform appendix observed in 73 cases was 8.97 cm., a maximum of 17 cm., and a minimum of 2.5 cm. (A. H.)

Out of 71 cases the appendix was observed in the inner and posterior aspect of the colon in 56; on the inner in 8; on the posterior in 6; and on the inferior aspect in 1. (A. H.)

The large intestine is about four and a half to five feet (136.8 to 152.3 cm.) in length, and in its course it describes an arch which encircles the convolutions of the small intestines. It is largest at its commencement, and lessens in size until a

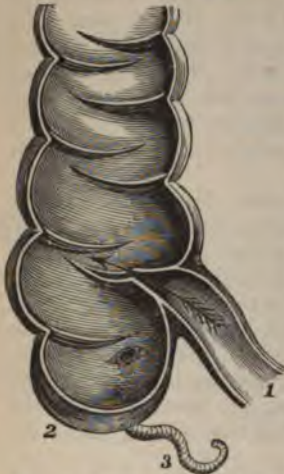

FIG. 156.—SECTION THROUGH THE JUNCTION OF THE LARGE AND SMALL INTESTINE TO SHOW THE ILEO-CÆCAL VALVE AND APPENDIX VERMIFORMIS.

1. Ileum. 2. Cæcum or caput coli.
3. Appendix vermiformis.

the upper part of the rectum it becomes narrowest; below this it again forms dilatation, the *ampulla*, just above its termination at the anus. It is successively divided into cæcum, ascending, transverse, and descending colon, sigmoid flexure and rectum. The commencement of the large intestine is generally confined by the peritoneum to the iliac fossa, in which it lies, being separated from the iliacus muscle by the iliac fascia and by more or less connective tissue and fat.* Tracing the large intestine from this point, it is continued as the *ascending colon*. We find it somewhat smaller than the cæcum, and it ascends through the right lumbar region in front of the right kidney as high as the under surface of the liver, where it abruptly makes a bend to the left side—the *hepatic flexure* of the colon: it then crosses the umbilical region transversely from right to left, and is known as the *transverse colon*. Reaching the left hypochondriac region, it makes a sharp bend downwards beneath the lower border of the spleen, forming the *splenic flexure* of the colon; † thence it descends in front of the left kidney, ‡ through the left lumbar region into the left iliac, as the *descending colon*. In the iliac fossa the intestine, as the *sigmoid flexure*, becomes narrow and makes a curve like the letter S. Lastly, the bowel enters the pelvis on the left side of the sacrum, and here takes the name of

* But this is not invariably so. The bowel is, in some subjects, connected to the fossa by a fold of peritoneum or a *meso-cæcum*. I have seen this fold sufficiently loose to allow the caput coli to travel over to the left iliac fossa.

† This transverse part of the colon, in some instances, makes a coil behind the stomach to the diaphragm; such a state of things, when the bowel happens to be distended, is apt to give rise to symptoms of diseased heart. See some observations in point by Dr. Copland, in *Lond. Med. Gaz.* 1847, vol. v. p. 660.

‡ The contiguity of the ascending and descending colon to the right and left kidney respectively, explains the occasional bursting of renal abscesses into the intestinal canal.

m. This term, so far as concerns the human subject, is misapplied; the canal runs anything but a straight course through the is, since it curves to adapt itself to the sacrum. Looking at the entire course of the colon, observe that it forms an arch, of which the concavity embraces the convolutions of the small intestines.

Let us now see to what extent the small and the large intestines are invested with a peritoneal coat. The *small intestines*, with the exception of the duodenum, which cannot at present be examined, shall find are completely surrounded by peritoneum, except at their mesenteric border, along which the vessels pass to the bowel; the *cæcum* is covered, as a rule, only in front and on its sides, the anterior surface being connected to the iliac fascia by connective

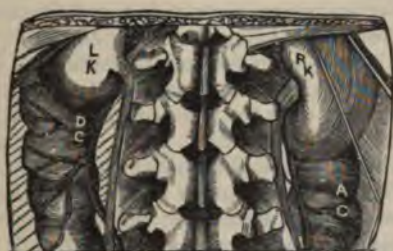

FIG. 157.—RELATIVE POSITION OF THE KIDNEYS AND THE LARGE INTESTINE, SEEN FROM BEHIND.

L. K. Left kidney. R. K. Right kidney, crossed obliquely by the last dorsal artery and nerve. A. C. Ascending colon. D. C. Descending colon.

the *ascending colon* is also only covered on the front aspect; the posterior surface being loosely connected by areolar tissue to the quadratus lumborum and right kidney; the *transverse colon* is almost entirely surrounded by peritoneum, which is reflected horizontally backwards as a broad double layer—the *transverse meso-colon*—to the spine; the *descending colon*, smaller than the transverse colon, and more deeply situated than the ascending colon, is only invested with peritoneum on its anterior and inner surfaces; the *sigmoid flexure* is completely invested with peritoneum, which connects this part of the bowels with a loose fold to the left iliac fossa; the *rectum* is completely surrounded by peritoneum in its upper half, and is connected to the front of the sacrum by a fold, the *meso-rectum*; the lower half of the rectum, the first three inches (7.5 cm.), is only covered in front with

peritoneum; the last inch and a half (3.8 cm.) has no peritoneal investment at all.*

**Relations of the
Large Intestine.**

At present we have only traced the course of the large intestine through the different abdominal regions, but now we are able to see the relations of the various portions of the bowel.

The *cæcum* rests in the right iliac fossa, separated from the iliacus by the iliac fascia and connective tissue; in front it has the anterior abdominal wall.

The *ascending colon* has behind it the quadratus lumborum and right kidney; in front, it has the abdominal wall and small intestines; above, it is in contact with the under aspect of the liver to the right of the gall-bladder.

The *transverse colon* is concave posteriorly, and has above, the liver, gall-bladder, the stomach, and the lower border of the spleen; behind, it has the transverse meso-colon and the third part of the duodenum; in front, it is in contact with the abdominal wall and great omentum; below, with the small intestines.

The *descending colon*, deeper situated than the ascending colon, lies behind, in contact with the left crus of the diaphragm, the left kidney and quadratus lumborum; in front, with the small intestines, and on its left side, with the abdominal wall.

The *sigmoid flexure* is in relation behind with the iliac fossa, the left spermatic artery and ureter, the left common iliac vessels; in front, with the small intestines and abdominal wall.

The relations of the *rectum* cannot at present be satisfactorily made out; the description of them has been deferred till the dissection of the side view of the pelvic viscera.

**Length of the
Alimentary Canal.**

The small intestine, including the duodenum, varies from sixteen to twenty-four feet in length, and the large intestine from four and a half to five feet (136.8 to 152.3 cm.); these measurements are subject to some variation according to the height of the subject.

**Situation of the
Liver.**

The liver occupies the whole of the right hypochondrium, and extends over the epigastric region, more or less, into the left. Unless the individual be very corpulent we can ascertain during life the extent to which the liver projects below the costal cartilages, and the general dimensions of the organ may be tolerably well told by percussion. Its *anterior border* is sharp and thin, and presents in

* It should be recollected, that the ascending and descending colon are not infrequently completely invested by peritoneum, and therefore, virtually speaking, have a mesentery. This occasional occurrence is important when the operation of right or left lumbar colotomy has to be performed.

the epigastric region a deep notch for the round ligament, and generally projects a little way below the ribs; its *posterior border* is broad and connected to the diaphragm by the coronary ligament; it is in relation behind with the inferior vena cava, the aorta, and the crura of the diaphragm. Its *upper convex surface* ascends as high as the fifth intercostal space, is accurately adapted to the arch of the diaphragm, and is divided into two unequal parts by the falciform or suspensory ligament; its *under surface* overlies part of the stomach, and of the duodenum, the right kidney and suprarenal capsule, and the hepatic flexure of the colon. Its *right border* is thick; its *left* is thin and sharp. To the diaphragm the liver is connected by folds of peritoneum, called *ligaments*. One of these, nearly vertical in direction, and called the *suspensory*, or, from its shape, the *falciform* ligament, is situated a little to the right of the mesial line. The lower and free edge of it contains the impervious remains of the umbilical vein, called the *round* ligament. The suspensory ligament, traced backwards, leads to another broad fold extending horizontally from the diaphragm to the posterior border of the liver; this constitutes the *lateral* ligament, right or left, according as we trace it on one or the other side of the falciform ligament.

The junction of the lateral and falciform ligaments is described by some authors as the *coronary* ligament.

Situation of the Gall-bladder.

The gall-bladder is the reservoir for the bile, and is closely confined by the peritoneum in a slight depression on the under surface of the right lobe of the liver, to which it is connected by areolar tissue; occasionally the gall-bladder is completely surrounded by peritoneum. It is pyriform in shape, and its broad end or fundus, covered with peritoneum, projects beneath the anterior border of the liver opposite the ninth costal cartilage. It measures three to four inches (7.5 to 10 cm.) in length, is an inch and a half (3.8 cm.) broad, and contains from eight to twelve drachms (32 to 48 c.c.). The neck is inclined upwards and towards the left, and is firmly connected to the liver by areolar tissue. The gall-bladder is in relation *above* with the liver and small blood-vessels; *below*, with the transverse colon and with the first portion of the duodenum; its *neck* is curved upon itself like the letter S, and bending downwards terminates in the cystic duct. It sometimes happens that the gall-bladder, in consequence of some obstruction to its duct, becomes unusually distended, and occasions a swelling below the margin of the ribs, which might be mistaken for a hepatic abscess. The close proximity of the gall-bladder to the duodenum and the transverse colon explains the occasional evacuation of gall-stones by ulceration into the intestinal canal.

Situation of the Spleen.

The spleen is the dark, purple-grey, flattened organ deeply situated in the left hypochondrium, between the stomach and the ninth, tenth, and eleventh ribs. It is placed nearly vertically; its outer surface is smooth and convex, to correspond with the diaphragm and ribs; its inner surface, where its great vessels enter, is concave, and connected to the great end of the stomach by a broad peritoneal fold, called the *gastro-splenic omentum*. Its *external surface* is in relation with the diaphragm which separates the organ from the ninth, tenth, and eleventh ribs; its *internal surface* is concave, and presents a vertical fissure—the *hilum*—situated nearer the posterior than the anterior border; it is at this fissure that the two layers of peritoneum are reflected from the stomach to the spleen, and the splenic vessels enter and emerge; it is in relation with the cardiac end of the stomach, the tail of the pancreas, the left supra-renal capsule, and the left crus of the diaphragm; the *upper border* is rounded, and is connected to the diaphragm by a fold of peritoneum—the *suspensory ligament*; the *lower border* is in contact with the splenic flexure of the colon; the *posterior border* is thick, and is connected with the left kidney by areolar tissue; the *anterior margin* usually presents a more or less deep notch. Its hilum is connected with the cardiac end of the stomach by a fold of peritoneum—the *gastro-splenic omentum*; and with the under surface of the diaphragm by a small peritoneal fold—the *suspensory ligament*.*

Situation of the Pancreas.

This is the large salivary gland of the abdomen. It is placed transversely across the back of the abdomen, in front of the spine, about the level of the first lumbar vertebra. It is about seven inches (17.5 cm.) in length, and an inch and a half (3.8 cm.) in breadth. Its *right end* or *head* is contained within the curve of the duodenum; its *left end*, or *tail*, extends as far as the spleen. The further connections and relations of the pancreas cannot at this stage of the dissection be satisfactorily seen.

Situation of the Kidneys.

The kidneys are two large excretory glands, situated at the back of the abdomen in each lumbar region, nearly opposite the two last dorsal and the two upper lumbar vertebræ—the right, owing to the size of the liver, being a little lower than the left. They lie imbedded in fat, which maintains them in their proper position. *Behind*, they rest on the crus of the diaphragm, on the quadratus lumborum and psoas, separated by the aponeurosis of the transversalis; in *front*, the right kidney is in relation with the perito-

* We find occasionally in the gastro-splenic omentum one or more small spleens in addition to the large one.

the right lobe of the liver, the second part of the duodenum, the ascending colon: the left kidney is in contact with the peritoneum, the cardiac end of the stomach, the spleen, the end of the jejunum, and the descending colon; *externally*, it is convex, and in contact with the abdominal parietes; *internally*, it is concave and presents a deep hollow—the *hilum*, from which pass the renal and large vessels; *above*, it is in relation with the supra-renal capsule; *below*, it extends nearly as low as the crest of the

These are two ductless glands, situated at the top of the kidneys and behind the peritoneum. The right one is triangular; the left, oval and kidney-shaped. The right supra-renal capsule is in relation *in front* under aspect of the liver; the left, with the pancreas and *behind*, it rests on the crus of the diaphragm; the *upper border* is convex and thin; the *lower border* is concave, and rests on the kidney; the *inner border* is in relation with the semilunar ganglion and splanchnic nerves, and with the vena cava on the right side and with the aorta on the left side. The anterior surface is deeply indented, from which the supra-renal vein passes out to join on the right side the inferior vena cava, and on the left side the left renal vein.

A certain range of motion being necessary to the abdominal viscera, they are provided with a serous membrane, called the *peritoneum*. This membrane, like other serous membranes, is a closed sac, one part of which lines the abdominal cavity, the other is reflected over the contained viscera. The two layers are respectively termed the *parietal* and the *visceral* layers. In the female, however, it is not, strictly speaking, a closed sac, but communicates with the cavity of the uterus through the Fallopian tubes. The internal surface of the peritoneum is smooth and polished, and lined by squamous endothelium; the external—the *sub-peritoneal tissue*—is composed of areolar tissue, and connects the internal layer to the invested viscus or abdominal parietes. There is nothing between the parietal and the visceral layers—in other words, inside the sac—but just sufficient fluid to lubricate its smooth and polished surface. The viscera, more or less, outside the sac; some lie altogether behind it, as the pancreas, kidneys, and supra-renal capsules; others, as the parts of the duodenum, cæcum, ascending and descending colon, are only partially covered by it; while others, as the stomach, jejunum, ileum, and some parts of the large intestine, are completely invested by it: these latter push the visceral layer before them and so give rise to membranous folds; the larger the fold, the less the mobility of the viscus which occasions it.

Course of the Peritoneum.

Now trace the peritoneum as a continuous membrane. Since the peritoneum is a perfect sac, it matters not where we begin: we must come back to the starting-point.

If a longitudinal section be made through the viscera in the

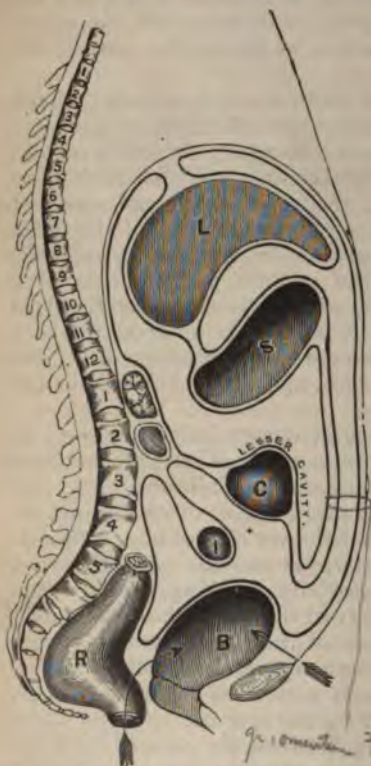

FIG. 158.—DIAGRAM OF THE PERITONEUM.

to its under surface, at which point we started.*

The peritoneum passes from the under surface of the right lobe

middle of the body, one can trace the peritoneum thus—beginning at the diaphragm, and taking, for brevity's sake, two layers at a time (Fig. 158).

From the diaphragm two layers of peritoneum proceed to the liver, forming its *lateral ligaments*; they separate to enclose the liver, meet again on its under aspect, and pass on under the name of the *gastro-hepatic omentum*, to the small curve of the stomach. Separating here, they embrace the stomach, and, meeting again at its greater curve, pass down like a curtain over the small intestine to form the *great omentum*. At the lower margin of the great omentum they are reflected upwards (so that the great omentum consists of four layers) to the front of the transverse colon, which they enclose, and, after joining again at the back of the colon, proceed to the spine, forming the *transverse meso-colon*. At this situation the two layers diverge, the upper one ascends in front of the pancreas, and the crura of the diaphragm

* In foetal life, the ascending layers of the great omentum may be traced back to the spine near the pancreas; and here the layers diverge from each other. The upper layer ascends in front of the pancreas to the diaphragm; the lower layer proceeds over the arch of the colon, and then back to the spine, thus forming the transverse meso-colon. Its reflections afterwards are the same as in the adult. As the foetus grows, the great omentum becomes adherent to the arch of the colon.

the liver to the kidney, forming a slight fold—the *hepato-renal*; on the left side, where the peritoneum extends from the diaphragm to the cardiac end of the stomach, it passes as a slight curvature, forming the *gastro-phrenic ligament*; an extension of it is seen passing as a distinct fold—the *costo-colic ligament*—from the diaphragm to the splenic flexure of the colon.

The lower layer is reflected from the spine over the small intestine back again to the spine, to form the *mesentery*. From the root of the mesentery it descends into the pelvis, and invests the lower two-thirds of the rectum. From the rectum, in the male, it is reflected to the posterior part of the bladder, forming the *recto-vesical pouch*, and thence to the wall of the abdomen, along which it may be traced up to the diaphragm. In the female, it is reflected from the rectum on to the posterior wall of the vagina half an inch (1.25 in.) from the uterine extremity, constituting the *recto-vaginal pouch* (*Douglas' pouch*), and thence over all the back, but only half-way down the front of the uterus, to the posterior wall of the bladder; after which its reflections are the same as in the male.

This is the course of the peritoneum as seen in a longitudinal section, but there are lateral reflections which cannot be seen except in a transverse section: thus, from the great end of the stomach, the layers proceed to the spleen, forming the *gastro-splenic omentum*; from the transverse meso-colon it is reflected on either side to the ascending and descending colon.

The structures *completely invested* with peritoneum are, the stomach, liver, first part of the duodenum, the jejunum and ileum, the transverse colon, sigmoid flexure, upper part of rectum, spleen, testes, and ovaries.

The following parts of the alimentary canal are only *partially covered* by peritoneum: namely, the descending and transverse portions of the duodenum, the cæcum, the ascending and descending colon (with exceptional cases), the middle part of the rectum, the upper part of the vagina, and the hinder wall of the bladder.

The viscera *uncovered* by peritoneum are, the lower part of the stomach, the anterior and the lower part of the posterior wall of the bladder, the anterior and part of the posterior wall of the bladder. Anatomists speak of the *lesser cavity of the peritoneum*, as distinguished from the greater. This lesser cavity, or *cavity of the lesser omentum*, is situated behind the stomach and the descending part of the great omentum. If air be blown through the foramen

For a detailed description of the development of the great omentum and the transverse meso-colon, see a paper by C. B. Lockwood, *Journal of Anatomy and Physiology*, vol. xviii.

of Winslow (which is the constricted communication between the greater and lesser cavities of the peritoneum), the lesser cavity becomes distended. It is bounded *in front* by the lesser omentum, the stomach, and the descending layers of the great omentum; *behind*, by the ascending layers of the great omentum, the colon, the upper layer of the transverse meso-colon and its ascending layer; *above*, by the liver; *below*, by the turn of the great omentum.

Foramen of Winslow.

This foramen is the narrow circular opening between the greater and lesser cavities of the peritoneum, through which the two cavities communicate. It is situated behind the right edge of the gastro-



FIG. 159.—DIAGRAM OF A TRANSVERSE SECTION THROUGH THE UPPER PART OF THE ABDOMINAL CAVITY, SEEN FROM ABOVE.

G.P. Greater cavity of the peritoneum. L.P. Lesser cavity of the peritoneum. A. Aorta. St. Stomach. S. Spleen. V. Inferior vena cava. L. Liver.



FIG. 160.—DIAGRAM OF A TRANSVERSE SECTION THROUGH THE LOWER PART OF THE ABDOMINAL CAVITY.

G.O. The great omentum with its cavity. I. Small intestine. A. Aorta. V. Inferior vena cava. A.C. Ascending colon. D.C. Descending colon. K. Kidneys.

hepatic or lesser omentum. By passing your finger into it, you will find the foramen bounded *above*, by the lobulus Spigelii or caudatus of the liver; *below*, by the commencement of the duodenum and by the curving forwards of the hepatic artery; *in front*, by the lesser omentum, enclosing the hepatic artery and duct and the vena portæ; and *behind*, by the vena cava inferior.

The several folds, formed by the reflections of the peritoneum, which connect the viscera either to each other or to the back of the abdomen, are classified respectively as ligaments, mesenteries, and omenta: the *ligaments* are attached to the viscera, and help to maintain them in position; the *mesenteries* pass from the abdominal walls to the large and small intestines, and maintain them in position and allow of blood-vessels to pass to and from them; and the

the broad, flat duplicatures which pass from the stomach to the surrounding viscera.

This is the fold which suspends the small intestine from the back of the abdomen. To the great omentum and the transverse arch of the colon. The fixed part or root is about six inches (15 cm.) in length, and from the left side of the second lumbar vertebra obliquely to the spine to the right sacro-iliac symphysis. The loose part of the mesentery is very broad, and curves like a ruffle, enclosing the small intestine from the beginning of the jejunum to the end of the ileum.

Its shape resembles an open fan, and its length from the vertebral column to its attachment to the intestine is about four inches (10 cm.). Above, it is connected with the under surface of the transverse meso-colon; below, with that part of the peritoneum which covers the inner part of the cæcum and ascending colon. We find between its two layers the mesenteric vessels, nerves, and lymphatics.

Meso- This broad fold connects the transverse colon to the back of the abdomen, and between its two layers the vessels pass to and from this portion of the large gut. It forms an imperfect partition dividing the abdomen into an upper compartment, containing the stomach, liver, and spleen; and a lower, containing the convolutions of the small

**and
ing Meso-** As regards the cæcum, and the ascending and descending portions of the colon, they are, as a general rule, bound down by the peritoneum in their respective situations (Fig. 160). The peritoneum covers only two-thirds or thereabouts of their anterior surface; their posterior surface is connected by loose cellular tissue to the back of the abdomen. The colon, ascending or descending, may be opened in the lumbar region, below the kidney, without injury to the peritoneum: a fact upon which is founded the operation of colotomy for the relief of stricture of the rectum. In some cases, the ascending and descending colon (more commonly the latter) are completely surrounded by peritoneum and attached to the lumbar regions, respectively, by a right and a left meso-colon.

Meso-colon. The sigmoid flexure is, as a rule, completely invested by peritoneum, which passes as a thin layer into the iliac fossa, allowing a considerable amount of movement to the intestine.

am. The upper third of the rectum is also surrounded by peritoneum, which passes to the

sacrum and thus retains it in position. The hæmorrhoids pass between its layers.

Great Omentum. This broad peritoneal fold, known as the *gastro-colic omentum*, is composed of two layers, and proceeds as a double layer from the lower border of the stomach, as far as the pelvis, where these two layers enclose the transverse colon. It lies like a curtain over the convolutions of the small intestines, and we find it in the female extending low into the pelvis; in others, small and usually in the left hypochondrium. Its thickness varies considerably: in thin subjects it is often translucent; in corpulent persons, on the other hand, it is loaded with fat, and contributes in a great measure to the size of the abdomen.

Gastro-hepatic or Lesser Omentum. This double fold passes from the greater curvature of the stomach to the fissure on the under surface of the liver, and the upper curve of the stomach. It is composed of two layers, and between them are the portal vein and hepatic artery, with the nerves going to the liver, and the hepatic lymphatics coming from it. The right border of this fold forms the anterior rounded margin of a constriction, and forms the anterior rounded margin of a constriction, and forms the *foramen of Winslow*, which leads into the lesser peritoneum: its left border passes on to the œsophagus, and the common bile duct lies to the right, the hepatic artery to the left, and the vena portæ behind and between them. The finger may be introduced behind the right border of this fold through the foramen of Winslow into the lesser peritoneum.

Gastro-splenic Omentum. This fold proceeds from the greater curvature of the stomach to the spleen, and is continuous with the great omentum. It consists of two layers, the branches, *vasa brevia*, which proceed from the greater curvature of the stomach to the greater end of the spleen.

Ligaments. The reflections of the peritoneum on the abdominal walls to the liver, the stomach, the bladder, and uterus, and constituting their *ligaments*, have already been described with the respective viscera.

Branches of the Abdominal Aorta. Our next object should be the examination of the arteries which supply the viscera. The *abdominal aorta* enters the abdomen between the pillars of the diaphragm in front of the last dorsal vertebra, then, descending a little to the left of the spine, divides into the body of the fourth lumbar vertebra, a little to the left of the middle line into the two common iliac arteries. The relations of these vessels cannot at present be sufficiently made out, so that

described later on. In its course it gives off its branches in the following order (Fig. 161):—

1. The *phrenic*, for the supply of the diaphragm.
2. The *cœliac axis*, a short, thick trunk, which immediately subdivides into three branches for the supply of the stomach, the liver, and the spleen.
3. The *superior mesenteric*, for the supply of all the small intestines and the upper half of the large.
4. 5. The *supra-renal* and the *renal* arteries.
6. The *spermatic*, for the testicles; the *ovarian*, for the ovaries.
7. The *inferior mesenteric*, for the supply of the lower half of the large intestine.
8. The *lumbar*, four branches analogous to the intercostals, for the supply of the back part of the abdomen.
9. The *arteria sacra media*, which is given off at the bifurcation of the aorta, supplies the fifth lumbar artery and, running down in front of the sacrum, supplies the rectum and other structures.

By some anatomists the branches are arranged in two classes—those destined to supply the viscera, and those to supply the abdominal parietes: the former are the cœliac axis, supra-renal, renal, spermatic, superior and inferior mesenteric arteries; the latter are the phrenic, the lumbar, and sacra media arteries.

Dissection.

These branches are to be traced throughout in the following order. Take the cœliac axis first. To dissect this artery and its branches, the body must be well raised and the stomach drawn down, as in Fig. 162, and the anterior layer of peritoneum removed from the gastro-spermatic omentum. A close network of very fine vessels surrounds the visceral branches of the aorta. This tissue consists almost entirely of plexuses of nerves, derived from the sympathetic system, each plexus taking the name of the artery which it surrounds. In these plexuses, the largest surrounds the cœliac axis like a ring. This is the solar

plexus, and is formed by the junction of the two semilunar ganglia (see Fig. 70, p. 196). From this, as from a root, other secondary plexuses branch off, and surround the following arteries—the phrenic,

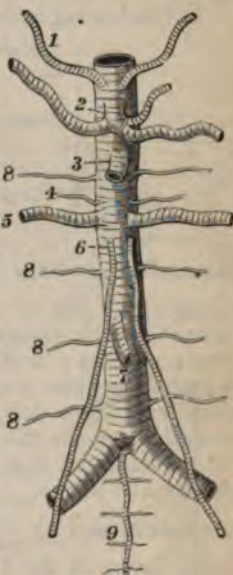


FIG. 161.—BRANCHES OF THE ABDOMINAL AORTA.

1. Phrenic. 2. Cœliac axis. 3. Superior mesenteric. 4. Supra-renal. 5. Renal. 6. Spermatic. 7. Inferior mesenteric. 8. Lumbar. 9. Sacra media.

coronary, hepatic, splenic, superior mesenteric, inferior mesenteric, and renal, the plexuses receiving the names of the arteries around which they twine. It requires a lean subject and much patience to trace them.

Cæliac Axis and its Branches.

The *cæliac axis* arises from the front of the aorta, between the pillars of the diaphragm, immediately above the upper border of the pancreas, to the left of the lobulus Spigelii, to the right of the cardiac end of the stomach, and having the semilunar ganglia on each side. It is a short, thick trunk which runs between the two layers of the lesser omentum, and, after a course of about half an inch (*13 mm.*), divides into three branches, the hepatic running to the right, the splenic to the left, and the coronaria ventriculi upwards and to the left side.

The following is the plan of the cæliac axis and its branches:—

CÆLIAC AXIS.	{	Coronaria ven- tricoli.	{	œsophageal.	
				gastric.	
		Hepatic . . .	{	pyloric.	{ gastro-epiploica dextra. pancreatico-duodenalis superior.
		gastro-duodenalis.			
		Splenic . . .	{	pancreatic branches.	
				gastro-epiploica sinistra.	
				vasa brevia to stomach.	

Coronaria Ventriculi. The *coronaria ventriculi*, the smallest of the three, ascends a little to the left towards the œsophageal end of the stomach, where it gives off *œsophageal* branches, which anastomose with the œsophageal branches of the thoracic aorta; and others to the cardiac end of the stomach, which inosculate with the vasa brevia of the splenic artery. It then runs from left to right, along the lesser curvature of the stomach towards the pylorus, supplying branches on both surfaces of the stomach, and finally anastomoses with the pyloric branch of the hepatic artery.

Hepatic Artery.

The *hepatic artery* ascends to the right between the layers of the lesser omentum to the transverse fissure of the liver, where it divides into two branches, right and left, for the supply of the respective lobes of the liver.

In its course to the liver, it lies to the left of the common bile-duct and in front of the portal vein: all three are contained in the right half of the lesser omentum. The hepatic gives off—

a. The *pyloric*, which descends to the upper border of the pylorus, and runs along the lesser curve of the stomach from right to left, inosculating with the coronaria ventriculi.

b. The *gastro-duodenalis* descends behind the ascending portion of the duodenum, divides, after a short course, into (*a*) the *gastro-epiploica dextra*, which runs

along the greater curve of the stomach, between the layers of the great omentum, from right to left, and anastomoses with the gastro-epiploica sinistra from the splenic, supplying both surfaces of the stomach and the great omentum; and (β) the *pancreatico-duodenalis superior*, which runs down between the head of the pancreas and the descending portion of the duodenum, and anastomoses with the *pancreatico-duodenalis inferior*, a branch of the superior mesenteric, and with the pancreatic branches of the splenic.

c. The *cystic*, commonly a branch of the right hepatic, ascends along the neck of the gall-bladder, and divides into two branches, one of which ramifies on the under surface of the gall-bladder, the other passes between the liver and the upper surface of the gall-bladder.

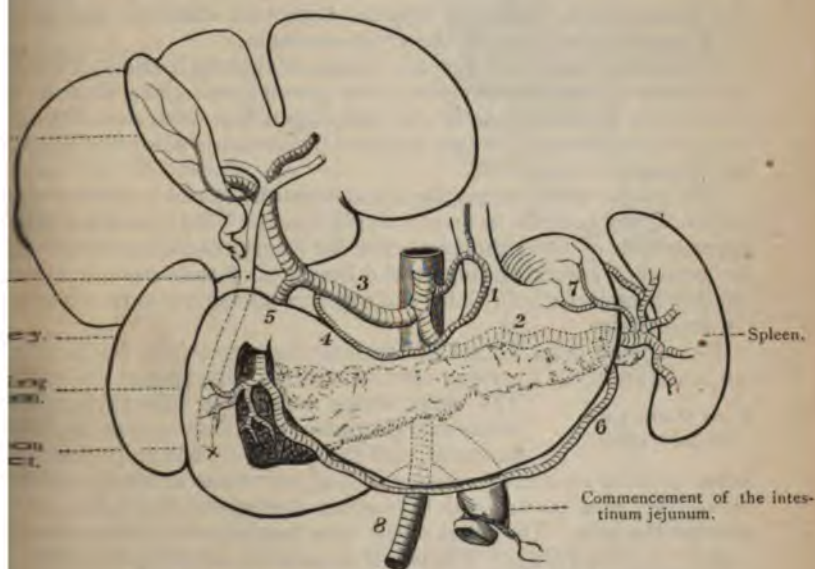


FIG. 162.—DIAGRAM OF THE BRANCHES OF THE CŒLIAC AXIS.

(Pancreas in dotted outline behind the stomach.)

1. Splenic a. 2. Splenic a. 3. Hepatic a. 4. Pyloric a. 5. Gastro-duodenalis.
6. Gastro-epiploica sinistra. 7. Vasa brevia. 8. Superior mesenteric a.

Splenic Artery.

The *splenic*, the largest of the three, proceeds tortuously towards the left side, above its corresponding vein, along the upper border of the pancreas to the hilum of the spleen, which it enters by numerous branches.

It gives off: 1. Several small branches to the pancreas, *pancreatica parva*; rather larger than the rest, *pancreatica magna*, accompanies the pancreatic duct. These arteries anastomose with the *pancreatico-duodenalis* branches of the hepatic and superior mesenteric arteries. 2. The *gastro-epiploica sinistra*, which

runs to the right along the great curve of the stomach, between the layers of the great omentum, and inosculates with the gastro-epiploica dextra. 3. *Vasa brevia*, five to seven in number, which proceed between the layers of the *gastro-splenic* omentum, to the great end of the stomach, where they communicate with branches from the coronaria ventriculi, and the gastro-epiploica sinistra. 4. The *splenic* branches are five or six in number, and enter the fissure of the spleen.

Thus the stomach is supplied with blood by four channels, which by their inosculation form a main artery along its lesser curve, another along its greater; from these, numerous branches are furnished to both surfaces of the stomach. The artery of the greater curve also sends down numerous *omental* branches, which form a network between the layers of the great omentum.

The vein corresponding to the coronaria ventriculi artery, called the *coronary*, commences close to the pylorus, runs along the lesser curve of the stomach as far as the œsophagus, and then, descending to the right, between the two layers of the gastro-hepatic omentum, opens into the vena portæ.

The *splenic vein* returns the blood from the spleen by five or six branches which unite to form a single trunk. This runs along the upper border of the pancreas below the artery, and after receiving the branches corresponding to the branches of the artery and the inferior mesenteric vein, joins the superior mesenteric vein to form the vena portæ.

The *hepatic veins* do not run with the hepatic artery, but return the blood from the liver and terminate in the vena portæ.

Vena Portæ: its Peculiarities. The veins which return the blood from the abdominal portion of the alimentary canal, the pancreas, and the spleen, do not empty themselves into the vena cava inferior, but all unite into one large vein, called the *vena portæ*, which ramifies throughout the liver, and secretes the bile. The trunk of the vena portæ itself is about three inches (7.5 cm.) long. Tracing it downwards, you find that it is formed behind the great end of the pancreas and in front of the inferior cava by the confluence of the splenic and superior mesenteric veins (Fig. 163). In its passage to the liver, the vena portæ is accompanied by the hepatic artery and the common bile-duct, lying behind and between them. At the transverse fissure of the liver it presents a slight enlargement, called the *sinus*, and then divides into two branches corresponding to the right and left lobes. The vein ramifies in the substance of the liver like an artery, and is surrounded, with the branches of the hepatic artery and duct, in a sheath of areolar hepatic tissue called *Glisson's capsule*. The vena portæ may, then, be compared to the stem of a tree, of which the roots arise in the digestive organs, and the branches spread out in the liver. After receiving the veins corresponding to the

branches of the hepatic artery, the vena portæ returns its blood into the inferior vena cava through the venæ cavæ hepaticæ.

The veins which empty themselves into the vena portæ have no valves. Therefore, if any obstruction arises in the venous circulation through the liver, the roots of the portal vein are apt to become congested; this is a common cause of hæmorrhoids, diarrhœa, hæmorrhage from the bowels, and ascites.

Hepatic Duct. The hepatic duct is formed by the junction of the right and left hepatic ducts, which issue from the transverse fissure. The hepatic duct descends nearly vertically for about an inch and a half (3.8 cm.), when it is joined at an acute angle by the cystic

Cystic Duct. duct. The cystic duct, about an inch (2.5 cm.) in length, descends, from the neck of the gall bladder, towards the left in the gastro-hepatic omentum, lying to the right of the hepatic artery and in front of the vena portæ. The hepatic and cystic ducts unite to form the ductus

**Ductus Communis
Choledochus.**

communis choledochus, or the common bile duct; the duct thus formed, passes downwards and to the left, between the two layers of the lesser omentum, close to its right border. It is about three inches (7.5 cm.) long, and if distended would be about the size of a crow-quill. It descends behind the first portion of the duodenum; in front of the vena portæ; to the right of the hepatic artery; to the left of the descending portion of the duodenum; and behind the head of the pancreas. Then turning towards the right, it gets behind the descending duodenum, and opens obliquely into the back part of the second portion, near the junction with the third. The

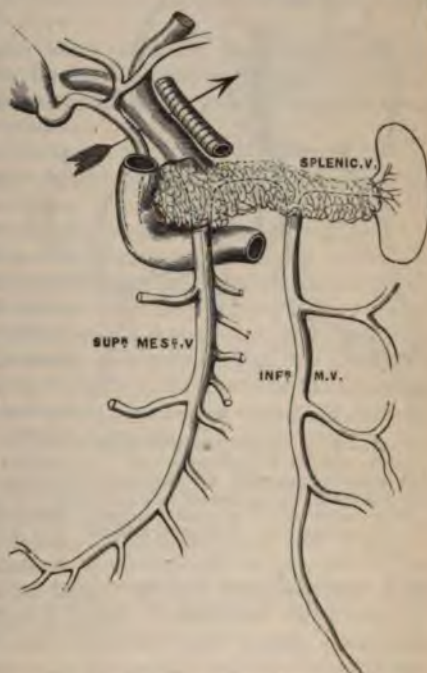


FIG. 163.—DIAGRAM OF THE VENA PORTE.
(The arrow is introduced behind the free border of the lesser omentum.)

duct runs through the coats of the bowel for nearly three-quarters of an inch (*18 mm.*), and sometimes before doing so unites with the pancreatic duct (p. 439).

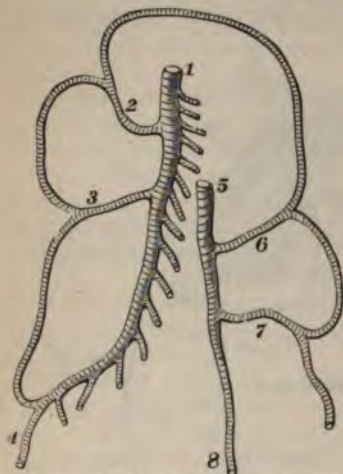


FIG. 164.—PLAN OF THE MESENTERIC ARTERIES AND THEIR COMMUNICATIONS.*

1. Superior mesenteric a. 2. Colica media.
3. Colica dextra. 4. Ileo-colica. 5. Inferior mesenteric a. 6. Colica sinistra.
7. Arteria sigmoidea. 8. Superior hæmorrhoidal a.

white threads), and can be traced into the glands from all parts of the small intestine.† After traversing the glands, they all eventually empty their contents into the receptaculum chyli (p. 192).

Superior Mesenteric Artery and Branches.

This large artery arises from the front of the aorta just below the cœliac axis, descends beneath the pancreas, in front of the transverse part of the duodenum (Fig. 162, No. 8, p. 437), and then runs between the layers of the mesentery towards the right iliac fossa, where it terminates in branches for the supply of the cæcum. Thus it describes a gentle curve from left to right. It is crossed by the pancreas and splenic vein, and will be seen to supply the descending and transverse duodenum, the jejunum, ileum, and the ascending and transverse colon. It is accompanied by its cor-

Dissection. The great omentum,

with the arch of the colon, must now be turned up over the chest, and the small intestines pushed towards the left side. Then, by removing the anterior layer of the peritoneum from the mesentery, we expose the mode in which the superior mesenteric artery ramifies so as to supply the small intestines. In making this dissection, the mesenteric glands immediately attract notice. They lie in great numbers between the layers of the mesentery, and vary considerably in size. The fine tubes, called lacteal vessels, which traverse the glands, are too thin and transparent to be seen under ordinary circumstances. But in cases where sudden death has taken place during digestion, they are found distended with chyle (resembling fine

* The inferior pancreatico-duodenal artery is not represented.

† The arrangement of the chyloferous vessels is well displayed in the plates of Mascagni.

responding vein, and is surrounded by the superior mesenteric sympathetic plexus. It gives off the following branches:—

1. The *inferior pancreatico-duodenal* branch, which runs up behind the pancreas, within the concavity of the duodenum, to inosculate with the *superior pancreatico-duodenal* branch of the hepatic.

2. The *Vasa intestini tenuis* of the small intestine, from ten to sixteen in number, are given off from the left or convex side of the curve, and are distributed to the jejunum and ileum; while from the concave side come—

3. The *ileo-colic*;

4. The *right colic*, for the supply of the ileum, cæcum, and ascending colon; and

5. The *middle colic*, for the supply of the transverse colon.

The student should now trace the branches to the small intestine, in order to see the series of arches which they form by their mutual inosculations. There are three or four tiers of them, each tier composed of smaller and more numerous branches than the preceding. The ultimate branches ramify in circles round the intestine. This circular arrangement of the vessels in the coats of the bowel is practically interesting, because it enables one in almost all cases to distinguish the intestine from the hernial sac.

The *colic* branches of the superior mesenteric are the *ileo-colic*, which is the continuation of the main trunk, and divides into two branches: one supplies the lower part of the ileum, and the other the cæcum;

The *right colic*, which proceeds towards the ascending colon; and

The *middle colic*, which ascends between the layers of the meso-colon to the arch. They are arranged after the same plan as those of the small intestine: that is, they inosculate and form a series of arches which successively decrease in size, and finally terminate in circles round the bowel.

The *superior mesenteric vein* joins the splenic behind the pancreas, and forms the *vena portæ* (p. 439).

Dissection of the Inferior Mesenteric Artery and Branches.

To trace this artery, the small intestine must be drawn over towards the right side, and the peritoneum covering the artery removed, since the artery lies behind the peritoneum. It is given off from the front of the aorta, about two inches (5 cm.) above its bifurcation, and is surrounded by the inferior mesenteric plexus of sympathetic nerves. Descending towards the left iliac fossa, it crosses obliquely over the left common iliac artery, passes between the layers of the meso-rectum, and taking the name of *superior hæmorrhoidal*, is finally distributed to the upper part of the rectum. Its branches are:—

1. The *colica sinistra*, which crosses behind the peritoneum, over the left kidney, and supplies the descending colon.

2. The *sigmoidea*, which runs over the psoas, is distributed to the sigmoid flexure.

3. The *superior hæmorrhoidal*, which supplies the upper part of the rectum, and will be dissected with the side view of the pelvis.

These branches of the inferior mesenteric inosculate in the form of arches, like the colic branches of the superior mesenteric. The *colica sinistra*, too, forms a large arterial arch with the *colica media*, so that there is a chain of arterial communications from one end to the other of the intestinal canal (Fig. 164).

The *inferior mesenteric vein* ascends nearly vertically behind the peritoneum, passes in front of the left psoas, behind the third portion of the duodenum and the pancreas, and joins the splenic behind the pancreas.

Dissection. To see the relations of the duodenum and the pancreas, two ligatures about an inch (*2.5 cm.*) apart should be placed on the upper end of the jejunum, and two others at a similar distance apart on the lower end of the sigmoid flexure of the colon. After the jejunum and the sigmoid flexure have been divided between the ligatures respectively, the small and large intestines are to be removed by cutting through the peritoneal folds which connect them to the abdominal walls. By turning up the stomach, we expose the duodenum curving round the great end of the pancreas.

Duodenum, Relations of. The duodenum (Fig. 162, p. 437) commences at the pyloric end of the stomach, and terminates on the left side of the second lumbar vertebra, where the *intestinum jejunum* begins. It is about eight to ten inches (*20-25 cm.*) in length and two inches (*5 cm.*) in diameter, and is divided into three parts, an ascending, descending, and transverse.

The first portion ascends obliquely as high as the neck of the gall-bladder; then, making a sudden bend, it descends in front of the right kidney as low as the third lumbar vertebra. Lastly, making another bend, it ascends obliquely across the spine to the left side of the second lumbar vertebra: here the intestine takes the name of jejunum. Thus the duodenum describes a horseshoe curve, the concavity of which is directed towards the left side, and embraces the head of the pancreas.

The first or *ascending* portion is about two inches (*5 cm.*) long, and is completely invested by peritoneum. It is comparatively free, so that the movements of the stomach may not be restricted. In front of it are the liver and the neck of the gall-bladder. Behind it are the bile-duct, the hepatic artery, and the *vena portæ*. The second or *descending* portion is about three inches (*7.5 cm.*) long, and is covered by peritoneum only on its anterior surface. It is

firmly connected to the deeper structures behind, and to the pancreas on its left side, so that no movement is permitted in this portion. It descends from the neck of the gall-bladder to the right side of the body of the third lumbar vertebra. It lies behind the transverse colon, in front of the right kidney and the ductus communis choledochus; on the left side it is in relation with the head of the pancreas, its duct, and the superior and inferior pancreaticoduodenal arteries. The third or *transverse* portion, about four inches (10 cm.) long, is situated behind the transverse meso-colon, just above the mesentery and the superior mesenteric vessels. Above it are the pancreas, and the superior mesenteric artery and vein, which pass between the pancreas and the duodenum: behind, it rests upon the crura of the diaphragm, the inferior vena cava, and the aorta. This portion, like the second, is only covered in front by the peritoneum. Notice how firmly the duodenum is braced up on the left side of the second lumbar vertebra, and how the jejunum begins here by an abrupt downward bend.

Pancreas, Relations of.

The pancreas is a large compound racemose gland, situated immediately behind the stomach (Fig. 163, p. 439). It is of an elongated form, and of pinkish-white colour. It is placed transversely across the spine; its larger end, or *head*, is embraced by the duodenum; its lesser end, or *tail*, is in contact with the spleen. It is about six to eight inches in length, its average breadth is one inch and a half, and its thickness from half an inch to an inch. Its weight is from $2\frac{1}{4}$ oz. to $3\frac{1}{2}$ oz. (63.7 to 89 gm.), although it frequently exceeds the latter weight.

In *front*, the gland has the ascending layer of the transverse meso-colon and the stomach: its *right extremity*, or *head*, is embraced by the duodenum, separated from it by the pancreaticoduodenal arteries; *behind* the head is the ductus communis choledochus, whilst the body is in relation posteriorly with the inferior vena cava, the superior mesenteric vein and artery, the aorta, the beginning of the vena portæ, the crura of the diaphragm, the left kidney, the supra-renal capsule, and the inferior mesenteric vein; its *left extremity*, or *tail*, touches the concavity of the lower surface of the spleen, and is in front of the left supra-renal capsule; the *upper border* is in relation with the coeliac axis, the splenic artery and vein lying in a groove in the gland, and on the right side with the ascending portion of the duodenum and the hepatic artery; the *lower border* is in relation with the transverse portion of the duodenum, from which it is separated by the superior mesenteric vessels, and to the left side with the inferior mesenteric vein.

Its *duct* (*canal of Wirsung*) runs from left to right, near the lower

border and anterior surface of the gland, and empties itself into the back part of the descending portion of the duodenum, conjointly with, or close to, the opening of the common bile-duct. It receives numerous branches from the splenic artery, which runs along its upper border; some from the superior mesenteric, which lies immediately beneath it, and others from the gastro-duodenalis.

Dissection.

The liver, stomach, duodenum, pancreas, and spleen should now be collectively removed. For this purpose it is necessary to cut through the ligaments of the liver, the venæ cavæ hepaticæ, and the branches of the celiac axis. These viscera, with the remainder of the intestinal canal, should be macerated in water, while you examine all that is to be seen at the back of the abdomen: namely, the deep-seated muscles, the aorta, the inferior vena cava, the kidneys, the lumbar plexus of nerves, and the sympathetic nerve.

Kidneys and Ureter, Relations of.

The kidneys, two large glands which excrete the urine, are situated in the lumbar region, behind the peritoneum, one on each side of the spine. They extend from the eleventh rib nearly as far as the crest of the ilium, and lie embedded in more or less fat, on the quadratus lumborum, the psoas, and the crura of the diaphragm. The adult kidney is 4.4 inches (11 cm) in length, 2 inches (5 cm) wide, and 1 inch (2.5 cm) in thickness. It weighs in the male 4 to 6 oz. (113.5 to 170 gms.), in the female 4 to 5½ oz. (113.5 to 156 gms.). Surmounting each is a small body, called the supra-renal capsule.

The *anterior surface* is convex and the right kidney has *in front* the liver, the ascending colon, the descending portion of the duodenum, and the colica dextra artery; the left kidney has *in front* the lower part of the spleen, the cardiac end of the stomach, the descending colon, the tail of the pancreas, and the colica sinistra artery. This explains how it is that a renal abscess or calculus is sometimes evacuated by the rectum. *Above*, the right kidney is in contact with the under surface of the liver, and its upper end reaches as high as the lower border of the eleventh rib; the left kidney is in contact above with the spleen, and reaches to the level of the upper border of the eleventh rib. The *posterior surface* is flat and lies on the corresponding crus of the diaphragm, the quadratus lumborum, and the psoas, separated, however, by the anterior layer of the aponeurosis of the transversalis; the *outer border* is convex, and looks towards the parietes; the *inner border* presents a deep notch, the *hilum*, continuous with a cavity, the *sinus*, through which pass the renal artery and vein, the ureter, the renal plexus of nerves and lymphatics, surrounded by connective tissue and fat. The vessels and duct have the following relations:

anteriorly is the renal vein, posteriorly is the ureter, the renal artery being between them. The ureter descends almost vertically on the psoas muscle, enters the pelvis over the division of the common iliac artery, and empties itself into the lower part of the bladder after running obliquely through its coats. The kidney,

below, descends nearly as low as the crest of the ilium, and is not so broad as the upper extremity. The kidneys and supra-renal capsules must be removed and reserved for further examination.

Semilunar Ganglia. The *semilunar ganglia*, two in number, are contained in the solar plexus, and are situated one on each side of the coeliac axis, in the neighbourhood of the suprarenal bodies; that on the right side will be found lying under the vena cava inferior. They consist of irregular ganglionic masses. Above, each ganglion receives the great splanchnic nerve (Fig. 70, p. 196), and the two ganglia are connected on their inner sides. Filaments are distributed to the supra-renal and renal plexuses and to the plexuses which surround the branches of the abdominal aorta. The branches of the solar plexus will be described later on.

Diaphragm. This is a partly muscular and partly tendinous arch, so constructed as to form a complete moveable partition between the chest and the abdomen: a floor for the one, and a roof for the other. Its upper or thoracic surface is convex; its lower or abdominal, concave. On removing its peritoneal coat, and a thin fascial covering from the transversalis fascia, we observe a broad tendon in the centre, and that muscular fibres converge to it from all sides (Fig. 165). The diaphragm *arises*, 1. From the ensiform cartilage by fleshy fibres; 2. From the inner surfaces of the cartilages of the six lower ribs by as many digitations, which correspond with those of the transversalis; 3. From two thin tendinous arches, called, respectively, the *ligamenta arcuata, externum* and *internum* (the external arch is the thickened upper border of the anterior layer of the transversalis fascia, and extends from the last rib to the transverse process of the first lumbar vertebra, and arches over the quadratus lumborum; the internal passes from the transverse process of the first lumbar vertebra to the body of the same vertebra, and arches over the psoas); and 4. From the front of the bodies of the lumbar vertebræ by two elongated bundles, called the *crura* of the diaphragm. Both crura have tendinous origins; the right crus is, however, a little longer than the left; the former arises from the first, second, and third lumbar vertebræ and their intervening cartilages; the left does not descend so low by one vertebra. The inner fibres of each crus decussate, those of the right being the more anterior. In their

decussation the fibres separate the aortic from the œsophageal openings. Between the two crura the aorta enters the abdomen.

From these various origins the fibres ascend, at first nearly vertically, and then all arch inwards, and converge to be inserted into the central tendon.

The *central tendon* is nearly the highest part of the diaphragm. It presents a white, glistening surface, owing to the crossing of its tendinous fibres; its shape may be compared to that of a trefoil leaf, and it is composed of a right and left leaflet and a middle leaflet, separated from each other by indentations. Of the three

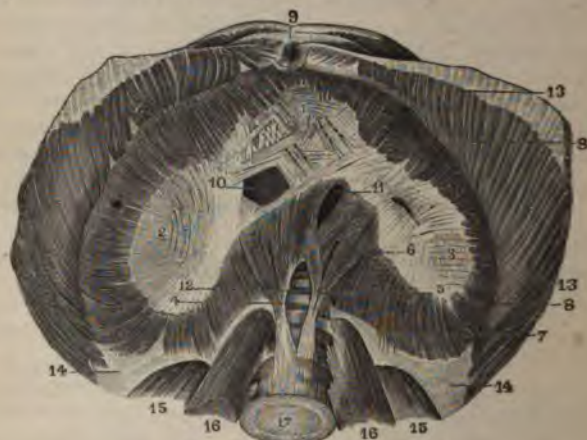

FIG. 165.—THE DIAPHRAGM.

1. Anterior or middle leaflet of the central aponeurosis. 2. Right leaflet. 3. Left leaflet. 4. Right crus. 5. Left crus. 6. Slit for the great splanchnic nerve. 7. Muscular fibres which arise from the arcuate ligament. 8, 8. Fibres which arise from the cartilages. 9. Fibres which arise from the base of the ensiform cartilage. 10. Opening for the vena cava. 11. Œsophageal opening. 12. Aortic opening. 13. Superior part of the transversalis turned back. 14, 14. Aponeurosis of the transversalis. 15, 15. Quadratus lumborum m. 16, 16. Psoas magnus m. 17. Third lumbar vertebra.

leaflets, the right is the largest and the left the smallest. The chief point of interest about the tendon is that, in consequence of its connections with the pericardium, below which it lies (Fig. 66, p. 180), it is always maintained on the same level; so that it helps to support the heart, and serves as a fixed point for the insertion of the muscular fibres of the diaphragm.

Openings in the Diaphragm.

There are three large openings in the diaphragm for the transmission of the aorta, the œsophagus, and the inferior vena cava, respectively, and several smaller apertures for the transmission of nerves and vessels. The *aortic opening* is osseo-aponeurotic, and lies in

the middle line between the two crura in front of the spine; it transmits, also, the vena azygos major and the thoracic duct, both of which lie rather to the right side of the aorta. Trace the crura upwards, and observe that the inner fibres of each cross each other in front of the aorta, somewhat like the letter X.* Above the decussation, and a little to the left of it, is the *oesophageal opening*; this is oval and entirely muscular, and transmits the oesophagus and the pneumogastric nerves. The opening for the vena cava (*foramen quadratum*) is situated in the highest part of the central tendon, rather to the right of the middle line, and is quadrate in shape. Through this opening pass the inferior vena cava, some lymphatics from the convex surface of the liver, and usually a branch from the right phrenic nerve. Observe that the vein is intimately connected to its margin, and kept permanently open. Lastly, there pass through the crura, on each side, the sympathetic and the greater and lesser splanchnic nerves; and in addition, on the left side, the vena azygos minor. The arch of the diaphragm, in expiration, extends about as high as the fifth rib on the right side and the sixth rib on the left.

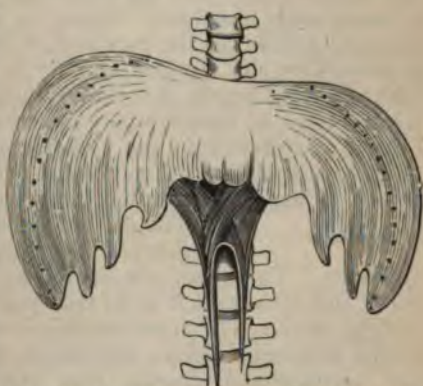

FIG. 166.—DIAPHRAGM, FROM ITS UPPER SURFACE.
(The dotted lines show the amount of descent on contraction.)

The nerves of the diaphragm are the phrenic (p. 189), and the five or six lower intercostal nerves. The diaphragm also receives minute filaments from the diaphragmatic plexuses, which come from the semilunar ganglia. On its under surface, on the right side, close to the supra-renal capsule, the plexus joins some branches of the right phrenic nerve, at which spot there is a small ganglion (*ganglion diaphragmaticum*), from which filaments are given off to the liver, vena cava, and supra-renal capsule. It is absent on the left side. Its blood vessels are the two phrenic, derived from the aorta, the internal mammary (p. 170), and the lower intercostal.

Function of the Diaphragm.

The diaphragm is the great muscle concerned in inspiration. During inspiration the muscular sides of the diaphragm contract, and become less arched (as shown by the dotted line in Fig. 166); the floor of

* This decussation is not always complete. But the right crus always crosses more or less over the left, so that the crura are never strictly parallel.

the chest sinks in consequence, and more room is made for the expansion of the lungs. During expiration the diaphragm relaxes and the air is expelled, partly by the elasticity of the lungs and the thoracic walls, partly by muscular action. This alternate sinking and rising of the diaphragm constitutes a chief part of the mechanism of breathing. But the diaphragm conduces to the performance of many other functions. Acting in concert with the abdominal muscles, it assists in the expulsion of the fæces and the urine, also in parturition and in vomiting; for in all these operations we first take in a deep breath, that the diaphragm may be in a state of contraction, and so form a resisting surface, against which the viscera may be compressed by the abdominal muscles. Moreover, by its rapid or spasmodic contractions it is one of the chief agents concerned in laughing, sneezing, coughing, hiccough.

Dissection.

The student should now dissect the large vessels and the muscles of the back part of the abdomen. To do so, the mesentery which lies in front of the aorta and vena cava is to be removed, as well as the fat and connective tissue. The dissection should include the parietal branches of the abdominal aorta; afterwards, its great primary divisions—the common and external iliac arteries—should be cleaned as far as Poupart's ligament. The quadratus lumborum, the psoas, and iliacus muscles should be carefully cleaned, care being taken not to injure the nerves and arteries lying in front of them; thus, in front of the quadratus lumborum are the last dorsal, the ilio-hypogastric, and ilio-inguinal nerves, which cross the muscle obliquely; in front of the iliacus are the external cutaneous and anterior crural nerves; and coming through, and then lying in front of the psoas, is the genito-crural nerve, while to the inner side of the muscle is the obturator nerve. The gangliated cord of the sympathetic nerves, situated on each side of the bodies of the vertebræ, must also be made out; and, lastly, the sheath which invests the psoas should be examined, and the branches of the lumbar plexus preserved as they emerge from beneath the outer border of the muscle.

Before examining the course of the aorta, notice that a chain of lymphatic glands extends along the brim of the pelvis and the bodies of the lumbar vertebræ, following the course of the great blood-vessels. Generally speaking, they are small; only one here and there attracts observation. They transmit the lymphatics from the lower limbs, the abdominal wall, and the testicle; and all eventually lead to the *receptaculum chyli*, or beginning of the thoracic duct (Fig. 69, p. 191). This is usually found on the right of the aorta, close to the second lumbar vertebra.

**Course and Relations
of the Abdominal
Aorta.**

The *abdominal aorta* enters the abdomen between the crura of the diaphragm in front of the body of the last dorsal vertebra, and descends a little to the left side of the front of the spine, as low as the middle of the fourth lumbar vertebra, where it divides into the two common iliac arteries. It follows the curve of the lumbar convexity, attaining its greatest curve on a level with the third lumbar vertebra. It rapidly lessens in size, owing to the large branches it gives off in its course. The division of the aorta into the two common iliac arteries is about the level of the highest point of the crest of the ilium, and just below the left side of the umbilicus. The artery has *in front* of it, the stomach and the lesser omentum, the solar plexus surrounding the coeliac axis, the splenic vein, the pancreas, the transverse portion of the duodenum, the left renal vein, the mesentery, the aortic sympathetic plexus, and a chain of lymphatic glands. To the *right side* of it, lie the right crus of the diaphragm, the inferior vena cava, the thoracic duct, the vena azygos, and the right semilunar ganglion. To the *left side* of it, are the left crus, the left semilunar ganglion, and the sympathetic nerves. *Behind*, it rests on the receptaculum chyli, the thoracic duct, the left lumbar veins, and the anterior common ligament.


The branches of the aorta still to be examined arise from it in pairs—namely, the phrenic, capsular, renal, spermatic, and lumbar (Fig. 167).

Phrenic Arteries.

These arteries supply the under surface of the diaphragm, and occasionally arise separately, usually by a common trunk, from the aorta, after its passage under the crura of the diaphragm (Fig. 167). The *right phrenic* passes outwards, behind the liver and the inferior vena cava, and then gets to the right side of the caval opening in the diaphragm; the *left phrenic* ascends behind the oesophagus, and gets to the left side of the oesophageal opening. Each ascends, lying on its corresponding crus, as far as the central tendon, where it divides into two branches: one, the external, passes transversely across the tendon to the side of the diaphragm; the other, the internal branch, which seems to be the continuation of the artery, runs forward to the anterior part of the muscle. Their first branches are to the supra-renal capsules; then, the internal branch of the right gives off a small branch to the vena cava, the corresponding branch of the left sends one to the oesophagus. Moreover, small branches are distributed respectively to the liver and to the spleen. They inosculate with each other, with the musculo-phrenic branches of the internal mammary, and the intercostal arteries. The *right phrenic vein* terminates in the inferior vena cava; the *left vein* in the renal vein, if not in the vena cava.

Supra-renal Arteries.

The *supra-renal* or *capsular arteries* are two very small branches, given off from the aorta, one on each side, opposite to the superior mesenteric artery; each runs upon the crus of the diaphragm, the right behind the inferior cava, and is distributed to the supra-renal body, inosculating with branches from the phrenic and renal arteries. The *right capsular vein* terminates in the inferior cava, the *left* in the left renal vein.



Arteries and The *renal arteries* arise from the aorta immediately below the superior mesenteric artery, and run transversely to the hila of the kidneys. Both are covered by responding veins. The right is longer and rather lower than the left, and behind the vena cava. Each, after sending a small branch to the suprarenal gland and ureter, enters its kidney, not as a single trunk, but by several branches, corresponding to the original lobes of the organ. The *renal veins* lie behind the arteries, and join the vena cava at right angles. The left is longer than the right, and crosses over the aorta; it also receives the spermatic, capsular, and phrenic veins of its own side.

Genital Arteries The *spermatic arteries*, two in number, arise from the front of the aorta, a little below the renal, and pass to the testes in the male and to the ovaries in the female.

Veins. The *spermatic veins* run down behind the peritoneum, obliquely over the psoas, crossing over the front of the external iliac artery immediately above the crural arch, and the front of the right artery in addition lying over the vena cava. Each then passes through the internal abdominal ring and inguinal canal, with the other constituents of the spermatic cord, to the testicle, where it becomes tortuous and divides into several branches, some of which accompany the vas deferens and supply the epididymis; others supply the testis by piercing the tunica albuginea. Each artery is covered, below the external abdominal ring, by a very convoluted plexus of *ampulliform plexus*. At the inner ring they terminate in two tortuous branches which unite before they empty themselves, on the *right* side, obliquely, into the vena cava; on the *left* side at right angles into the left renal vein, after passing behind the sigmoid flexure of the colon. In the female the *ovarian arteries* arise from the aorta towards the pelvis, and lie between the two layers of the broad ligament. Some branches are tributed to the ovaries, some branches also going to the Fallopian tubes, and some to the side of the uterus to anastomose with the uterine artery of the internal iliac. They likewise send small offsets to the round ligament, and thence to the pubes and groin.

Arteries There are usually five of these arteries on each side; four arise from the back of the aorta, the fifth comes from the *arteria sacra media*. They are analogous to the costal arteries on a small scale. They proceed outwards over the bodies of the vertebrae beneath the sympathetic nerve and the arches formed by the psoas.

Branches. The two upper pass beneath the crura of the diaphragm; those on the lower being also behind the vena cava inferior. Passing towards the intervertebral foramina, they, like the intercostals, divide into dorsal and abdominal branches.

The *dorsal branches* pass between the transverse processes of the vertebrae, and are supplied by the posterior branches of the corresponding nerves, and are of a moderate size. They contribute to the large development of the muscles of the back, which they supply. They also send *spinal branches*, which enter the spinal canal through the vertebral foramina; some of these are distributed to the anterior part of the spinal cord, and others to the bodies of the lumbar vertebrae, forming a series of anastomoses behind them.

The *abdominal branches* all run outwards behind the quadratus lumborum, and the last, which usually runs in front. After supplying the quadratus and the psoas, they pass forwards between the abdominal muscles and supply the walls of the abdomen.* They anastomose, *laterally*, with the ilio-lumbar and circumflex

as the thoracic intercostals, by communicating with the internal mammary, and the arterial ring round the chest, so do the lumbar, by communicating with the ilio-lumbar, and the arterial ring round the walls of the abdomen.

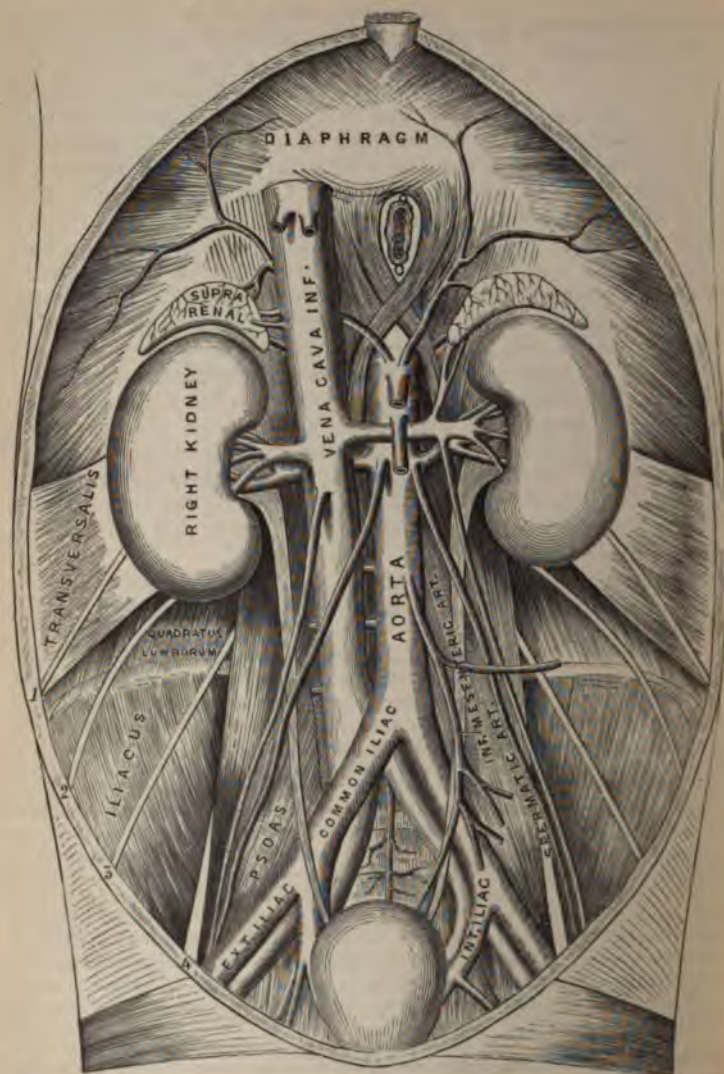


FIG. 167.—DIAGRAM OF THE COURSE AND RELATIONS OF THE ABDOMINAL AORTA AND VENA CAVA INFERIOR.

1. Ilio-hypogastric n. 2. Ilio-inguinal n. 3. External cutaneous n. 4. Anterior crural n.

cleaned, and, if more convenient, the student might dissect the muscles on one side, and the nerves and arteries on the other.

Psoas Fascia. The fascia covering the iliacus and psoas muscles is seen to be thin above and thicker below. It consists of two portions, the psoas and the iliac fascia. The *psoas fascia* is attached to the sides of the lumbar vertebræ and their intervertebral cartilages, internally to the sacrum, and above to the ligamentum arcuatum internum; externally it is thinner, and is continuous with the fascia lumborum. It is this sheath which determines the ordinary course of a psoas abscess—namely, beneath the crural arch into the upper part of the thigh; for it is a rare exception when the pus travels into the pelvis.

Iliac Fascia. The *iliac fascia* covers the iliacus muscle, and is attached to the inner lip of the crest of the ilium, and to the brim of the pelvis, through its connection with the sheath of the psoas and the tendinous insertion of the psoas parvus. Its most important attachment is to the outer half of the crural arch, and it is here directly continuous with the fascia transversalis (Fig. 154, p. 411), so that together they present an effectual barrier to the escape of intestine beneath this part of the arch.* On the inner half of Poupart's ligament these two fasciæ are separated by the femoral vessels, so that the fascia transversalis lies in front of, the fascia iliaca behind the artery and vein, thus forming their sheath as they pass down the thigh. This portion of the iliac fascia also forms a sheath for the psoas and iliacus as far as their insertion, and becomes continuous with the iliac portion of the fascia lata. Internally the iliac fascia is attached to the linea ilio-pectinea, where it becomes continuous with the pubic portion of the fascia lata. The external iliac artery and vein lie in front of the fascia, while the anterior crural nerve is behind it.

These fasciæ are now to be dissected off, when the psoas and iliacus will be completely exposed.

Psoas Magnus. This long muscle *arises* by five muscular fasciculi from the transverse processes of all the lumbar vertebræ, also from the bodies of the last dorsal and all the lumbar vertebræ and their intervening fibro-cartilages, but only from the projecting borders of their bodies, not from the central concave part; here the fibres arise from tendinous arches thrown over the lumbar vessels. The muscle descends vertically along the brim of

* The iliac fossæ are liable to be the seat of suppuration, and the course which the pus takes depends upon its position with regard to the iliac fascia. If the pus be seated in the loose cellular tissue between the peritoneum and the fascia, it usually advances just above the crest of the ilium, or towards the groin through the inguinal canal; but, if seated beneath the fascia, the pus usually makes its way under the crural arch towards the upper and outer part of the thigh.

iliac arteries; *in front*, with the internal mammary and epigastric arteries; and *above*, with the intercostals.

The *lumbar veins* empty themselves into the vena cava inferior, the left passing behind the aorta.

The *arteria sacra media*, a diminutive continuation of the aorta, proceeds from its bifurcation, and runs down, behind the left common iliac vein and in front of the sacrum, to the coccyx. It sends off the fifth lumbar artery and lateral branches, which anastomose with the lateral sacral arteries; it also supplies small vessels to the posterior part of the rectum, which run forwards between the layers of the meso-rectum. In close connection with the terminal branch of this artery at the tip of the coccyx is a small, roundish body called the *coccygeal* or *Luschka's gland*.* It is about the size of a pea, and is placed between the levatores ani and the sphincter ani. It is probably composed of a plexus of small arteries, which are surrounded by one or more layers of granular polygonal cells. The body itself is invested by connective tissue, in which also some branches from the ganglion impar have been traced. This gland should be considered as an arterial gland, of which the intercarotic ganglion is another example.

The *vena sacra media* empties itself into the left common iliac vein.

Vena Cava Inferior. The *vena cava inferior* is formed by the junction of the two common iliac veins, a little to the right side of the intervertebral cartilage between the fourth and fifth lumbar vertebræ. It ascends in front of the spine, in the greater part of its course lying to the right of the aorta. As it approaches the diaphragm, the vena cava inclines a little to the right, separated from the aorta by the right crus of the diaphragm. It is then received into a deep groove on the posterior border of the liver, and afterwards passes through the tendinous opening in the diaphragm to reach the right auricle of the heart. Its relations, beginning from below, are—*in front*, the mesentery, the third part of the duodenum, the pancreas, the right spermatic artery, the portal vein, and the liver; *behind* it are the right renal artery, the right lumbar arteries, the sympathetic of the right side, and the right phrenic artery; on its *left* is the aorta, and higher up the right crus. It receives the lumbar veins, the right spermatic (the left joins the renal), the renal, the right supra-renal, the right phrenic, and the hepatic veins which are usually three in number, one each from the right and left lobes, and one from the lobulus Spigelii.

The student should now direct his attention to the three large muscles which are seen at the back of the abdomen: the quadratus lumborum situated between the last rib and the crest of the ileum; the iliacus occupying the iliac fossa; and the psoas magnus passing from the sides of the lumbar vertebræ, along the brim of the pelvis, and beneath Poupart's ligament, to be inserted into the lesser trochanter of the femur. The nerves should at the same time be

* Callender, *British Medical Journal*, June 13, 1874.

cleaned, and, if more convenient, the student might dissect the muscles on one side, and the nerves and arteries on the other.

Psoas Fascia.

The fascia covering the iliacus and psoas muscles is seen to be thin above and thicker below. It consists of two portions, the psoas and the iliac fascia. The *psoas fascia* is attached to the sides of the lumbar vertebræ and their intervertebral cartilages, internally to the sacrum, and above to the ligamentum arcuatum internum; externally it is thinner, and is continuous with the fascia lumborum. It is this sheath which determines the ordinary course of a psoas abscess—namely, beneath the crural arch into the upper part of the thigh; for it is a rare exception when the pus travels into the pelvis.

Iliac Fascia.

The *iliac fascia* covers the iliacus muscle, and is attached to the inner lip of the crest of the ilium, and to the brim of the pelvis, through its connection with the sheath of the psoas and the tendinous insertion of the psoas parvus. Its most important attachment is to the outer half of the crural arch, and it is here directly continuous with the fascia transversalis (Fig. 154, p. 411), so that together they present an effectual barrier to the escape of intestine beneath this part of the arch.* On the inner half of Poupart's ligament these two fasciæ are separated by the femoral vessels, so that the fascia transversalis lies in front of, the fascia iliaca behind the artery and vein, thus forming their sheath as they pass down the thigh. This portion of the iliac fascia also forms a sheath for the psoas and iliacus as far as their insertion, and becomes continuous with the iliac portion of the fascia lata. Internally the iliac fascia is attached to the linea ilio-pectinea, where it becomes continuous with the pubic portion of the fascia lata. The external iliac artery and vein lie in front of the fascia, while the anterior crural nerve is behind it.

These fasciæ are now to be dissected off, when the psoas and iliacus will be completely exposed.

Psoas Magnus.

This long muscle *arises* by five muscular fasciculi from the transverse processes of all the lumbar vertebræ, also from the bodies of the last dorsal and all the lumbar vertebræ and their intervening fibro-cartilages, but only from the projecting borders of their bodies, not from the central concave part; here the fibres arise from tendinous arches thrown over the lumbar vessels. The muscle descends vertically along the brim of

* The iliac fossæ are liable to be the seat of suppuration, and the course which the pus takes depends upon its position with regard to the iliac fascia. If the pus be seated in the loose cellular tissue between the peritoneum and the fascia, it usually advances just above the crest of the ilium, or towards the groin through the inguinal canal; but, if seated beneath the fascia, the pus usually makes its way under the crural arch towards the upper and outer part of the thigh.

the pelvis, beneath the crural arch into the thigh, and is *inserted* by a strong tendon into the back part of the lesser trochanter of the femur. *In front*, the psoas has in relation with it the psoas fascia, the ligamentum arcuatum internum, the common and external iliac artery and vein, the kidney and ureter, the spermatic vessels, the genito-

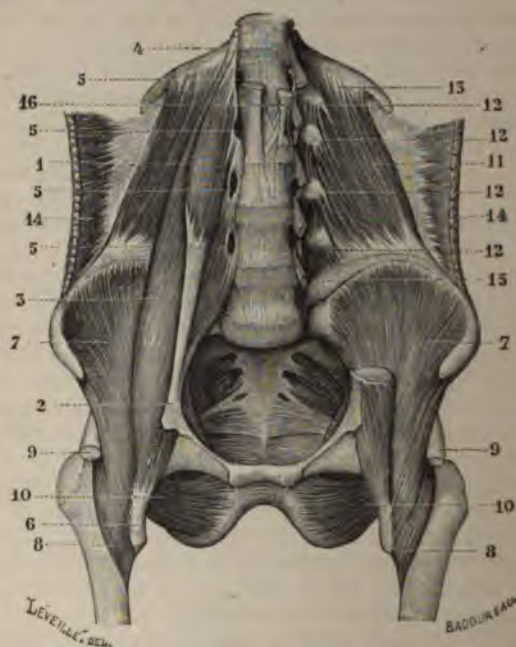


FIG. 168.—PSOAS, ILIACUS, AND QUADRATUS LUMBORUM MUSCLES.

1. Psoas parvus. 2. Its tendon cut at its attachment to iliac fascia. 3. Psoas magnus. 4. Its origin from the body of the twelfth dorsal vertebra. 5, 5, 5, 5. Its origin from the four lumbar vertebrae, showing the fibrous arch for each. 6. Tendon of insertion to the lesser trochanter. 7, 7. Iliacus. 8, 8. Inferior and external fibres, inserted on an anterior plane below the lesser trochanter. 9, 9. Rectus femoris. 10, 10. Obturator externus. 11. Quadratus lumborum. 12, 12, 12, 12. Posterior fasciculi attached to the transverse processes of the four upper lumbar vertebrae; the long fasciculi covering these processes have been removed, to allow the posterior to be seen. 13. The external fasciculi larger than the posterior are inserted into the twelfth rib by a short aponeurosis. 14, 14. Transversalis. 15. Ilio-lumbar ligament. 16. The two crura of the diaphragm.

crural nerve, the colon, the renal vessels, the vas deferens, the psoas parvus when present; *behind* it are the ilium, the transverse processes of the lumbar vertebrae, the quadratus lumborum, the anterior layer of the transversalis aponeurosis, the lumbar plexus of nerves, and the obturator nerve, which lower down runs along the inner

border of the muscle ; on its *inner side* are—the crus of the diaphragm, the bodies of the lumbar vertebræ, the lumbar arteries, the lumbar glands, and the sympathetic nerves ; to the inner side of the left psoas is the aorta, and to that of the right psoas is the inferior vena cava. Towards its insertion the tendon of the psoas lies between the iliacus and pectineus.

As it passes under the crural arch, the tendon of the psoas lies immediately over the capsule of the hip-joint, and there is a large bursa between them to facilitate the play of the tendon. It should be borne in mind that occasionally, even in young subjects, but more frequently in old ones, in consequence of wear and tear, this bursa communicates with the hip-joint. The fact is important, for it explains how a psoas abscess sometimes makes its way into the hip-joint, a result frequently fatal.

Psoas Parvus. Once in about eight or ten subjects there is a small muscle called the *psoas parvus* placed superficially to the preceding muscle. It *arises* from the sides of the bodies of the last dorsal and the first lumbar vertebræ, and the intervening fibro-cartilage ; thence, descending in front, and to the inner side of the psoas magnus, it ends in a long flat tendon, which spreads out, and is *inserted* into the linea ilio-pectinea.

Iliacus. The iliacus *arises* from the iliac fossa, the inner lip of the crest of the ilium, the ilio-lumbar ligament,* the base of the sacrum, and the anterior superior spine of the ilium ; below, also from the anterior inferior spine and from the capsule of the hip-joint. The fibres converge beneath the crural arch, and are *inserted* mainly into the outer side of the tendon of the psoas, and partly into the triangular surface of the femur, below and anterior to the lesser trochanter. Thus the two muscles, so far as their action goes, may be considered as one, and are sometimes called the ilio-psoas.

The iliacus in the abdomen is in relation, *in front*, with the iliac fascia, the external cutaneous and anterior crural nerves, with the cæcum on the right, and with the sigmoid flexure on the left side ; *behind*, it is in contact with bone ; on its *inner side* is the psoas. In the thigh it is in relation, *in front*, with the rectus, the sartorius, the fascia lata, the anterior crural nerve, the profunda femoris and the external circumflex arteries ; *behind*, with the capsular ligament of the hip-joint ; on the *inner side*, with the psoas ; and on the *outer*, with the crureus and vastus internus muscles.

The combined *action* of the psoas and iliacus is to assist in raising the body from the recumbent position, and to fix the pelvis steadily

* This ligament extends from the transverse process of the last lumbar vertebra to the ilium.

on the thigh; this supposes the fixed point to be at the trochanter minor. If the fixed point be at the spine, then the muscle flexes and rotates the femur outwards.* It is this action which often occasions so much displacement in fractures of the upper third of the femur.

**Quadratus Lum-
borum and its
Sheath.**

This quadrilateral muscle extends from the crest of the ilium to the last rib, and is contained in a sheath formed for it by the aponeurotic origin of the transversalis (Fig. 166).

The anterior layer of its sheath is attached to the roots of the *transverse* processes of the lumbar vertebræ, and the posterior layer to their summits. The muscle, broader below than above, *arises* by two portions—one from the ilio-lumbar ligament and from the crest of the ilium for two inches (5 cm.) external to it, and is *inserted* into the last rib, and by tendinous slips into the apices of the *transverse* processes of the upper four lumbar vertebræ; the other portion of the muscle arises from the *transverse* processes of the third, fourth, and fifth lumbar vertebræ, and is inserted into the lower margin of the last rib, in front of the preceding portion. The principal use of the muscle is to steady the spine; it also steadies the last rib, and enables it to serve as a fixed point for the action of the intercostal muscles and the diaphragm.†

By raising the quadratus, we observe the aponeurotic origin of the transversalis from the summits of the *transverse* processes; this constitutes the posterior part of its sheath, and separates the muscle from the erector spinæ.

**Common Iliac
Arteries and Veins.**

The abdominal aorta divides, in front of the left side of the fourth lumbar vertebra, into two great branches, termed the *common iliac arteries*. They diverge at an acute angle, and after a course of about two inches (5 cm.) downwards and outwards, each divides, over the sacro-iliac symphysis, into the external and internal iliac arteries. They lie upon the bodies of the fourth and fifth lumbar vertebræ. The right common iliac is rather larger than the left. They are covered *in front* by peritoneum, they are crossed by branches

* It is easy to demonstrate that the action of the psoas magnus is an internal rotator, although the angle which the neck of the femur makes with its neighbours favors a view to the contrary; but when it is remembered that the insertion is on an anterior plane to the axis of rotation, it is undoubtedly an internal rotator. (A. H.)

† The respective attachments of the quadratus lumborum, the crossing of its fibres, and its mode of action, lead to the inference that it is a large intercostal muscle. It is worth remembering that the outer edge of the quadratus lumborum, in a well-grown adult, is about three inches (7.5 cm.) from the spines of the lumbar vertebræ, and midway between the last rib and the crest of the ilium. It is just outside the edge of this muscle that we can cut down to open the large bowel without wounding the peritoneum.

of the sympathetic to form the hypogastric plexus, and they are crossed at or near their division by the ureters; on the *outer side* they are in relation with the psoas. So far, then, the relations of both common iliac arteries are similar. But each has its special relations as follows:—

The special relations of the right common iliac are, that it has *behind* it the two common iliac veins, which separate it from the fifth lumbar vertebra; on its *outer side*, it has, above, the inferior vena cava; below, the right common iliac vein.

The special relations of the left common iliac are, that it has *in front* of it the end of the sigmoid flexure of the colon, and the superior hæmorrhoidal artery; and to its *inner side*, the left common iliac vein, which gradually gets more behind it towards the sacro-iliac symphysis.

The relations of these arteries with regard to their corresponding veins are practically important in reference to the operation of tying them. This operation is, obviously, easier on the left side than the right.*

If the common iliac artery were ligatured, the collateral circulation would be maintained through the following vessels: by the internal mammary anastomosing with the deep epigastric a.; by the lumbar arteries with the circumflex iliac and the ilio-lumbar a.; by the lumbar with the gluteal; by the middle sacral with the lateral sacral a.; by the spermatic with the deferential, cremasteric, external pudic, and superficial perineal arteries; by the superior hæmorrhoidal with the middle and inferior hæmorrhoidal a.; by the lower intercostals with the epigastric a. (superficial and deep); and by the middle and inferior hæmorrhoidal, the pudic and its branches, and the vesical arteries communicating in the middle line with the corresponding branches of the opposite side.

External Iliac Artery.

The *external iliac artery*, the continuation of the preceding artery, passes along the brim of the pelvis, first on the inner side, and then in front of the psoas. Lower down it passes under the crural arch, midway between the anterior superior spine of the ilium and the symphysis pubis, where it takes the name of femoral. The artery has

* The length of the common iliac artery is apt to vary in different persons. We have seen it from three-fourths of an inch to three and a half inches (*18 mm. to 8.8 cm.*) long. These varieties may arise either from a high division of the aorta, or a low division of the common iliac, or both. It is impossible to ascertain, beforehand, its length in any given instance, as there is no necessary relation between its length and the height of the adult individual. It is often very short in men of tall stature, and *vice versa*. The left is usually described as rather longer than the right; but, from the examination of 100 bodies, our conclusion is that their average length is the same.

in front of it, the peritoneum, the intestines, and a sheath derived from the iliac fascia investing the artery and the vein; it has also the spermatic vessels in front, and it is crossed by a branch of the genito-crural nerve, the deep circumflexa ilii vein, and the vas deferens; *behind*, it is in relation with the psoas magnus and corresponding vein, which lies also on the inner side of the artery; the iliac fascia also lies behind the vessels, but a thin layer of fascia derived from it is continued over them; *internally*, it has the corresponding vein, and low down, towards Poupart's ligament, the vas deferens; *externally*, it has the psoas magnus and the iliac fascia. In front of and on the inner side of the artery are a chain of lymphatic glands.

The branches given off by this artery are:—

a. *Small branches* to the psoas and lymphatic glands.

b. The *deep epigastric*, already described (p. 412).

c. The *deep circumflexa ilii*, which arises from the outer side of the artery, just above the crural arch, and, ascending upwards towards the anterior superior spine of the ilium in a sheath formed by the fascia iliaca, runs along the inner aspect of the iliac crest, and subsequently perforates the transversalis muscle.* In the dissection of the abdominal muscles (p. 412), the continuation of it was seen skirting the crest of the ilium between the internal oblique and the transversalis, and sending a branch upwards between these muscles for their supply. The main trunk, much reduced in size, inosculates with the ilio lumbar derived from the internal iliac.

Sympathetic Nerve. The general plan upon which the sympathetic nerve is arranged has been noticed in the dissection of the neck (p. 164). The lumbar portion of it must now be examined.

The lumbar portion of the sympathetic descends on each side in front of the bodies of the lumbar vertebræ, along the inner border of the psoas. The nerve has an oval ganglion of greyish colour opposite each lumbar vertebra, so that there are either four or five of them on each side. These ganglia are connected together by small filaments of a white colour, and each ganglion receives, on its outer side, two branches from the corresponding spinal nerve, as in the chest; other branches pass inwards, and form in front of the aorta—the *aortic plexus*; and some pass downwards over the common iliac arteries to form the hypogastric plexus.

Solar Plexus and the Semilunar Ganglia.

The *solar* or *epigastric plexus* is situated in front of the aorta, and surrounds the coeliac axis in a dense network of nerve filaments, in which are several ganglia. It receives the great splanchnic nerves, part of the lesser splanchnic, and some branches from the pneumogastric nerves. The solar plexus gives

* The course of this artery should be borne in mind in opening iliac abscesses.

off filaments which form plexuses surrounding the various branches of the abdominal aorta, and are as follows:—

Diaphragmatic.	Supra-renal.
Coeliac.	Renal.
Gastric.	Spermatic.
Hepatic.	Superior mesenteric.
Splenic.	Inferior mesenteric.
Hypogastric.	

The *diaphragmatic plexus* is derived from the upper part of the semilunar ganglion, and is larger on the right than on the left side. It joins with some filaments of the phrenic nerve, and whilst in relation with the supra-renal body it gives off some branches to it. The right plexus has a small ganglion in it—*diaphragmatic ganglion*—and sends off filaments to the vena cava inferior and to the hepatic plexus.

The *coeliac plexus* receives branches from the lesser splanchnic nerve, and, on the left side, it receives a filament from the right pneumogastric nerve. It divides into the gastric, hepatic, and splenic plexuses, which ramify on the corresponding arteries and their branches; the *gastric plexus* receives in addition filaments from the pneumogastric nerves; the *hepatic plexus*, the largest, is joined by branches from the left pneumogastric and right phrenic nerves, and it distributes filaments to the right supra-renal plexus; the *splenic plexus* is formed by branches from the left semilunar ganglion and the right pneumogastric nerve.

The *supra-renal plexus* is formed by branches from the solar plexus, the semilunar ganglion, and the diaphragmatic plexus, and is larger on the right than on the left side.

The *renal plexus* consists of numerous filaments from the semilunar ganglion, and from the solar and aortic plexuses; it is also reinforced by branches from the splanchnic nerves. From this plexus is given off—

The *spermatic plexus*, which likewise receives filaments lower down from the aortic plexus; in the female it takes the name of the *ovarian plexus*.

The *superior mesenteric plexus* receives, in addition to its branches from the solar plexus, some filaments from the right pneumogastric nerve and the coeliac plexus. It is the densest of all the plexuses derived from the solar plexus, and it breaks up into secondary plexuses corresponding to the branches of the artery of the same name.

The *inferior mesenteric plexus* comes mainly from the left side of the aortic plexus.

Hypogastric Plexus. The *hypogastric plexus* is situated between the common iliac arteries on the last lumbar vertebra and the sacrum. It consists of an intricate interlacement of sympathetic filaments, which pass down into the pelvis, for the supply of the pelvic viscera. Although this plexus is so intricate it presents no distinct ganglia. As it passes down it receives branches from some of the spinal nerves, but mainly from the third and fourth sacral nerves. From this large plexus are derived secondary plexuses, which ramify around branches of the internal iliac artery: thus there are, the inferior hæmorrhoidal plexus, the vesical, the uterine, the ovarian, the prostatic, and the vaginal; all of which send filaments which accompany the smallest branches of the arteries.

Lumbar Plexus of Nerves.

The *lumbar plexus* is formed by the union of the anterior branches of the four upper lumbar nerves and is frequently connected with the last dorsal nerve by a small loop—the dorsi-lumbar nerve. The fifth does not enter into the formation of this plexus, but joins the sacral plexus under the name of the lumbo-sacral cord. The plexus lies over the transverse processes of the corresponding vertebrae, embedded in the substance of the psoas, so that this muscle must be dissected away before the plexus can be seen. Like the brachial plexus, the nerves composing it successively increase in size from above. Its branches are five in number, and arise in the following order (Fig. 169).



FIG. 169. PLAN OF THE LUMBAR PLEXUS AND BRANCHES.

- a.* Ilio-hypogastric n. *b.* Ilio-inguinal n. *c.* External cutaneous n. *d.* Anterior crural n. *e.* Crural branch of genito-crural n. *f.* Obturator n. *g.* Genital branch of genito-crural n. *h.* Lumbo-sacral n. 1. First lumbar n. 2. Second lumbar n. 3. Third lumbar n. 4. Fourth lumbar n. 5. Fifth lumbar n.

the spermatic cord, comes out through the external abdominal ring and supplies the skin of the inner and upper part of the thigh, of the penis and scrotum in the male, and of the labium in the female.

The *genito-crural nerve* is small, and comes from the second lumbar, and by a few filaments from the communicating branch of the first. After perforating the psoas, it lies for a short distance upon its anterior surface, and then runs down along the outer side of the external iliac artery. Near the crural arch it divides into the *genital branch* (*g*), which runs down on the external iliac artery, and,

so that this muscle must be dissected away before the plexus can be seen. Like the brachial plexus, the nerves composing it successively increase in size from above. Its branches are five in number, and arise in the following order (Fig. 169).

a. The *first lumbar nerve* generally divides into two branches, the upper being the ilio-hypogastric, the lower the ilio-inguinal. They pass downwards and outwards nearly parallel with each other, cross obliquely over the quadratus lumborum to the crest of the ilium, and then separate.

The *ilio-hypogastric nerve* emerges from the outer border of the psoas, and crossing the quadratus lumborum, passes forwards to the crest of the ilium, where it pierces the transversalis and divides into its two terminal branches—the *iliac* branch, which pierces the internal and external oblique muscles and supplies the skin over the gluteal region, behind the last dorsal nerve; and the *hypogastric* branch, which runs forwards between the transversalis and internal oblique, and then perforates the aponeurosis of the external oblique to supply the skin of the hypogastric region.

The *ilio-inguinal nerve*—the smaller—comes through the psoas and perforates the transversalis close to the front of the iliac crest, where it communicates with the preceding nerve. It then pierces the internal oblique, and lying in front of

piercing the fascia transversalis, descends through the internal abdominal ring, along the inguinal canal, on the posterior aspect of the spermatic cord; it supplies the cremaster in the male, and the round ligament in the female; and the *crural* branch (*e*), which proceeds under the crural arch, enters the sheath of the femoral vessels, and, piercing the anterior layer of the sheath, just external to the artery, is lost in the skin of the upper part of the front of the thigh; here it communicates with the middle cutaneous nerve and supplies also a few filaments to the femoral artery, where it perforates the sheath of that vessel.

The *external cutaneous nerve of the thigh* (*c*) is generally derived from the loop between the second and third lumbar nerves. It runs through the psoas, then, crossing obliquely over the iliacus towards the anterior superior spine of the ilium, passes beneath the crural arch, and is finally distributed to the skin on the outside of the thigh. If the external cutaneous be not found in its usual situation, look for it as a distinct branch of the anterior crural, nearer the psoas muscle. 3rd.

The *anterior crural* (*d*), the largest and most important branch, is formed by the union of the third and fourth lumbar nerves, receiving a small branch from the second. It descends in a groove between the psoas and the iliacus behind the fascia iliaca, supplies both these muscles and a branch to the femoral artery, and then, passing under the crural arch to the outer side of the femoral artery, is finally distributed to the extensor muscles of the knee, to the sartorius and pectineus, and the skin of the thigh and leg.

The *obturator nerve* (*f*), next in size to the anterior crural, proceeds from the third and fourth lumbar nerves, and sometimes from the second. It descends through the psoas muscle, and then, getting to its inner border, runs along the brim of the pelvis above its corresponding vessels to the obturator foramen, through the upper part of which it passes to the adductor muscles of the thigh.

The *accessory obturator nerve*, by no means a constant branch, is derived from the third and fourth lumbar nerves, and sometimes from the obturator nerve. It runs down along the inner border of the psoas, passes in front of the horizontal ramus of the os pubis, supplies the pectineus, and gives off a small branch to the hip-joint, and another to communicate with the anterior branch of the obturator nerve.

Postponing the minute anatomy of the abdominal viscera, begin the examination of the contents of the pelvis.

DISSECTION OF THE PELVIC VISCERA.

The functions of the pelvis are to protect its own viscera; to support those of the abdomen; to give attachment to the muscles which steady the trunk; to transmit the weight of the trunk to the lower limbs, and to give origin to the muscles which move them. In adaptation to these functions, the form of the pelvis is that of an arch, with broadly expanded wings at the sides, and projections in appropriate situations to increase the leverage of the muscles. The sacrum, impacted between the ilia, represents the keystone of the arch, and is capable of supporting not only the trunk, but great burdens besides. The sides or pillars are represented by the ilia; these transmit the weight to the heads of the thigh-bones, and are thickest and strongest just in that line, *i. e.*, the brim of the pelvis, along which the weight is transmitted. Moreover, to effect the direct transmission of the weight, the plane of the arch is oblique.

This obliquity of the pelvis, its hollow expanded sides, its great width, the position and strength of the tuberosities of the ischia, are so many proofs that man is adapted to the erect posture.

The general conformation of the pelvis in the female is modified, so as to be adapted to utero-gestation and parturition. Its breadth and capacity are greater than in the male. Its depth is less. The alæ of the iliac bones are more expanded. The projection of the sacrum is less perceptible, and consequently the brim is more circular. The depth of the symphysis pubis is less, the span of the pubic arch is wider. The bones, too, are thinner, and the muscular impressions less strongly marked.

The cavity of the pelvis being curved, the axis, or a central line drawn through it, must be curved in proportion. For all practical purposes, it is sufficient to remember that the axis of the pelvis corresponds with a line drawn from the anus to the umbilicus.*

Contents of the Male Pelvis.

The male pelvis contains the last part of the intestinal canal (named the rectum), the bladder with the prostate gland at its neck, and the vesiculæ seminales. If the bladder be empty, some of the small intestine will be in the pelvis; not so if the bladder be distended.

The relative positions of these pelvic viscera are as follows: most posteriorly is the rectum, which follows the curve of the sacrum and coccyx, and ends at the anus; immediately in front is the oval hollow viscus, the bladder, which alters in size and position according to the amount of urine it contains; in front of the

* In a well-formed female the base of the sacrum is $3\frac{3}{4}$ inches higher than the upper part of the symphysis pubis, and the point of the coccyx is rather more than half an inch higher than the lower part of the symphysis. The obliquity of the pelvis is greatest in early life. In the fetus, and in young children, its capacity is small, and the viscera, which subsequently belong to it, are situated in the abdomen.

The relative diameters of the male and the female true pelvis are as follows:—

	MALE.						FEMALE.					
	Brim.		Cavity.		Outlet.		Brim.		Cavity.		Outlet.	
	In.	Cm.	In.	Cm.	In.	Cm.	In.	Cm.	In.	Cm.	In.	Cm.
Transverse, . .	$4\frac{1}{2}$	(11.3)	$4\frac{1}{2}$	(11.3)	$3\frac{1}{2}$	(8.8)	$5\frac{1}{4}$	(13.1)	5	(12.5)	$4\frac{1}{4}$	(11.8)
Oblique, . . .	$4\frac{1}{4}$	(10.6)	$4\frac{1}{2}$	(11.3)	4	(10.0)	5	(12.5)	$5\frac{1}{4}$	(13.1)	$4\frac{3}{4}$	(11.8)
Antero-posterior, . . .	4	(10.0)	$4\frac{1}{2}$	(11.3)	$3\frac{3}{4}$	(8.1)	$4\frac{1}{2}$	(11.3)	$5\frac{1}{4}$	(13.1)	5	(12.5)

bladder, surrounding its neck, and behind the os pubis, is the prostate gland. Placed beneath the bladder are the vesiculæ seminales, and curving round the sides of the bladder are the vasa deferentia, which subsequently lie beneath the base of the bladder. Passing downwards and inwards over the brim of the pelvis are the ureters, which likewise get beneath the fundus vesicæ. The bladder and the rectum are partially invested with peritoneum. Besides the pelvic viscera just enumerated, there are found, to the outer part of the pelvic cavity, the internal iliac artery and its branches, and the sacral plexus of nerves, with the obturator nerve running forwards to the obturator foramen. All the pelvic viscera are more or less invested by prolongations from the pelvic fascia, which constitute some of the true ligaments of the bladder; also a capsule for the prostate, and coverings for the pelvic muscles. The superior hæmorrhoidal artery, the continuation of the inferior mesenteric, passes down into the pelvis, and supplies the upper half of the rectum. Some of these structures will now be described, while others can be better dissected in the side view of the pelvis.

Course of the Rectum.

The rectum enters the pelvis on the left side of the sacrum, and, after describing a curve corresponding with the concavity of the sacrum, terminates at the anus. In the first part of its course it is loosely connected to the back of the pelvis by a peritoneal fold, called the *meso-rectum*: between the layers of this fold, the superior hæmorrhoidal vessels, the continuation of the inferior mesenteric, with nerves and lymphatics, runs to the bowel.

The rectum does not take this course in all cases; sometimes it makes one, or even two lateral curves. In some rare cases it enters the pelvis on the right side instead of the left. Since these variations from the usual arrangement cannot be ascertained during life, they should make us cautious in the introduction of bougies.*

Recto-vesical Pouch. Whilst the parts are still undisturbed, introduce the finger into the *recto-vesical peritoneal pouch* (Fig. 170). This is a cul-de-sac formed by the peritoneum in passing from the front of the rectum to the lower and back part of the bladder. In the adult male, the bottom of this pouch is about one inch (2.5 cm.) distant from the base of the prostate gland; † therefore part of the under surface of

* In old age the rectum has sometimes a zigzag appearance immediately above the anus. These lateral inclinations are probably produced by the enormous distensions to which the bowel has been occasionally subjected.

† The bottom of the pouch is from three to four inches (7.5 to 10 cm.) distant from the anus.

the bladder is not covered by peritoneum; and since this part is in immediate contact with the rectum, it is practicable to tap the distended bladder through the front of the bowel without injuring the peritoneum. It sometimes happens that the peritoneal pouch comes down nearer to the prostate than usual—we have seen it in actual contact with the gland; so that, in such a case, it would be impossible to tap the bladder from the rectum without going through the peritoneum. In children the peritoneum comes down lower than it does in the adult, because the bladder in the child is not a pelvic viscus.

The recto-vesical pouch is permanent. But there is another peritoneal pouch on the front part of the bladder, which is only

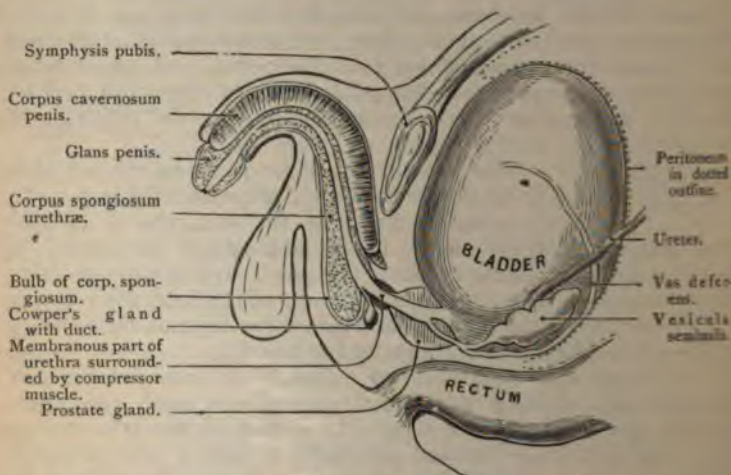


FIG. 170.—DIAGRAM OF THE RELATIVE POSITION OF THE PELVIC VISCERA.

produced when the bladder is distended. To produce it, the bladder should be blown up through one of the ureters. The bladder soon fills the pelvis, and then, rising into the abdomen, occasions the pouch between it and the abdominal wall. At first the pouch is shallow, but it gradually deepens as the bladder rises. If the bladder be distended half-way up to the umbilicus, which is commonly the case when it has to be tapped, we find that the bottom of the pouch would be about two inches (5 cm.) from the symphysis pubis (Fig. 170). Within this distance from the symphysis, the bladder may be tapped in the linea alba, without risk of wounding the peritoneum. Thus, the surgeon has the

choice of two situations in which he may tap the bladder—above the os pubis, or from the rectum. Which of the two be more appropriate, must be decided by the circumstances of the case.

False Ligaments of the Bladder. The reflections of the peritoneum from the pelvic walls to the bladder constitute the *false ligaments of the bladder*, and they can be best examined before the viscera are disturbed, although they will be described when the bladder itself is dissected.

The *two posterior* pass forwards from the sides of the rectum to the back of the bladder, forming the lateral boundaries of the deep recto-vesical pouch. Each contains within its duplicature the obliterated hypogastric artery, the ureter, together with some vessels and nerves.

The *two lateral* pass inwards from the sides of the pelvis to the sides of the bladder.

The *superior* passes upwards from the summit of the bladder to the back of the anterior abdominal wall, covering the urachus and the obliterated hypogastric arteries.

Contents of the Female Pelvis. The relative positions of the pelvic viscera in the female should now be examined, leaving the special description till a later stage.

General Position of the Uterus and its Appendages. The uterus is interposed between the bladder in front and the rectum behind. From each side of it a broad fold of peritoneum extends transversely to the side of the pelvis, dividing that cavity into an anterior and a posterior part. These folds are called the *broad ligaments* of the uterus (Fig. 192, p. 520). On the posterior surface of the ligament are the ovaries, one on each side. They are completely covered by peritoneum, and suspended to the ligament by a small peritoneal fold. Each ovary is attached to the uterus by a cord termed the *ligament of the ovary*. Along the upper part of the broad ligament we find between its layers a tube about four inches (10 cm.) long, called the *Fallopian tube*, which conveys the ovum from the ovary into the uterus. For this purpose one end of it terminates in the uterus, while that nearer to the ovary expands into a wide mouth, furnished with prehensile fringes—*fimbriæ*—which, like so many tentacles, grasp the ovum as soon as it escapes from the ovary. One of these fimbriæ is attached to the ovary. Lastly, there run up to the ovary, between the layers of the broad ligament, the ovarian vessels, which arise from the aorta in the lumbar region, like the spermatic arteries in the male, because the ovaries are originally formed in the loins.

On the anterior surface of the broad ligament, on either side between its layers, is the *round ligament* of the uterus. This cord proceeds from the fundus of the uterus, anterior to the Fallopian

the peritoneum in the male. It is called the *canal of*

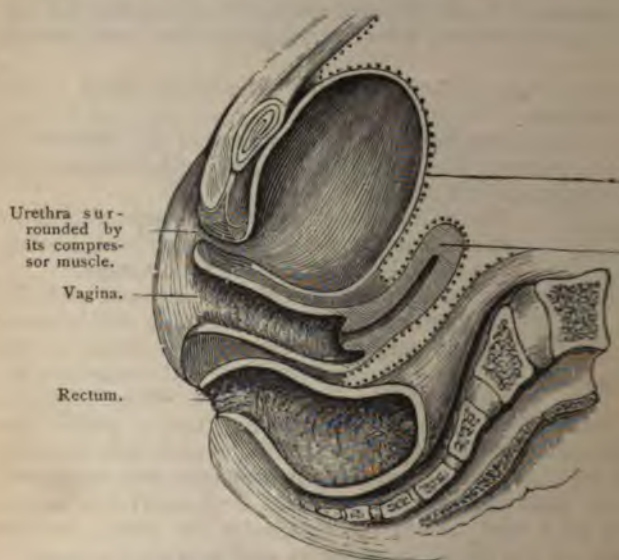


FIG. 171.—VERTICAL SECTION THROUGH THE FEMALE PELVIC VISCERA.

generally obliterated in the adult. It is sometimes the
inguinal hernia.

Reflections of the

From the front of the rectum the
is reflected on to a small part of the

In cases of ascites the fluid might distend the recto-vaginal pouch, and bulge into the vagina, so that it would be practicable to draw it off through this channel.

DISSECTION OF THE MALE PERINEUM.

Before dissecting the perineum, it is expedient first to examine the osseous and ligamentous boundaries of the lower aperture of the pelvis. Looking at the male pelvis (with the ligaments preserved), we observe that this aperture is of a lozenge shape; that it is bounded *front* by the pubic arch and the subpubic ligament; *laterally*, anteriorly, by the rami of the os pubis and ischium, and by the tuberosity of the ischium, posteriorly, by the great sciatic ligament; and *behind*, by the tip of the coccyx.

This space, for convenience of description, is subdivided into two by a line drawn from one tuber ischii to the other. The anterior forms a nearly equilateral triangle, of which the sides are from three to three and a half (7.5 to 8.8 cm.) inches long; and, since it transmits the urethra, it is called the *urethral region* of the perineum. The posterior, containing the anus, is called the *ischio-rectal* or *anal region* (Fig. 172).*

The subject should be placed in the usual position for lithotomy, with a block placed beneath the pelvis. A full-sized staff should now be passed into the bladder, the rectum moderately distended with tow, and the scrotum raised by means of hooks. A central ridge, named the *raphé*, extends from the anus, along the perineum, scrotum, and under surface of the penis. Between the tuberosities of the ischia and the anus are two depressions, one on each side, marking the *ischio-rectal fossæ*, which are found immediately beneath the skin, filled with more or less fat. In the lateral operation of lithotomy, the incision should commence at a point midway between the anus and the posterior fold of the scrotum, close to the left side of the raphé; it should be carried downwards and outwards to a point midway between the tuber ischii and the anus. In the bilateral operation, the incision is semilunar, the horns being made on either side between the tuber ischii and the anus, equidistant from these points respectively; while the centre of the

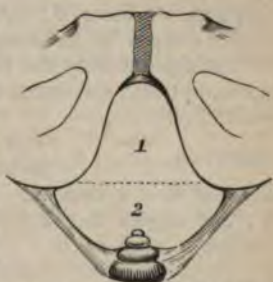

FIG. 172.—DIAGRAM OF THE FRAMEWORK OF THE PERINEUM.

* The dimensions of the lower outlet of the pelvis are apt to vary in different subjects, and the lithotomist must modify his incision accordingly.

incision runs about three-quarters of an inch (18 mm.) above the anus.

Anal Glands.

At the anus the skin becomes finer and more delicate, forming a gradual transition towards mucous membrane: during life it is drawn into wrinkles by the permanent contraction of the cutaneous sphincter. Moreover, the skin at the margin of the anus is provided with numerous minute glands,* which secrete an unctuous substance to facilitate the passage of the feces. When this secretion becomes defective or vitiated, the anal cutaneous folds are apt to become excoriated, chapped, or fissured; and then defæcation becomes very painful. At the margin of the anus a thin white line can be distinguished, indicating, not only the junction of the skin with the mucous membrane, but also the linear interval between the external and internal sphincters.

Dissection.

The skin should be reflected by making an incision along the raphé, round the margin of the anus to the coccyx. Two others must be made on each side at right angles to the first, the one at the upper, and the other at the lower end of it. The skin of the perineum must then be

Subcutaneous Tissue.

reflected outwards with much care, otherwise the superficial sphincter ani may be reflected with the skin. In reflecting the skin notice the characters of the subcutaneous structure.† Its characters alter in adaptation to the exigencies of each part. On the scrotum the fibrous element of the tissue is entirely absent; while the connective tissue element is most abundant, and during life elastic and contractile. But, towards the deeper part of the anus the fat accumulates more and more, and on either side of

Fat in Ischio-rectal Fossæ.

the rectum it is found in the shape of large masses, filling up what would otherwise be two deep hollows in this situation—namely, the *ischio-rectal fossæ*. These fossæ are pyramidal, with their bases towards the skin, and their apices at the divergence of the obstructor internus and levator ani. They are about two inches (5 cm.) in depth, and much deeper posteriorly than in front. This accumulation of fat on each side of

* These glands are the analogues of the anal glands in some animals, e.g., the dog and the beaver. They are found not only about the anus, but also in the subcutaneous tissue of the perineum, a fact for the demonstration of which we are indebted to the late Professor Quekett. They are large enough to be seen with the eye.

† The probable thickness of this subcutaneous tissue is a point which ought to be borne in mind by the lithotomist in making his first incision. Its great thickness explains the depth to which the surgeon has to cut in letting out the urine from the ischio-rectal fossa.

is permits the easy distension and contraction of the lower the bowel during and after the passage of the fæces. Over the ischia are large masses of fat, separated by fibrous septa, passing from the skin to the bone, so as to form an elastic padding to sit upon. Occasionally, too, there are more large *bursæ* interposed between this padding and the

skin respecting the general characters of the subcutaneous tissue of the perineum. Some anatomists describe it as consisting of three, four, or even more layers, but in nature we do not find it so, may, indeed, be divided into as many layers as we please, according to our skill in dissection; but this only complicates what is itself, simple.

External Sphincter ani. The external sphincter ani must now be cleaned, care being taken not to remove any of the integuments, which are intimately connected with the skin. Posteriorly the lower border of the gluteus maximus must be displayed, and the cutaneous vessels and nerves crossing the perineum, towards the anus, must be dissected.*

Internal Sphincter. The *external sphincter* of the anus is elliptical, and is composed of a thin layer of striped muscular tissue about an inch (2.5 cm.) in length. It arises from the tip of the coccyx and the anal ligament. The muscular fibres surround the anus, and are inserted in a pointed manner in the tendinous centre of the rectum, in conjunction with the transversus perinei, the accelerator, and the levator ani (Fig. 173, p. 471). It is called the *internal sphincter*, to distinguish it from a deeper and more powerful muscular fibres which surrounds the last inch or more of the rectum, and is situated next to the mucous membrane.

Cutaneous Vessels and Nerves. The cutaneous vessels and nerves of the perineum come from the internal pudic artery and nerve, and chiefly from that branch of it called the *superficialis perinei*. They may be traced presently.

The *external or inferior hæmorrhoidal arteries* cross transversely through the ischioanal fossa, from the ramus of the ischium towards the anus. They come from the internal pudic (which can be felt on the inner side of the ischium), and, running along the margin of the rectum, divide into numerous branches, which supply the rectum, levator ani, and external sphincter ani. The *nerves* which accompany the arteries come from the pudic nerve, and supply the sphincter ani and the skin of the perineum.

The *fourth sacral nerve* emerges through the coccygeus close to the tip of the coccyx, and, through its *hæmorrhoidal or perineal branch*, supplies the external sphincter and the skin of the perineum between the coccyx and the anus.

At the margin of the anus extending outwards from the margin of the anus is a thin stratum of involuntary fibres, called the *corrugator cutis ani*, which by its action produces the corrugated ridges of skin from the anus.

The *inferior pudendal nerve* comes through the muscular fascia of the thigh a little above the *tuber ischii*, and ascends, dividing into filaments, which supply the front and outer part of the scrotum and perineum. It is a branch of the lesser sciatic nerve, and communicates in front with the posterior branch of the superficial perineal nerve.

Superficial Fascia of the Perineum.

The subcutaneous fascia of the perineum is composed of a *superficial* and a *deep* layer. The *superficial* layer contains more or less fat, and is continuous with that of the scrotum, the thighs, and the posterior part of the perineum. The *deeper* layer is a stratum of considerable strength, and is best demonstrated by blowing air beneath it with a blow-pipe; its connections are as follows: It is attached on each side to the anterior lip of the ramus of the os pubis and ischium superficial to the crus penis; traced forwards, it is directly continuous with the *tunica dartos* of the scrotum; traced backwards, at the base of the urethral triangle, it is reflected beneath the *transversus perinei* muscle, and joins the *deep perineal fascia* or *triangular ligament*. These connections explain why urine effused into the perineum does not make its way into the ischio-rectal fossæ or down the thighs, but passes readily forwards into the connective tissue of the scrotum, penis, and groins.

Dissection.

Remove the fascia to see the muscles which cover the bulb of the urethra and the *crura* of the penis. The bulb of the urethra lies in the middle of the perineum, and is covered by a strong muscle, called *accelerator urinæ*. The *cruræ* penis are attached, one to each side of the pubic arch, and are covered each by a muscle, called *erector penis*. A narrow slip of muscle, called *transversus perinei*, extends on either side from the *tuber ischii* to the *tendinous centre* of the perineum. This point is about one inch and a quarter (3.1 cm.) in front of the anus, and serves for the attachment of muscular fibres from all quarters of the perineum.

Thus the muscles of the perineum describe on each side a triangle, of which the sides are formed by the *accelerator urinæ* and the *crus penis* respectively, and the base by the *transversus perinei*. Across this triangle run, up from base to apex the superficial perineal vessels and nerves. External to the ramus of the ischium is seen the *inferior pudendal nerve*, a branch of the lesser sciatic.

Superficial Perineal Vessels and Nerves.

The *superficial perineal artery* lies beneath the deep layer of the superficial perineal fascia, and comes from the internal pudic as it runs up the inner side of the *tuber ischii*. Though the main trunk cannot be seen, it can be easily felt by pressing the finger against the bone. The artery comes into view a little above the level of the anus, passes up usually in front of the *transversus*

perinei muscle, and gets to the perineal triangle lying to the inner side of the erector penis. It distributes branches to all the muscles, and is finally lost on the scrotum. The only named branch is called *transversalis perinei* (Fig. 173). This is given off near the base of the triangle, and runs transversely inwards with the transversus perinei muscle towards the central tendon of the perineum, where

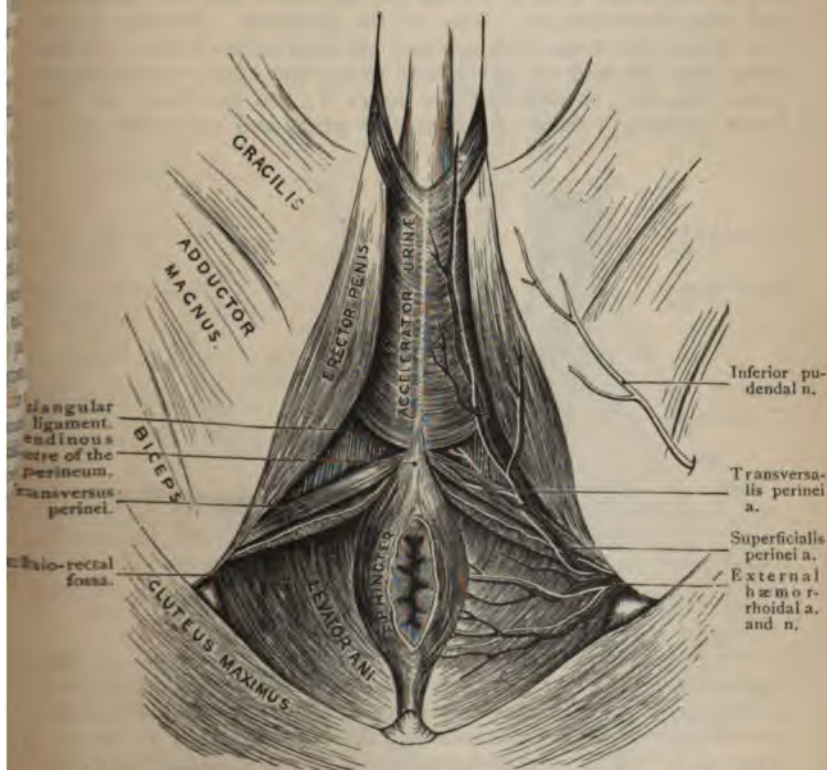


FIG. 173.—MUSCLES, WITH SUPERFICIAL VESSELS AND NERVES, OF THE PERINEUM.

it anastomoses with its fellow. It is necessarily divided in the first incision in lithotomy, and deserves attention, because it is sometimes of considerable size.

The artery is accompanied by two *veins*, which are frequently dilated and tortuous, especially in diseased conditions of the scrotum.

The *nerves*, two in number, are derived from the internal pudic, follow the course of their corresponding arteries, and give off similar branches. They not only supply the skin of the perineum and scrotum, but each of the perineal muscles.

Accelerator Urinæ. This muscle embraces the bulb of the urethra, and is composed of two lateral symmetrical halves. It *arises* from a fibrous median raphé beneath the bulb, and from the tendinous centre of the perineum. Starting from this origin the fibres diverge, and are *inserted* as follows: The *upper* ones proceed on either side round the corpus cavernosum penis, like the branches of the letter V, and are fixed on its dorsal surface, in front of the erector penis, and expanding also

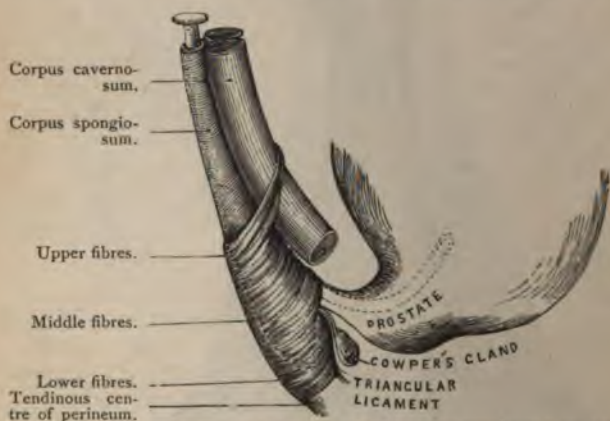


FIG. 174.—DIAGRAM TO SHOW THE ACCELERATOR URINÆ IN PROFILE.

into a broad aponeurosis, which covers the dorsal vessels of the penis; the *middle* completely embraces the bulb and adjacent part of the corpus spongiosum like a ring, and meet in an aponeurosis on the upper surface of the urethra; the *lower* are fixed to the anterior surface of the deep perineal fascia, often called the triangular ligament (Fig. 174).*

Thus, the entire muscle acts as a powerful compressor of the bulb, and expels the last drops of urine from this part of the urethra.† By dividing the muscle along the middle line and turn-

* This muscle is called also the *ejaculator urinæ* or the *bulbo-cavernosus*.

† The middle fibres assist in the erection of the corpus spongiosum, and the upper fibres in that of the penis, the former by compressing the bulb, the latter by compressing the dorsal vein.

ing back each half, its insertion, as above described, can be clearly made out.

Erector Penis. This muscle is moulded upon the crus of the penis. It *arises* by musculo-tendinous fibres from the inner surface of the tuber ischii, from the crus itself, and

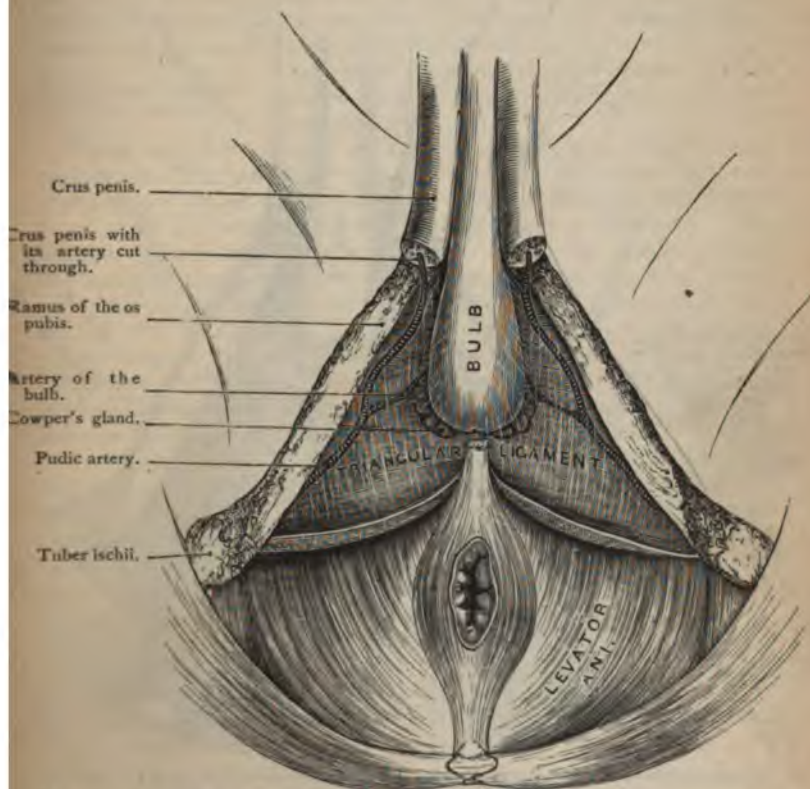


FIG. 175.—DIAGRAM TO SHOW THE TRIANGULAR LIGAMENT OF THE URETHRA OR DEEP PERINEAL FASCIA.

from the ramus of the os pubis; the fibers ascend, completely covering the crus, and terminate on a strong aponeurosis, which is inserted into the external and inferior aspect of the crus penis (Fig. 173). The *action* of this muscle is to compress the root of the

penis, and so, by preventing the return of the venous blood, contributes to the erection of the organ.*

Transversus Perinei. This muscle is of insignificant size, and sometimes absent (Fig. 173). It arises from the inner aspect of the tuber ischii, and proceeds forwards and inwards

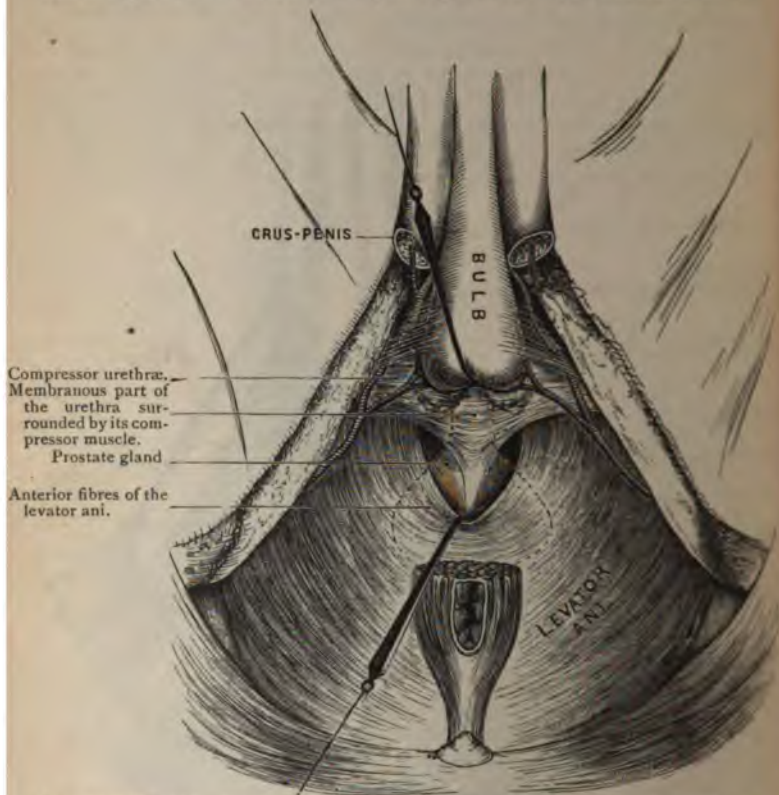


FIG. 176.—DIAGRAM OF THE PARTS BEHIND THE ANTERIOR LAYER OF THE TRIANGULAR LIGAMENT OF THE URETHRA.

(The anterior fibres of the levator ani are hooked down to show part of the prostate; the rest is tracked by a dotted line.)

towards the central point of the perineum, where it is blended with the muscle of the opposite side, with the fibres of the accelerator urinæ in front, and with the external sphincter behind. This muscle with its artery is divided in lithotomy.

* This muscle is sometimes called the *ischio-cavernosus*.

The *deep transversus perinei* is a small muscle occasionally present; it arises more deeply from the pubic arch than the superficial muscle, and passes inwards behind the bulb to the central tendon.

The next stage of the dissection consists in reflecting and removing the accelerator urinæ from the bulb of the urethra, the erectors penis with the crura penis from the rami of the os pubis and ischium, and the transversi perinei muscles. This done, the *triangular ligament* or *deep perineal fascia* is fairly exposed.

Triangular Ligament of the Urethra.

Understand that the triangular ligament of the urethra and the deep perineal fascia are synonymous terms.

The *triangular ligament*, shown in Fig. 176, is a strong fibrous membrane stretched across the pubic arch. It is about an inch and a half (3.8 cm.) in depth, with the base directed backwards. It consists of two layers—an anterior and a posterior. The *anterior layer* is firmly attached on each side to the *posterior* lip of the rami of the os pubis and ischium, beneath the crus penis; superiorly—*i. e.*, towards the symphysis of the os pubis—it is connected with the subpubic ligament; inferiorly, it does not present a free border, but is connected to the tendinous centre of the perineum, and is continuous with the deep layer of the superficial perineal fascia which curves backwards under the transversus perinei muscle, and with the ischio-rectal or anal fascia (p. 470).

The anterior layer of the triangular ligament is perforated about one inch (2.5 cm.) below the symphysis pubis for the membranous part of the urethra. The aperture through which the urethra passes does not present a distinct edge, because the ligament is prolonged forwards over the bulb, and serves to keep it in position. It also presents apertures for the transmission of the dorsal vein, and outside this for the pudic arteries and nerves.

The *posterior layer* cannot at present be seen. It belongs, strictly speaking, to the obturator prolongation of the pelvic fascia, and slopes somewhat backwards from the anterior layer so as to leave an interval between them, in which are found structures which will be presently described.

Points of Surgical Interest.

The triangular ligament is very important surgically for these reasons:—

1. Here we meet with difficulty in introducing a catheter, unless we can hit off the right track through the ligament. The soft and spongy tissue of the bulbous part of the urethra in front of the ligament readily gives way if force be used, and a false passage results.

2. By elongating the penis, we are much more likely to hit off the proper opening through the ligament.

3. When, in retention of urine, the urethra gives way *anterior* to this ligament, it is this which prevents the urine from travelling into the pelvis. Its connection

with the superficial perineal fascia prevents the urine from getting into the ischio-rectal fossæ: nor can the urine make its way into the thighs. The only outlet for it is into the connective tissue of the scrotum and penis.

4. When suppuration or extravasation of urine takes place *behind* the ligament, the pus is pent up and should be speedily let out; if not, it may find its way into the connective tissue of the pelvis, and may burst into the urethra or the rectum.

5. The ligament is partially cut through in lithotomy.

Parts divided in

Lateral Lithotomy.

The parts divided in the lateral operation of lithotomy are: the skin, the superficial fascia, the transverse perineal muscle, vessels and nerve, the inferior hæmorrhoidal vessels and nerves, the inferior fibres of the accelerator urinæ, the anterior fibres of the levator ani, the triangular ligament (anterior layer), the compressor urethræ, the membranous and prostatic parts of the urethra, and a small portion of the prostate.

Parts to be avoided.

The incision in lateral lithotomy should not be made too far forwards, for fear of wounding the artery of the bulb; nor too far inwards, for fear of injuring the rectum; nor too far outwards, for fear of cutting the pudic artery.

Structures between the Layers of the Triangular Ligament.

The anterior layer of the triangular ligament must now be cut away to see what lies between its two layers. These parts are shown in Fig. 176, namely: 1, the membranous part of the urethra, surrounded by, 2, the compressor urethræ muscle; 3, Cowper's glands and their ducts; 4, the pudic artery and its branch, the artery of the bulb; the artery of the crus and the dorsal artery of the penis being given off in front of the anterior layer; 5, the pudic nerve and its branches; 6, the dorsal vein of the penis; 7, the subpubic ligament.

Dissection.

To obtain the best perineal view of the compressor urethræ muscle, cut through the spongy part of the urethra about three inches (7.5 cm.) above the end of the bulb, and dissect it from the corpus cavernosum. Thus, the upper fibres of the constrictor will be exposed; to see the lower, it is only necessary to raise the bulb. The most perfect view, however, of the muscle is obtained by making a transverse section through the rami of the ossa pubis, so as to get at the muscle from above, as shown in Fig. 177.

Compressor or Constrictor Urethræ.

This muscle consists of transverse fibres which surround and support the whole length of the membranous portion of the urethra in its passage between the two layers of the triangular ligament. It arises from the ramus of the os pubis on either side for about half an inch (13 mm.); from thence its fibres pass, some above, some below the urethra, along the whole length of its membranous part. It forms a complete muscular covering for the urethra between the prostate and the bulb. It is chiefly through its agency that we retain the urine. This muscle is the chief cause of spasmodic

picture of the urethra. Besides this muscle, the membranous portion of the urethra is surrounded by involuntary circular muscular fibres, placed beneath the compressor urethrae, and continuous with the muscular fibres of the bladder.

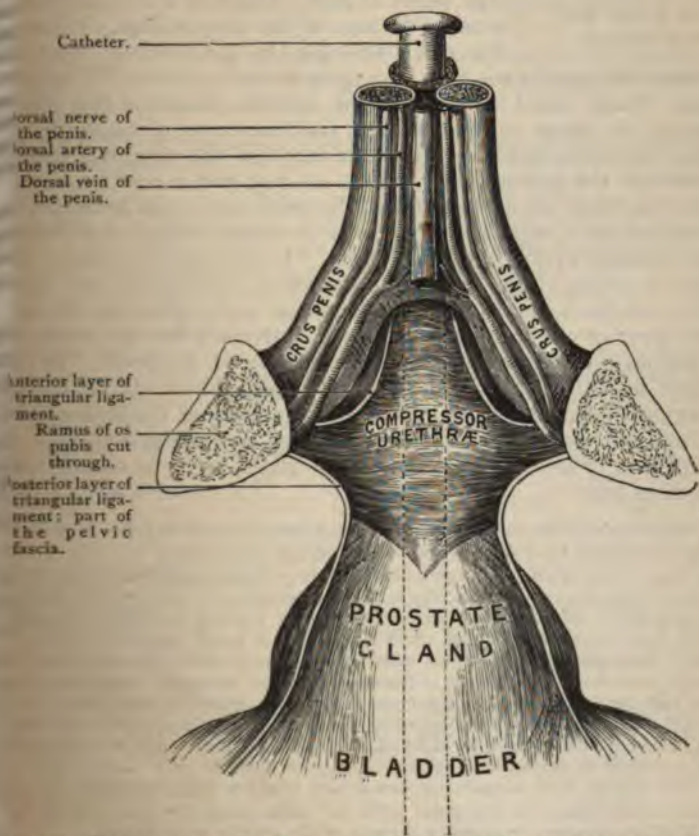


FIG. 177.—DIAGRAM OF THE RELATIONS OF THE COMPRESSOR URETHRAE SEEN FROM ABOVE.

Cowper's Glands. These small glands are situated, one on either side, immediately behind the bulb between the two layers of the triangular ligament, in the substance of the compressor urethrae. Their size is about that of a pea, but it varies in different individuals. They are compound racemose glands, consisting of several lobules firmly connected together by cellular and

some muscular tissue. From each a slender duct runs forwards, and, after a course of about one inch, opens obliquely into the floor of the bulbous part of the urethra (Fig. 174). They furnish a secretion accessory to generation.

Pudic Artery and its Branches.

The *internal pudic artery* is a branch of the anterior division of the internal iliac. It leaves the pelvis through the great sciatic foramen between the pyriformis and coccygeus muscles, above the sciatic artery, winds round the spine of the ischium, re-enters the pelvis through the lesser sciatic foramen, and then runs along the inner side of the tuber ischii, between the layers of the obturator fascia, up towards the pubic arch. About an inch and a half (3.8 cm.) above the tuber ischii, the trunk of the pudic artery can be felt; but we cannot see it, nor draw it out, for it is securely lodged in a fibrous canal formed by the obturator fascia. It subsequently pierces the posterior layer of the triangular ligament, runs along the inner margin of the ramus of the os pubis, and lastly, piercing the anterior layer of the triangular ligament, it divides into the artery of the corpus cavernosum and the dorsal artery of the penis. In the present dissection we find the artery between the two layers of the triangular ligament, where it gives off the artery of the bulb of the urethra, and then pierces the triangular ligament (Fig. 175).

Taken in order, the branches of the pudic artery as seen in this dissection are:—

a. The *external hæmorrhoidal*, the *superficial perineal*, and the *transverse perineal* branches have already been described (pp. 470, 471).

b. The *artery of the bulb* is of considerable size, and passes transversely inwards between the two layers of the triangular ligament; it runs inwards through the substance of the compressor urethræ, and before it enters the bulb divides into two or three branches. It also sends downwards a small branch to Cowper's gland. From the direction of this artery it will at once strike the attention that there is great risk of dividing it in lithotomy. If the artery run along its usual level, and the incision be not made too high in the perineum, then indeed it is out of the way of harm. But, supposing the reverse, the vessel must be divided. This deviation from the normal distribution is met with about once in twenty subjects, and there is no possibility of ascertaining this anomaly beforehand.

c. The *artery of the corpus cavernosum*, one of the terminal branches, ascends for a short distance near the pubic arch, and soon enters the crus, running forwards in its cavernous structure by the side of the septum pectiniforme.

d. To see the *dorsal artery of the penis*, the crus should be dissected from its attachment to the symphysis pubis. The artery pierces the suspensory ligament, and can be traced upon the dorsum of the penis down to the glans. It forms a complete arterial circle with its fellow round the corona glandis, and gives numerous ramifications to the papillæ on the surface.

The *veins* corresponding with the branches of the pudic artery terminate in the pudic vein, with the exception of the *dorsal vein of the penis*. This vein is of large size and results from the union

of two small veins in front of the dorsum of the penis which receive the blood from the glans, the corpus spongiosum, and the prepuce. The vein runs along the middle of the dorsum, pierces, first, the suspensory ligament, and then the triangular ligament under the symphysis, and divides into two branches which open into the prostatic plexus.

Pudic Nerve.

The *pudic nerve* comes from the lower part of the sacral plexus, and corresponds, both in its course and branches, with the artery.

It gives off, close to its origin, (a) the *external or inferior hæmorrhoidal*, which communicate in front with the superficial perineal and inferior pudendal nerves; (b) the *perineal*, which accompanies the superficial perineal artery, and divides into a posterior and an anterior branch; the former runs to the front of the ischio-rectal fossa, distributing branches to the sphincter and the skin in front of the anus; the latter lies in front of the preceding, and supplies the scrotum and under aspect of the penis; both communicate with each other and with the inferior pudendal nerve; (c) *muscular branches* to the transversus perinei, the accelerator urinæ, the erector penis, and the compressor urethræ; (d) the *dorsal nerve*, which is the main trunk of the nerve, runs with the pudic artery, and with it pierces the posterior, and then the anterior layer of the triangular ligament; then perforating the suspensory ligament of the penis, it accompanies the dorsal artery on its outer side, along the dorsum of the penis to the glans. In its passage it supplies the integuments of the penis, and sends off one or two branches into the corpus cavernosum. This part of the penis also receives filaments from the sympathetic system.

Ischio-rectal Fossa. This is the deep hollow, on each side, between the anus and the tuber ischii. When all the fat is removed from it, observe that it is lined on all sides by fascia. Introduce the finger into it to form a correct idea of its extent and boundaries. *Externally*, it is bounded by the tuber ischii and the fascia covering the obturator internus muscle; *internally*, by the rectum, levator ani, and coccygeus; *posteriorly*, by the gluteus maximus; *anteriorly*, by the transversus perinei. The fossa is crossed by the external hæmorrhoidal vessels and nerves.

These deep spaces on each side of the rectum explain the great size which abscesses in this situation may attain. The pus can be felt only through the rectum. Nothing can be seen outside. Perhaps nothing more than a little hardness can be felt by the side of the anus. These abscesses should be opened early, else they form a large cavity, and may burst into the rectum, and result in a fistula.

DISSECTION OF THE FEMALE PERINEUM.

The *pu'denda* in the female consist of folds of the integument, called the labia. Between these is a longitudinal fissure which leads to the orifices of the urinary and genital canals.

Labia Majora.

The pubic region is generally surmounted by an accumulation of fat, called *mons Veneris*, which is covered with hair. From this, two thick folds of skin

descend, one on either side, constituting the *labia majora*, and gradually diminish in thickness towards the perineum. Their junction, about an inch (2.5 cm.) above the anus, is called the *posterior commissure*, or *frænulum labiorum*, within which is a transverse crescentic fold, the *fourchette*: it is generally torn in the first labor. Between the fourchette and the posterior commissure is an oval depression, called the *fossa navicularis*. The inner layer of the skin of the labium is thinner, softer, and more like mucous membrane than the outer; for this reason, whenever pus forms in the labium, the abscess bursts on the inner side. Where the labia are in contact, they are provided with small sebaceous glands, of which the minute ducts are observable on the surface. They are the analogues of the scrotum in the male, and occasionally contain extruded ovaries, forming a hernia of the ovary.

Clitoris.

In form and structure the clitoris resembles the penis on a diminutive scale, being about an inch and a half (3.8 cm.) long. It has, however, no corpus spongiosum or urethra. Like the penis, it is attached to the sides of the pubic arch by two crura (Fig. 178, p. 482), each of which is grasped by its special *erector clitoridis*. The crura are continued forward like the corpora cavernosa of the male, and unite to form the body of the organ, which is surmounted by a small *glans*. It has also, like the penis, a suspensory ligament. The glans is provided with extremely sensitive papillæ, and covered by a little prepuce. Its dorsal arteries and nerves are large in proportion to its size, and have precisely the same course and distribution as in the penis. Its internal structure consists of a plexus of blood-vessels, which freely communicate with those of the labia minora; for one cannot be injected without the other.

Labia Minora or Nymphæ.

By separating the external labia, two small and thin folds of mucous membrane about an inch and a half (3.8 cm.) in length, are exposed, one on either side, termed *labia minora*. These folds converge anteriorly, and form a covering for the clitoris, called *preputium clitoridis*; posteriorly, they are gradually lost on the inside of the labia majora. They, unlike the labia majora, do not contain fat, but are composed of minute veins. Between the nymphæ and about the clitoris are a number of sebaceous glands.

Between the labia minora, and below the clitoris, is an angular depression called the *vestibule*, at the back of which is the *meatus urinarius*. Immediately below this is the vagina, of which the orifice is partially closed in the virgin by a thin fold of mucous membrane called the *hymen*.

Hymen.

The *hymen* is a thin fold of mucous membrane which, in the virgin, extends across the lower part of the entrance of the vagina, about half an inch (13 mm.)

behind the fourchette. In most instances its form is crescent-shaped, with the concavity upwards. There are several varieties of hymen: sometimes there are two folds, one on either side, so as to make the entrance of the vagina a mere vertical fissure: or there may be a septum perforated by several openings, *hymen cribriformis*, or by one only, *hymen circularis*. Again, there may be no opening at all in it, and then it is called *hymen imperforatus*. Under this last condition no inconvenience arises until puberty. The menstrual discharge must then necessarily accumulate in the vagina: indeed, the uterus itself may become distended by it to such an extent as even to simulate pregnancy.

When the hymen is ruptured, it shrivels into a few irregular eminences, called *carunculæ myrtiformes*.

The presence of the hymen is not necessarily a proof of virginity, nor does its absence imply the loss of it. Cases are related by writers on midwifery in which a division of the hymen was requisite to facilitate parturition. In Meckel's Museum, at Halle, are preserved the external organs of a female in whom the hymen is perfect even after the birth of a seven-months' child.

Between the orifice of the vagina and the erector clitoridis is imbedded in the loose tissue on either side a small gland, which corresponds to Cowper's gland in the male. Each is about half an inch (*13 mm.*) in length. Its long, slender duct runs forwards and opens on the inner side of the nymphæ external to the hymen. In cases of virulent gonorrhœa these glands are apt to become diseased, and give rise to the formation of an abscess in the labium very difficult to heal.

**Bartholin's or
Duverney's Glands.**

Urethra.

A smooth channel, called the *vestibule*, three-quarters of an inch (*18 mm.*) in length, leads from the clitoris down to the orifice of the urethra. This orifice, *meatus urinarius*, is not a perpendicular fissure like that of the penis, but rounded and puckered, and during life has a peculiar dimple-like feel, which assists us in finding it when we pass a catheter. You should practise the introduction of the catheter in the dead subject, for the operation is not so easy as might at first be imagined, provided the parts are not exposed. The point of the forefinger of the left hand should be placed at the entrance of the vagina, and the meatus felt for; when the catheter, guided by the finger, slips, after a little manœuvring, into the urethra.* The canal is about one inch and a half (*3.8 cm.*) in length, and runs

* In every case, and especially when any vaginal discharge exists, the parts should be exposed and cleansed in order to avoid septic infection of the bladder and kidney. The catheter must, of course, be made absolutely clean. (A. H.)

along the upper wall of the vagina. The two canals are in such close apposition that you can feel the urethra imbedded in the vagina like a thick cord. The urethra is slightly curved with the concavity upwards; but for all practical purposes it may be considered straight. Its direction, however, is not horizontal. In the unimpregnated state it runs nearly in the direction of the axis of the outlet of the pelvis; so that a probe pushed on in the course of the urethra would strike against the promontory of the sacrum. But, after impregnation, when the uterus begins to rise out of the pelvis, the bladder is more or less raised also in consequence of their mutual connection; therefore the urethra, in the latter months of utero-gestation, acquires a much more perpendicular course.

The female urethra is provided with a *compressor* muscle, similar in origin and arrangement, to that which surrounds the membranous part of the urethra in the male. It also passes through the triangular ligament. The prostate gland is wanting, but there are minute glands scattered around the neck of the bladder. In consequence of the wider span of the pubic arch, and the more yielding nature of the surrounding structures, the female urethra is much more dilatable than the male. By means of a sponge-test, it may be safely dilated to admit the easy passage of the fore-finger into the bladder. Advantage is taken of this great dilatability in the extraction of calculi from the bladder.

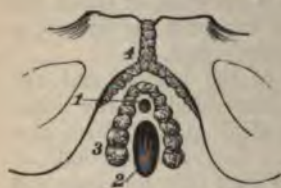

FIG. 178.—BULB OF THE VAGINA.*
1. Meatus urinarius. 2. Vagina.
3. Bulb of vagina. 4. Clitoris with its two clura.

The mucous coat of the urethra is pale and arranged in longitudinal folds, and is lined by squamous epithelium, which changes to the spheroidal variety near the bladder. Next to the mucous coat is a layer of elastic and non-striped muscular fibres intermixed. The muscular tissue is arranged in two layers—an outer, consisting of circular fibres, and an inner of longitudinal fibres. Externally there is a plexus of veins bearing a strong resemblance to erectile tissue.

Vagina.

The vagina is the canal which leads to the uterus; at present, only the orifice of it can be seen. It is surrounded by a sphincter muscle, easily displayed by removing the integument. The muscle is about three-fourths of an inch (*18 mm.*) broad, and connected with the cutaneous sphincter of the anus in such a manner that they together form something like the figure 8.

* Taken from an injected preparation in the Musée Orfila, at Paris.

On each side of the orifice of the vagina, between the mucous membrane and the sphincter, is a plexus of tortuous veins, termed the *bulb of the vagina*, from its analogy to the bulb of the urethra in the male. This vaginal bulb is about an inch (2.5 cm.) long, and extends across the middle line between the meatus urinarius and the clitoris, as shown in Fig. 178.

The description of the perineal branches of the pudic vessels and nerves, given in the dissection of the male perineum, applies, *mutatis mutandis*, to the female, excepting that they are proportionably small, and that the artery which supplies the bulb of the urethra in the male is distributed to the bulb of the vagina in the female.

ANATOMY OF THE SIDE VIEW OF THE PELVIC VISCERA.

To obtain a side view of the pelvic viscera, the left innominate bone should be removed thus: Detach the peritoneum and the levator ani from the left side of the pelvis, cut through the external iliac vessels, the obturator vessels and nerve, and the nerves of the lumbar plexus; then saw through the os pubis about two inches (5 cm.) external to the symphysis, and cut through the sacro-iliac symphysis; now draw the legs apart, and saw through the base of the spine of the ischium; after cutting through the pyriformis, the great sacro-sciatic ligament, the great and small sciatic nerves, and the gluteus maximus muscle, the innominate bone can be easily detached. This done, the rectum should be distended with tow, and the bladder blown up through the ureter. A staff should be passed through the urethra into the bladder, and a block placed under the sacrum.

The reflection of the peritoneum as it passes from the front of the rectum to the lower part of the bladder (forming the recto-vesical pouch), and thence over the back of the bladder to the wall of the abdomen, has been already described. You see where the distended bladder is bare of peritoneum, and that it can be tapped either through the rectum or above the pubes without injury to the serous membrane, as shown by the arrows in Fig. 179.

The peritoneal connections of the bladder are called its false ligaments; *false* in contradistinction to the *true*, which are formed by the fascia of the pelvis, and really *do* sustain the neck of the bladder in its proper position. The *false ligaments* are five in number, two posterior, two lateral, and one superior. The *posterior* are produced by two peritoneal folds, one on either side the recto-vesical pouch; the *two lateral*, by reflections of the peritoneum from the sides of the pelvis to the sides of the bladder; the *superior* is produced by

False Ligaments of the Bladder.

the passage of the peritoneum from the front of the bladder to the abdominal wall. These have been already described (p. 465).

Pelvic Fascia.

To expose the *pelvic fascia*, the peritoneum must be removed from that side of the pelvis which has not been disturbed: in doing so notice the abundance of loose connective tissue interposed between the peritoneum and the fascia to allow the bladder to distend with facility. Whenever urine is extravasated into this loose tissue, it is sure to produce the most serious consequences; therefore in all operations on the perineum it is of the utmost importance not to injure this fascia.

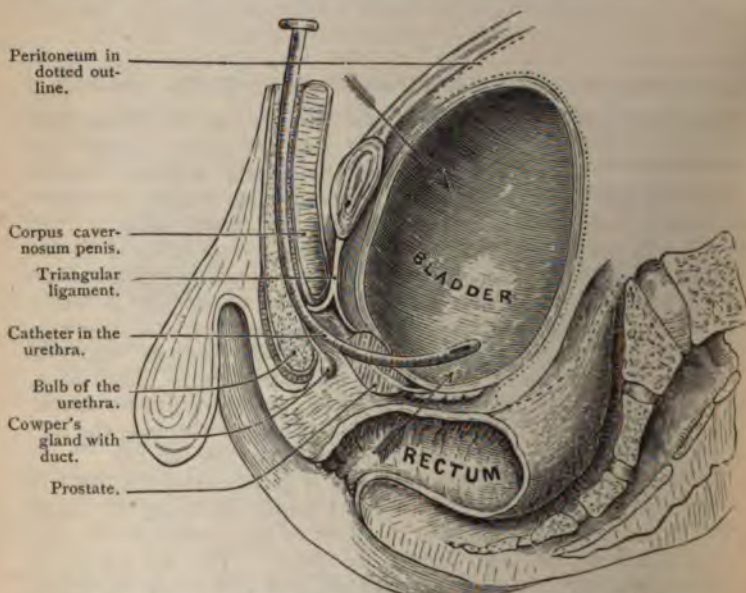


FIG. 179.—VERTICAL SECTION THROUGH THE PERINEUM AND PELVIC VISCERA.
(The arrows point out where the bladder can be tapped.)

The pelvic fascia is a thin but strong membrane, and constitutes the true ligaments of the bladder and the other pelvic viscera, supporting and maintaining them in their proper position.

Examine, first, to what parts of the pelvis the fascia is attached; secondly, the manner in which it is reflected on the viscera.

Beginning, then (Fig. 180), we see that, in front, the fascia is continuous with the transversalis fascia, and laterally with the iliac fascia, and that superiorly it is attached to the body of the os pubis,

to the brim of the pelvis, and to the side of the bone just above the attachment of the obturator internus, close to the obturator foramen and the great sciatic notch. Here it becomes gradually thinner, covers the pyriformis and the sacral plexus, and is gradually lost on the front of the sacrum.

Traced forwards, we find that it is attached to the bone along the upper border of the obturator internus, and, as it passes forwards over the obturator foramen, completes the canal through

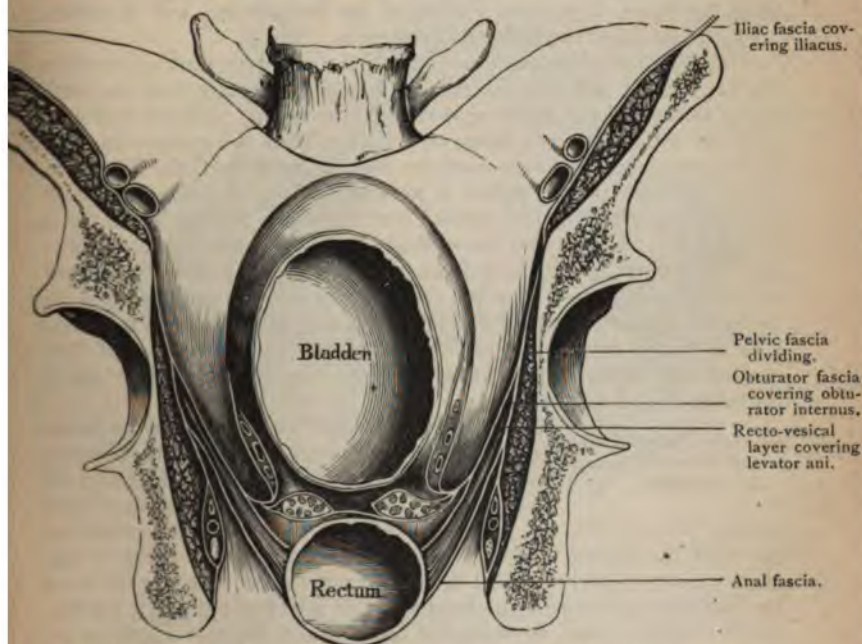


FIG. 150.—TRANSVERSE SECTION OF THE PELVIS, TO SHOW THE REFLECTIONS OF THE PELVIC FASCIA. (After Gray.)

which the obturator vessels pass to the foramen; anteriorly, it is attached to the posterior surface of the lower part of the symphysis pubis. From this attachment the fascia descends as far as a line drawn from the spine of the ischium to the pubic symphysis, where it forms a dense white line which marks the division of the fascia into two layers, an outer, the obturator, and an inner, the recto-vesical fascia. It also serves for the attachment of a considerable part of the middle portion of the levator ani.

The *obturator fascia*, the outer layer, is the continuation of the pelvic fascia, and descends on the inner surface of the obturator internus, forming at the same time a sheath for the pudic vessels and nerve, the nerve being the lowest. It is attached to the pubic arch, to the tuberosity of the ischium, and to the margin of the great sacro-sciatic ligament. It is continuous in front, below the symphysis pubis, with the corresponding layer of the opposite side, and here forms the posterior layer of the triangular ligament. From this fascia is derived the *ischio-rectal* or *anal fascia*, which lines the under or perineal surface of the levator ani, and is subsequently lost upon the side of the rectum.

The *recto-vesical fascia* descends on the upper or internal surface of the levator ani, and invests the bladder, prostate, and rectum. From the symphysis pubis it is reflected over the prostate and the neck of the bladder to form, on either side of the symphysis, two well-marked bands—the *anterior true ligaments* of the bladder. From the side of the pelvis it is reflected on to the side of the bladder, constituting the *lateral true ligaments* of that viscus, and encloses the prostate and the vesical plexus of veins. A prolongation from this ligament encloses the vesicula seminalis, the lower layer of which passes between the bladder and the rectum, to join its fellow from the opposite side. The continuation of the recto-vesical fascia covers the remainder of the upper surface of the levator ani as far as its attachment to the rectum, where it is reflected round this tube.

**General Position of
the Pelvic Viscera
in the Male.**

The pelvic viscera are so surrounded by veins and loose areolar tissue that he who dissects them for the first time will find a difficulty in discovering their definite boundaries. The rectum runs at the back of the pelvis, and follows the anterior curve of the sacrum and coccyx. The bladder lies in front of the rectum, immediately behind the symphysis pubis. At the neck of the bladder is the prostate gland through which the urethra passes. In the cellular tissue, between the bladder and the rectum, there is, on each side, a convoluted tube, called the vesicula seminalis, and on the inner side of each vesicula is the seminal duct or vas deferens. Before describing these parts in detail, it is necessary to say a few words about the large tortuous veins which surround them.

**Vesico-prostatic
Plexus of Veins.**

Beneath the pelvic fascia surrounding the prostate and the neck of the bladder are large and tortuous veins, which form the prostatic and the vesical plexuses. They empty themselves into the internal iliac. In early life they are not much developed, but as puberty approaches they gradually increase in size, and one not familiar with the anatomy of these parts would hardly credit the size which they sometimes attain in old persons. They communicate freely behind with the

inferior hæmorrhoidal plexus, or veins about the anus, and they receive the blood returning from the penis through the large veins which pass under the pubic arch.

If, in lithotomy, the incision be carried beyond the limits of the prostate, the great veins around it must necessarily be divided; these, independently of any artery, are quite sufficient to occasion serious hæmorrhage.

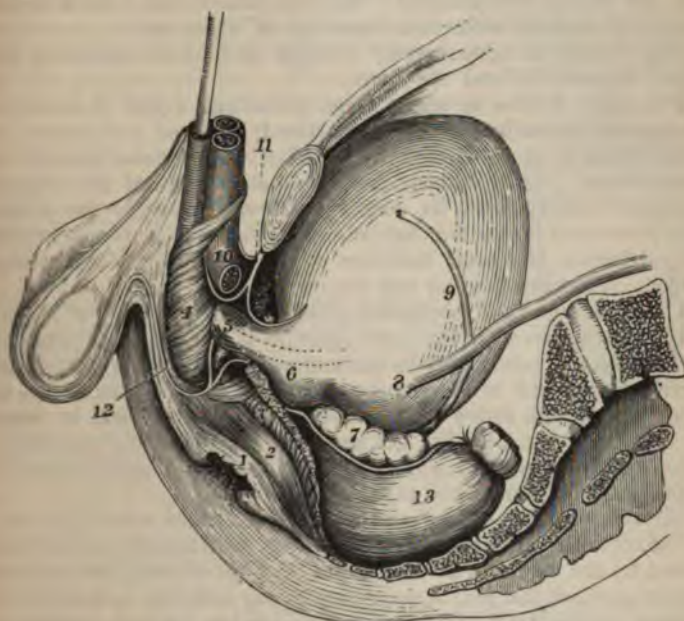


FIG. 181.—SIDE VIEW OF THE PELVIC VISCERA.

(Taken from a Photograph.)

1. External sphincter. 2. Internal sphincter. 3. Levator ani cut through. 4. Accelerator urine.
5. Membranous part of the urethra, surrounded by compressor muscle. 6. Prostate gland.
7. Vesicula seminalis. 8. Ureter. 9. Vas deferens. 10. Crus penis divided. 11. Triangular ligament. 12. Superficial perineal fascia. 13. Rectum.

Rectum and its Relations.

The rectum is about eight inches (20 cm.) long. It is a continuation of the sigmoid flexure of the colon, enters the pelvis at the left sacro-iliac articulation, describes a curve corresponding to the sacrum and coccyx, and terminates at the anus. The rectum also inclines from the left side to the middle line, and before its termination the bowel turns downwards, so that the anal aperture is dependent. Although it loses the sacculated appearance, it is not throughout of equal calibre and its capacity becomes greater as it

descends into the pelvis; immediately above the sphincter, it presents a considerable dilatation, the *ampulla* (Fig. 179). This dilatation is not material in early life, but it increases as age advances. Under such circumstances the rectum loses altogether its cylindrical form, and bulges up on either side of the prostate and the base of the bladder. For this reason the rectum should always be emptied before the operation of lithotomy.

The rectum is conveniently divided into three portions, the upper, the middle, and the lower.

The *upper portion* is about three inches and a half (8.8 cm.) in length, and extends as low as the third bone of the sacrum, to which bone it is connected by a fold of peritoneum, termed the *meso-rectum*. In this fold, the terminal branch of the inferior mesenteric artery with its vein runs down to supply the bowel. This portion of the rectum has behind it, the sacral plexus of nerves, the pyriformis, and some branches of the left internal iliac artery; in front, it has the bladder and the recto-vesical pouch.

The *middle portion* comprises three inches (7.5 cm.) in length, and is continuous with the lower portion at the tip of the coccyx. It is connected posteriorly to the sacrum and coccyx by loose connective tissue, and is covered by peritoneum only in front in the upper part, which forms the recto-vesical pouch. It has in front, the fundus of the bladder, the vesiculæ seminales, the vasa deferentia, and the prostate; while in the female it is closely connected to the posterior wall of the vagina.

The *lower portion* comprises the lowest inch and a half (3.8 cm.) of the rectum. It is entirely destitute of peritoneum, and is supported by the levatores ani, the larger portions of which are inserted into its side; it has also surrounding it, the internal, and lastly the external sphincters.* There is a considerable interval between it and the membranous portion of the urethra in the male, and the vagina in the female.

Digital Examination of the Rectum. The relations of the front part of the rectum—that, namely, included between the recto-vesical pouch and the anus—are most important.

If the forefinger be introduced into the anus, and a catheter into the urethra, the first thing felt through the front wall of the bowel is the membranous part of the urethra (Fig. 181). It lies just within the sphincter, and is about $\frac{1}{2}$ of an inch (20 mm.) in front of the gut. About one and a half or two inches (3.8 to 5 cm.) from

* Some authors maintain that the rectum proper begins at the second portion above noted; but if the appearance of the muscular coat is to be taken, this description is the better of the two. The muscular coat is in two complete layers longitudinal on the outside, and circular on the inside, starting at the left sacro-iliac joint. (A. H.)

the anus the finger comes upon the prostate gland; this is in close contact with the gut, and is readily felt on account of its hardness; by moving the finger from side to side we recognize its lateral lobes. Still higher up, the finger goes beyond the prostate, and reaches the trigone of the bladder: the facility with which this can be examined depends, not only upon the length of the finger and the amount of fat in the perineum, but upon the degree of distension of the bladder; the more distended the bladder, the better can the prostate be felt. These several relations are practically important. They explain why, with the finger in the rectum, we can ascertain whether the catheter is taking the right direction—whether the prostate be enlarged or not. We might even raise a stone from the bottom of the bladder so as to bring it in contact with the forceps.

The rectum is supplied with blood by the superior, middle, and inferior hæmorrhoidal arteries. The superior comes from the inferior mesenteric (p. 442); the middle from the anterior division of the internal iliac artery, and the inferior from the pudic artery. The superior hæmorrhoidal veins join the inferior mesenteric, and consequently the portal system; the middle and the inferior hæmorrhoidal veins join the internal pudic, and thence the internal iliac vein. They are very large and form loop-like plexuses about the lower part of the rectum. Having no valves, they are liable to become dilated and congested from various internal causes; hence the frequency of hæmorrhoidal affections.

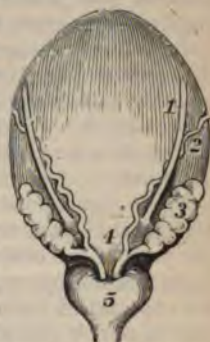

FIG. 182.—POSTERIOR VIEW OF THE BLADDER.
1. Ureter. 2. Vas deferens. 3. Vesicula seminalis. 4. Trigone. 5. Prostate.

Bladder.

This viscus, being a receptacle for the urine, must necessarily vary in size, and accordingly the nature of its connections and coats is such as to permit this variation. When contracted, the bladder sinks into the pelvis behind the pubic arch, and is completely protected from injury. But, as it gradually distends, it rises out of the pelvis into the abdomen, and, in cases of extreme distension, may reach up to the umbilicus.* Its outline can then be easily felt through the walls of the abdomen.

* When the bladder is completely paralysed it becomes like an inorganic sac, and there seems to be no limit to its distension. Hall found, in a drunkard, the bladder so dilated that it would hold twenty pints of water. (*Elem. Phys. art. Vesica.*) Frank saw a bladder so distended as to resemble ascites, and evacuated from it twelve pounds of urine. (*Oratio de Signis Morborum, &c. &c.* Ticini, 1788.)

W. Hunter, in his *Anatomy of the Gravid Uterus*, has given the representation of a bladder distended nearly as high as the ensiform cartilage.

The form* of the distended bladder is oval, and its long axis, if prolonged, would pass superiorly through the umbilicus, and inferiorly through the end of the coccyx. The axis of a child's bladder is more vertical than that of the adult; for in children the bladder is not a pelvic viscus. This makes lithotomy in them so much more difficult.

The quantity of urine which the bladder will hold without much inconvenience varies. As a general rule, it may be stated at about a pint. Much depends upon the habits of the individual; but some persons have, naturally, a very small bladder, and are obliged to empty it more frequently.

In young persons the lowest part of the bladder is the neck, or that part which joins the prostate. But as age advances, the bottom of the bladder gradually deepens so as to form a pouch behind the prostate. In old subjects, particularly if the prostate be enlarged, this pouch becomes deep, micturition becomes tedious, and the bladder cannot completely empty its contents. It sometimes happens that a stone in the bladder is not felt; the reason of which may be that the stone, lodged in such a pouch below the level of the neck of the bladder, escapes the detection of the sound. Under these circumstances, if the patient be placed on an inclined plane with the pelvis higher than the shoulders, the stone falls out of the pouch, and is easily struck.

The bladder is divided into a summit, a body, a base, and a neck.

The *summit* is its highest part, and to it is attached a thin fibrous cord, the urachus, which passes up to the umbilicus, and is the obliterated remains of a canal connecting the foetal bladder with a sac external to the foetus, called the allantois.

The *body* on its anterior aspect is not covered with peritoneum, and is in relation with the symphysis pubis, the triangular ligament, and the obturator internus; posteriorly, it is covered with peritoneum, and is in relation in the male with the rectum, and in the female with the uterus; laterally, it is only covered with peritoneum behind, and is in relation with the obliterated hypogastric arteries, the vasa deferentia, and ureters.

The *base* is the lowest part of the bladder resting upon the middle portion of the rectum, and is only slightly covered behind with peritoneum; below, it is in contact with the vesiculæ seminales and vasa deferentia, which latter pass forward as far as the prostate; the reflection of the peritoneum posteriorly with the vasa deferentia

* In all animals with a bladder, the younger the animal the more elongated is the bladder. This is indicative of its original derivation from a tube, i. e., the *urachus*. In the infant, the bladder is of a pyriform shape, as it is, permanently, in the quadruped; but as we assume more and more the perpendicular attitude, the weight of the urine gradually makes the lower part more capacious.

converging towards the front, forms a triangular space through which the bladder is tapped in cases of retention of urine.

The *neck* is the narrow portion where the urethra begins, and its direction is downwards and forwards. It is embraced by the prostate gland.

Ureter.

The *ureter** is about twelve inches (30 cm.) long, and conveys the urine from the kidney to the bladder. In the dissection of the abdomen (p. 444), it was seen descending along the psoas muscle, behind the spermatic vessels, and crossing the common iliac artery into the pelvis. Tracing it downwards, in the posterior false ligament of the bladder, below the obliterated hypogastric artery, we find that it runs along the side of the bladder, external to the vas deferens, and enters it about an inch and a half (3.8 cm.) behind the prostate, and about two inches (5 cm.) from its fellow of the opposite side (Fig. 180). It perforates the bladder very obliquely, so that the aperture, being valvular, allows the urine to flow into, but not out of it. The narrowest part of the ureter is at the vesical orifice; here, therefore, a calculus is more likely to be arrested in its progress than at any other part of the canal.

Vas Deferens.

This tube, about twenty-four inches (60 cm.) in length, conveys the seminal fluid from the testicle into the prostatic part of the urethra. Taking its origin at the lower part of the globus minor behind the testis, it ascends at the back part of the testis and epididymis, along the back of the spermatic cord through the inguinal canal into the abdomen; then, leaving the cord at the inner ring, it curves round the deep epigastric artery, then crosses over the external iliac vessels, and descends into the pelvis on the side of the bladder, gradually approaching nearer the middle line. Before it reaches the prostate, it passes between the bladder and the ureter; then becoming very sacculated, it runs forwards internal to the vesicula seminalis, and is joined by the duct of this vesicle. The common duct thus formed, *ductus communis ejaculatorius*, terminates in the lower part of the prostatic portion of the urethra (Fig. 182, p. 485). In point of size and hardness, the vas deferens has very much the feel of whipcord; †

* The length of the ureter is variously stated up to eighteen inches (4.5 cm.), but the length given above is the average. It is about $\frac{1}{6}$ of an inch (4 mm.) in diameter when distended, except about two inches (5 cm.) below the kidney, where it is slightly contracted. (A. H.)

† The description in the text assumes the bladder to be distended. But when the bladder is empty, the vas deferens runs down upon the side of the pelvis. In this course it may be seen, through the peritoneum, crossing—1, the external iliac vessels; 2, the remains of the umbilical artery; 3, the obturator artery and nerve; 4, the ureter.

its diameter in the funicular, inguinal, and pelvic portions as far as the post vesicular position is $\frac{1}{10}$ of an inch (2.5 mm.), the walls being very thick and calibre very small, about $\frac{1}{25}$ of an inch (1 mm.), and is composed of cellular, muscular, and mucous coats.

Vesiculæ Seminales. These are situated, one on either side, between the base of the bladder and the rectum, and serve as reservoirs for the fluid secreted by the testes, and also secrete themselves a fluid accessory to that of the testicles (Fig. 181). Each is a tube, but so convoluted that it is like a little sacculated bladder. When rolled up, the tube is about two and a half inches (3.8 cm.) long, and a quarter of an inch (6 mm.) in breadth; unrolled, it would be more than twice that length, and about the size of a small writing quill. Several caecal prolongations proceed from the main tube, after the manner of a stag's horn. The vesiculæ seminales do not run parallel, but diverge from each other, posteriorly, as far as the reflection of the recto-vesical peritoneal pouch, like the branches of the letter V, and each lies immediately on the outer side of the vas deferens, into which it opens.

The vesiculæ seminales contain a brownish-coloured fluid, presumed to be in some way accessory to the function of generation.*

Prostate Gland. The prostate gland is situated at the neck of the bladder, and surrounds the first part of the urethra (Fig. 181). In the healthy adult it is about the size and shape of a horse chestnut. Its apex is directed forwards as far as the deeper layer of the triangular ligament. It is surrounded by a plexus of veins (p. 486), and is maintained in its position by the pelvic fascia (p. 485). Its upper surface is about three-quarters of an inch (18 mm.) below the symphysis pubis; its apex is about one inch and a half (3.8 cm.) from the anus; the base is about two and a half (6.3 cm.).

Above the prostate are the pubo-prostatic or anterior ligaments of the bladder, with the dorsal vein of the penis between them; below, and in contact with it, is the rectum; on each side of it is the levator ani; in front of it are the membranous part of the urethra (surrounded by its compressor muscle) and the triangular ligament; behind, are the neck of the bladder and the vesiculæ seminales with the ejaculatory ducts.

The transverse diameter is about one inch and a half (3.8 cm.); the vertical is about an inch (2.5 cm.). But the gland varies in size at different periods of life. In the child it is imperfectly developed: it gradually grows towards puberty, and generally increases in size with advancing age.

* The vesiculæ seminales are imperfectly developed till the age of puberty. In a child three years of age they can hardly be inflated with the blowpipe.

To ascertain the size and condition of the prostate during life, the bladder should be at least half full: the prostate is then pressed down towards the rectum, and readily within reach of the finger.

Anatomy of the Urethra in its passage under the Pubic Arch. The urethra is a canal about eight inches (20 cm.) in length, and leads from the bladder to the end of the penis. It is divided into three portions—the *prostatic*, the *membranous*, and the *spongy*. At present only the relations of the *membranous part*, which comprises that part of the canal between the prostate and the bulb, can be examined. The urethra in this part is the narrowest part of the canal, and measures three-quarters of an inch (18 mm.) on its upper surface, and one-half (13 mm.) on its lower surface, in consequence of the encroachment of the bulb. In its passage under the pubic arch it is surrounded by the compressor urethræ, and below it are Cowper's glands. It traverses the two layers of the triangular ligament, and is about an inch (2.5 cm.) below the symphysis pubis, from which it is separated by the dorsal vessels and nerves of the penis, and by some connective and muscular tissue; it is nearly the same distance above the rectum; it is not, however, equidistant from this portion of the intestine at all points, because of the downward bend which the rectum makes towards the anus.*

The membranous part of the urethra in children is very long, owing to the smallness of the prostate at that period of life; it is also composed of thin and delicate walls, and lies close to the rectum. In sounding a child, therefore, it is very necessary not to use violence, else the instrument is likely to pass through the coats of the urethra and make a false passage.

Levator Ani. This muscle supports the anus and lower part of the rectum like a sling; and, with the coccygeus and compressor urethræ, forms a muscular floor for the cavity of the pelvis. To see the muscle, the pelvic fascia must be reflected from its upper surface. It *arises* in front, from the posterior aspect of the os pubis near the symphysis; behind, from the inner surface of the spine of the ischium; and, between these bones, from the tendinous line which marks the division of the pelvic fascia into the obturator and recto-vesical layers (Fig. 180, p. 485). From this long origin the fibres descend inwards towards the middle line, and are *inserted* thus: the anterior, the longest, passing under the prostate, meet their fellow in the middle line of the perineum in *front* of the anus (forming the *levator prostatae*), joining the fibres of the trans-

* If a clean vertical section were made, we should see that the two canals form the sides of a triangular space, of which the apex is towards the prostate. This is sometimes called the recto-urethral triangle.

versus perinei and the external sphincter at the central tendon of the perineum; the middle, the most numerous, are inserted into the side of the rectum; the posterior are inserted, partly into the coccyx, and partly into the median raphé between the coccyx and the anus, and meet their fellow beneath the rectum.

The levator ani is supplied by the inferior hæmorrhoidal, the two lower sacral, and the coccygeal nerves.

The action of the levators ani is to retract the anus and the rectum after it has been protruded in defæcation by the combined action of the abdominal muscles and the diaphragm.

Coccygeus. This muscle is placed behind the levator ani, and should be regarded as a continuation of that muscle. It is triangular in shape, and *arises* by its apex from the spine of the ischium and the lesser sacro-sciatic ligament, gradually spreads out, and is *inserted* into the side of the lower part of the sacrum and the coccyx. Its posterior fibres are in relation with the pyriformis, its anterior fibres are continuous with the levator ani. This muscle is supplied by the two lower sacral and the coccygeal nerves.

Dissection. At this stage of the dissection, the bladder should be drawn downwards, and the branches of the internal iliac artery and the sacral plexus clearly displayed on the right side, by carefully clearing away the prolongations of the pelvic fascia which surround them.

Internal Iliac Artery and Branches. From the division of the common iliac artery, the *internal iliac* descends into the pelvis, and after a course of about an inch and a half (3.4 cm.) divides, opposite the great sacro-sciatic notch, into two large branches, an anterior and posterior (Fig. 183). The artery lies upon the lumbo-sacral cord, the pyriformis muscle, the external and internal iliac veins; the ureter, enclosed in the posterior false ligament of the bladder, passing in front: the psoas lies to its outer side at the commencement of its course.

The *posterior* division gives off the ilio-lumbar, lateral sacral, and gluteal arteries; the *anterior* gives off the superior vesical, obturator, inferior vesical, middle hæmorrhoidal, sciatic, and pudic; also the uterine and vaginal in the female. Such is their usual order; but these branches, though constant as to their general distribution, vary as to their origin.

The branches of the posterior division are—

a. The *ilio-lumbar* is analogous to the lumbar branches of the aorta. It ascends beneath the psoas and the external iliac vessels to get to the superficial surface of the iliacus. Here it divides into an iliac and a lumbar branch; the *iliac branch* supplies branches to the iliacus, a branch to the diploë of the ilium, and a large branch along the iliac crest, which finally inosculates with the deep circumflexa

ili, the epigastric, the gluteal, and the external circumflex arteries; the *lumbar branch* supplies the psoas and the quadratus lumborum, and anastomoses with the last lumbar artery; it distributes a small branch to the cauda equina, through the foramen, between the last lumbar and first sacral vertebræ.

b. The *lateral sacral*, usually two in number, an upper and a lower, descend in front of the sacral foramina, and inosculate on the coccyx with the middle sacral artery; the upper enters one of the upper sacral foramina, and, after supplying the structures in the sacral canal, emerges on the back through one of the posterior foramina and supplies the muscles in the neighbourhood, anastomosing with the gluteal artery; the lower descends in front of the pyriformis, supplying branches to this muscle, the bladder, and rectum, and others which enter the anterior sacral foramina for the supply of the cauda equina, and finally emerge through the posterior sacral foramina to end in the muscles and skin of the back: this branch inosculates with the middle and lateral sacral arteries and the gluteal.

c. The *gluteal* is the largest branch. It passes immediately out of the pelvis through the great sciatic notch, above the pyriformis muscle, and then divides into

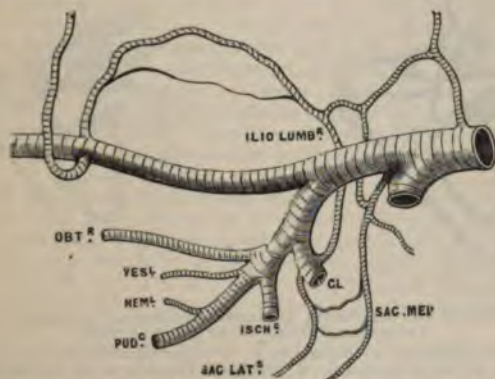


FIG. 183.—PLAN OF THE BRANCHES OF THE INTERNAL ILIAC ARTERY.

a superficial and deep branch; the former passes beneath the gluteus maximus; the latter passes between the gluteus medius and minimus, and then divides into two branches, one running along the upper attached border of the gluteus minimus, the other passing obliquely across the same muscle as far as the great trochanter, to anastomose with the external circumflex artery. These will be dissected with the gluteal region.

The anterior division gives off—

a. The *superior vesical artery*, which comes off from the unobliterated portion of the hypogastric, and supplies the upper part of the bladder. It gives off the *middle vesical artery*, which supplies the base of the bladder and the vesicula seminalis; a small branch, the *deferential*, which accompanies the vas deferens to the testis and inosculates with the spermatic artery; and smaller branches to the ureter.

b. The *inferior vesical artery*, which ramifies on the under surface of the bladder, the vesiculæ seminales, and the prostate, anastomosing with branches of the corresponding artery of the other side.

versus perinei and the external sphincter at the central tendon of the perineum; the middle, the most numerous, are inserted into the side of the rectum; the posterior are inserted, partly into the coccyx, and partly into the median raphé between the coccyx and the anus, and meet their fellow beneath the rectum.

The levator ani is supplied by the inferior hæmorrhoidal, the two lower sacral, and the coccygeal nerves.

The action of the levators ani is to retract the anus and the rectum after it has been protruded in defæcation by the combined action of the abdominal muscles and the diaphragm.

Coccygeus. This muscle is placed behind the levator ani, and should be regarded as a continuation of that muscle. It is triangular in shape, and *arises* by its apex from the spine of the ischium and the lesser sacro-sciatic ligament, gradually spreads out, and is *inserted* into the side of the lower part of the sacrum and the coccyx. Its posterior fibres are in relation with the pyriformis, its anterior fibres are continuous with the levator ani. This muscle is supplied by the two lower sacral and the coccygeal nerves.

Dissection. At this stage of the dissection, the bladder should be drawn downwards, and the branches of the internal iliac artery and the sacral plexus clearly displayed on the right side, by carefully clearing away the prolongations of the pelvic fascia which surround them.

Internal Iliac Artery and Branches. From the division of the common iliac artery, the *internal iliac* descends into the pelvis, and after a course of about an inch and a half (3.8 cm.) divides, opposite the great sacro-sciatic notch, into two large branches, an anterior and posterior (Fig. 183). The artery lies upon the lumbo-sacral cord, the pyriformis muscle, the external and internal iliac veins; the ureter, enclosed in the posterior false ligament of the bladder, passing in front: the psoas lies to its outer side at the commencement of its course.

The *posterior* division gives off the ilio-lumbar, lateral sacral, and gluteal arteries; the *anterior* gives off the superior vesical, obturator, inferior vesical, middle hæmorrhoidal, sciatic, and pudic; also the uterine and vaginal in the female. Such is their usual order; but these branches, though constant as to their general distribution, vary as to their origin.

The branches of the posterior division are—

a. The *ilio-lumbar* is analogous to the lumbar branches of the aorta. It ascends beneath the psoas and the external iliac vessels to get to the superficial surface of the iliacus. Here it divides into an iliac and a lumbar branch; the *iliac branch* supplies branches to the iliacus, a branch to the diploë of the ilium, and a *large branch* along the iliac crest, which finally inosculates with the deep circumflexa

ilii, the epigastric, the gluteal, and the external circumflex arteries; the *lumbar branch* supplies the psoas and the quadratus lumborum, and anastomoses with the last lumbar artery; it distributes a small branch to the cauda equina, through the foramen, between the last lumbar and first sacral vertebrae.

b. The *lateral sacral*, usually two in number, an upper and a lower, descend in front of the sacral foramina, and inosculate on the coccyx with the middle sacral artery; the upper enters one of the upper sacral foramina, and, after supplying the structures in the sacral canal, emerges on the back through one of the posterior foramina and supplies the muscles in the neighbourhood, anastomosing with the gluteal artery; the lower descends in front of the pyriformis, supplying branches to this muscle, the bladder, and rectum, and others which enter the anterior sacral foramina for the supply of the cauda equina, and finally emerge through the posterior sacral foramina to end in the muscles and skin of the back: this branch inosculates with the middle and lateral sacral arteries and the gluteal.

c. The *gluteal* is the largest branch. It passes immediately out of the pelvis through the great sciatic notch, above the pyriformis muscle, and then divides into

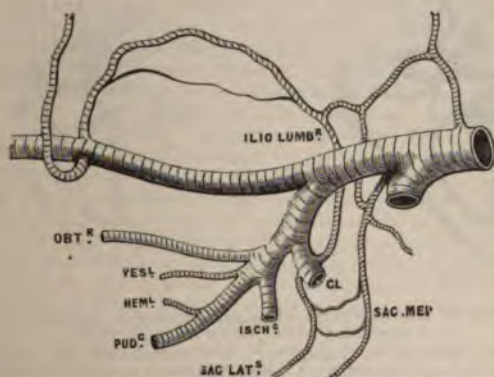


FIG. 183.—PLAN OF THE BRANCHES OF THE INTERNAL ILIAC ARTERY.

a superficial and deep branch; the former passes beneath the gluteus maximus; the latter passes between the gluteus medius and minimus, and then divides into two branches, one running along the upper attached border of the gluteus minimus, the other passing obliquely across the same muscle as far as the great trochanter, to anastomose with the external circumflex artery. These will be dissected with the gluteal region.

The anterior division gives off—

a. The *superior vesical artery*, which comes off from the unobliterated portion of the hypogastric, and supplies the upper part of the bladder. It gives off the *middle vesical artery*, which supplies the base of the bladder and the vesicula seminalis; a small branch, the *deferential*, which accompanies the vas deferens to the testis and inosculates with the spermatic artery; and smaller branches to the ureter.

b. The *inferior vesical artery*, which ramifies on the under surface of the bladder, the vesiculæ seminales, and the prostate, anastomosing with branches of the corresponding artery of the other side.

c. The *middle hæmorrhoidal artery*, which usually arises in conjunction with the preceding, and supplies the rectum, inosculating with the other hæmorrhoidal arteries.

d. The *obturator artery*, which runs along the side of the pelvis, below the corresponding nerve, to the upper part of the obturator foramen, through which it passes to be distributed to the muscles of the thigh. *In the pelvis* it lies between the peritoneum and the pelvic fascia, and gives off a small branch to the iliacus, which anastomoses with the ilio-lumbar; a *vesical branch*, which passes backwards to supply the bladder; and another, the *pubic branch*, which ramifies on the back of the os pubis, and inosculates with the corresponding branch of the deep epigastric artery and with its fellow of the opposite side. *External to the pelvis* it divides into an external and internal branch, which respectively skirt the outer and inner margins of the obturator foramen.

The obturator artery does not, in all subjects, take the course above stated,

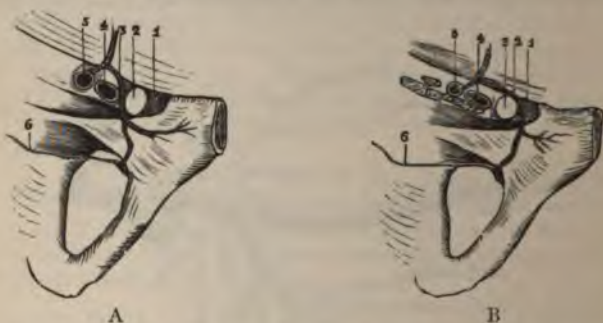

FIG. 184.—VIEW OF THE DIFFERENT DIRECTIONS WHICH AN ABNORMAL OBTURATOR ARTERY MAY TAKE. (SEEN FROM ABOVE.)

- A. 1. Gimbernat's Ligament. 2. Femoral ring. 3. Abnormal obturator artery. 4. External iliac vein. 5. External iliac artery. 6. Diminutive obturator artery arising from its normal source. B. 1. Gimbernat's ligament. 2. Abnormal obturator artery. 3. Femoral ring. 4. External iliac vein. 5. External iliac artery. 6. Diminutive obturator artery.

since, in one case in three and a half, it arises from the deep epigastric, and in one out of seventy-two cases it has its origin by a branch from the obturator joining a branch from the epigastric. It may arise from the external iliac near the crural arch, or by a short trunk in common with the epigastric.* Under these circumstances, in order to reach the obturator foramen, it generally descends on the *outer* side of the femoral ring. Instances, however, occasionally occur, where it makes a sweep round the *inner* side of the ring; so that three-fourths of the ring, or, what comes to the same thing, of the neck of a femoral hernia, would in such a case be surrounded by a large artery.

* In most subjects a small branch of the obturator ascends behind the ramus of the os pubis to inosculate with the epigastric. The variety in which the obturator arises in common with the epigastric is but an unusual development of this branch. The branch derives additional interest from the fact, that after ligature of the external iliac it becomes greatly enlarged, and carries blood directly into the epigastric. See a case in *Med. Chir. Trans.*, vol. xx., 1836.

e. The *sciatic artery* is the larger of the two branches into which the anterior trunk divides. It proceeds over the pyriformis and the sacral plexus, to the lower border of the great sciatic notch, through which it passes out of the pelvis between the pyriformis and coccygeus to the buttock, where it runs with the great sciatic nerve between the great trochanter and the ischial tuberosity. It gives off small *muscular branches* in the pelvis to the pyriformis, coccygeus, and levator ani; *vesical branches* to the bladder, prostate, and vesiculæ seminales; and *hemorrhoidal branches* to the rectum.

f. The *internal pudic artery* supplies the perineum, scrotum, and penis. In the pelvis it usually lies above the sciatic, and rests upon the pyriformis and sacral plexus, having the rectum to its inner side. It passes out of the pelvis through the great sciatic foramen, below the pyriformis and above the coccygeus, crosses over the spine of the ischium, and re-enters the pelvis through the lesser foramen. It then ascends on the inner side of the obturator internus towards the pubic arch, where it gives branches to the several parts of the penis. In its passage on the inner side of the obturator muscle it is enclosed in a strong tube of fascia, formed by the obturator fascia, and is situated about one inch and a quarter (3.1 cm). above the tuberosity of the ischium. It now ascends under cover of the ascending ramus of the ischium, where it pierces that part of the pelvic fascia which forms the posterior layer of the triangular ligament, and continues its course close to the ramus of the os pubis, between the two layers of the ligament, the anterior layer of which it pierces, and then divides into the artery of the corpus cavernosum and the dorsal artery of the penis. Throughout its course it is accompanied by the pudic nerve and veins. The branches of the pudic artery were described in the dissection of the perineum (p. 478).

The pudic artery, however, sometimes takes a very different course. Instead of passing out of the pelvis, it may run by the side of the prostate gland to its destination; or, one of the large branches of the pudic may take this unusual course, while the pudic itself is regular, but proportionably small. Anatomists are familiar with these varieties, and a winter session rarely passes without meeting with several examples of them. It need hardly be said that lithotomy, under such conditions, might be followed by a large hæmorrhage.

The *middle sacral artery* is a small branch of the abdominal aorta at its point of bifurcation. It descends in front of the body of the fifth lumbar vertebra, the sacrum, and the coccyx. In its course it gives off small branches to the rectum, to the anterior sacral foramina, and it finally inosculates on the sacrum and the coccyx with the lateral sacral arteries. It gradually becomes smaller as it passes down and terminates near the tip of the coccyx in a small body about the size of a pea, called the *coccygeal* or *Luschka's gland*, which has been previously described (p. 452).

Respecting the *veins* in the pelvis, they correspond with the arteries, and empty themselves into the internal iliac vein. The remarkable plexus of veins about the prostate, neck of the bladder, and rectum, has been described (p. 486).

Nerves of the Pelvis. Those which proceed from the spinal cord should be examined first, afterwards those derived from the sympathetic system.

Sacral Nerves. Five sacral nerves proceed from the spinal cord through the anterior sacral foramina. The upper four, from their large size, at once attract observation; but the fifth is small: it perforates the coccygeus muscle, supplying it and the skin over the coccyx.

Sacral Plexus.

The anterior divisions of three upper sacral nerves, and part of the fourth, with the lumbosacral cord, form the sacral plexus. The great nerves of this plexus lie on the anterior surface of the pyriformis, covered by the pelvic fascia, which separates it from the branches of the internal iliac vessels and the pelvic viscera. The large cords, diminishing in size from above downwards, converge from the sacral foramina to the great sacro-sciatic foramen, where they coalesce to form a broad flat cord, which passes out of the pelvis beneath the pyriformis muscle, for the supply of the flexor muscles of the inferior extremity.

Before describing the branches of the sacral plexus, it will be best to trace those sacral and coccygeal nerves which do not enter into the formation of the sacral plexus.

The lower part of the *fourth sacral nerve* lies on the coccygeus muscle, and divides into muscular and visceral branches, sending a filament downwards to join the fifth sacral nerve. It distributes branches to the pelvic viscera, and muscular twigs to the levator ani, the coccygeus, and sphincter, the latter of which also furnishes a small cutaneous filament to the skin between the bone and the anus.

The *fifth sacral nerve* emerges between the sacrum and the coccyx, pierces the coccygeus, and lies on its anterior surface. It is joined by a twig from the fourth sacral, and, after running a short distance, pierces the coccygeus again, and is distributed to the skin over the back of the coccyx. It communicates with the coccygeal nerve, and supplies the coccygeus muscle.

The *coccygeal nerve*, not easily found, emerges through the end of the sacral canal, and comes forwards through the coccygeus, between the first and second pieces of the coccyx. It pierces the great sacro-sciatic ligament, and, after receiving the communicating twig from the fifth sacral nerve, it passes backwards to supply the integument over the back and side of the coccyx. The communications between these three last nerves are sometimes described as the *coccygeal plexus*.

The *muscular branches* of the sacral plexus are as follows:—

a. *Muscular branches*, distributed to the pyriformis, the gemelli, the quadratus femoris, and the obturator internus. The *nerve to the obturator internus* is given off from the anterior aspect of the plexus (sometimes from the pudic), leaves the pelvis through the great sciatic foramen with the pudic artery, winds with it round the ischial spine, and re-enters the pelvis with the artery to reach the inner aspect of the obturator internus; it distributes a small twig to the gemellus superior. The branch to the quadratus femoris is derived from the plexus near the preceding nerve; it passes down, beneath the gemelli and obturator internus, to enter the anterior or deep aspect of the quadratus femoris, lying between this muscle and the capsule of the hip-joint: it sends off a small twig to the inferior gemellus, and another to the hip-joint.

b. The *superior gluteal nerve* proceeds from the lumbo-sacral cord and the first sacral nerve, leaves the pelvis through the great sacro-sciatic foramen with the gluteal artery, above the pyriformis, and there divides into two branches; the *upper* passes along the iliac attachment of the gluteus minimus, supplying it and the gluteus medius; the *lower* accompanies the lower branch of the gluteal artery, and supplies the glutei medius and minimus and the tensor fasciæ femoris.

c. The *pubic nerve* runs with the pudic artery, and is contained in the same sheath of the obturator fascia; it divides into two branches—the perineal nerve, and the dorsal nerve of the penis; the *former* accompanies the superficial perineal artery, and supplies cutaneous branches and muscular branches to the external sphincter, the accelerator urinæ, the transversus perinei, the erector penis, and the compressor urethræ; the *dorsal nerve* accompanies the last part of the pudic artery, and, after piercing the anterior layer of the triangular ligament and the suspensory ligament, runs along the dorsum of the penis external to the dorsal artery, and is distributed to the glans and the prepuce.

d. The *small sciatic nerve* is formed by the junction of two branches from the sacral plexus, and passes through the great sacro-sciatic foramen below the pyriformis, and then divides into two branches: one, a motor—the *inferior gluteal*—supplies the gluteus maximus; the other, a sensory, supplies cutaneous branches to the back of the thigh and leg, to the skin over the gluteus maximus, and to the perineum and scrotum. These will be dissected later on with the lower extremity.

e. The *great sciatic nerve* is the large nerve-cord which passes

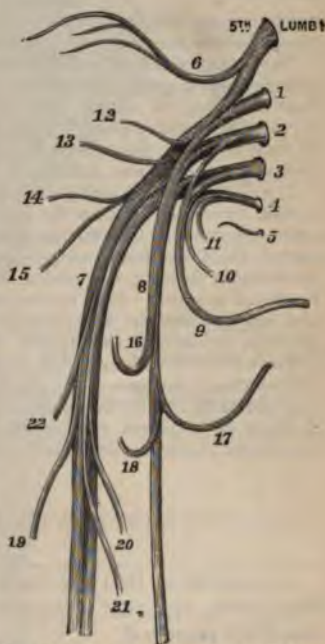


FIG. 185.—PLAN OF THE SACRAL PLEXUS AND BRANCHES.

- 1, 2, 3, 4, 5. Sacral nn. 6. Superior gluteal n. 7. Great sciatic n. 8. Lesser sciatic n. 9. Pudic n. 10. N. of obturator internus. 11. N. of levator ani. 12. N. of pyriformis. 13. N. of gemellus superior. 14. N. of gemellus inferior. 15. N. of quadratus femoris. 16. N. of gluteus maximus. 17. Long pudendal n. 18. Cutaneous n. of the buttock. 19. N. of the long head of the biceps. 20. N. of semi-tendinosus. 21. N. of semi-membranosus. 22. N. of short head of the biceps.

along the back of the thigh anterior to the gluteus maximus and the hamstring muscles, and will be dissected at a later stage.

Pelvic Sympathetic Plexus.

From the lumbar region the sympathetic nerve descends into the pelvis along the inner side of the anterior sacral foramina. In this part of its course its ganglia vary in number from four to five. The nerves of opposite sides unite in front of the coccyx, where they form the *ganglion impar*.

The arrangement of the sympathetic nerves in the pelvis is similar to that in the abdomen, each ganglion receiving a branch from the ganglion above and another from the ganglion below. The external branches communicate with the sacral nerves, one probably going to, and the other coming from, the spinal nerves; the internal branches pass partly to join the pelvic plexus, and partly to the plexus around the *arteria sacra media*.

The *pelvic plexuses* are two in number, and are situated one on each side of the rectum, being derived from the hypogastric plexus, which passes downwards between the common iliac arteries into the pelvis, reinforced by filaments from the second, third, and fourth sacral nerves and ganglia. The visceral branches are exceedingly delicate, and cannot be traced unless the parts have been previously hardened in spirit. They accompany the arteries supplying the respective organs, and are the *inferior hæmorrhoidal plexus* to the rectum; the *vesical plexus* to the sides and base of the bladder, and secondary plexuses to the vas deferens and vesicula seminalis; the *prostatic plexus* to the prostate, the vesicula seminalis, and the cavernous structure of the penis; and, in the female, the *vaginal plexus* to the vagina and its erectile tissue, and the *uterine plexus* to the neck and lower part of the body of the uterus, running between the layers of the broad ligament. It also distributes numerous filaments to the fundus of the uterus and the Fallopian tubes.

STRUCTURE OF THE BLADDER, PROSTATE, URETHRA, AND PENIS.

It is assumed that the parts have been collectively taken out of the pelvis, and that the partial peritoneal covering of the bladder has been removed.

The bladder, in a fairly dilated condition, measures about five inches (12.5 cm.) in length and three (7.5 cm.) in breadth, and when moderately full will contain about a pint (472 c.c.) of urine.

Structure of the Bladder.

The bladder is composed of a partial peritoneal coat, a muscular and a mucous; between the last two there is a layer of connective tissue, which is called the cellular coat.

The *serous* or *peritoneal coat* invests the posterior, lateral, and superior surfaces of the bladder: it is absent on the anterior and inferior aspect.

The *muscular coat* is situated beneath the serous, and consists of unstriped muscular fibres, which interlace with each other in all directions. Their general arrangement is as follows: An *outer*, or *longitudinal*, layer arises from the pubo-prostatic ligaments, the upper half of the circumference of the prostate and the neck of the

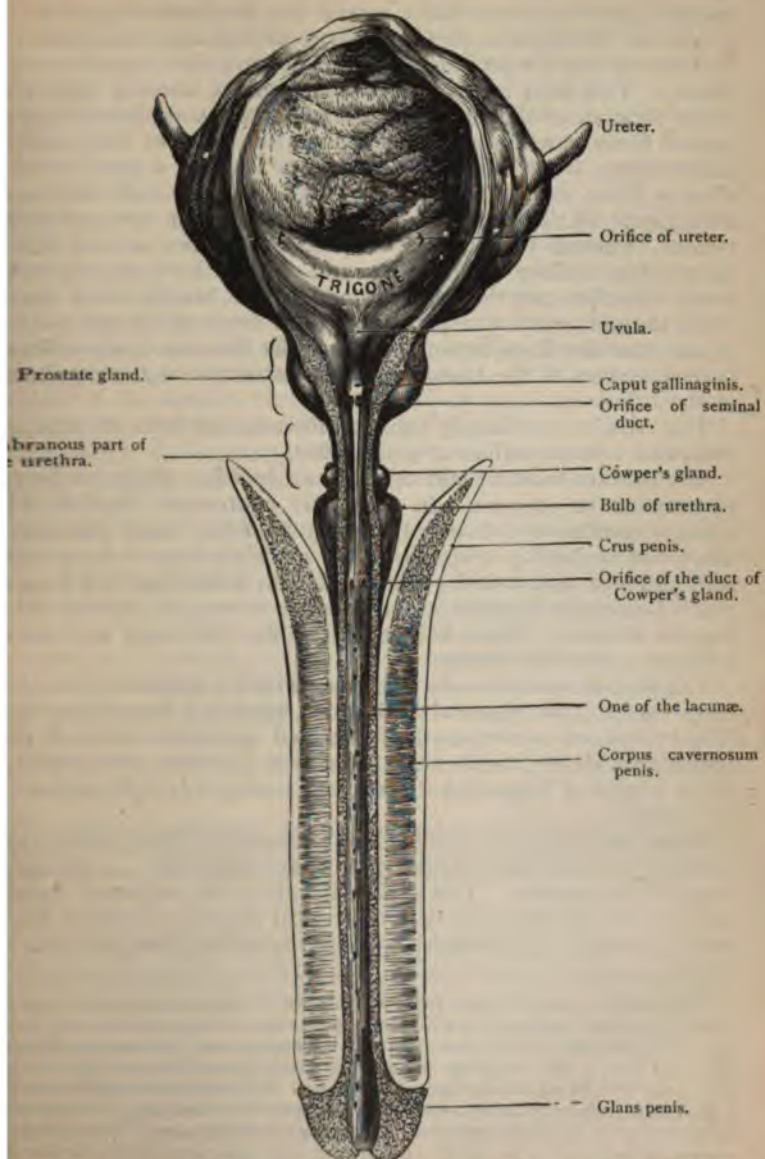


FIG. 186.—BLADDER AND URETHRA, LAID OPEN BY AN INCISION ALONG THE UPPER SURFACE.

bladder, and thence its fibres spread out longitudinally over the summit of the bladder, pass round its posterior aspect and base, to be inserted into the prostate in the male, and the vagina in the female. This layer is especially marked on the anterior and posterior surfaces of the bladder. There are also some lateral longitudinal fibres which pass backwards from the sides of the prostate and interlace in all directions. Between these is a thin layer of *circular fibres*, especially developed near the neck and the commencement of the urethra, where they form a sphincter—*sphincter vesicæ*. Towards the sides of the bladder the two sets of fibres have a less definite arrangement and form a kind of network; these, therefore, are the weakest parts of the bladder, and more liable to the formation of pouches.* The development and colour of the muscular fibres depend upon how far the subject has suffered from irritation of the bladder, or any obstruction to the expulsion of the urine.

The *cellular coat* loosely connects the muscular with the mucous coat, and is firmly adherent to the latter.

The bladder must be laid open by an incision along its front, to examine its interior. In a recently contracted bladder, the mucous membrane is disposed in irregular folds, which disappear when the bladder is distended. In a healthy state it is smooth, soft, and pale pink colour; when inflamed, it becomes of a bright red. Under the microscope its surface is seen to be studded with mucous follicles. These follicles secrete the thick ropy mucous inflammation of the bladder.

The *mucous coat* is loosely connected with the subjacent muscular layer, except at the *trigone* of the bladder, where it is firmly adherent. The epithelium is composed of flattened polyhedral cells of the transitional variety, and beneath these there have been described by Klein a layer of large club-shaped cells arranged at right angles to the surface.

When the interior of the bladder is examined, there is seen immediately behind the urethra a triangular smooth surface, the apex being at the urethra. This surface is called the *trigonum vesicæ*, and is paler and smoother than the vesical mucous membrane elsewhere; laterally it is bounded by ridges extending from the urethra

* These pouches arise in the following manner: A portion of mucous membrane is protruded through one of the muscular interstices, so as to form a little sac. This is small at first, but gradually increases in size, because, having no muscular coat, it has no power of emptying itself; generally speaking, several such sacs are met with in the same bladder, and they sometimes contain calculi. If a calculus, originally loose in the bladder, happen to become lodged in a pouch by the side of it, a sudden remission of the symptoms may ensue. This explains our occasional inability to detect its presence at each examination with the sound.

to the orifices of the ureters, the base being between the two ureters. This space corresponds with another one already described external to the bladder, and which is bounded laterally by the vesiculæ seminales, and behind by the reflection of the peritoneum. It is more richly provided with blood-vessels and nerves than the rest of the bladder, and is endowed with more acute sensibility. This is why a stone is more painful when the bladder is empty, and in the erect than in the recumbent position.

The *vesical orifice of the urethra* is situated at the lower and anterior part of the bladder, not at the most dependent part, which forms the pouch behind the orifice, in which urine is apt to accumulate in old persons. It appears small and contracted in the fresh bladder, but, if the little finger be introduced into it, it will dilate considerably. Immediately behind the orifice there is, in some bladders, a slight elevation called the *uvula*. It is composed of a portion of the mucous membrane raised up by an accumulation of the prostatic and submucous tissue, but is rarely of sufficient size to interfere with the passage of the urine. This elevation must be distinguished from enlargement of the third or middle lobe of the prostate.

The *orifices of the ureters* are situated about an inch and a half (3.8 cm.) behind the urethra, and about two inches (5 cm.) apart. These tubes perforate the coats of the bladder obliquely, and slant towards each other, standing out in relief under the mucous membrane.* A slight ridge proceeds from the orifice of each ureter to the neck of the bladder, looking like a continuation of the ureter itself. If the mucous membrane be removed from these ridges, we find that they are produced by muscular fibres. Sir Charles Bell, † who first drew attention to them, believed them to be of use in regulating the orifices of the ureters, and named them *the muscles of the ureters*.

The bladder is supplied with blood by the *superior, middle, and inferior vesical* arteries. The superior comes from the unobliterated portion of the hypogastric; the middle, from the superior vesical or the internal iliac; the inferior, from the

* This slanting of the ureters serves all the uses of a valve. The urine enters the bladder, drop by drop, but cannot return, because the internal coat is pressed against the other side of the orifice, so as to stop it. When the bladder becomes thickened, in consequence of difficulty in passing urine, it sometimes happens that the ureters lose their valvular direction, so that the urine, when the bladder contracts, is partly forced back up the ureters: the result is, that they become dilated, and the pelvis of the kidney also.

† *Med. Chir. Trans.*, vol. iii. He says: "These muscles guard the orifices of the ureters by preserving the obliquity of the passage, and pulling down the extremities of the ureters according to the degree of the contraction of the bladder generally."

anterior division of the internal iliac or the pudic. Small branches are also distributed to the bladder by the obturator and sciatic arteries.

The *veins* of the bladder form large plexuses around its neck, sides, and base, and empty themselves into the internal iliac veins. The *lymphatics* follow the course of the veins.

Its *nerves* are derived from the hypogastric and sacral plexuses; the former is chiefly distributed to the top, the latter to the neck and the bottom of the bladder.

Prostate.

Having already examined the form, size, and relations of the prostate (p. 492), we have now to make out its lobes. There are *two lateral lobes* presenting on their upper and lower surfaces a median longitudinal furrow, the lower groove terminating behind in a deep cleft; and a third or *middle lobe*. The middle one is pyriform in shape, unites the lateral lobes, and is situated between them and the urethra. In health it does not appear like a separate lobe; but when abnormally enlarged, it projects toward the cavity of the bladder, and acts like a bar at the mouth of the urethra.

Make a longitudinal incision through the upper surface of the prostate to expose the urethra. This canal runs rather nearer to its upper than its lower surface, and is not of the same calibre throughout. This part of the urethra is about an inch and a quarter (*3.1 cm.*) long, and about $\frac{1}{3}$ of an inch (*8.3 mm.*) in diameter. It forms a sinus in the interior of the prostate, described by anatomists as the *sinus of the prostate*, into which the ducts of the prostate open. Along the floor of the sinus is a longitudinal ridge, about three-quarters of an inch (*18 mm.*) in length, broad and elevated behind, but gradually fading in front. This is called the crest of the urethra, and the most prominent part of it is named the *verru montanum*, or *caput gallinaginis*, from its supposed resemblance to the head of a woodcock. On each side of this prominence the common ejaculatory ducts open (Fig. 186, p. 501).

Immediately in front of the caput gallinaginis, in the middle line, is a small opening which will admit a probe. It leads backwards into a little cul-de-sac or pouch in the substance of the prostate. This pouch is described as the analogue of the uterus, and called the *utriculus* or *sinus pocularis*. It is also called the *uterus masculinus*. It is of a pyriform shape, running backwards and upwards with the narrowest part at the orifice, and its length is about $\frac{1}{4}$ of an inch (*6 mm.*). It ascends between the lateral lobes of the prostate, and beneath the middle; its coats are comparatively thick with some muscular tissue enclosed in them, and it is lined with squamous epithelium. The minute orifices of the ducts are seen opening into the floor of the prostatic sinus. The substance of the gland is permeated by the divisions and subdivisions of the ducts. They are not visible to the naked eye, but if traced out with the microscope

they are seen to terminate in blind sacculated extremities, upon which the capillaries ramify in rich profusion.*

Structure of the Prostate.

The prostate is surrounded by a firm capsule of fibrous tissue, and is composed of muscular as well as glandular tissue. Nearly two-thirds of it is made up of unstripped muscular fibres, which constitute the stroma of the gland, and have the following arrangement: externally, beneath the capsule, they form a thick layer, continuous behind with the external muscular layer of the bladder; and in front they are arranged in a circular manner round the urethra at its vesical orifice, so as to form in conjunction with the vesical muscular tissue, a sphincter; the next layer forms a dense interlacing stratum, in the meshes of which is found the glandular tissue; the deepest layer consists of a thick layer of circular fibres, blending posteri-

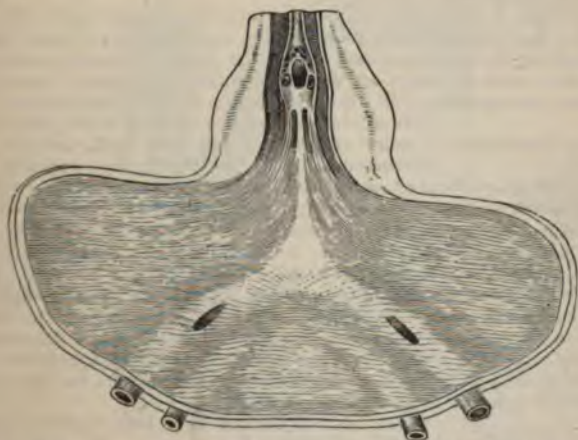


FIG. 187. LOWER PART OF THE HUMAN BLADDER LAID OPEN: showing clear part or trigone, the slit-like openings of the ureters, the divided ureters and vesiculae seminales; the sinus prostaticus, and on each side of it the openings of the ejaculatory ducts, and below both numerous small apertures of the prostatic ducts.

only with the internal vesical muscular layer, and continuous in front with those of the membranous part of the urethra. The anterior part of the prostate is chiefly muscular; posteriorly, the glandular elements predominate.

The glandular tissue consists of numerous tubular alveoli, which open into elongated excretory ducts lined with columnar epithelium. The alveoli are connected together by connective tissue, associated with fibrous prolongations from the capsule of the gland, and with the muscular tissue. The excretory ducts are

* This was first demonstrated by the late Mr. Quekett. The same anatomist has also discovered that the secreting cells of the gland contain calculi of microscopic minuteness. He finds them, almost without exception, in the prostate at every period of life. For further detail concerning them, consult the article 'Prostate' in 'Todd's Cyclopaedia.'

from twelve to twenty in number, and open into the prostatic sinus in the floor of the urethra.* The prostate is remarkable for its dilatability. If a small incision be made through the anterior part of the gland, the *base being left entire*, the gland may be dilated by the finger sufficiently to allow the extraction of even large calculi.

Any change in the dimensions of the prostate affects the canal which runs through it, and more or less obstructs the flow of urine. If the entire gland be uniformly enlarged, the length of the prostatic urethra is increased; if the enlargement preponderate at one part more than another, then the canal will deviate more or less from its natural track, and assume a more angular or a lateral curve according to the part enlarged. When the middle lobe becomes enlarged, there arises, at the neck of the bladder, a growth which will, in proportion to its size, more or less obstruct the passage of the urine. In the efforts made to introduce a catheter into the bladder, it sometimes happens that the end of the instrument is pushed through this hypertrophied lobe.

The prostate is supplied with *arteries* from the internal pudic, the inferior vesical, and the hæmorrhoidal; its *veins* form a plexus, the prostatic, around the gland, receiving in front the dorsal vein of the penis, and ending behind in the internal iliac vein; its *nerves* are derived from the hypogastric plexus, and are interspersed with ganglion cells; the *lymphatics* pass to the internal iliac glands.

Vesiculæ Seminales. The external appearance of these bodies, each of which consists of a tube coiled upon itself, has been already described (p. 492). Respecting their structure, we find that they have an *external* or *connective-tissue coat* derived from the recto-vesical fascia; a *middle* or *muscular*, consisting of superficial fibres arranged transversely, and of deep fibres arranged longitudinally, and continuous with those of the urethra; and an *internal* or *mucoous*, which is lined by a scaly epithelium, and presents a honeycombed structure, not unlike that of the gall-bladder. The duct emerges from the anterior part of the vesicula, and joins at an acute angle the *vas deferens* behind the prostate, to form the common ejaculatory duct (p. 489). Its *arteries* come from the inferior vesical and middle hæmorrhoidal; its *veins* pass to the internal iliac vein, and its *nerves* are derived from the hypogastric plexus. The function of these bodies is twofold—they act as reservoirs for the semen, and secrete a fluid accessory to generation.

Cowper's Glands. The glands of Cowper have been examined *in situ* in the dissection of the perineum (p. 477). They are placed close to the urethra, one on either side, immediately behind the bulb and between the two layers of the triangular ligament. They consist of a number of lobules united by firm connective tissue, and their collective size is somewhat larger than a pea. Each pours its secretion by a minute duct, about an inch (2.5 *cm.*) long, into the bulbous part of the urethra. The use of these glands is analogous to that of the vesiculæ seminales and the prostate—namely, to pour into the urethra a fluid accessory in some way to generation. They are found in all mammalia, and in some, *e.g.*, the mole, they increase in size periodically with the testicle.

Urethra. The urethra is the canal which extends from the bladder to the end of the penis, and serves not only as the outlet for the urine, but to transmit the secretion

* In the ducts of the prostate we often find small calculi, of a brown colour, consisting of phosphate of lime. Cases are sometimes met with in which these calculi by degrees attain a considerable size, and distend the prostate into a sac, which, when examined by the rectum, feels not unlike a bag of marbles.

of the testicles and the several glands accessory to generation. It varies in length from eight to nine inches ($20-22.5$ cm.), and is divided into three portions, according to the different structures by which it is surrounded in different parts of its course. The first inch and a quarter (3.1 cm.) is surrounded by the prostate gland, and is called the *prostatic portion*; the next three-quarters of an inch (18 mm.) which passes under the pubic arch, is surrounded by

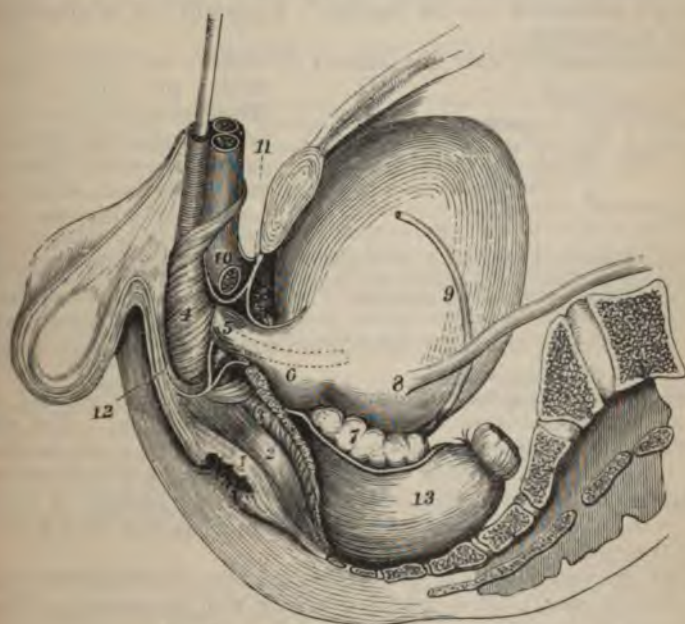


FIG. 188.—SIDE VIEW OF THE PELVIC VISCERA.

(Taken from a Photograph.)

1. External sphincter. 2. Internal sphincter. 3. Levator ani cut through. 4. Accelerator urinæ.
 5. Membranous part of the urethra, surrounded by compressor muscle. 6. Prostate gland.
 7. Vesicula seminalis. 8. Ureter. 9. Vas deferens. 10. Crus penis divided. 11. Triangular ligament. 12. Superficial perineal fascia. 13. Rectum.

the compressor urethræ, and is termed the *membranous portion*; the remainder of its course, about six inches (14 cm.) in length, is contained in the corpus spongiosum, and is called the *spongy portion*. The length of the urethra will vary much in different subjects, and according to the condition of the penis.

The direction of the urethra, when the penis hangs flaccid, is

like the letter S reversed; but if the penis be held straight, the canal forms only one curve through the pubic arch, with the concavity upwards. The degree of this curvature varies at different periods of life. In the child, the bladder being more an abdominal than a pelvic viscus, the curve forms part of a much smaller circle than in the adult; but it gradually widens as age increases, and catheters are shaped accordingly. However, the parts, when in a sound state will yield sufficiently to admit the introduction of a straight instrument into the bladder. A straight staff is sometimes used in lithotomy.

In its contracted state, the sides of the urethra are in close apposition;

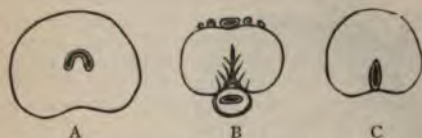


FIG. 189.—TRANSVERSE SECTIONS OF THE URETHRA. A. Through the prostate. B. Through the corpus spongiosum. C. Through the glans penis.

the appearance it presents on a transverse section differs in the different parts of its course. Through the glans it is flattened vertically; through the prostate it is crescentic, with its convexity upwards, owing to the *veru montanum*. But throughout the

rest of its course the canal exhibits on section the appearance of a transverse slit (Fig. 189).

The urethra must be laid open from end to end along its roof, to see that the canal is not of uniform calibre throughout. The external orifice is the narrowest and the least dilatable part; so that the urine may be expelled in a jet. Therefore, any instrument which will enter the meatus ought to pass into the bladder, if there be no stricture. The junction of the membranous with the bulbous part is almost as narrow.

The *prostatic portion* of the urethra has been described with the prostate (p. 504); the *membranous portion* with the anatomy of the side view of the pelvic viscera (p. 493).

The *spongy portion*, so termed because it is surrounded by the erectile tissue of the corpus spongiosum, is about six inches (14 cm.) long. That part of it running through the bulb is called the *bulbous portion*, and is the most dilatable part of the urethra except the prostatic. In the centre of the glans penis the canal widens into a sinus termed *fossa navicularis*; its termination, at the *meatus urinarius*, is the most contracted part of the urethra.

The most *dilatable* part of the urethra is the prostatic. Even the narrowest parts of the canal must admit of considerable dilatation, since calculi of from $\frac{1}{4}$ to $\frac{1}{3}$ of an inch (6 to 8 mm.) in diameter can pass through it.

The common ejaculatory ducts (Fig. 186, p. 501) open into the prostatic part of the urethra, by the side of the veru montanum. The ducts of Cowper's glands open into the bulbous part. Besides these glands, a number of ducts open into the urethra, proceeding from small glands situated in the submucous tissue. These ducts, called the *glands of Littre*, or *lacunæ*, are large enough to admit a bristle, and run in the same direction as the stream of the urine. Most of them are on the lower surface of the urethra; but one, called *lacuna magna*, is on the the upper surface, about one inch and a half (3.8 cm.) down the canal.

The urethra is composed of three coats—a mucous, muscular, and erectile.

The *mucous coat* is continuous posteriorly with that of the bladder, and it sends down prolongations into the various ducts which open into it. It is arranged in longitudinal folds in the membranous and spongy portions, and is lined by columnar epithelium except near the glans, where there are papillæ, covered with squamous epithelium; this, therefore, is the most sensitive part.

Beneath the mucous membrane is a double layer of *unstriped muscular tissue*, the superficial fibres being arranged longitudinally, the internal fibres circularly. The superficial fibres are continuous with those of the bladder, the external fibres of which surround the spongy portion of the urethra, being placed between it and its fibrous capsule; the deeper fibres of the bladder pass forwards, surrounding the prostatic urethra, and subsequently the spongy urethra, immediately beneath the mucous membrane. Between the mucous and muscular coats is a layer of areolar tissue, the *submucous tissue*.

The *erectile coat*, a thin stratum of erectile tissue derived from the corpus spongiosum, extends from this body round the membranous and the prostatic portions of the canal.

Lastly, the urethra is provided with a closely-set network of *lymphatic vessels*, which has been demonstrated by quicksilver injections. They run from behind, forwards, and join the lymphatics of the glans penis. Eventually, their contents are transmitted down the great trunks on the dorsum penis to the inguinal glands. This explains the pathology of a bubo.

The Penis.

The *penis* is a pendulous organ through which runs the urethra for three-fourths of its course; it consists of a root, a body, and the glans penis. The *root* is the broadest part, and is connected by two crura to the rami of the pubic bones; its dorsum being supported by a strong elastic suspensory ligament, which is attached to the symphysis pubis. The *body* is cylindrical, consisting of the two corpora cavernosa and the corpus spongiosum. The *glans* is the expanded extremity which presents at its apex the orifice of the urethra, and at its base where it is attached to the body there is a deep circular groove, the *cervix*, the elevated margin in front being called the *corona glandis*. In these situations are a number of minute sebaceous glands, *glandulæ Tysonii odoriferæ*, which secrete a sebaceous substance, called smegma preputii. The surface of the glans has no sebaceous glands, but is covered with minute vascular

papillæ, endowed with keen sensibility by the dorsal nerves of the penis. The skin of the penis is remarkably thin and extensible, and connected to the body of the organ by loose areolar tissue, destitute of fat. At the extremity the skin forms the prepuce, or foreskin, for the protection of the glans;* and the thin fold which passes from the under surface of the glans to the prepuce is called *frænum præputii*. The skin, altered in character, is reflected over the glans, to which it is intimately adherent, and at the orifice of the urethra is continuous with the mucous membrane.

The bulk of the penis consists of two parallel cylindrical bodies, of erectile structure, named from the appearance of their interior *corpora cavernosa*. In a groove along their under surface is lodged a third cylindrical body, the *corpus spongiosum*, composed of vascular spongy tissue, through which runs the urethra; an expansion of this at the end of the organ forms the *glans*. These structures, then—the corpora cavernosa and the corpus spongiosum—together form the penis; though the corpus spongiosum appears closely united to the corpora cavernosa, yet it is quite distinct from them, as shown in the transverse section (Fig. 190).

Corpora Cavernosa. The *corpora cavernosa*, placed side by side, constitute more than two-thirds of the bulk of the penis. Each commences posteriorly by a gradually tapering portion, called the *crura penis*, which is attached along a groove in the rami of the ischium and os pubis, where it is embraced by the erector penis (p. 472). The two crura converge, come into apposition at the root of the penis, prior to which each presents an enlargement, less in man than in some animals, called the *bulb of the corpus cavernosum*; they then run together, side by side, to form the body of the organ. Anteriorly, each terminates in a rounded extremity, received into a corresponding depression in the glans, to which it is connected by fibrous tissue.

A section through the corpus cavernosum shows that its interior is composed of a delicate reticular structure, surrounded by a white fibrous and elastic coat, from $\frac{1}{8}$ to $\frac{1}{2}$ of an inch (*1 to 2 mm.*) in thickness, and is separated from its fellow by a fibrous septum called the septum pectiniforme.

* When the foreskin is, from birth, so tight that the glans cannot be uncovered, such a state is called a congenital phymosis. This condition occasions no inconvenience in childhood, but is apt, after puberty, to become troublesome and painful, so that it may become necessary to slit up the prepuce and set the glans at liberty. In persons who have a tight foreskin, it sometimes happens that, when the glans has been uncovered, the prepuce cannot be again drawn over it: this is called a paraphymosis. The neck of the glans becomes tightly girt; great distension and inflammation are the consequences unless the foreskin be reduced.

The *septum pectiniforme* is a median vertical partition between the two corpora cavernosa; it is only complete near the root of the penis; along the rest of the organ there are vertical slits in it, giving it the appearance of a comb; hence its name. Through the intervals in this partition the blood-vessels of the two corpora cavernosa communicate freely with each other.

The *fibrous investment* is thick and strong, and consists of longitudinal bundles of white fibrous tissue, intermingled with yellow elastic fibres. From the interior of the fibrous coat numerous delicate septa, *trabeculae*, pass into the interior of the corpus cavernosum, intersecting each other in all directions, dividing it up into a multitude of small spaces. This trabecular tissue consists of fibrous lamellæ, with elastic and some non-striated muscular tissue. The spaces, lined by a layer of flattened epithelium cells, similar to that of veins, communicate freely with each other, as may be readily ascertained by blowing air into the penis; they are smaller, and their component septa thicker at the circumference than in the centre of the corpora cavernosa, at the root than towards the glans. Each corpus cavernosum thus consists of innumerable spaces mainly occupied by dilated venous sinuses, from which the blood is conveyed by the dorsal vein, the prostatic plexus,

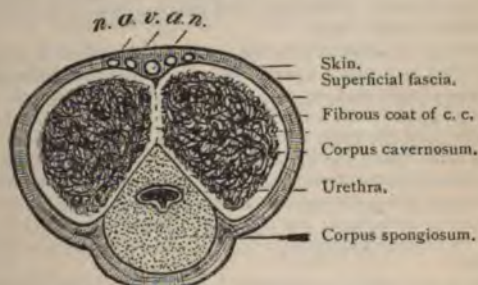


FIG. 190.—TRANSVERSE SECTION OF THE MIDDLE THIRD OF THE BODY OF THE PENIS.
n. Nerve. a. Artery. v. Vein.

and the pudendal veins. When the penis is flaccid, these spaces are empty; when it is erect, they are distended with blood.

The arteries of the corpora cavernosa come from the branches of the pudic (p. 478), which enter the inner side of each crus, at its bulbous enlargement, and proceed forwards near the septum, distributing numerous ramifications. These are supported in the middle of the fibrous trabeculae, and end, some in capillaries which convey their blood at once into the intertrabecular spaces; others in tendril-like prolongations with dilated extremities which project into the spaces, called *helicine arteries* by Müller, and which open directly into the cavities of the veins by funnel-shaped orifices. The helicine arteries are absent near the glans, and are best marked at the root of the penis. The peculiar appearance which they present when distended with injection is due to the fact that they are bound down to the trabecular tissue by fibrous bands.

The blood from the intertrabecular spaces of the penis returns, partly through veins which pass out on the upper surface of the penis into the dorsal vein (which joins the prostatic plexus), partly through the deep veins which leave the inner side of each crus and the bulb to join the internal iliac.

Corpus Spongiosum. The *corpus spongiosum* is the erectile tissue which surrounds the urethra as it runs along the penis. It commences in the middle of the perineum, anterior to the triangular ligament, in a bulb-like form—the *bulb*—and at the end of the penis it expands to form the *glans penis*. It receives posteriorly an expansion from the triangular ligament, and presents a median groove, marking its development from two lateral halves. The urethra does not pass through the middle of the spongy body, but runs nearer to its upper surface. The bulb hangs more or less pendulous from the urethra, and is surrounded by the accelerator urinæ muscle (p. 472). In old persons it extends lower down than in children, and is, consequently, more exposed to injury in lithotomy.

The corpus spongiosum has a fibrous coat resembling very much the external fibrous investment of the corpus cavernosum, but it is thinner, whiter, and composed of more elastic tissue. The reticular structure is also finer, and the cavernous meshes smaller, and arranged in a longitudinal direction. Plain muscular fibres surround the urethra, and they are also found in considerable amount in the external fibrous coat.

Its interior consists of erectile tissue, composed of a plexus of minute tortuous veins, lined by a single layer of flattened endothelial cells, and which communicate very freely with each other. This is easily demonstrated by injecting the dorsal vein of the penis with wax. In this way, we not only fill the spongy body, but also the glans, and the large veins which form the plexus round the corona glandis.

The *veins* return the blood; some by small veins, which emerge from the glans and collect on the dorsal surface to form the dorsal vein; others pass into the dorsal vein, either through the corpora cavernosa, or by curving round the sides of the corpora cavernosa; but by far the larger number join the prostatic and the pudic veins, communicating also with the subcutaneous veins of the penis and the scrotum.

The *nerves* of the penis are the *pudic* and its *superficial perineal branch*. The largest branches run along the dorsum to the surface of the glans; a few only enter the erectile tissue of the organ. The pudic nerve and its branch supply the skin and the mucous membrane. Some of the filaments distributed to the glans have connected with them Pacinian bodies, and some end in simple and compound end-bulbs. The erectile tissue is supplied by numerous filaments proceeding from the *hypogastric plexus*.

The *lymphatics* consist of a superficial and a deep set; the *superficial*, proceeding from the glans and the integument of the penis, join the inguinal glands. The lymphatics of the glands communicate freely all round it: this explains why a venereal sore on one side sometimes affects the inguinal glands on the other. The *deep* lymphatics from the corpora cavernosa and the corpus spongiosum pass beneath the pubic arch and join the lymphatics of the pelvis.

DISSECTION OF THE FEMALE PELVIC VISCERA.

After the removal of the left innominate bone, as described in the dissection for the side view of the male pelvic viscera, the vagina, rectum, and bladder should be moderately distended, the two former with tow, the latter with air. This done, the reflections of

Side view of the Female Pelvic Organs.

the peritoneum must be traced, the description of which will be found in the dissection of pelvic viscera from above (Fig. 171, p. 466). After this, clean off the peritoneum, and make out the pelvic fascia and its prolongations.

Pelvic Fascia.

To the description of the fascia already given in the dissection of the male pelvis (p. 484), nothing need be added, except that from the side of the pelvis it is reflected over the side of the vagina and the uterus, as well as the bladder.

It is this fascia which in great measure supports the uterus in its proper level in the pelvis. When, from any cause, the fascia becomes relaxed, there is a liability to prolapsus uteri.

Levator Ani.

For the description of this muscle, see p. 493.

Bladder.

The female bladder is broader transversely, and, upon the whole, more capacious* than the male. The vesical plexus of veins is not so large, and there are no vasa deferentia or prostate gland. The short urethra has a constrictor muscle, as in the male, and is supported in a similar manner by the pelvic fascia.

Venous Plexus

about the Vagina.

Though the veins round the neck of the bladder are comparatively small in the female, attention should be directed to the plexus of large veins which surround the vagina. They communicate freely with the veins about the rectum, and empty themselves into the internal iliac. Their congestion in pregnancy sufficiently accounts for the dark colour of the vagina and the external organs, and the frequent occurrence of hæmorrhoidal tumours. These veins must be removed, with the connective tissue in which they are embedded, before a clear view of the parts can be obtained.

Urethra.

The urethra has already been described (p. 481). But, in the side view of the parts, we have the opportunity of observing how closely the bladder and urethra are connected to the upper wall of the vagina; and we can understand how, in cases of protracted delivery, it sometimes happens that the contiguous coat of the bladder and the vagina give way, and that a fistulous communication remains between them, through which urine constantly dribbles.

Vagina.

It is necessary to slit open the whole of the vagina along the side to obtain a clear idea of the manner in which it embraces the lower end of the uterus, and of the extent to which the neck of the uterus projects into it. (Fig. 171, p. 466).

* This is only so from force of habit, for the organ is really smaller than in the male. (A. H.)

The length of the vagina, in the unimpregnated adult, is about four inches (10 cm.) on its anterior wall, and between five and six (12.5 to 15 cm.) along its posterior wall, owing to its curved direction.* It may be more or less, the difference in each case depending upon the depth of the pelvis, the stature, and age of the individual. The vagina, however, is never so long that we cannot, during life, feel the neck of the uterus projecting at the top of it, higher up, or lower down, according to circumstances. For instance, it is a little lower down in the erect than in the recumbent position; again, in the early months of utero-gestation the uterus descends a little into the vagina, so that this canal becomes shorter: the reverse holds good when the uterus begins to rise out of the pelvis.

The axis of the vagina is slightly curved with the concavity upwards; it corresponds with the axis of the outlet of the pelvis.

The width of the vagina is not uniform throughout. The narrowest part is at the orifice; it is also a little constricted round the neck of the uterus. The widest part is about the middle: here a transverse section through it presents the appearance of a broad horizontal fissure. If, therefore, you would insert the bivalve speculum with the least amount of pain, the blades of the speculum should be vertical when introduced into the orifice, and afterwards turned horizontally.

Structure of the Vagina.

The vagina consists of a mucous coat, of a muscular coat, and of an external coat of erectile tissue.

The *mucous membrane* is of a pale rose colour, continuous above with that of the uterus, and below with the integument of the labia majora. It is rough and furrowed, especially near the orifice, and it presents two longitudinal ridges—*columnæ rugarum*—which run, one along the anterior, the other along the posterior wall. From each side of these proceed a series of transverse ridges—*rugæ*—with rough margins directed forwards. They are well marked in virgins, but repeated parturition and increasing age gradually smooth them down. The use of the vaginal rugæ is to excite the sensibility of the glans in coition. They themselves also possess keen sensibility, being richly endowed with papillæ. The mucous membrane is provided with numerous papillæ, conical in shape, and covered with a thick lining of squamous epithelium. In the submucous tissue, which is very loose, there is a good deal of muscular tissue, with a considerable venous plexus, forming a kind of erectile tissue; in it, also, are found an abundant supply of muciparous glands, which increase in size and number towards the uterus.

The *muscular coat* is arranged in two layers, a longitudinal and a circular, between which there may be demonstrated a number of interlacing fibres passing from one to the other layer. The longitudinal fibres are continuous with the superficial muscular fibres of the uterus, while the latter are chiefly aggregated at

* This is subject to great variations, especially in the African, where it is longer and more capacious. (A. H.)

the orifice of the vagina, forming a kind of sphincter muscle, which is continuous with the external sphincter ani. Superiorly, the vagina is intimately attached to the neck of the uterus, while to the rectum it is but loosely connected.

The *erectile tissue* found in the connective tissue forms the chief strength of the vagina, being about one-twelfth of an inch in thickness. If this coat be minutely injected, we find that it is composed mainly of a plexus of veins surrounded with numerous fasciculi of unstriped muscular fibres.

Uterus.

The uterus is the hollow muscular organ which receives the ovum, retains it for nine months to bring it to maturity, and then expels it by virtue of its muscular walls. Its situation and peritoneal connections have been described (p. 465). Its axis slants forwards, so that, upon the whole, the axis of the vagina and uterus describes a curve nearly parallel to the axis of the pelvis. The uterus, then, is so situated that it is ready to rise out of the pelvis into the abdomen after the embryo has attained a certain size.

The uterus in the unimpregnated state is pyriform, or rather triangular, with the angles rounded, and is somewhat flattened antero-posteriorly. It is retained in its position by the broad and round ligaments, and measures about three inches (7.5 cm.) in length, two (5 cm.) in its broadest part, and one inch (2.5 cm.) thick in its upper part, and weighs from an ounce (28 $\frac{1}{3}$ gm.) to an ounce and a half (44 $\frac{1}{2}$ gm.); but there is a variety in this respect, arising from age, the effect of pregnancy, and other causes.

For convenience of description the uterus is divided into the fundus, the body, and the cervix.

The *fundus* is applied to the broadest part, which lies above the level of the Fallopian tubes, and is completely invested by peritoneum.

The *body* is the central part, and gradually narrows down to the cervix. Its lateral margins are nearly straight, and give attachment, respectively, from above downwards, to the Fallopian tube, the round ligament, the ligament of the ovary, and the broad ligament; its anterior surface is flat, and for full three-fourths of its extent is covered with peritoneum; its posterior surface is convex, and is entirely invested with peritoneum.

The *cervix* is the lower narrow part which projects into the vagina. The vagina is very closely attached round the neck of the uterus; observe that it is attached higher up behind than in front. At the free end of the cervix there is a transverse slit, the *os uteri*, bounded in front by the anterior lip, behind by the posterior lip.

Postponing for the present the examination of the interior of the vagina and the uterus, let us pass on to the vessels and nerves of these organs.

Uterine and Vaginal Arteries.

The uterus is supplied by the uterine arteries derived from the internal iliac, and also by the ovarian arteries; the vagina by the vaginal arteries from the same source; and the ovaries by the ovarian arteries (which correspond to the spermatic arteries in the male) given off from the abdominal aorta just below the renal arteries.

The *uterine artery* proceeds from the anterior division of the internal iliac, towards the neck of the uterus, between the layers of the broad ligament, and then ascends tortuously by the side of the uterus, giving off numerous branches to it, which anastomose freely with each other, and with a small branch from the ovarian artery. The fundus of the uterus is mainly supplied with branches from the ovarian arteries.

The *vaginal artery* ramifies along the side of the vagina, and distributes branches to the lower part of the bladder and the rectum.

The *veins* of large size, corresponding with the arteries, form the uterine sinuses and the vaginal plexuses, which empty themselves into the internal iliac vein.

Nerves of the Uterus.

The *nerves* of the uterus are derived from the third and fourth sacral nerves, from the hypogastric and ovarian plexuses (p. 459). They accompany the blood-vessels in the broad ligament to the neck of the uterus, and ascend with them along its sides.

Some small filaments continue with the vessels, and form around them plexuses, upon which minute ganglia are found. But most of the nerves soon leave the vessels, and, subdividing, sink into the substance of the uterus, chiefly about its neck and the lower part of its body. A branch may be traced passing up to the fundus of the uterus, and another to the Fallopian tube.

The nerves of the uterus enlarge during pregnancy like the arteries. Surgically speaking, the *os uteri* may be said to have no nerves, for it is insensible to the cauterly and to the knife.

The *lymphatics* of the uterus are small in its unimpregnated state, but greatly increase in size when it is gravid. Those from the fundus and the ovaries proceed with the ovarian vessels to the lumbar glands, thus explaining the affection of these glands in ovarian diseases. Those from the body and the lower part of the uterus accompany the uterine arteries, and join the glands in the pelvis; some, however, run with the round ligament to the groin; hence, in certain conditions of the uterus, the inguinal glands may be affected.

The uterus, vagina, Fallopian tubes, and the ovaries should now be collectively removed from the pelvis for the purpose of examining their internal structure.

The structure of the vagina has been already described (p. 514).

Structure of the Uterus.

Before the uterus is laid open, examine the shape of that portion of the neck which projects into the vagina. The back part of the cervix appears to project into the vagina more than the front; but this arises from the vagina being attached higher up posteriorly. If the vagina were cut away from the cervix, the anterior lip of the uterus

would appear to project a trifle more than the posterior. For this reason, as well as on account of the natural slope forwards of the uterus, the front lip is felt first in an examination per vaginam.* The length, however, and the general appearance of the vaginal part of the cervix vary according to the age; it is also considerably altered by parturition. In the adult virgin it is smooth and round, and projects about half an inch (13 mm.); its mouth is a small transverse fissure. But after parturition it loses its plumpness, the lips become flaccid and fissured, and the mouth larger than it was before.†

The uterus must now be laid open by a longitudinal incision, to examine its interior. In doing so, observe the thickness of its walls, which is greatest towards the fundus. Before coming into the proper cavity in the body of the uterus, slit up a long, narrow canal which leads up into it through the neck. This canal, which is about an inch (2.5 cm.) in length, is not of the same dimensions throughout; it is dilated in the middle, and gradually narrows towards each end. The upper end, which leads into the body of the uterus, is called *os internum*; the lower end, which leads into the vagina, *os externum*. The passage is called the *canal of the cervix*. It remains unchanged in pregnancy for some time after the cavity in the body has expanded, but gradually disappears with the increasing size of the embryo.

The shape of the *cavity* in the body of the uterus is triangular, with the apex towards the cervix. In a virgin uterus the cavity is very small, and its sides are convex; but in a uterus which has borne many children, the cavity has lost the convexity of its sides, and has increased in capacity. Each angle at the base is somewhat prolonged, and leads to the minute opening of the Fallopian tube. This prolongation of the angles is noticed more or less in different females, and is the last indication of the two horns of the uterus in some orders of mammalia.

The interior of the uterus is smooth at the fundus, but the reverse at the cervix. Here there is a central longitudinal ridge,

* This is the only way to reconcile the discrepancies one meets with in anatomical works respecting the comparative length of the lips of the uterus. Krause, Weber, Busch, and others, say the anterior is the longer; Mayer, Meckel, Quain, and others, the posterior.

† Instances are recorded in which the neck of the uterus is preternaturally long. It has been known to project even as much as an inch and a half (3.8 cm.) into the vagina. In such cases it gradually tapers, and terminates in a very narrow mouth. This is said to be one cause of sterility, and it is recommended either to dilate the mouth, or to cut off a portion of the neck. In support of this opinion, it is stated that Dupuytren was once consulted by a lady on account of barrenness; finding the neck of the uterus unusually elongated, he removed a portion of it, and shortly the lady became pregnant. (Hynl, *Handbuch der top. Anatom.*)

both in front and behind (as in the vagina); from these, other closely set oblique ridges curve off laterally, like the branches of a palm-tree, called *arbor vite uterina*. The roughness produced by these ridges occasions an impression as though we were touching cartilage when a sound is introduced into the uterus.

The *neck* of the uterus is provided with small muciparous glands, of which the minute ducts open in the furrows between the ridges referred to. The secretion of these glands is glairy, albuminous, and slightly alkaline. Soon after impregnation the secretion becomes so firm as to plug the mouth of the uterus; but shortly before and during parturition it is poured out in great quantity, to facilitate

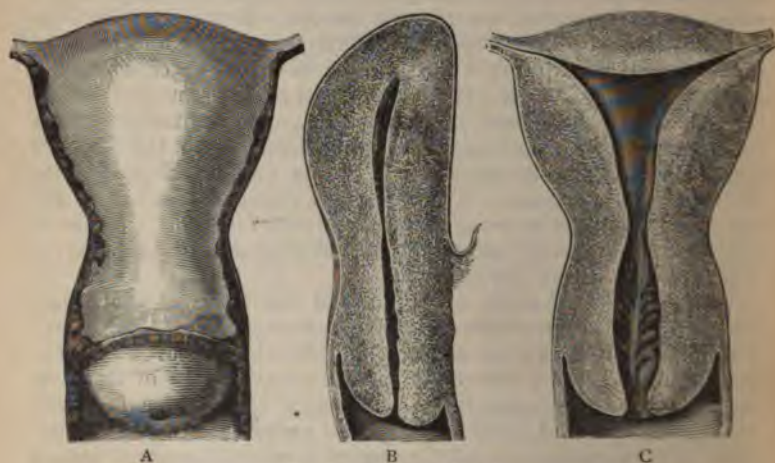


FIG. 191.—VIRGIN UTERUS.

A. Anterior view. B. Median section. C. Lateral section.

the passage of the child. It happens occasionally that one or more of the ducts of these glands becomes obstructed, and then dilate into small transparent vesicles, which gradually rise to the surface and burst.*

The walls of the uterus consist of an outer serous coat derived from the peritoneum, an inner mucous lining, and an intermediate layer of unstriped muscular tissue.

The *serous coat* has been already described.

The *muscular coat* forms the greater part of the thickness of the

* These were first described by Naboth, and supposed to be true ova; hence their name, *ovula Nabothi*. (*De Sterilitate Mulierum*. Lips., 1707.)

walls of the uterus, and consists of non-striped or involuntary muscular fibres, chiefly aggregated at the fundus, less so at the junction of the Fallopian tubes. The texture of these fibres is very close, and interwoven together with blood-vessels, nerves, lymphatics, and connective tissue; so that in the unimpregnated uterus it is almost impossible to trace them. In the impregnated condition it is less difficult to trace them, and we can make out that the fibres are arranged in three layers—an external, a middle, and an internal.*

The *external layer*, placed immediately beneath the peritoneum, is thin, and its fibres, beginning as longitudinal at the cervix, run transversely round the uterus, some of them being continued in an oblique direction over the body into the broad ligaments; these are continued on to the Fallopian tubes, the round ligaments, and the ligaments of the ovaries. A band of longitudinal fibres passes from the anterior surface of the uterus round the fundus to its posterior aspect, beneath the recto-uterine folds of the peritoneum.

The *middle layer* runs in all directions, having no definite arrangement of its fibres.

The *internal layer* is composed mainly of concentric circles which surround the orifices of the Fallopian tubes; at the cervix its fibres are arranged transversely, forming a sphincter. It is this layer which forms the thickest stratum and is closely connected with the mucous membrane; it is called the *muscularis mucosa*.

Upon the whole, the collective disposition of the muscular layers is such as to exert equal pressure on all sides when called into action. At the same time that they expel the foetus, the muscular fibres perform another very important function: they close the large venous sinuses consequent upon the great increase in the amount of blood during pregnancy. Therefore, little hæmorrhage accompanies the expulsion of the placenta, provided it have been attached to the fundus or the side of the uterus. But every one knows the danger of what is called *placenta prævia*. Here, the placenta, placed entirely or partly over the orifice of the uterus, is attached to a part of the organ which must of necessity expand during labour, and every uterine contraction increases, instead of checking, the bleeding. For the same reason, paralysis of the muscular fibres in immediate connection with the placenta, be it where it may, is likely to be a source of serious hæmorrhage in parturition.

The *mucous membrane* of the uterus is more delicate and softer than that of the vagina, with which it is continuous, and is closely united to the subjacent tissue. The greater part of it is lined by a columnar ciliated epithelium, but that which lines the lower part of the cervix is squamous, like that of the vagina. Examined with a lens, the mucous membrane lining the body of the uterus is seen to be

* In the unimpregnated uterus the muscular fibres are about $\frac{1}{110}$ th of an inch in length; in the gravid uterus they increase to $\frac{1}{30}$ th of an inch.

covered with minute follicles or tubes (*uterine glands*) arranged at right angles to its surface. These tubes pass outwards in a more or less spiral manner, some of them appearing branched and dilated at their extremities. They become greatly developed shortly after impregnation, and take an important part in the formation of the *membrana decidua*.

The arrangement of the mucous membrane in the cervix has been already described (p. 518) when the uterus was laid open to expose its cavity.

Fallopian Tubes. The *Fallopian tubes* or *oviducts* are situated, one on each side, along the upper free border of, and enclosed by, the broad ligament of the uterus, and convey the ovum from the ovary to the uterus (Fig. 192). They are about four inches (10 cm.) in length: one end, the *ostium internum*, opens by a minute orifice into the upper angle of the cavity of the uterus; the other terminates in a wide, funnel-shaped mouth, the *ostium abdominale*, surrounded by fringe-like processes called the

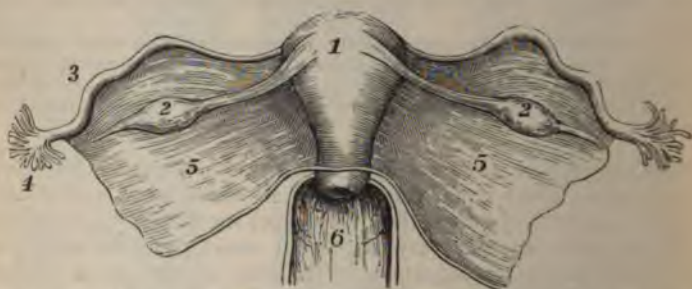

FIG. 192.—DIAGRAM OF THE UTERUS, ITS BROAD LIGAMENTS, THE OVARIES, AND FALLOPIAN TUBES. (SEEN FROM BEHIND.)

1. Uterus. 2. Ovary, with its ligaments. 3. Fallopian tube. 4. Fimbriated extremity of Fallopian tube. 5, 5. Broad ligament. 6. Vagina.

fimbriæ. This termination of the Fallopian tube is called its *fimbriated extremity*,* and its canal opens into the peritoneal cavity, so that thus the cavity of the peritoneum in the female communicates through the uterus and the vagina indirectly with the exterior. The fimbriated extremity extends about an inch (2.5 cm.) beyond the ovary, and, by floating it in water, one or two of the fimbriæ may be seen connected with the outer end of the ovary. If the Fallopian tube be opened from the dilated end, and a probe introduced into it, you will find that the tube runs very tortuously at first, then straight into the uterus, gradually contracting in size, so

* The fimbriated extremity is sometimes called the *morsus diaboli*, since it embraces in a peculiar way the ovary during sexual excitement.

that the uterine orifice scarcely admits a bristle. The free end of the tube communicates with the cavity of the peritoneum. This is the only instance where a mucous membrane is directly continuous with a serous one. It explains how the embryo may escape into the peritoneal cavity, though this is an extremely rare occurrence. It also explains what is said to have occurred, namely, the escape of the fluid in dropsy through the Fallopian tubes. In a well-injected subject, the Fallopian tubes are seen to be well supplied with blood from the ovarian arteries.

The coats of the Fallopian tube are three—an *external serous coat*, derived from the peritoneum; a *middle muscular coat*, consisting of plain muscular fibres; an external layer, longitudinal, and an internal layer, circular, both being continuous with those of the uterus; and an *internal mucous coat* arranged in longitudinal folds, especially at the ovarian end, and covered with a columnar ciliated epithelium.

Ovaries.

The *ovaries* (called by Galen, *testes muliebres*, being the analogues of the testes in the male) are two oval bodies situated between the two layers of the broad ligament of the uterus, in its posterior part. They are connected on their inner side to the uterus by a thin cord, called the *ligament of the ovary*, and at their outer end they are usually attached to one of the fimbriæ of the Fallopian tube by fibrous tissue. The ovaries are of whitish colour, with the long axis transverse, flattened from above downwards; and in females who have not often menstruated their surface is smooth and even; in after-life they become puckered and scarred by the repeated escape of the ova.

The position of the ovaries is described by Professor His as being nearly vertical, and he states that the Fallopian tube curves round the outer to the lower border of the ovary, so that the fimbriated extremity lies beneath the ovary, with its fimbriæ directed upwards; thus the ova on their escape from the ovary fall into the Fallopian tube.*

The ovary is about an inch and a half (3.8 cm.) long, three-quarters of an inch (18 mm.) wide, and about half an inch (13 mm.) thick; its weight being from one to two drachms (4 to 8 gm.). It consists of a dense soft stroma, imbedded in which are numerous small vesicles (*Graafian vesicles*), muscular tissue, blood-vessels, and nerves, the organ being invested by a serous covering.

The *serous layer* covers the ovary, but does not present the ordinary features of a peritoneal investment, for the covering is dull and not shining, and the epithelium consists of a single layer of columnar cells which are the remains of the germ epithelium, from

* His, "Lage der Eierstöcke," *Archiv. f. Anat.*, 1881.

which the ova and the other cells in the Graafian vesicles have been originally developed.*

The *stroma* composes the substance of the ovary, and consists of some connective tissue associated with a large amount of spindle-shaped cells, resembling in their appearance unstriped muscle-cells. It contains also elastic tissue, and is abundantly supplied with blood-vessels, which are larger at the hilum of the ovary, diminishing in size towards its surface. The outer part of the stroma is much condensed, so as to give a white appearance to the organ; this has been described as a proper fibrous coat, the *tunica albuginea ovarii*, but which does not actually exist as a separate layer.

If a section be made through the ovary, you will find that imbedded in the stroma are a large number of small transparent vesicles, which are more abundant at the circumference of the ovary, while in the central part there are comparatively few, it being composed almost entirely of the stroma.

The transparent vesicles just alluded to are the *Graafian follicles*, or the ovisacs, which contain the ova.† In the outer part or cortical layer of the stroma of the ovary may be observed a large number of closely set minute vesicles, about $\frac{1}{100}$ th of an inch (0.2 mm.) in diameter, more numerous in the ovaries of young children and in some animals. In the central part or medullary portion of the stroma are seen larger and less numerous vesicles, the largest being placed most deeply; but these, as they become mature, gradually make their way towards the surface, probably by absorption, and when fully developed measure from $\frac{1}{20}$ th to $\frac{1}{8}$ th of an inch (1 to 4 mm.) in diameter. One, or perhaps more than one, Graafian vesicle ruptures at each menstrual period, and the little ovum it contains escapes from the vesicle, and is either grasped by, or falls into the fimbriated end of the Fallopian tube, and is thus conveyed into the uterus. The ruptured vesicle from which the ovum has escaped becomes filled with blood, and subsequently also with an exudation from its walls, so as to constitute a reddish-yellow substance, called the *corpus luteum*, which persists for a while and then degenerates into a small stellate fibrous cicatrix.

The Graafian vesicles are very numerous, especially in the young subject, the smaller ones being the most numerous, their average diameter being about $\frac{1}{100}$ th of an inch (0.2 mm).‡ Ex-

* Waldeyer, *Eierstock u. Ei*, Leipzig, 1870; and in Stricker's *Handbuch*, 1871.

† So called after De Graaf, a Dutch anatomist, who discovered them in 1672, and believed they were the true ova.

‡ It has been computed that in the ovaries of a child at birth there are no less than 70,000 Graafian follicles.

ternal to the larger vesicles there can be distinguished a *membrana propria* or basement membrane; internal to this, the stroma becomes altered so as to constitute a distinct wall to the follicle. Within this, and lining the wall of the vesicle, there is a layer of nucleated cells, called the *membrana granulosa*, which surrounds a transparent albuminous fluid in which the *ovum* or *germ* is contained. The vesicle, as it approaches the surface of the ovary, develops an additional layer of granular cells, called the *discus proligerus*, within which the ovum is imbedded, lying usually towards the free surface of the ovary.

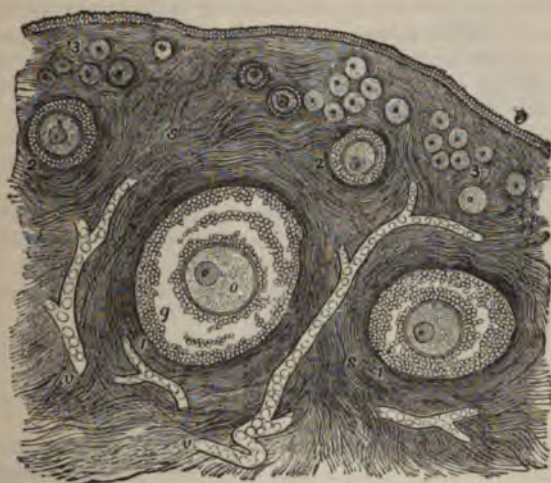

FIG. 193.—SECTION OF AN OVARY.

e. Germ epithelium. 1. Large-sized follicles. 2, 2. Middle-sized, and 3, 3, smaller-sized follicles. *o.* Ovum within a Graafian follicle. *v, v.* Blood-vessels of the stroma. *g.* Cells of the membrana granulosa.

The ramifications of the *ovarian artery* through the ovary are remarkable for their convolutions; they run in parallel lines, as in the testicle. Its *nerves* are derived from the ovarian plexus, which comes from the renal. The *ovarian veins* form, like the spermatic veins, near the ovary, the pampiniform plexus, and then terminate, the right in the inferior vena cava, the left in the renal vein.

Parovarium.

The *parovarium*, or the *organ of Rosenmüller*, is the remains of a foetal structure situated in the broad ligament, between the Fallopian tube and the ovary. It consists of a series of convoluted closed tubules, lined with epithelium, converging from beneath the Fallopian tube to the ovary. At their ovarian end the tubules are separate, but at their broader

end they are joined by a longitudinal tube running parallel to the lower border of the Fallopian tube. It is the vestige of a foetal structure, and is the analogue of the epididymis in the male, and is connected at its uterine end with the remains of the Wolffian duct.

DISSECTION OF THE ABDOMINAL VISCERA.

The liver is the largest glandular organ in the body, and in the adult weighs from fifty to sixty ounces (1550 to 1860 gm.). It serves for the secretion of the bile, and, moreover, alters some of the constituents of the blood in its passage through the organ. Its diameter in the transverse direction is from ten to twelve inches (25 to 30 cm.); from before backwards it measures from six to seven inches (15 to 17.5 cm.), and its greatest thickness, which is at its back, is about three inches (7.5 cm.).

Its surface is entirely covered with peritoneum, except a small part behind, which is connected to the diaphragm and the upper part of the right kidney by cellular tissue, and again in the hollow which lodges the gall-bladder.

The *upper surface* is smooth and convex in adaptation to the diaphragm, and is marked by a fold of peritoneum running from behind forwards, dividing this surface into two unequal lobes, a right and a left, the right being the larger. The fold of peritoneum is the *suspensory* or *broad ligament*.

The *under surface* is concave and irregular, and is divided into a right and left lobe by the longitudinal fissure.

The *posterior border* is thick and round, having attached to it the *coronary ligament*.

The *anterior border* is thin and sharp, and presents a notch indicating the division into a right and left lobe; the notch lodges the round ligament, which is the remains of a foetal structure, the umbilical vein. There is also to the right side of the notch a slight groove corresponding to the base of the gall-bladder.

The *right border* is thick and round, the *left* is flat and thin.

Fissures. The under surface is irregular, and is marked by five fissures which map out the five lobes (Fig. 194). They are the longitudinal fissure, the fissure for the ductus venosus, the fissure for the gall-bladder, the fissure for the inferior vena cava, and the transverse fissure. The relative position of these fissures (the liver being *in situ*) may be best impressed on the memory by comparing them collectively to the letter H. The transverse fissure represents the cross-bar of the letter; the longitudinal fissure and the fissure for the ductus venosus represent the left bar; the fissures for the gall-bladder and the vena cava make the right bar.

The *longitudinal fissure* divides the right from the left lobe, and contains the round ligament, which is the remains of the umbilical vein in the foetus. It is deeper in front than behind, and is not infrequently bridged over by liver tissue, constituting the *pons hepatis*.

The *fissure for the ductus venosus* is the continuation backwards of the longitudinal fissure to the posterior border of the liver, and contains a fibrous cord, which is the obliterated remains of what was in the foetus the ductus venosus.

The *fissure for the gall-bladder* is a shallow depression to the right of the longitudinal fissure, and lodges the gall-bladder.

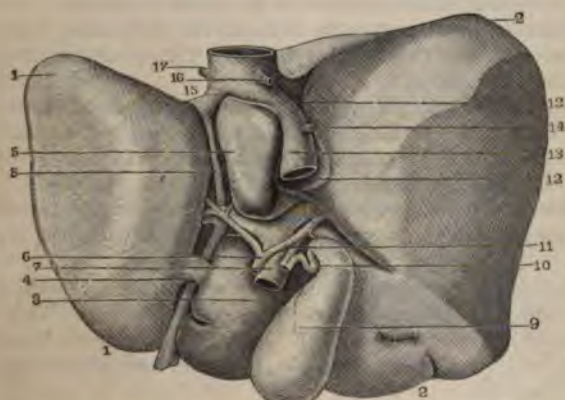


FIG. 194.—UNDER SURFACE OF THE LIVER.

1. Left lobe. 2. Right lobe. 3. Lobulus quadratus. 4. Pons hepatis. 5. Lobulus spigelii.
6. Hepatic artery. 7. Portal vein. 8. Obliterated ductus venosus. 9. Gall-bladder. 10.
Cystic duct. 11. Hepatic duct. 12, 12. Fissure for the vena cava. 13. Inferior vena cava.
14. Vein to the capsule of the liver. 15. Left hepatic vein. 16. Right diaphragmatic vein.
17. Left diaphragmatic vein.

The *fissure for the inferior vena cava* runs obliquely backwards and joins at an acute angle the fissure for the ductus venosus at the posterior border of the liver. It begins close to the right extremity of the transverse fissure, and is not uncommonly surrounded by hepatic tissue.

The *transverse* or *portal fissure*, about two inches (5 cm.) in length, unites the other fissures, and transmits the large vessels which enter the liver in the following order: in front is the hepatic duct, behind is the vena portæ, and between them the hepatic artery.

The lobes of the liver, five in number, are also seen on its under surface.

Hepatic Artery in front.

Lobes. The *right lobe*, much larger than the left, is separated from it by the longitudinal fissure on its under aspect, and by the falciform ligament on its upper surface. Its superior surface is smooth and convex, somewhat quadrilateral in shape; on the under surface it is marked by three fissures—the transverse, and those for the gall-bladder and vena cava. It has also on its under surface two shallow fossæ: the anterior (*impressio colica*) is for the hepatic flexure of the colon; the posterior (*impressio renalis*) for the right kidney and the supra-renal capsule.

The *left lobe* is the smaller; its upper surface is smooth and convex, its lower is concave and rests on the stomach.

The remaining lobes may be considered as forming parts of the right lobe, and are the lobulus Spigelii, the lobulus caudatus, and the lobulus quadratus.

The *lobulus Spigelii* is a prominent quadrilateral lobe, placed between the transverse fissure and the fissures for the ductus venosus and vena cava; behind the transverse fissure it is connected to the right by a ridge, the lobulus caudatus.

The *lobulus caudatus*, which passes obliquely forwards and to the right, separating the fissure for the vena cava from the transverse fissure.

The *lobulus quadratus* is a square lobe situated between the gall-bladder, the longitudinal and the transverse fissures. This lobe is occasionally connected to the left lobe by a bridge of hepatic substance arching over the longitudinal fissure, and alluded to before as the pons hepatis.

Ligaments.

The liver has five ligaments, of which the *coronary*, the *right* and *left lateral*, and the *falciform* are reflections of the peritoneum; the fifth is the *round ligament*, placed in the anterior free border of the falciform ligament in the longitudinal fissure; it consists of the remains of the umbilical vein of the fœtus. The ligaments have been already described (p. 426).

Vessels.

The vessels which pass to and from the liver are five also in number: the hepatic artery, the vena portæ, the hepatic veins, the hepatic duct, and the lymphatics. The consideration of these is deferred till we have examined the capsule of the liver.

The *fibrous coat* surrounds the liver, and is best seen on those parts of it not covered with peritoneum. This coat is connected on the surface of the gland to the areolar tissue which surrounds the lobules, but does not send down partitions to form a framework for the interior. It is continuous, at the transverse fissure, with the sheath of loose areolar tissue, called *Glisson's capsule*, which sur-

rounds the vessels as they enter that fissure, and encloses them in a common sheath in their ramifications through the liver.

The interlobular connective tissue is exceedingly delicate; hence the great liability of the liver to be lacerated by external violence, and consequent hæmorrhage into the peritoneal cavity.

Lobules.

The liver consists of an aggregation of small polyhedral masses, called *lobules*, about the size of a millet seed, which range from $\frac{1}{4}$ th to $\frac{1}{2}$ th of an inch (1 to 2 mm.) in diameter. These lobules are more or less distinctly marked out by septa of areolar tissue, and in a transverse section have the appearance of mosaic pavement (Fig. 195); but in a perpendicular section they somewhat resemble an oak leaf (Fig. 196). Each lobule is mapped out by, and separated from, the adjacent lobules by delicate connective tissue, in which runs a plexus of vessels—*interlobular plexus*—consisting of branches of the portal vein. From this plexus passes inwards into the lobule a fine capillary network, whose branches converge to the centre of the lobule and end in a single vein, the *intralobular vein*, which, in its turn, opens into the *sublobular vein*, and thence into the *hepatic vein*. With the interlobular plexus run the biliary ducts. The lobules themselves consist of a minute plexus of blood-vessels, ducts, and cells—*hepatic cells*—which latter fill up the spaces between the ramifications of the vessels. It will facilitate the understanding of the different hepatic vessels, if it be borne in mind, (1) that the portal vein, hepatic artery, and hepatic duct ramify together from first to last, enclosed in a common sheath of connective tissue, called *Glisson's capsule*; (2) that the hepatic veins run alone from first to last, and terminate in the inferior vena cava as it passes under the liver.

The *portal vein* enters the transverse fissure of the liver, accompanied by the entering hepatic artery and the emerging right and left hepatic ducts, which, as before stated, are surrounded in the liver by a common sheath called Glisson's capsule. In the liver the portal vein ramifies between the lobules and gives off numerous branches, called *interlobular* or peripheral veins, which

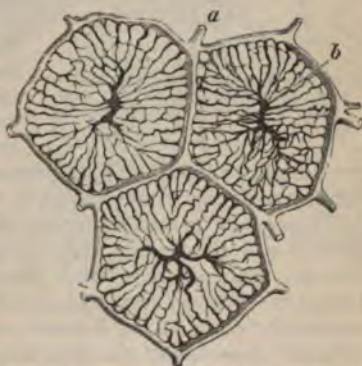

FIG. 195.—TRANSVERSE SECTIONS OF THREE LOBULES OF THE LIVER, MAGNIFIED TO SHOW THE PORTAL VENOUS PLEXUS. (After Kiernan.)

a. Interlobular vein. b. Intralobular or central vein.

pass between the lobules and communicate freely with each other. These receive the *vaginal* and *capsular veins* which convey the blood from the corresponding branches of the hepatic artery. The interlobular plexus of veins gives off a minute capillary network, which penetrates into the interior of the lobule, and converges towards the centre of the lobule to open directly into a single central vein called the *intralobular vein*. The capillaries which compose this network run in a nearly parallel direction from the circumference to the centre of the lobule, and communicate freely with each other by small transverse branches. The intervals between the branches of the capillary network is very small, varying from $\frac{1}{1000}$ th to $\frac{1}{400}$ th of an inch, while the vessels themselves are comparatively large,

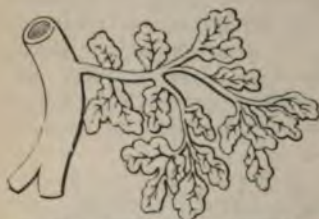


FIG. 196. LONGITUDINAL SECTIONS OF THE LOBULES OF THE LIVER. Intralobular Veins seen Joining the Sublobular.

being about $\frac{1}{2500}$ th of an inch in diameter. The intralobular vein returns the blood from the centre of the lobule, and opens immediately into a *sublobular vein*, larger or smaller as the case may be, upon which the lobule is sessile (Fig. 196).

The sublobular veins, increasing in size, empty themselves into the smaller *hepatic veins*; these unite to form the main hepatic trunks, usually three in number, one each from the right and left lobes and

the lobulus Spigelii. These hepatic veins open into the inferior vena cava as this vessel passes to the posterior border of the liver.

The *hepatic artery*, entering the transverse fissure of the liver, divides and subdivides with the portal vein and biliary ducts, and ramifies with them between the lobules. The artery distributes branches—*vaginal branches*—whilst within the portal canals which supply the coats of the hepatic vessels and Glisson's capsule; also *capsular branches* to the fibrous coat of the liver, which appear on the surface of the liver in stellate plexuses; and *interlobular branches*, which accompany the corresponding veins and pass into the lobules to join the capillary network which leads to the radicles of the intralobular vein.

The interior of each lobule—that is, the space left between the several vessels—is filled by the *hepatic cells*. They are of spheroidal or polyhedral shape, with a diameter varying from $\frac{1}{1000}$ th to $\frac{1}{800}$ th of an inch, and have no cell-wall. They consist of a granular substance of a light yellow tinge, containing one or more distinct nuclei having a highly refracting nucleolus. In some cases the cells contain fat globules; when these accumulate in large quantities, they constitute what is called a fatty liver. The office of the

hepatic cells is to separate the bile from the blood, and when filled with bile, to discharge their contents into the biliary ducts.

The *biliary ducts* are the channels through which the bile is conveyed into the hepatic ducts. They commence as minute passages—*bile canaliculi*—which are formed between and around the hepatic

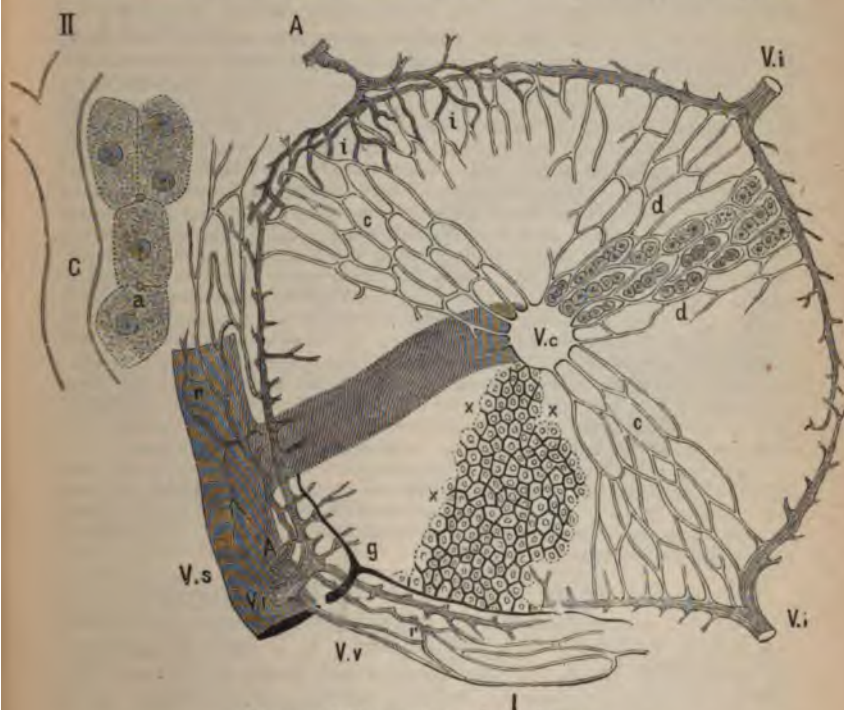


FIG. 197. I. DIAGRAM OF A LIVER LOBULE.

V.i, V.i. Interlobular vein (portal). V.c. Central or intralobular vein (hepatic). c.c. Capillaries between both. V.s. Sublobular vein. V.v. Vena vascularis. A.A. Hepatic artery, giving branch r,r, to Glisson's capsule and the larger vessels, and ultimately forming the venæ vasculares at i,i, opening into the intralobular capillaries. g. Bile ducts. x,x. Intralobular biliary channels between the liver cells. d,d. Position of the liver cells between the meshes of the blood capillaries.

II. ISOLATED LIVER CELLS.—C. Blood capillaries. a. Fine bile-capillary channel.

cells, and then pass outwards to the circumference of the lobule, where they open into the bile-ducts between the lobules.* Here

* The biliary ducts between the lobules are lined with a short columnar epithelium, resting on a basement membrane; but it is doubtful whether the bile-canaliculi are very minute ducts, or whether they are not simple intercellular passages between the hepatic cells.

they form a plexus—*interlobular*—which opens into ducts which run with the hepatic artery and portal vein in the portal canals; eventually these join with other ducts to form the right and left hepatic ducts, which leave the transverse fissure of the liver, and, after a course of about an inch, unite to form a single duct, the *common hepatic duct*.

The *lymphatics* of the liver are arranged in two sets: superficial and deep. The *superficial* may be divided into those on the upper convex surface and those on the under aspect; the lymphatics on the convex surface are: (1) those which run backwards between the layers of the falciform ligament and then pass through the diaphragm behind the ensiform cartilage to enter the anterior mediastinal glands, and thence to the right lymphatic duct; (2) those which pass forwards over its anterior margin to the under aspect to enter the glands in the gastro-hepatic omentum; (3) those which run to the right lateral ligament, and then either pierce the diaphragm to join the anterior mediastinal glands, or pass inwards to open into the thoracic duct at its commencement; and (4) those which run to the left lateral ligament, which, after piercing the diaphragm, open into the anterior mediastinal glands. The lymphatics on the under aspect are arranged as follows: (1) those on the right side of the gall-bladder open into the lumbar glands; (2) those surrounding the gall-bladder accompany the hepatic artery to join the glands in the gastro-hepatic omentum; (3) those on the left side enter the glands on the lesser curve of the stomach and the œsophagus. The *deep lymphatics* originate partly in the connective tissue between the lobules, and there accompany the hepatic artery and portal vein and duct to the transverse fissure, to join the lymphatic glands on the lesser curve of the stomach and behind the pancreas; some lymphatics also accompany the branches of the hepatic veins.

The *nerves* of the liver are derived from the pneumogastric, chiefly the left, and from the hepatic plexus which comes from the cœliac plexus. These plexuses enter the liver at the transverse fissure, surround the hepatic artery and the portal vein, and accompany these vessels in their ramifications through it. The ultimate termination of these nerves is not known.

The *functions* of the liver may be thus briefly expressed: 1. It renders the albuminous matter (albuminose), brought to it by the portal vein, capable of being assimilated. 2. It forms a substance, *glycogen*, easily converted into sugar, which passes into the hepatic veins, and, being consumed, helps to maintain animal heat. 3. It secretes the bile, which assists in converting the chyme into chyle, and reducing it into a state fit to be absorbed by the lacteals. 4. The bile acts as a natural aperient. 5. The bile is an antiseptic, and probably prevents the decomposition of the food during its passage through the intestine.

Gall-bladder. The gall-bladder, or reservoir for the bile, is pyriform in shape, and is confined in a slight depression on the under surface of the right lobe of the liver (p. 427). It is about four inches (10 cm.) long, an inch (2.5 cm.) in its broadest part, and is capable of holding about 1½ oz. (49.2 c.c.) of fluid. Its broadest part projects beyond the anterior margin of the liver, and it is maintained in its position by the peritoneum,

which usually is continued over it from the liver, but which may occasionally completely invest it, so as to form a kind of mesentery. It is divided into a fundus, a body and a neck. The *fundus* is its broadest part, and usually projects a little beyond the front border of the liver; from this it gradually narrows, forming the *body*; and this again still further contracts to form the *neck*, which makes a bend downwards, curving upon itself like the letter S. The neck terminates in a duct called the *cystic duct*, which, after a course of about an inch (2.5 cm.), joins the common hepatic duct at an acute angle. The common duct thus formed, called the *ductus communis choledochus*, is about three inches (7.5 cm.) long, and of the size of a crow-quill; it opens into the inner side of the back of the descending part of the duodenum, after running very obliquely through the coats of the bowel.

The gall-bladder consists of two coats, and of a partial peritoneal covering which only completely surrounds the fundus.

The *middle coat* consists of strong connective tissue, whose fibres interlace in all directions, and in which involuntary muscular fibres can be traced, running mainly in the long axis of the gall-bladder.

The *mucous coat* can only be seen when the gall-bladder has been opened, which should now be done by laying it open from the fundus to the neck. It is loosely connected to the middle coat, and it is gathered into ridges, which give it a honeycombed appearance, more or less tinged yellowish-brown by the bile. This appearance is most marked in the middle of the gall-bladder, where the surface is covered with polygonal ridges enclosing depressions, in which may be seen with a lens numerous openings leading down to mucous follicles. It is covered with columnar epithelium, which secretes an abundance of viscid mucus. At the bend of the neck of the gall-bladder both its coats project very much into the interior, making the opening considerably narrower than it appears to be outside. In the cystic duct the mucous membrane presents a series of folds, so arranged one after the other as to form a complete spiral valve. The probable use of this



FIG. 198.—DIAGRAM OF A TRANSVERSE SECTION THROUGH THE LOWER PART OF THE ABDOMINAL CAVITY.

G.O. The great omentum with its cavity. I. Small intestine. A. Aorta. V. Inferior vena cava. A.C. Ascending colon. D.C. Descending colon. K. Kidneys.

is to prevent the too rapid flow of the bile. The gall-bladder appears to serve mainly as a reservoir for the bile while digestion is not going on. The bile becomes during its sojourn in the gall-bladder very viscid and intensely bitter.

The gall-bladder is supplied with blood from the cystic branch of the right hepatic artery; its blood is returned by the cystic vein, which opens into the vena portæ; its nerves are derived from the celiac plexus, which accompany the hepatic artery.

Pancreas.

The *pancreas* is a large gland belonging to the acino-tubular class. It is placed transversely across the posterior wall of the abdomen in the epigastric and left hypochondriac regions on the body of the first lumbar vertebra, and measures from six to eight inches (15 to 20 cm.) in length, about an

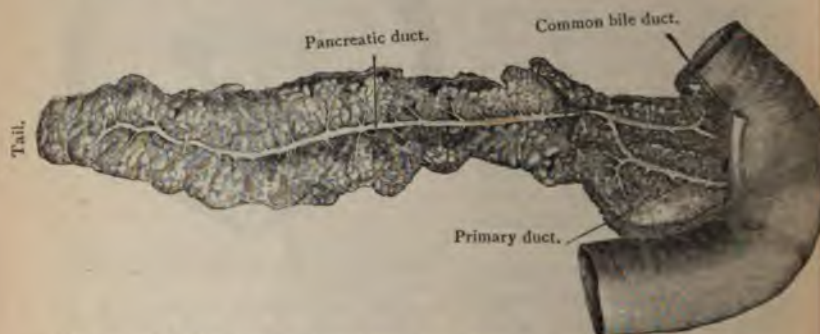


FIG. 199.—PANCREAS AND DUODENUM SEEN FROM BEHIND. THE GLAND IS CUT TO SHOW THE DUCT.

inch and a half (3.8 cm.) in breadth, and from half an inch to an inch (13 mm. to 2.5 cm.) in thickness, its weight being usually from two to three and a half ounces (62 to 108 gm.).*

It presents for examination a head, a body, and a tail.

The *head*, situated to the right side, is turned down, and is embraced by the descending and transverse portions of the duodenum, the superior and inferior pancreatico-duodenal arteries running between them. A considerable prolongation usually extends upwards from the posterior part of the gland, and reaches the lesser curve of the stomach; this constitutes sometimes a separate mass, and is then termed the *lesser pancreas*.

The *tail* is the narrow end of the pancreas, which extends to the left as far as the hilum of the spleen.

* It is of a soft structure and a pinkish-cream colour. (A. H.)

The *body* is convex in front, and is covered by the ascending layer of the transverse meso-colon.

The pancreas has a *posterior surface* which is concave, and lies on the vena cava, the aorta, the crura of the diaphragm, the superior mesenteric artery and vein, the commencement of the vena portæ, and the inferior mesenteric vein; an *upper border* which is thick, and is in relation with the splenic artery and vein, the celiac axis, the hepatic artery, and the first portion of the duodenum; and a *lower border* which is thin, and is in relation with the superior mesenteric artery and vein, and on its left with the inferior mesenteric vein.

The *duct of the pancreas*, called also the *duct of Wirsung*, passes from left to right in the pancreas, nearer its lower than its upper border, and nearer its anterior than its posterior surface. Commencing at the tail by the junction of the smaller ducts, it receives in its course to the right side, repeatedly, other ducts, and thus gradually increases in size until it reaches the head, where it usually receives a large branch from the lesser pancreas; the large duct then curves downwards, and comes into relation with the common bile duct; it then passes very obliquely through the coats of the descending duodenum on its posterior aspect, and then either opens separately, or in conjunction with the common bile duct, into this portion of the intestine.

The *structure* of the pancreas resembles in most of its characters that of the salivary glands. The alveoli are tubular, frequently convoluted, and are lined by columnar epithelium, which leaves only a narrow lumen, which is often occupied by spindle-shaped cells called the *centro-acinar cells*.* The ducts are very constricted at their commencement from the alveolus, and are lined by short columnar epithelial cells, which become larger towards the termination of the duct.

The *arteries* of the pancreas are derived from the splenic, the superior and inferior pancreatico-duodenal branches, respectively, of the hepatic and the superior mesenteric arteries. The veins open into the splenic and superior mesenteric veins. The *lymphatics* end in the lumbar glands; its *nerves* are derived from the solar plexus.

The *uses* of the pancreatic fluid are: to convert the starchy matters into dextrine and grape sugar; to emulsify (in conjunction with the bile) the fatty particles, and, by its alkaline salts, partly saponify the fatty acids, thus enabling them to be taken up by the lacteals, and, lastly, to convert into peptones the albuminous and gelatinous substances of food. It is an alkaline fluid, very similar

* The other ductless glands are the thyroid, thymus, and supra-renal capsules.

to that secreted in the salivary glands, but contains no sulphocyanogen.

Spleen. The *spleen* is a very vascular sponge-like organ, and belongs to the class of ductless glands.

It varies in size according to the amount of blood in it, fluctuating in weight, consistently with health, between five and ten ounces.* It is of a reddish-blue colour, is more or less elliptical in shape, and in its natural position is placed with its long axis nearly vertical. It is about five inches (12.5 cm.) in length, three to four inches (7.5 to 10 cm.) in breadth, and from one to one and a half inches (2.5 to 3.8 cm.) in thickness; in volume it varies from $9\frac{3}{4}$ to 15 cubic inches (or 159.25 c. cm. to 245 c. cm.) Its *outer surface* is smooth and convex, and corresponds to the ninth, tenth, and eleventh ribs on the left side, being in relation with the under aspect of the diaphragm; its *inner surface* is concave, and is adapted to the cardiac end of the stomach; this surface is divided into a larger anterior and a smaller posterior portion by a vertical fissure—the *hilum*—at the bottom of which are large openings, through which the vessels enter and emerge from the spleen. The borders are: an *upper*, thick and rounded; a *lower*, pointed; a *posterior*, rounded; and an *anterior*, also rounded, and often notched.

As already mentioned, the spleen is connected to the stomach by the *gastro-splenic omentum*, and to the under aspect of the diaphragm by the *suspensory ligament*.

The spleen is invested with two coats—a serous or peritoneal, and a fibro elastic. The *outer* or *serous coat* entirely covers the organ, except at the hilum, from which it is reflected to the stomach; it is thin and smooth, and is intimately connected to the subjacent fibrous coat. Its *fibro elastic coat* (*tunica propria*), thick and strong, not only covers the spleen, but sends inwards throughout its substance fibrous bands (*trabeculae*), which interlace in all directions, and thus form an intricate network of what are termed *trabecular spaces* or *areolae*; this coat consists of a strong, white, and elastic tissue, and is consequently exceedingly elastic to admit of the varying size of the spleen; it moreover contains more or less unstriped muscular fibres, so that it contracts faintly on the application of the galvanic current. Besides this, the trabeculae form sheaths and supports for the splenic vessels throughout their ramifications.

The areolae, above described, are filled with what is termed the

* In ague and other forms of fever it sometimes attains a weight of from 18 to 20 pounds (8.1 to 9 kilograms); it diminishes in weight after forty years of age, and is enlarged during and after digestion.

spleen pulp. This pulp is a soft reddish-brown substance, and under the microscope is seen to consist of connective-tissue corpuscles, which with their branched communicating processes, called the *sustentacular cells of the pulp*, make up a fine reticular tissue, the interstices of which are filled with red and white blood-corpuscles. Thus the areolæ are divided into a large number of smaller spaces by these sustentacular cells, and the white blood-cells contained within them are more numerous than in normal blood, especially in the neighbourhood of the Malpighian corpuscles. The cells have either one or more nuclei according to their size, and present distinct amœboid movements. In these cells frequently small yellowish granules may be distinguished, which are probably derived from blood-cells, for they present all the characters of hæmatin. Blood-corpuscles in all stages, from an unchanged disc to one of complete disintegration, may be seen; and it has been shown by Klein that some of them present knob-like projections, as if from budding of small nuclei by a process of gemmation.

The *splenic artery* enters the hilum of the spleen by several branches which ramify in its substance, ensheathed and supported by its fibrous framework.* The artery is remarkable for its large size, as compared with the organ to which it is distributed, and also for its serpentine course. The smaller branches leave the trabeculæ, still invested by a sheath derived from the fibro-elastic coat of the spleen; but, before they terminate in penicillate tufts the sheath becomes changed into a thick investment of lymphoid tissue, which surrounds the smallest arterioles. The lymphoid tissue, which forms the sheath of the arterioles, is here and there dilated into oval enlargements, called the *Malpighian corpuscles*, varying in size from $\frac{1}{70}$ th to $\frac{1}{25}$ th of an inch (.3 to 1 mm.) in diameter. These bodies are sometimes thickenings on the side of the arterioles, but more commonly they completely surround the vessels. They are visible in a fresh spleen, and look like white spots scattered through the dark pulp. There do not appear to be any definite boundaries between them and the reticular tissue; their interior consists of a fine reticulum, denser at the circumference than at the centre, and is filled with lymphoid cells possessing amœboid movements. The smaller arteries, after branching in all directions, enter the spleen pulp, and their lymphoid walls alter in character, presenting numerous branched processes which communicate with the branched cells of the sustentacular tissue. Through this connection they pour their blood directly into the pulp tissue, and thus into relation with the constituents of the pulp tissue, by which means it is subjected to

* The ramifications of the splenic artery may be seen by washing away the pulp and floating the flocculent-looking spleen in water.

important changes. The *veins* commence in the pulp tissue in the same way as the arteries, and are at first formed by the arrangement into rows of the connective-tissue corpuscles, which subsequently become spindle-shaped and overlap each other, so constituting a variety of endothelial lining to the venous passages. Assuming more the ordinary character of veins, they travel along the trabeculæ like the arteries, but do not accompany them, and freely communicate with each other, and so far are unlike the arteries. The small veins present transverse lines or markings, caused by the encircling elastic fibres around the vessels of the sustentacular tissue of the spleen. After entering the trabecular tissue, which forms sheaths for the veins, they gradually join and form four to six large veins, which leave the hilum to constitute the splenic vein.

The *lymphatics* of the spleen are arranged in two sets—a *trabecular* and a *perivascular*: the former originate in the trabeculæ, and are connected with the lymphatics beneath the capsule; the latter arise in the lymphoid tissue around the arteries, and subsequently run one on each side of the arteries, anastomosing frequently by transverse branches. The trabecular and perivascular lymphatics join at the hilum, and run between the layers of the gastro-splenic omentum to the lymphatic glands.

The *nerves* come from the solar plexus and the right pneumogastric nerve.

The function of the spleen appears to be that of a great blood-gland, and thus concerned in the development of white corpuscles; for the blood which is conveyed from the spleen contains a large excess of white corpuscles. The large number of red blood-corpuscles, in various stages of disintegration, also points to another use of the spleen as the gland for the degeneration of red blood-cells into pigment, which is conveyed through the spleen to the liver to be used in the secretion of the bile. It is also presumed that the gland elaborates the albuminous materials of food, and stores them up for a time before they pass into the circulation.

Kidneys. The kidneys, two in number, are situated in the lumbar region, behind the peritoneum, imbedded in fat. The left, usually situated higher than the right, is generally longer and somewhat heavier. Their colour is reddish-brown. Each is about 4.4 inches (11 cm.) in length, two inches (.5 cm.) in breadth, and one inch (2.5 cm.) in thickness. Each weighs from four to six ounces (113.5 to 170 gm.) in the male, and in the female, four to five and a half ounces (113.5 to 156 gm.).

The kidney presents for examination two surfaces, two borders, and an upper and a lower end.

The *anterior surface* is convex, and is covered with peritoneum, and looks somewhat outwards; the *posterior surface* is rather flattened, and rests on the anterior layer of the lumbar aponeurosis and psoas magnus; the *outer border* is convex and rounded; the

inner border presents, about its middle, a deep notch about an inch (2.5 cm.) in length, the *hilum*, leading to a hollow in the kidney, the *sinus*, for the entrance and exit of the renal vessels and ureter, the nerves and lymphatics; these have the following relations to one another: in front lies the renal vein; behind is the ureter; between them is the renal artery; the *upper end* is large and thick, and looks upwards and inwards, and upon it rests its corresponding supra-renal capsule; the *lower end*, smaller and flatter than the upper end, looks downwards and outwards.

The kidney is surrounded by a thin *fibrous capsule* of thick connective tissue, to which it is loosely connected by areolar tissue and minute vessels, except at the hilum; here it is reflected inwards and becomes continuous with the walls of the renal vessels and ureter. The capsule can be readily stripped off when healthy, leaving the surface perfectly smooth.*

A longitudinal section should be made through the kidney, from the outer to the inner border, to demonstrate the interior. This section displays two distinct parts—an *outer or cortical portion*, and an *inner or medullary portion*.

The *cortical structure* is deeper in colour than the medullary portion, and is soft and easily lacerated. It forms the external portion of the kidney to the extent of $\frac{1}{3}$ to $\frac{1}{2}$ of an inch (5 to 6 mm.), arching over the bases of the pyramids. It moreover sends down prolongations between the pyramids as far as the sinus, forming the *septula renum* or the *columns of Bertini*. The cortical substance consists of convoluted and straight tubes, *tubuli uriniferi*, of little reddish granules called *Malpighian bodies*, and of blood-vessels, nerves and lymphatics (Fig. 200).

The *medullary structure* is composed of numerous conical masses, the *pyramids of Malpighi*, having their bases directed to the surface, their sides in relation with the columns of Bertini, and their apices, termed *papillæ* or *mammillæ*, projecting into one of the calices of the ureter. The pyramids, of which there are from eight to sixteen, are surrounded by the cortical substance; they are composed of minute straight tubules (which proceed from the cortical portion to end in the papillæ), of looped tubes described by Henle, and of arteries and veins.†

At the hilum is the dilated commencement of the ureter, called

* Under the capsule there have been traced unstriped muscular fibres forming an incomplete layer.

† Each pyramid represents what was, in the early stage of the kidney's growth, a distinct and independent lobe. In the human subject the lobes gradually coalesce, and no trace of their primordial state remains, except the pyramidal arrangement of the tubes. But in the kidneys of the lower mammalia, of birds and reptiles, the lobes are permanently separate.

the *pelvis of the kidney*. It is funnel-shaped, and its broad part divides into three principal channels, *infundibula*, an upper, middle, and lower, which again branch, and form from eight to twelve cup-like excavations, called *calices*. Into each of these calices one, sometimes two or more papillæ project. Between the calices the

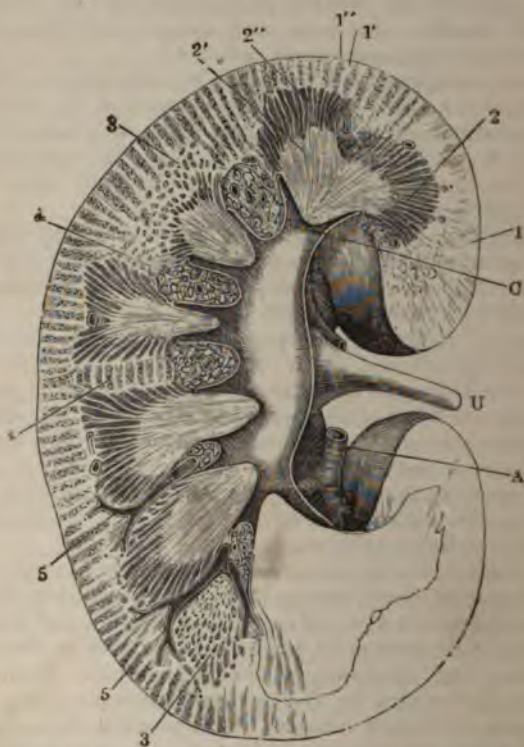


FIG. 200.—LONGITUDINAL SECTION OF THE KIDNEY (Tyson, after Henle).

1. Cortex. 1''. Labyrinth. 1'. Medullary rays. 2. Medulla. 2'. Papillary portion of medulla. 3. Transverse section of tubules in boundary layer. 4. Fat of renal sinus. *. Transversely coursing medullary rays. 5. Artery. 5. Artery. C. Renal calyx. U. Ureter. A. Branch of Renal artery.

branches of the renal artery ascend to ramify in the kidney, lying imbedded in fat. The pelvis and the calices are composed of three layers—an *external fibrous layer* continuous with the reflected part of the capsule into the sinus; a *middle or muscular*, consisting of

longitudinal and circular fibres, the former extending nearly as far as the calices, the latter encircling the calyx round the papillæ; and an *internal* or *mucous coat* reflected over the papillæ.

Structure of the Kidney. With a lens each papilla may be seen to be studded with 24 to 80 apertures, which are the terminations of the *tubuli uriniferi*. These apertures open into the bottom of about twenty shallow depressions on a papilla, called *foveolæ*. The orifices are from $\frac{1}{160}$ th to $\frac{1}{125}$ th of an inch (200 to 300 μ^*) in diameter. These tubes as they pass out into the pyramidal structure run straight, bifurcate repeatedly at very acute angles, their subdivisions running parallel, and reach the bases and sides of the pyramids, from which they pass into the cortical substance, greatly increased in number. These, termed the *straight* or *collecting tubes* (Fig. 202.0) pass into the cortical substance still as straight tubes, the central ones passing nearly to the surface, the outer ones being very short, and only run a short distance into the cortex, so that they are arranged as a series of cones, with their apices to the surface of the organ. These bundles are called the *pyramids of Ferrein*, or the *medullary rays*, and receive on each side the curved extremities of the convoluted tubes. We find the cortical substance is arranged between and around these medullary rays, which, from the intricate arrangement of its tubes, receives the name of the *labyrinth of the cortex*.

Each uriniferous tubule commences in a dilated extremity, termed the *Malpighian capsule* (300 μ) (Fig. 201.1), in which is enclosed an arterial, vascular tuft, the *Malpighian tuft*, of about $\frac{1}{30}$ th of an inch in diameter, and is visible to the naked eye as a minute red point. At the point of union of the tubule with the capsule it presents a narrow portion, called the *neck* (2), beyond which the tubule becomes convoluted for a considerable distance, forming the *first* or *proximal convoluted tube* (3). As it descends toward the medullary ray, the tubule becomes nearly straight, but having a slight spiral tendency: this portion of the tube is termed the *spiral tubule* (4) (Schachowa). The tubule now enters the medullary portion, narrowing very suddenly in its calibre, and descends towards the apex of the pyramid, constituting the *descending limb of Henle's loop* (5). The tubule here bends upon itself, forming a loop, the *loop of Henle* (6), and ascends to re-enter the cortical substance as the *ascending limb of Henle's loop* (7), which is larger than the descending limb. On passing out of the medullary ray of the cortical portion the tubule becomes irregularly dilated, and takes the name of the *irregular tubule* (8,9); this is continued on into another convoluted portion, called the *second, irregular or distal convoluted tubule*

* μ , micromillimeter.

(10, 11) which, before entering the straight tube, becomes much narrowed and curved, called the *primitive collecting* or *junctional tubule*. We have thus traced the straight tubes from their termina-

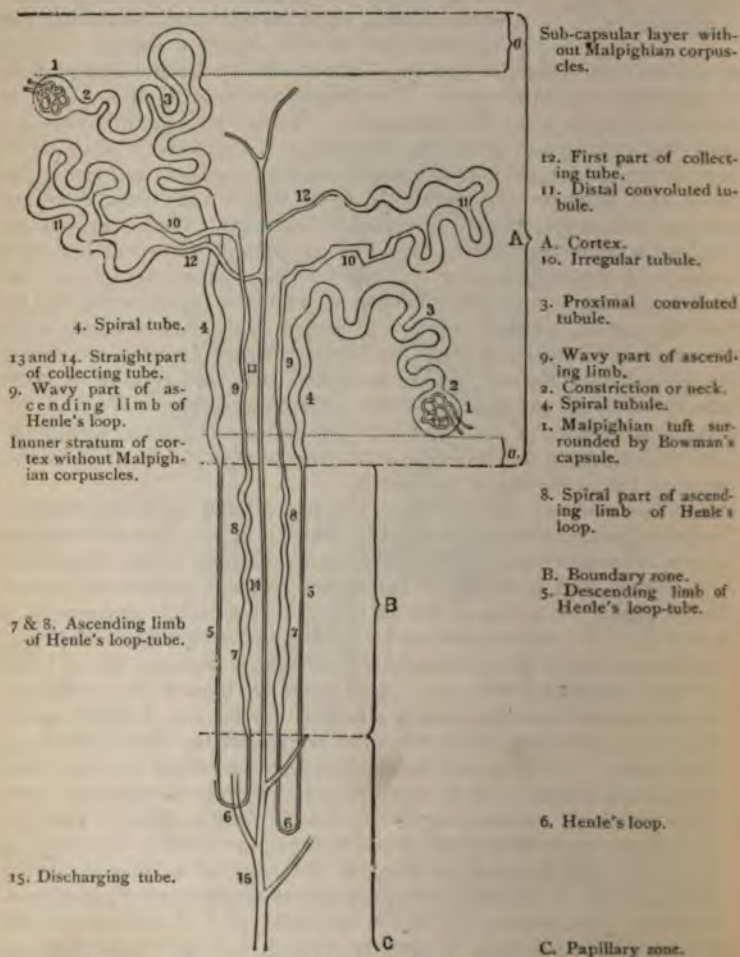


FIG. 201.—DIAGRAM OF THE COURSE OF TWO URINIFEROUS TUBULES.

tion at the papillæ to their commencement at the pyramids of Ferrein, and have also traced the convoluted tubules from their origin

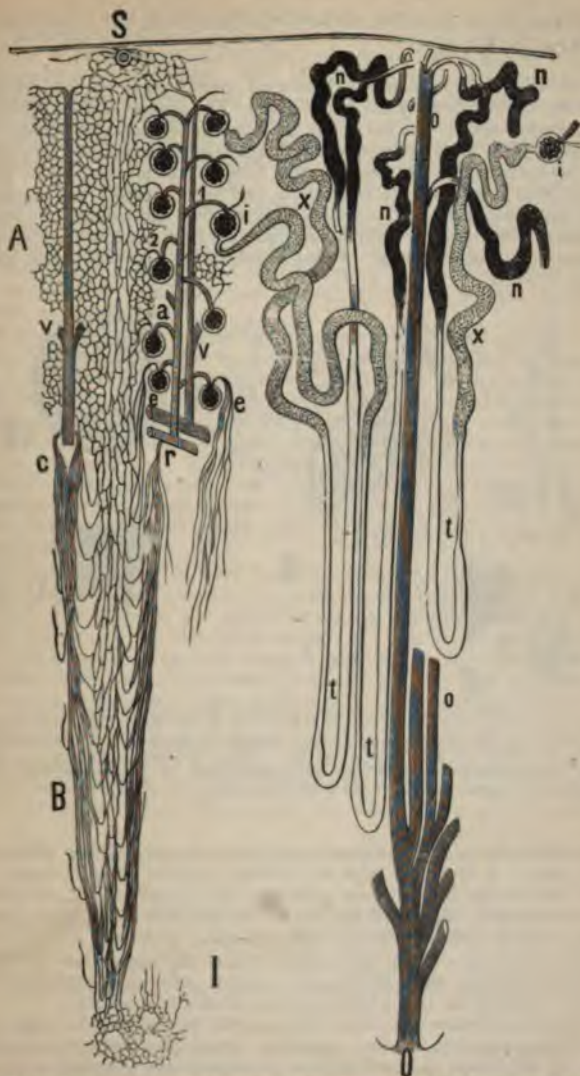


FIG. 202.—BLOOD-VESSELS AND URINIFEROUS TUBULES OF THE KIDNEY (SEMI-DIAGRAMMATIC).

A. Capillaries of the cortex. B. Of the medulla. *a*. Interlobular artery. *i*. Vas afferens. *s*. Vas efferens. *r, z*. Vasa recta. *z*. Vena recta. *p, v*. Interlobular vein. *S*. Origin of a vena stellata, cortical vein. *i, i*. Bowman's capsule and glomerulus. *X, X*. Convoluted tubules. *t, t*. Henle's loop. *n, n*. Junctional piece. *o, o*. Collecting tubes. *O*. Excretory tube.

in the Malpighian capsules to their junction with the commencement of the straight tubes.

The tubuli uriniferi consist of a basement membrane lined with epithelium, which varies in the different parts of the tubuli. The *capsule* is lined with flattened cells, having oval nuclei; the *neck* (Fig. 203, 11.) has cubical epithelium; the *first convoluted tubule* is lined with polyhedral epithelium, presenting numerous rod-like processes, resting at one end on the basement membrane, while the other extends towards the lumen of the tubule, and thus presents the appearance of striation; the *spiral tube* of Schachowia has similar epithelium; the *descending limb* is lined with flattened epithelium, like that in the capsule; the *ascending limb* presents epithelium similar to that found in the first convoluted and spiral

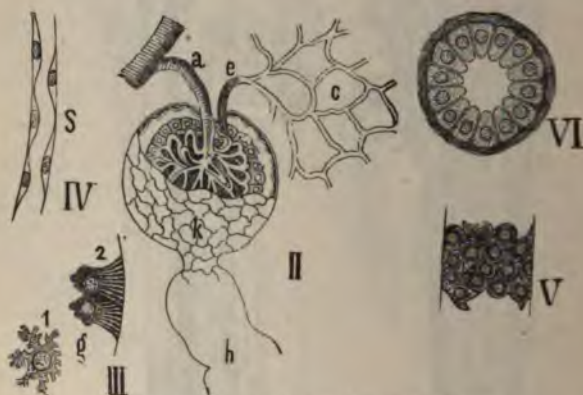


FIG. 203.—II. BOWMAN'S CAPSULE AND GLOMERULUS.

a. Vas afferens. e. Vas efferens. c. Capillary network of the cortex. k. Endothelium of the capsule. h. Origin of a convoluted tubule. III. "Roddeed" cells from a convoluted tubule—2, seen from the side, with g, inner granular zone. 1. From the surface. IV. Cells lining Henle's looped tubule. V. Cells of a collecting tube. VI. Section of an excretory tube.

portion of the tubule, although smaller and with shorter rod-like processes; the *irregular tubule* is furnished with the rod-like cells of unequal length, which, however, render the lumen more uniform; the *second convoluted tubule* has epithelium somewhat like that of the first convoluted tubule, but having long cells with large nuclei, and possessing high refractive properties; the *curved or junctional tubule* has a large lumen, and is lined by angular or fusiform cells with short processes; the *collecting or straight tubes* are lined with cubical epithelium, which in the larger tubes becomes distinctly columnar.

The *renal artery* enters the hilum between the pelvis and the renal vein. It shortly divides into four or five branches, which pass outwards between the papillæ, and then enter the cortical portion between the pyramids. From these there pass to each Malpighian pyramid two branches, which ascend along its sides as far as its base, distributing in their course small vessels which pass to the Malpighian capsules. At the base of the pyramid they form arches, and make a bend from which two sets of branches are given off, the interlobular arteries and the arteriolæ rectæ (Fig. 202, r. e.).

The *interlobular arteries* (a) pass off at right angles between the medullary rays, and then run amongst the convoluted tubes, some to enter the Malpighian capsules, and others to reach the surface and supply the capsule, ending in the stellate veins beneath the capsule. The arteriole which passes to the Malpighian capsule is termed the *afferent vessel* (1), and, entering the dilated extremity of the uriniferous tube, breaks up into a number of convoluted capillary vessels, constituting the *glomerulus* of Malpighi. The blood is returned from the glomerulus by a small *efferent vein* (2), which emerges from the capsule close to the entrance of the artery. This vein, after a short course, breaks up, like an artery, into a dense network of capillaries, which ramify over the convoluted tubules (*v.v.*). Some of the veins from the lower glomeruli break up into straight vessels, and then pass from the medullary rays into the pyramid.

The *arteriolar rectæ* are destined for the supply of the Malpighian pyramids entering them at their bases, and then passing downwards to their apices, where they join the venous plexuses.

The *Malpighian bodies* are small red granular masses about $\frac{1}{10}$ th of an inch in diameter, and are only found in the cortical substance. Each is composed of the dilated commencement of a uriniferous tube forming the *Malpighian capsule*, containing within it a coil of small blood-vessels called the *Malpighian tuft* or *glomerulus*. The capsule is composed of a homogeneous membrane, and is pierced by a small artery, *afferent vessel*, which enters it opposite the commencement of the urinary tubule. In the capsule the artery breaks up into a coil of minute blood-vessels, *glomerulus*, and returns its blood by a vein, *efferent vessel*, which emerges from the capsule close to where the artery entered. The capillary plexus within the capsule is surrounded by the epithelium lining the interior of the capsule.*

The *renal veins* return the blood from three sources: from the veins situated beneath the capsule (Fig. 202, S.), and those corresponding to the interlobular arteries which pass between the medullary rays (*v.v.*), and at the bases of the Malpighian pyramids join the *venæ rectæ* (c); the *venæ rectæ* return the blood from the *arteriolar rectæ*, and begin in plexuses at the apices of the pyramids, they then pass outwards between the *tubuli recti*, and join the interlobular veins to form the proper renal veins; these pass down along the sides of the Malpighian pyramids, accompanied by their corresponding arteries, and in their course to the sinus receive the efferent veins from the adjacent cortical substance. At the sinus they communicate freely with each other and join to form the renal vein.

The *nerves*, about fifteen in number, forming the renal plexus, are derived from the lesser and smallest splanchnic nerves, the solar plexus, and the semilunar ganglion.

The *lymphatics*, consisting of a deep and a superficial set, pass to the lumbar glands.

Supra-renal Capsules. These bodies, situated at the top of the kidneys, belong to the class of ductless glands. They are of yellow-ochre color; the right is triangular, and resembles a cocked hat; the left is more almond-shaped and rather

* Histologists differ with respect to the disposition of the epithelium over the glomerulus; some assert that it has no epithelial covering, but that it hangs loose within the capsule; some, that the tuft is completely invested with epithelium, except where the afferent and efferent vessels pass in; others, again, that only that portion of the glomerulus which looks towards the neck of the tubule is covered with epithelium.

the larger of the two. They measure about an inch and a half (*right*, 3.8 cm.; *left*, 5 cm.) in their long diameter, about three-quarters (*right*, 18 mm.; *left*, 2.5 cm.) in breadth, and $\frac{1}{6}$ to $\frac{1}{4}$ of an inch (4 to 6 mm.) in thickness; they weigh from one to two drachms* (4 to 8 gm.). The gland is surrounded by connective tissue and fat, and is invested by a thin fibrous covering, which sends down partitions into the interior through furrows on their surface.

A perpendicular section shows that it consists of a firm exterior or cortical part, and of an interior or medullary substance, soft and pulpy.

The *cortical portion* is of a yellow colour and forms the principal part of the organ. It consists of parallel columns arranged perpendicularly to the surface, due to the capsule sending processes into the interior of the gland, which communicate at frequent intervals by transverse bands. There are thus formed numerous spaces which communicate with each other; the spaces at the surface are smaller, while those towards the centre are longer; the section through the cortex gives the appearance of a fine network, the external portion taking the name of the *zona glomerulosa*, the internal portion that of the *zona reticularis*, the intermediate portion that of the *zona fasciculata*. The reticular tissue is made up of fibrous tissue with longitudinal bundles of unstriped muscular tissue.

The *medullary portion* varies in colour according to the amount of blood contained in it, being sometimes a dark-brown colour, sometimes nearly white. Not infrequently the medullary part is converted into a cavity, but this is probably a post-mortem change. It consists of a plexus of minute veins, supported by the delicate areola tissue containing muscular fibres, and presents a reticular aspect. Among these are numerous granular and branched cells.†

The *arteries* to the gland are conveyed along the trabecular tissue, and, after supplying the gland-tissue, converge to the centre, where the blood is returned into the venous plexuses in the medullary portion. They are derived from the abdominal aorta, the phrenic and the renal arteries. The *vein* begins in the centre as a single vessel, and joins, on the right side, the inferior vena cava, and on the left side the left renal vein.

The *lymphatics* terminate in the lumbar glands.

The *nerves* are derived from the solar and renal plexuses, and in them are found numerous ganglia. They are distributed chiefly to the medullary portion.‡ Of late years the minute structure and functions of the supra-renal capsules have been much investigated, in consequence of the discovery made by Dr. Addison, of the close relation which exists between certain diseases in these bodies and a brown discoloration of the skin. Their precise function is still unknown.

Stomach and Intestines.

The alimentary canal is composed of four coats: a serous, a muscular, a submucous, and a mucous. First, is the *serous* or *peritoneal*

* Many authors give a much larger weight, varying from 7 gm. (two drachms) to 19 gm. (five drachms); the gland is larger in young adolescence, but atrophies in old age. (A. H.)

† The medullary cells are stained a deep brown colour on the addition of bichromate of potash, the cortical cells being scarcely affected by it.

‡ Luschka states that the branched granular cells of the medullary portion are connected with the nerve-fibres.

coat, described at p. 430. Secondly, under the serous is a *muscular* coat, upon which the chief strength of the canal depends. It consists of two distinct strata of plain muscular fibres; the outer stratum is longitudinal, the inner circular. This arrangement not only makes the bowel stronger, but regulates its peristaltic action, for the longitudinal fibres, by their contraction, tend to shorten and straighten the tube, while the circular fibres contract upon and propel its contents to greater advantage. Connecting this coat and the mucous, is a layer of areolar tissue called the *submucous coat*, in which the arteries break up before entering the mucous membrane. The *mucous* is the most complicated of all the coats, for it presents different characters in different parts, according to the functions which it has to perform.

Stomach.

The stomach should be moderately distended to see its size, which varies in different subjects according to the habits of the individual. When distended, an average stomach would be about ten or twelve inches (*25 to 30 cm.*) in length, and four (*10 cm.*) in depth and width; its weight is stated to be about four and a half ounces (*about 130 gm.*) (*capacity 6½ lbs. or 3.5 kilgm.*). It is conical in shape; the left part forms a large bulge called the *cardiac* or *splenic end*; and on the right side where the food passes out it becomes small and contracted, and is called the *pyloric end*. The stomach presents for examination two surfaces, two borders, two ends, and two orifices.

The *anterior surface* is convex, and looks upwards and forwards; the *posterior surface* looks downwards and backwards.

The *upper border* or the *lesser curvature* is concave and short, and extends from the œsophagus to the pylorus; it is connected to the liver by the gastro-hepatic omentum. The *lower border* or the *greater curvature* is convex, and affords attachment to the great omentum.

The *left end* is the larger, and is called the *cardiac* or *splenic end*; it bulges out to the extent of two or three inches (*5 to 7.5 cm.*) to the left of the entrance of the œsophagus, and is called the *great cul-de-sac* or *fundus*. The *right end* is narrow, and makes a double bend; near the first it bulges into a pouch, called the *antrum pylori*, or the *small cul-de-sac*.

The *œsophageal* or *cardiac orifice*, situated at the highest part of the stomach, is on the left, and receives the œsophagus; the *pyloric orifice* is continued on into the duodenum, and is narrow, being guarded by a musculo-mucous ring, the *pylorus*.*

* The position of the stomach within the abdomen, and its relations with surrounding structures, are matters of much dispute. Dr. Lesshaft has come to the conclusion that the stomach is nearly vertical, so that its fundus touches the diaphragm (See *Lancet*, March 11, 1882, p. 406.) His, and most anatomists, are of opinion that the long axis is placed obliquely from left to right within the abdomen.

The stomach is connected at its borders by peritoneal folds extending to neighbouring structures; thus, its lesser curve is connected with the transverse fissure of the liver by the gastro-hepatic or lesser omentum; its cardiac end is connected with the hilum of the spleen by the gastro-splenic omentum; to the left of the œsophagus it is connected with the diaphragm by the gastro-phrenic ligament; to its greater curve is attached the great

omentum, which is continuous on the left side with the gastro-splenic omentum.

The *pylorus* is the narrow circular ring, composed of circular muscular fibres and mucous membrane, through which the food passes into the duodenum. The serous and longitudinal muscular fibres take no part in its formation, being continued over it on to the duodenum.

The stomach consists of four coats: serous, muscular, submucous, and mucous.

The *serous* or *peritoneal coat* covers the surface of the stomach, except at the borders, where the peritoneum is continued as omenta to other organs; it is along these borders that the vessels run.

The *muscular coat* can be seen when the serous coat is removed. The fibres are of the unstriped variety, and arranged in three layers: an external or longitudinal, a

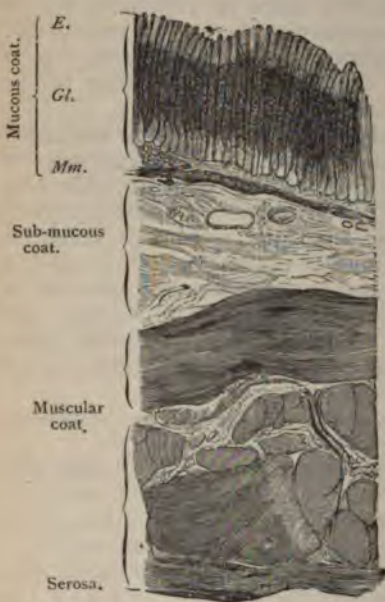


FIG. 304.—VERTICAL SECTION OF THE WALL OF THE HUMAN STOMACH $\times 15$.

E. Epithelium. Gl. Glands. Mm. Muscularis mucosae.

middle or circular, and an internal or oblique.

The *longitudinal fibres* are continuous with the longitudinal fibres of the œsophagus, and spread out over the stomach, being most numerous along the curvatures of the stomach; they are at the pyloric end continuous with the longitudinal fibres of the duodenum.

The *circular fibres* are well-marked about the middle of the stomach, but are most abundant at the pylorus, where they form a powerful sphincter.

The *oblique fibres* are scattered over the sides of the stomach, and are most distinct at the entrance of the œsophagus, crossing obliquely from left to right and from right to left. They are continuous with the well-marked circular fibres of the œsophagus.

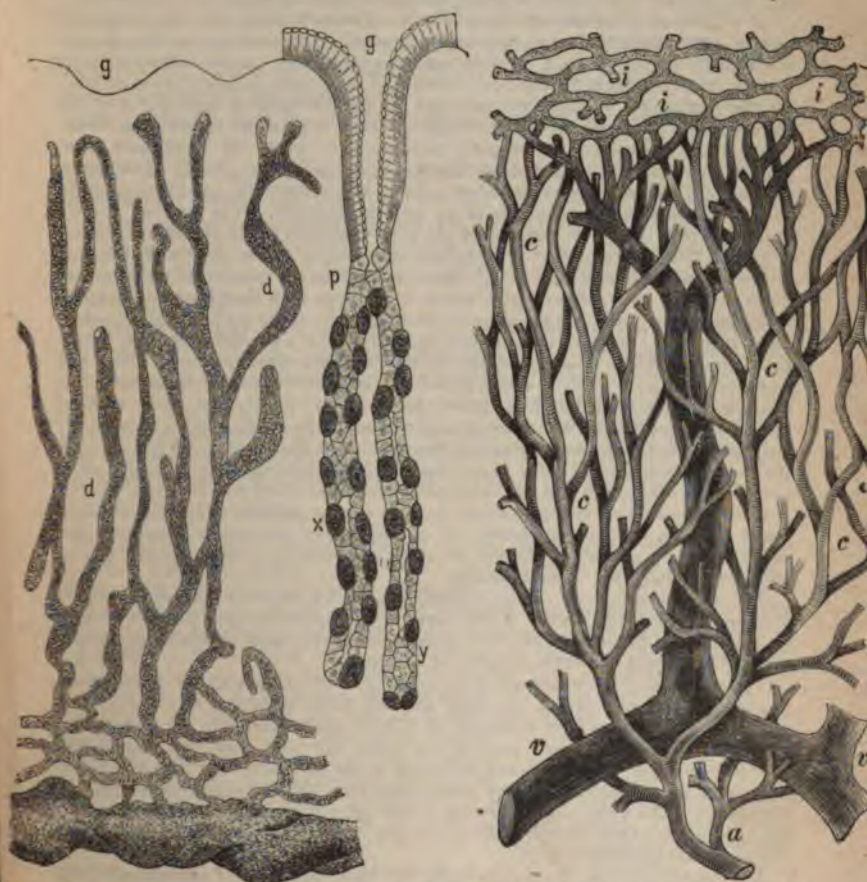


FIG. 205.—VERTICAL SECTION OF THE GASTRIC MUCOUS MEMBRANE. *g, g.* Pits on the surface. *p.* Neck of a fundus-gland opening into a duct. *g, x.* Parietal, and *y,* chief cells. *a, v, c.* Artery, vein, capillaries. *d, d.* Lymphatics, emptying into a large trunk, *e.*

The *submucous coat* serves to connect the muscular with the mucous coats. It consists of areolar tissue, and permits the muscular and mucous coats to move freely on each other, and

allows the blood-vessels to ramify minutely before they enter the mucous membrane.

When the stomach is laid open from the œsophageal to the pyloric orifice, the *mucous membrane* is seen to be thick, of pale pink or straw color, and is gathered into longitudinal folds—*rugæ*—which disappear when the stomach is distended.

If a portion of the mucous membrane be examined under the microscope, its surface will be seen to be mapped out into small hexagonal pits or *alveoli*, surrounded by ridges, giving it a honeycombed appearance. At the bottom of them are a number of minute apertures, the orifices of the *gastric follicles*. In a perpendicular section the follicles are arranged in parallel lines at right angles to the surface, and terminate in blind sacculated ends set in the submucous tissue. The entire thickness of the mucous membrane is made up of these tubular glands. The follicles consist of two kinds, *mucous* and *peptic glands*. Tubular in shape, they have a basement membrane lined with epithelium, and average about $\frac{1}{40}$ th of an inch long, and $\frac{1}{80}$ th of an inch in diameter. The *mucous glands* are found over the whole surface, but are most numerous at the pyloric end of the stomach. They are composed of tubes, each consisting of two or three short tubules, opening into a common duct, which itself opens into the bottom of an alveolus. They are lined with columnar epithelium, continuous with that lining the mucous membrane. The *peptic glands* are also found over the entire surface of the mucous membrane, and consist of tubules with branched caecal extremities opening into a common duct, which is, however, shorter than that of a mucous gland. They are lined with columnar epithelial cells, called the *central cells*, and are supposed to be concerned in the secretion of the gastric juice; these cells become, at the neck of the gland, much shorter and more granular. The lumen of the gland is very small, but is somewhat larger at the free and the caecal ends than in the middle. Toward the lower part or fundus of the gland there are found spheroidal and granular cells between the epithelium and the basement membrane, called *parietal cells*.

In the stomachs of young children there is a large amount of lymphoid tissue found between the gastric glands. It is aggregated into small masses in the mucous membrane, and resembles, in many respects, the solitary glands of the intestine, although not so well defined.

The mucous membrane of the stomach is lined by columnar epithelium, which also extends into the glands. A thin layer of unstriped muscular tissue (*muscularis mucosæ*) is found between the mucous membrane and its submucous tissue, varying in amount and in the number of its layers.

The glands of the stomach are richly supplied with blood, which is derived from the gastric, the *vasa brevia*, the right and left gastro-epiploica, and the pyloric arteries. The arteries form a stratum of minute inosculations in the submucous tissue, in which the closed ends of the tubes are set; from this stratum the capillary plexuses run up between the tubes to the surface of the stomach, where they again form a larger capillary plexus, and form the hexagonal spaces before alluded to. The *veins*, corresponding to the pyloric and gastric arteries, end in the *vena portæ*; those corresponding with the *vasa brevia* and the *epiploic arteries* open into the splenic vein.

The *lymphatics* enter the glands along the lesser and greater curvatures of the stomach, and may be divided into a superficial and a deep set.

The *nerves* are derived from the pneumogastric nerves and from the solar plexus.

Small Intestine.

The small intestine, consisting of the duodenum, jejunum, and ileum, forms a tube averaging twenty feet in length, which gradually lessens in calibre

until it opens into the cæcum. The duodenum is about twelve fingers' breadth (10 inches or 25 cm., and 2 inches or 5 cm. in diameter) in length, whence its name; the jejunum comprises two-fifths, the ileum three-fifths, of the remaining part of the small intestine. As regards their external characters, the duodenum and jejunum are more vascular than the ileum, and feel thicker in consequence of the peculiar arrangement of their mucous membrane; but there are no defined limits between the different portions of the intestinal canal.

Its coats are four in number: serous, muscular, submucous, and mucous.

The *serous coat* consists of peritoneum, and forms a complete investment, except in the case of the descending and transverse portions of the duodenum, which are only covered in front.

The *muscular coat* consists of an outer longitudinal layer and an inner circular thicker layer, which, however, becomes thinner towards the end of the ileum.

The *submucous coat* connects the muscular and mucous coats; immediately beneath the mucous membrane there is a very thin layer of non-striped muscular fibres, termed *muscularis mucosæ*.

The *mucous coat* can only be seen when the intestine is cut open from the upper end, and is composed of the following strata: the *muscularis mucosæ*, a layer of retiform tissue with lymph corpuscles, with blood-vessels and nerves; and, lastly, a layer of columnar epithelium.

When the intestine is laid open we see that the mucous membrane is arranged in close transverse folds, called *valvulæ conniventes* or *valves of Kerkring*. These differ from other folds in the alimentary canal—e.g., in the œsophagus and stomach—in that they are not obliterated when the tube is distended. Each fold extends about one-half or two-thirds round the intestine, but they are not all of equal size, and are about one-third of an inch (8 mm.) in depth. They commence immediately below the opening of the biliary and pancreatic ducts, and are most developed in the duodenum and the upper part of the jejunum. Below this part of the tube they gradually decrease in size, and become wider apart, till they finally disappear near the middle of the ileum. The use of the *valvulæ conniventes* is to increase the extent of surface for the absorption of chyle, to prevent the food passing too rapidly through the intestine, and for secretion.

If a portion of small intestine be washed and placed in water, the surface of the mucous membrane appears like the soft fur or pile upon velvet. This appearance is produced by small processes called *villi*. These are extremely vascular projections of the mucous membrane, about $\frac{1}{8}$ of an inch (5 mm.) in length, and are so numerous that $\frac{1}{12}$ of an inch (2 mm.) square contains from forty to ninety of them.* Their size, however, and their number, bear a direct ratio to those of the *valvulæ conniventes*. Under the microscope a villus is seen to consist of an outstanding process of the mucous membrane, covered by a layer of columnar epithelium, which rests upon a basement membrane. Each villus is

* Krause estimates the total number of villi at four millions.

furnished with an artery which forms a network of inosculations in it, and then returns its blood by a single vein. Down its middle runs a *lacteal* or absorbing vessel, which commences in a closed end near the summit of the villus, where it is surrounded by a layer of pale non-striped muscular fibres proceeding from the *muscularis mucosæ*. This is surrounded by a plexus of capillaries, external to which is the basement membrane supporting columnar epithelium. Forming the matrix of the villus is a fine network enclosing large flattened cells with oval nuclei and lymph cells.

Intestinal Glands.

There are four kinds of *glands** in the small intestine, called the glands of Lieberkühn, Brunner, Peyer, and the solitary glands. The first and last are distributed over the whole tract of the intestinal mucous membrane; the other two over particular parts.

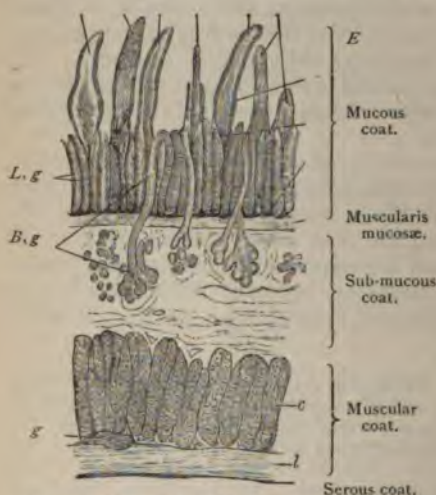


FIG. 206.—VERTICAL SECTION OF THE DUODENUM.
E. Epithelium. c and l. Circular and longitudinal muscular fibres. L. g. Lieberkühn's glands. B. g. Brunner's glands. g. Ganglion cells, v. Villi.

glands of the mucous membrane of the mouth.

The *glands of Peyer* (*glandulæ agminatæ*) abound most in the ileum, and are seen most distinctly in children. They are arranged in groups, from twenty to forty in number, on that part of the intestine most distant from the attachment of the mesentery. These groups are from half an inch to three inches (12 mm. to 7.5 cm.) long, and one inch (2.5 cm.) in width, of an oval form, and increase in size and number towards the lower part of the ileum. If a group be examined by dissecting away the muscular coat, you find that it is composed of a number of

The *simple follicles* or *crypts of Lieberkühn*, the most numerous of all, are minute tubes with blind ends, very thickly distributed over the small and the large intestines. Under the microscope their orifices are seen between the villi like so many minute dots. Their average length is 36 mm.; their walls consist of a delicate basement or endothelial membrane, and are lined with columnar epithelium.

The *duodenal* or *glands of Brunner* are found only in the duodenum and a small part of the beginning of the jejunum. They are just visible to the naked eye, and may be seen by removing the muscular coat. Their structure exactly resembles the round compound

* A satisfactory examination of the intestinal glands can be made only in specimens quite recent, taken from young persons who have died suddenly, or from a rapidly fatal disease.

small oval vesicles, like Florence flasks, imbedded in the submucous tissue. They are composed of masses of lymphoid tissue, of about $\frac{1}{8}$ of an inch (1.7 mm.) in diameter, and contain an opaque greyish fluid. No excretory ducts have been traced from these vesicles, but they are supposed to discharge their contents by rupture of their capsules. Between the vesicles are found Lieberkühn's follicles, and the surface of the patches is covered with villi. These glands are liable to be ulcerated in typhoid fever. They diminish in number and size with old age.

The *solitary glands* are scattered over all parts of the small and large intestines. They consist of the same lymphoid structure as the glands of Peyer, and only differ from them in being solitary instead of being aggregated into groups.

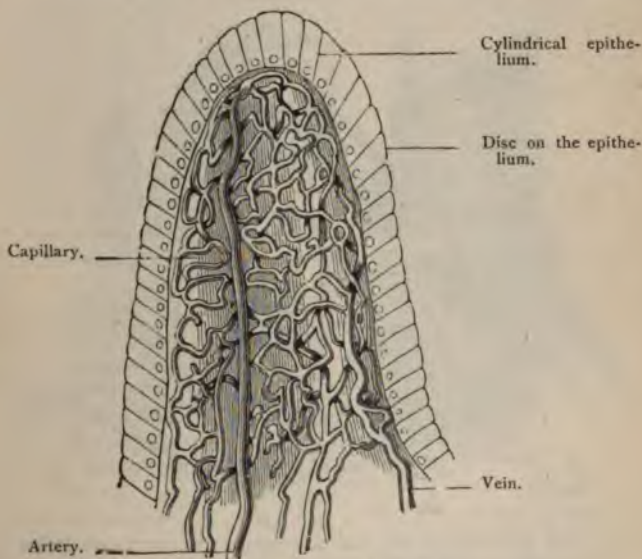


FIG. 207.—INJECTED BLOOD-VESSELS OF A VILLUS.

The *lymphatics* consist of two sets—those of the muscular, and those of the mucous coats; the latter receive those from the villi, at the base of which they form a minute plexus, and, after piercing the muscular coat, join with the former, which are chiefly found between the longitudinal and the circular layers of muscular fibres.

The *nerves* are derived from the superior mesenteric plexus, and accompany the superior mesenteric artery and its branches between the layers of the mesentery; after reaching the intestinal walls the nerve-filaments separate from the arteries. They then pierce the external longitudinal muscular fibres, and form a very minute gangliated plexus—*Auerbach's plexus*, or *plexus mesentericus*—which distributes filaments to the muscular layer of the entire intestinal canal. From this plexus numerous branches perforate the internal circular muscular layer, and unite to

form a largely gangliated plexus—*Meissner's plexus*—in the submucous tissue. The *intermuscular plexus* probably supplies the muscular coat and regulates the peristaltic action of the bowel; the *submucous plexus* determines the calibre of the blood-vessels.

Large Intestine. The principal external characters of the large intestine are that it is pouched or sacculated, and that it has attached to it little pendulous portions of fat covered by peritoneum, called *appendices epiploicae*. The pouches (sacculi) are produced by a shortening of the longitudinal muscular fibres, and by their being collected into three bands, about half an inch



FIG. 208.—SECTION OF A SOLITARY FOLLICLE OF THE SMALL INTESTINE.

a. Lymph-follicle covered with epithelium (*b*); but the villi, *c*, are denuded of epithelium. *d.* Lieberkühn's follicle. *e.* Muscularis mucosae. *f.* Sub-mucous tissue.

(13 mm.) wide, nearly equidistant from each other. One of these bands corresponds with the attached part of the circumference of the bowel; another with the front part; a third with its concavity. If at any given part the three bands be divided, the pouches immediately disappear.

In a colon moderately distended and dried, we observe that the mucous membrane forms numerous ridges or incomplete septa (Fig. 209); they correspond to the grooves on the external surface of the bowel, and disappear, like the sacculi, when the longitudinal bands are divided.

The *rectum* differs from the rest of the large intestine in that its longitudinal muscular fibres are not collected into bands, but distributed equally over its whole circumference. Moreover, both the longitudinal and circular fibres are of considerable strength, like those of the œsophagus, as one might expect from the particular functions which these parts of the alimentary canal have to perform. For an inch and half (3.8 cm.) above the anus, the circular fibres are remarkably developed, and constitute the *internal sphincter ani*.

The mucous membrane of the large intestine differs considerably from that of the small. There are neither valvæ conniventes nor villi, but the *glands of Lieberkühn* and the *lymphoid follicles* may be seen studding the mucous membrane (Fig. 210). The follicles are more abundant in the cœcum and in the appendix vermiformis than in any other part of the alimentary canal. The blood-vessels present the same hexagonal arrangement on the surface as that of the stomach. That the mucous membrane of the large intestine may be temporarily used as a substitute for the stomach is proved by the fact of persons having been nourished for many weeks solely by injections. The mucous membrane is lined throughout with columnar epithelium.

At the junction of the small with the large intestine the mucous membrane is folded so as to form a valve; but it is not a perfect one, as is proved by pouring water into the large intestine, or by the occasional vomiting of injections. The arrangement of the valve is best examined in a dried preparation. The opening is a transverse fissure like a button-hole, and the two flaps are arranged like an upper and a lower eyelid. The upper lid of the valve projects more than the lower, so that the contents of the ileum drop naturally down into the caput coli, where they are apt to collect and form hard lumps. The flaps of the valve consist of mucous membrane and the circular fibres of the ileum. The longitudinal fibres of the ileum are continued directly on to the cœcum; if these be divided the ileum can be drawn out, and the valve disappears.*

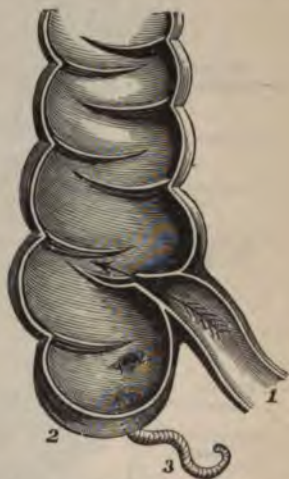

FIG. 209.—SECTION THROUGH THE JUNCTION OF THE LARGE AND SMALL INTESTINES, TO SHOW THE ILEO-CÆCAL VALVE.

1. Ileum. 2. Cœcum of caput coli. 3. Appendix vermiformis.

* It is interesting to note that the surface of the valve, towards the ileum, is covered with villi; not so the surface towards the large intestine.

Folds in the Rectum. In many subjects we observe that transverse or oblique folds of the mucous membrane project into the rectum. These cannot be seen to advantage unless the bowel be hardened by alcohol in its natural position. Three, more prominent than the rest, and half an inch (*13 mm.*), or thereabouts, in width, were first pointed out by Mr. Houston.* The lowest of these is found about one inch (*2.5 cm.*) above

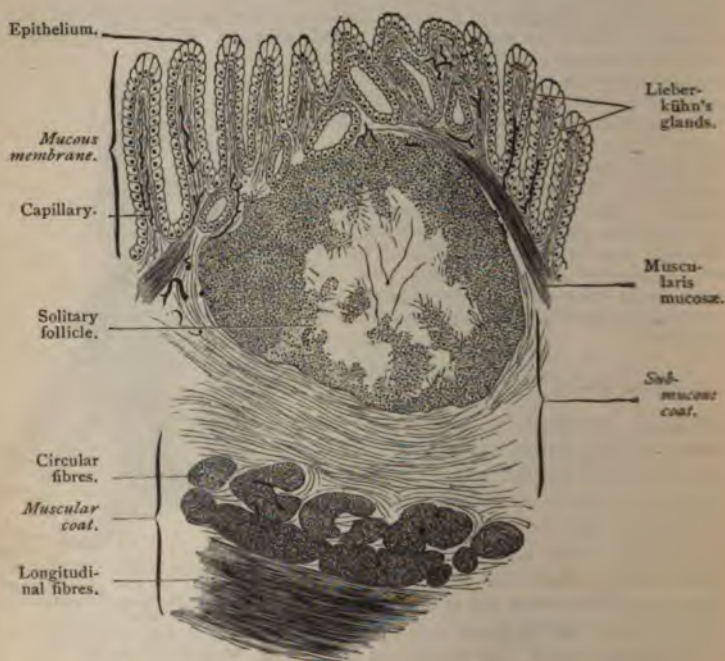


FIG. 210.—LONGITUDINAL SECTION OF THE LARGE INTESTINE.

the anus on the left and posterior portion of the gut, the second on the right and more anterior portion of the gut; about two and a half inches (*6.3 cm.*) above the orifice; while the third is still higher. When thickened or ulcerated, these folds are apt to occasion great pain and obstruction in defæcation.

* *Dublin Hospital Reports*, vol. v, p. 163.


**Arterial Supply of
the Alimentary
Canal.**

The present opportunity is the best for reviewing the arterial supply of, and the anastomoses round, the alimentary canal, from *the mouth to the anus*. Part of the blood supply has been examined in the dissection of the head and neck; part in the dissection of the œsophagus as it passes through the thorax; and the remainder in that of the abdomen. The following table represents the arteries in their order, beginning at the mouth:—

LOWER LIP,	Submental (deep branch). Mental. Inferior labial. Inferior coronary.
UPPER LIP,	Superior coronary.
CHEEK,	Buccal. Superior coronary (slightly). Facial. Transverse facial. Infra-orbital. Superior alveolar.
MOUTH, ROOF OF,	Descending palatine. Ascending palatine. Pharyngeal br. of ascending pharyngeal.
MOUTH, FLOOR OF, AND TONGUE,	Artery of the frænum. Ranine. Sublingual. Dorsales lingue. Tonsillar. Ascending palatine. Ascending pharyngeal.
EPIGLOTTIS,	Superior laryngeal artery.
PHARYNX,	Pterygo-palatine. Branches of ascending pharyngeal. Branches of ascending palatine. Superior thyroid.
ŒSOPHAGUS, CERVICAL, . . .	Superior thyroid. Inferior thyroid.
ŒSOPHAGUS, THORACIC, . . .	Inferior thyroid. Thoracic aorta. Gastric. Left phrenic.
ŒSOPHAGUS, ABDOMINAL, . . .	Gastric. Left phrenic.
STOMACH,	Gastric. Pyloric. Gastro-epiploica dextra. Gastro-epiploica sinistra. Vasa brevia. Gastro-duodenalis.
DUODENUM,	Pancreatico-duodenalis superior. Pancreatico-duodenalis inferior.
JEJUNUM,	Superior mesenteric.
ILEUM,	Superior mesenteric.
CÆCUM,	Colic br. of ileo-colic.
ASCENDING COLON,	Colica dextra.



TRANSVERSE COLON,	Colica media.
DESCENDING COLON,	Colica sinistra.
SIGMOID FLEXURE,	Sigmoid arteries.
RECTUM,	Superior hæmorrhoidal (inferior mesenteric). Middle hæmorrhoidal (internal iliac). Inferior hæmorrhoidal (internal pudic). Arteria sacra media.



DISSECTION OF THE LOWER EXTREMITY.

The body must be placed on its back, with a block placed beneath the buttocks, and the thigh should then be slightly flexed and abducted.

Surface Marking. The student, before commencing to reflect the skin, should notice the irregularities of the surface which are produced by subjacent structures. The upper part of the thigh is marked off from the abdomen by a more or less well-marked curved furrow, having its convexity downwards. This furrow corresponds with Poupart's ligament, which is attached externally to the anterior superior iliac spine, and internally to the spine of the os pubis. The spine of the os pubis can, even in the fattest subject, be distinctly felt, and is a very valuable landmark in the diagnosis between an inguinal and a femoral hernia; for the aperture through which an inguinal hernia emerges is the external abdominal ring, situated *above* the spine; the aperture through which a femoral hernia comes out is the saphenous opening, situated *outside* the spine. In front of the thigh is a large triangular depression corresponding with Scarpa's triangle, which has its base at Poupart's ligament. This depression, which is best seen in thin subjects, contains the large vessels and nerves passing down to the leg, the femoral artery being nearly in the centre of the space: a furrow indicating the course of these vessels may be observed extending obliquely down the inner side of the thigh. About three or four inches (7.5 to 10 cm.) below the anterior superior iliac spine, there is seen on the outer side of the thigh the well-marked prominence of the great trochanter, which is nearly on the same level as the spine of the os pubis. The sartorius can be seen passing obliquely inwards from the iliac spine, and crossing over the femoral vessels about four inches (10 cm.) below Poupart's ligament; in the latter two-thirds of its course it descends nearly vertically. The well-defined ridge, extending from the os pubis to the middle of the femur, when the thigh is abducted, is caused by the adductor longus muscle.

The prominence in front of the knee is produced by the patella, to which is attached above the tendon of the quadriceps muscle, and below, the ligamentum patellæ, both of which can be distinctly felt. On each side of the patella is a deep depression, which leads

on the outer side to a rounded prominence, the external condyle; and on the inner to the internal condyle, the latter being the larger. The synovial membrane which lines the knee-joint usually extends about two fingers' breadth above the patella, and is a little higher on the inner than on the outer side of the joint.

An incision should be made along the groin, extending from the anterior superior spine of the ilium to the spine of the os pubis; another, from the middle of the first down the front of the thigh for about six inches (15 cm.). The skin only should be reflected, outwards and inwards, when the superficial fascia will be exposed.

Superficial Fascia. The *superficial fascia* varies in thickness, according to the condition of the body. Like other superficial fasciæ, it is divisible into two or more layers, between which are situated the inguinal glands and the cutaneous vessels and nerves. The superficial layer is continuous with that of the abdomen, and becomes firmer below Poupart's ligament, to which, however, it is not connected; the deeper layer is best marked in the upper part of the thigh, especially where it stretches across the saphenous opening, to the margins of which it is closely attached; this portion is called the *cribriform fascia*, and is protruded forwards by a femoral hernia, forming one of its coverings; this layer is also attached to Poupart's ligament.

The superficial layer of this fascia should now be reflected, by searching for one of the subcutaneous veins (the internal saphena will do) which run between the upper and the deeper layers of the fascia. The cutaneous vessels can thus be traced, and come from the common femoral artery; they are three in number, the *superficial epigastric*, the *superficial external pudic*, and the *superficial circumflexa ilii* arteries. The first ascends over Poupart's ligament to the abdomen (p. 559); the second crosses inwards towards the os pubis; the third passes outwards to the ilium. Each artery is accompanied by one, sometimes by two veins, which empty themselves, either directly into the femoral, or into the great cutaneous vein of the thigh, called the saphena.

Superficial Inguinal Glands. These glands are easily recognized by their oval form and reddish-brown colour. There are two sets: one set runs parallel to Poupart's ligament, and receives the lymphatics from the skin of the penis, the scrotum, the perineum, the anus, the buttock, the lower part of the abdominal wall, and the upper and outer aspect of the thigh; the outer and lower set lies along the saphena vein, chiefly around the saphenous opening, and receives the lymphatics from the foot, the leg, and the lower part of the thigh. This explains why in cancer of the scrotum and syphilitic disease of the penis the first set becomes enlarged; and the second, in diseases of the lower ex-

tremity. The lymphatic vessels which pass to and from the glands are small, and may escape observation, unless specially looked for. They all pass through the femoral ring into the abdomen, and eventually empty themselves into the receptaculum chyli.

The glands mentioned in the preceding paragraph are all superficial. There are others, more deeply seated, close to the great vessels of the thigh; these are much smaller, and sometimes cannot be found.

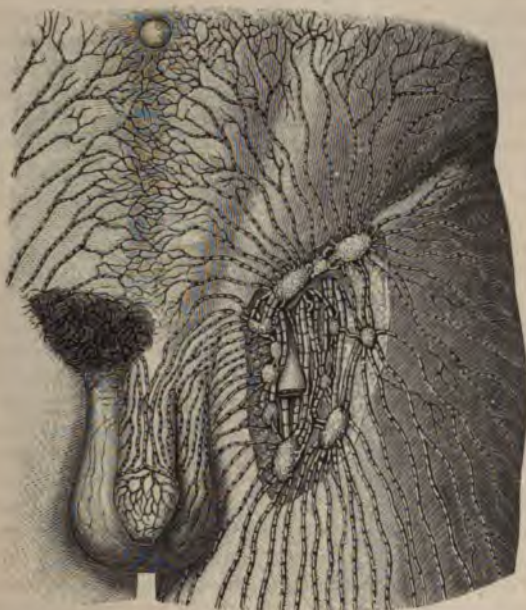


FIG. 211.—LYMPHATIC VESSELS AND GLANDS OF THE GROIN.

Superficial Arteries of the Groin.

The *superficial epigastric* artery comes through the fascia lata, sometimes through the saphenous opening, half an inch (13 mm.) below Poupart's ligament. It ascends over Poupart's ligament to pass to the subcutaneous tissue of the abdomen, as high as the umbilicus, and supplies the inguinal glands, and anastomoses with the deep epigastric and internal mammary arteries. Its further course is described at p. 397.

The *superficial circumflexa ilii* emerges through the fascia lata, runs parallel to Poupart's ligament towards the crest of the ilium,

on the outer side to a rounded prominence, the external condyle; and on the inner to the internal condyle, the latter being the larger. The synovial membrane which lines the knee-joint usually extends about two fingers' breadth above the patella, and is a little higher on the inner than on the outer side of the joint.

An incision should be made along the groin, extending from the anterior superior spine of the ilium to the spine of the os pubis; another, from the middle of the first down the front of the thigh for about six inches (15 cm.). The skin only should be reflected, outwards and inwards, when the superficial fascia will be exposed.

Superficial Fascia. The *superficial fascia* varies in thickness, according to the condition of the body. Like other superficial fasciæ, it is divisible into two or more layers, between which are situated the inguinal glands and the cutaneous vessels and nerves. The superficial layer is continuous with that of the abdomen, and becomes firmer below Poupart's ligament, to which, however, it is not connected; the deeper layer is best marked in the upper part of the thigh, especially where it stretches across the saphenous opening, to the margins of which it is closely attached; this portion is called the *cribriform fascia*, and is protruded forwards by a femoral hernia, forming one of its coverings; this layer is also attached to Poupart's ligament.

The superficial layer of this fascia should now be reflected, by searching for one of the subcutaneous veins (the internal saphena will do) which run between the upper and the deeper layers of the fascia. The cutaneous vessels can thus be traced, and come from the common femoral artery; they are three in number, the *superficial epigastric*, the *superficial external pudic*, and the *superficial circumflexa ilii* arteries. The first ascends over Poupart's ligament to the abdomen (p. 559); the second crosses inwards towards the os pubis; the third passes outwards to the ilium. Each artery is accompanied by one, sometimes by two veins, which empty themselves, either directly into the femoral, or into the great cutaneous vein of the thigh, called the saphena.

Superficial Inguinal Glands. These glands are easily recognized by their oval form and reddish-brown colour. There are two sets: one set runs parallel to Poupart's ligament, and receives the lymphatics from the skin of the scrotum, the perineum, the anus, the buttock, the lower part of the abdominal wall, and the upper and outer aspect of the thigh; the other set runs along the saphena vein, and receives the lymphatics from the skin of the thigh. The

Arterial Supply of the Alimentary Canal.

The present opportunity is the best for reviewing the arterial supply of, and the anastomoses round, the alimentary canal, from *the mouth to the anus*. Part of the blood supply has been examined in the dissection of the head and neck; part in the dissection of the œsophagus as it passes through the thorax; and the remainder in that of the abdomen. The following table represents the arteries in their order, beginning at the mouth:—

LOWER LIP,	Submental (deep branch). Mental. Inferior labial. Inferior coronary.
UPPER LIP,	Superior coronary.
CHEEK,	Buccal. Superior coronary (slightly). Facial. Transverse facial. Infra-orbital. Superior alveolar.
MOUTH, ROOF OF,	Descending palatine. Ascending palatine. Pharyngeal br. of ascending pharyngeal.
MOUTH, FLOOR OF, AND TONGUE,	Artery of the frænum. Ranine. Sublingual. Dorsales linguæ. Tonsillar. Ascending palatine. Ascending pharyngeal.
EPIGLOTTIS,	Superior laryngeal artery.
PHARYNX,	Pterygo-palatine. Branches of ascending pharyngeal. Branches of ascending palatine. Superior thyroid.
ŒSOPHAGUS, CERVICAL, . .	Superior thyroid. Inferior thyroid.
ŒSOPHAGUS, THORACIC, . .	Inferior thyroid. Thoracic aorta. Gastric. Left phrenic.
ŒSOPHAGUS, ABDOMINAL, . .	Gastric. Left phrenic.
STOMACH,	Gastric. Pyloric. Gastro-epiploica dextra. Gastro-epiploica sinistra. Vasa brevia. Gastro-duodenalis.
DUODENUM,	Pancreatico-duodenalis superior. Pancreatico-duodenalis inferior.
JEJUNUM,	Superior mesenteric.
ILEUM,	Superior mesenteric.
CÆCUM,	Colic br. of ileo-colic.
ASCENDING COLON,	Colica dextra.

ARTERIAL SUPPLY OF THE ALIMENTARY CANAL.

TRANSVERSE COLON,	Colica media.
DESCENDING COLON,	Colica sinistra.
SIGMOID FLEXURE,	Sigmoid arteries.
RECTUM,	Superior hæmorrhoidal (<i>inferior mesenteric</i>).
	Middle hæmorrhoidal (<i>internal iliac</i>).
	Inferior hæmorrhoidal (<i>internal pudic</i>).
	Arteria sacra media.

DISSECTION OF THE LOWER EXTREMITY.

The body must be placed on its back, with a block placed beneath the buttocks, and the thigh should then be slightly flexed and abducted.

Surface Marking. The student, before commencing to reflect the skin, should notice the irregularities of the surface which are produced by subjacent structures. The upper part of the thigh is marked off from the abdomen by a more or less well-marked curved furrow, having its convexity downwards. This furrow corresponds with Poupart's ligament, which is attached externally to the anterior superior iliac spine, and internally to the spine of the os pubis. The spine of the os pubis can, even in the fattest subject, be distinctly felt, and is a very valuable landmark in the diagnosis between an inguinal and a femoral hernia; for the aperture through which an inguinal hernia emerges is the external abdominal ring, situated *above* the spine; the aperture through which a femoral hernia comes out is the saphenous opening, situated *outside* the spine. In front of the thigh is a large triangular depression corresponding with Scarpa's triangle, which has its base at Poupart's ligament. This depression, which is best seen in thin subjects, contains the large vessels and nerves passing down to the leg, the femoral artery being nearly in the centre of the space: a furrow indicating the course of these vessels may be observed extending obliquely down the inner side of the thigh. About three or four inches (*7.5 to 10 cm.*) below the anterior superior iliac spine, there is seen on the outer side of the thigh the well-marked prominence of the great trochanter, which is nearly on the same level as the spine of the os pubis. The sartorius can be seen passing obliquely inwards from the iliac spine, and crossing over the femoral vessels about four inches (*10 cm.*) below Poupart's ligament; in the latter two-thirds of its course it descends nearly vertically. The well-defined ridge, extending from the os pubis to the middle of the femur, when the thigh is abducted, is caused by the adductor longus muscle.

The prominence in front of the knee is produced by the patella, to which is attached above the tendon of the quadriceps muscle, and below, the ligamentum patellæ, both of which can be distinctly felt. On each side of the patella is a deep depression, which leads

on the outer side to a rounded prominence, the external condyle; and on the inner to the internal condyle, the latter being the larger. The synovial membrane which lines the knee-joint usually extends about two fingers' breadth above the patella, and is a little higher on the inner than on the outer side of the joint.

An incision should be made along the groin, extending from the anterior superior spine of the ilium to the spine of the os pubis; another, from the middle of the first down the front of the thigh for about six inches (15 cm.). The skin only should be reflected, outwards and inwards, when the superficial fascia will be exposed.

Superficial Fascia. The *superficial fascia* varies in thickness, according to the condition of the body. Like other superficial fasciæ, it is divisible into two or more layers, between which are situated the inguinal glands and the cutaneous vessels and nerves. The superficial layer is continuous with that of the abdomen, and becomes firmer below Poupart's ligament, to which, however, it is not connected; the deeper layer is best marked in the upper part of the thigh, especially where it stretches across the saphenous opening, to the margins of which it is closely attached; this portion is called the *cribriform fascia*, and is protruded forwards by a femoral hernia, forming one of its coverings; this layer is also attached to Poupart's ligament.

The superficial layer of this fascia should now be reflected, by searching for one of the subcutaneous veins (the internal saphena will do) which run between the upper and the deeper layers of the fascia. The cutaneous vessels can thus be traced, and come from the common femoral artery; they are three in number, the *superficial epigastric*, the *superficial external pudic*, and the *superficial circumflexa ilii* arteries. The first ascends over Poupart's ligament to the abdomen (p. 559); the second crosses inwards towards the os pubis; the third passes outwards to the ilium. Each artery is accompanied by one, sometimes by two veins, which empty themselves, either directly into the femoral, or into the great cutaneous vein of the thigh, called the saphena.

Superficial Inguinal Glands. These glands are easily recognized by their oval form and reddish-brown colour. There are two sets: one set runs parallel to Poupart's ligament, and receives the lymphatics from the skin of the penis, the scrotum, the perineum, the anus, the buttock, the lower part of the abdominal wall, and the upper and outer aspect of the thigh; the outer and lower set lies along the saphena vein, chiefly around the saphenous opening, and receives the lymphatics from the foot, the leg, and the lower part of the thigh. This explains why in cancer of the scrotum and syphilitic disease of the penis the first set becomes enlarged; and the second, in diseases of the lower ex-

tremity. The lymphatic vessels which pass to and from the glands are small, and may escape observation, unless specially looked for. They all pass through the femoral ring into the abdomen, and eventually empty themselves into the receptaculum chyli.

The glands mentioned in the preceding paragraph are all superficial. There are others, more deeply seated, close to the great vessels of the thigh; these are much smaller, and sometimes cannot be found.

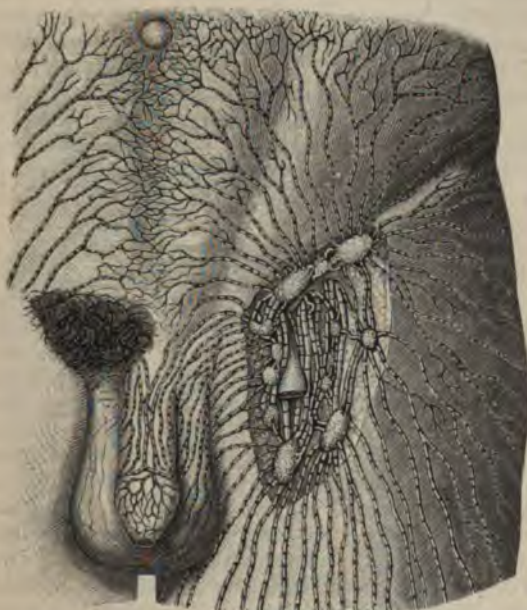

FIG. 217.—LYMPHATIC VESSELS AND GLANDS OF THE GROIN.

Superficial Arteries of the Groin.

The *superficial epigastric* artery comes through the fascia lata, sometimes through the saphenous opening, half an inch (13 mm.) below Poupart's ligament. It ascends over Poupart's ligament to pass to the subcutaneous tissue of the abdomen, as high as the umbilicus, and supplies the inguinal glands, and anastomoses with the deep epigastric and internal mammary arteries. Its further course is described at p. 397.

The *superficial circumflexa ilii* emerges through the fascia lata, runs parallel to Poupart's ligament towards the crest of the ilium,

on the outer side to a rounded prominence, the external condyle; and on the inner to the internal condyle, the latter being the larger. The synovial membrane which lines the knee-joint usually extends about two fingers' breadth above the patella, and is a little higher on the inner than on the outer side of the joint.

An incision should be made along the groin, extending from the anterior superior spine of the ilium to the spine of the os pubis; another, from the middle of the first down the front of the thigh for about six inches (15 cm.). The skin only should be reflected, outwards and inwards, when the superficial fascia will be exposed.

Superficial Fascia. The *superficial fascia* varies in thickness, according to the condition of the body. Like other superficial fasciæ, it is divisible into two or more layers, between which are situated the inguinal glands and the cutaneous vessels and nerves. The superficial layer is continuous with that of the abdomen, and becomes firmer below Poupart's ligament, to which, however, it is not connected; the deeper layer is best marked in the upper part of the thigh, especially where it stretches across the saphenous opening, to the margins of which it is closely attached; this portion is called the *cribriform fascia*, and is protruded forwards by a femoral hernia, forming one of its coverings; this layer is also attached to Poupart's ligament.

The superficial layer of this fascia should now be reflected, by searching for one of the subcutaneous veins (the internal saphena will do) which run between the upper and the deeper layers of the fascia. The cutaneous vessels can thus be traced, and come from the common femoral artery; they are three in number, the *superficial epigastric*, the *superficial external pudic*, and the *superficial circumflexa ilii* arteries. The first ascends over Poupart's ligament to the abdomen (p. 559); the second crosses inwards towards the os pubis; the third passes outwards to the ilium. Each artery is accompanied by one, sometimes by two veins, which empty themselves, either directly into the femoral, or into the great cutaneous vein of the thigh, called the saphena.

Superficial Inguinal Glands. These glands are easily recognized by their oval form and reddish-brown colour. There are two sets: one set runs parallel to Poupart's ligament, and receives the lymphatics from the skin of the penis, the scrotum, the perineum, the anus, the buttock, the lower part of the abdominal wall, and the upper and outer aspect of the thigh; the outer and lower set lies along the saphena vein, chiefly around the saphenous opening, and receives the lymphatics from the foot, the leg, and the lower part of the thigh. This explains why in cancer of the scrotum and syphilitic disease of the penis the first set becomes enlarged; and the second, in diseases of the lower ex-

tremity. The lymphatic vessels which pass to and from the glands are small, and may escape observation, unless specially looked for. They all pass through the femoral ring into the abdomen, and eventually empty themselves into the receptaculum chyli.

The glands mentioned in the preceding paragraph are all superficial. There are others, more deeply seated, close to the great vessels of the thigh; these are much smaller, and sometimes cannot be found.

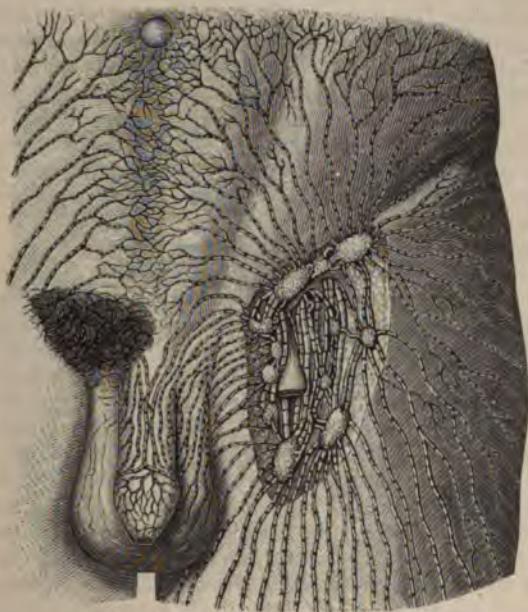

FIG. 311.—LYMPHATIC VESSELS AND GLANDS OF THE GROIN.

**Superficial Arteries
of the Groin.**

The *superficial epigastric* artery comes through the fascia lata, sometimes through the saphenous opening, half an inch (13 mm.) below Poupart's ligament. It ascends over Poupart's ligament to pass to the subcutaneous tissue of the abdomen, as high as the umbilicus, and supplies the inguinal glands, and anastomoses with the deep epigastric and internal mammary arteries. Its further course is described at p. 397.

The *superficial circumflexa ilii* emerges through the fascia lata, runs parallel to Poupart's ligament towards the crest of the ilium,

and ends in the subcutaneous tissue and inguinal glands. It anastomoses with the deep circumflex iliac, the gluteal, and the ascending branches of the external circumflex arteries.

The *superficial external pudic* comes through the saphenous opening, crosses over the spermatic cord, and supplies the penis and scrotum in the male, and the labium in the female. This artery is usually divided in the operation for femoral hernia, also in that for phymosis, since it runs along the penis to supply the prepuce. Arising directly from so large an artery as the femoral, it sometimes bleeds profusely; for it is an admitted fact that when even a small branch, coming directly from a principal artery, is divided near its origin, it will sometimes pour out as much blood as if an opening were punched out of the trunk as large as the area of the divided branch.* There is another pudic artery, called the *deep or inferior external pudic*: this runs between the fascia lata and the pectineus, supplying that muscle, the scrotum in the male, and the labium in the female. They both anastomose with branches of the internal pudic artery.

The incision should be prolonged down the thigh, over the knee, to the tubercle of the tibia. The skin must then be reflected, to expose the subcutaneous tissue over the whole of the front of the thigh. The cutaneous vessels and nerves should be looked for in the subcutaneous fat in the following situations: on the *inner side* are the inguinal branch of the ilio-inguinal nerve passing down through the external abdominal ring, internal to the saphenous opening; *lower down* are the two branches of the internal cutaneous nerve supplying the skin on the inner aspect of the thigh as far as the knee, the lower branch accompanying the internal saphena vein which ascends to pierce the saphenous opening; there are also low down some filaments from the long saphena nerve; on the *front* of the thigh there is found the crural branch of the genito-crural nerve, and lower down, as far as the knee, are the middle cutaneous nerves; on the *outer side* are seen filaments of the external cutaneous nerve.

**Internal Saphena
Vein.**

This is the chief subcutaneous vein of the lower limb. Its roots, arising from the inner side of a venous arch on the dorsum of the foot, unite into a single trunk, which ascends in front of the inner ankle, along the inner side of the leg, behind the knee, along the inner and front part of the thigh, where it passes through an opening—the

* Mr. Liston had occasion to tie the external iliac artery for a supposed injury (by a pistol-ball) to the femoral. It was discovered, after the death of the patient, that the ball had injured only one of the superficial branches of the femoral about an inch from its origin. See his paper in the *Med. Chir. Trans.*, vol. xxix, 1846.

saphenous opening—in the fascia lata, to join the femoral vein, immediately below the crural arch (Fig. 212). In this long course it receives many tributary veins, some of which are often large, especially one which, coursing round the inner part of the thigh, is frequently as large as the main trunk. Just before its termination it is joined by the superficial veins, which accompany the arteries of the groin, already alluded to (p. 559). Like all subcutaneous

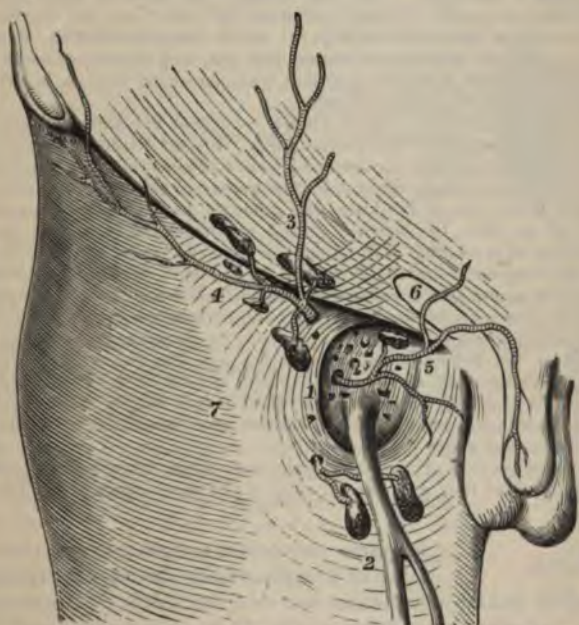


FIG. 212.—SUPERFICIAL VESSELS AND GLANDS OF THE GROIN. SAPHENOUS OPENING WITH THE CRIBRIFORM FASCIA.

1. Saphenous opening of the fascia lata. 2. Saphena vein. 3. Superficial epigastric a. 4. Superficial circumflexa ilii a. 5. Superficial pudic a. 6. External abdominal ring. 7. Fascia lata of the thigh.

veins, it is provided with valves, chiefly where joined by other veins, to support the column of the blood.

Cutaneous Nerves. The distribution of the cutaneous nerves of the thigh varies considerably, but they are always found more abundantly on the inner than on the outer aspect of the thigh. The nerves are divided into *external*, *middle*, and *internal*. All directly or indirectly proceed from the lumbar plexus, and, perforating the fascia lata, divide in the subcutaneous tissue.

a. The *external cutaneous nerve* is a branch of the second and third lumbar nerves. It enters the thigh beneath Poupart's ligament close to the anterior superior spine of the ilium. Here it divides into two branches, an anterior and a posterior. The *anterior* branch comes through the fascia lata about four inches (10 cm.) below Poupart's ligament, and can be traced down the outer side of the thigh as far as the knee, giving off numerous branches. The *posterior* branch, after coming through the fascia lata, divides into filaments, which are distributed to the skin over the nates and the posterior part of the thigh.

b. The *middle cutaneous nerves*, one or two in number, are given off by the anterior crural in the thigh. They pass through the sartorius about four inches (10 cm.) below Poupart's ligament, perforate the fascia lata, and descend along the front and inner part of the thigh as far as the knee, distributing branches on either side, some of which communicate with the long saphenous nerve. In its course along the front of the thigh it joins with the crural branch of the genito-crural and the internal cutaneous nerves.

c. The *internal cutaneous nerve*, also a branch of the anterior crural, crosses obliquely over the sheath of the femoral artery. It then divides into two branches, an anterior and an internal; the *anterior branch* comes through the fascia lata in the lower third of the thigh, where it terminates in two branches, one being distributed to the inner side of the knee, the other crossing over the patella to the outer side of the joint; the *internal branch* perforates the fascia lata just above the knee-joint, after running down along the posterior border of the sartorius, and supplies the integument on the inner side of the leg. Whilst still beneath the fascia lata, the internal cutaneous nerve unites below the adductor longus in a plexiform manner with the long saphenous and obturator nerves.*

d. The *crural branch of the genito-crural nerve* perforates the anterior layer of the sheath of the femoral vessels, comes through the fascia lata immediately below Poupart's ligament, and supplies the skin in front of the thigh. About two or three inches (5 to 7.5 cm.) below the crural arch it usually communicates with the middle cutaneous nerve. It also distributes a few filaments to the femoral artery in its passage under the crural arch.

e. The *inguinal branch of the ilio-inguinal nerve*, after emerging from the external abdominal ring, supplies the skin on the inner aspect of the upper third of the thigh.

Fascia Lata.

Remove the subcutaneous fat and the deeper layer of the superficial fascia, to examine the dense white fascia—the *fascia lata*—of the thigh. The use of this fascia is to cover the muscles of the thigh collectively, and to form separate sheaths for each; so that it not only keeps them together, but maintains each in its proper position. A knowledge of these sheaths is important, because they interfere with the progress of deep-seated matter towards the surface, and cause it to burrow in this or that direction according to the part in which it forms.

The fascia is not of equal strength all round the thigh. It is comparatively thin on the inner side; exceedingly thick and strong

* It is important to note that one, sometimes two, of these branches of the internal cutaneous crosses the sheath of the femoral artery, just where the sartorius begins to overlap it, and therefore at the spot where it is usually tied. See diagram, p. 573.

down the outer side; here, indeed, it has the appearance of a dense expanded aponeurosis, strapping down the vastus externus muscle, and is sometimes called the *ilio-tibial band*; and it certainly performs the office of a tendon, for it gives insertion between its two layers to two powerful muscles—namely, the tensor fasciæ femoris, and the gluteus maximus (Fig. 213).

The fascia lata is attached to the margin of the bones which constitute the framework of the lower extremity. Beginning from above, its attachment can be traced from the posterior surface of the sacrum and coccyx, along the crest of the ilium, thence along Poupart's ligament to the body of the os pubis and the linea ilio-pectinea, and along the rami of the os pubis and ischium. Proceeding down the thigh, it penetrates on each side of the limb to the linea aspera, forming what are called the *external* and *internal intermuscular septa*; the external one, the stronger, separates the vastus externus anteriorly from the short head of the biceps, both of which have origin from the fascia; the internal one separates the vastus internus in front from the adductor muscles behind. Below, it can be traced round the knee-joint, and is particularly strong, especially on the outer side, where it is attached to the head of the tibia and fibula, and forms the insertion of the tensor fasciæ femoris. The fascia lata is very strong over the gluteus medius—the *gluteal aponeurosis*—and at the upper border of the gluteus maximus divides into two layers, one superficial to the muscle, the other deep, which separates this muscle from the deeper muscles, and becomes connected with the great sacro-sciatic ligament. The fascia lata also furnishes thinner sheaths for the separate muscles.

There are numerous small apertures in the fascia, through which the cutaneous nerves and vessels are transmitted; but the most important one is the large opening—the *saphenous opening*—through which the saphena vein passes to join the femoral. The part of the fascia situated external to the saphenous opening is termed the iliac portion of the fascia lata; that internal to it, the pubic portion.

The *iliac portion* is attached to the crest of the ilium, to the whole length of Poupart's ligament, and, in conjunction with Gim-



FIG. 213.—FASCIA ON THE OUTSIDE OF THE THIGH.

1. Tensor fasciæ femoris.
2. Gluteus maximus.
3. Lower fibres of ditto.
4. Fascia lata.

bernat's ligament, to the linea ilio-pectinea; from this attachment it arches downwards and outwards, its inner margin forming the outer falciform edge of the saphenous opening; this border passes over the anterior sheath (formed by the transversalis fascia) of the femoral artery, and is seen to be continuous below with the *pubic portion*, which can be traced upwards over the pectineus and adductor longus muscles, behind the posterior sheath (formed by the iliac fascia) of the femoral vessels, where it is connected with the sheath of the iliacus and psoas muscles and the fibrous structures of the hip-joint. Above, it is attached to the linea ilio-pectinea, to the body and the ramus of the os pubis.

**Saphenous Opening
in the Fascia Lata.**

The *saphenous opening* is an oval aperture in the fascia lata, immediately below the crural arch, on the inner side of the front of the thigh, through which the saphena vein passes to join the femoral.

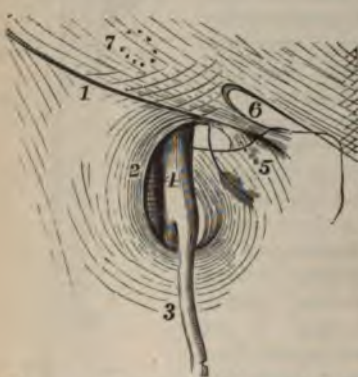

FIG. 214. DIAGRAM OF THE FEMORAL RING AND THE SAPHENOUS OPENING.

(The arrow is introduced into the femoral ring.)

1. Crural arch. 2. Saphenous opening of the fascia lata. 3. Saphena vein. 4. Femoral vein. 5. Gimbernat's ligament. 6. External abdominal ring. 7. Position of the internal ring in dotted outline.

There is no definite border to the saphenous opening until the fascia—*cribriform*, which covers the opening and blends with its margin—has been removed. It is situated just below the crural arch and external to the spine of the os pubis; it is oval, with the long axis vertical, and is about one inch and a half (3.8 cm.) long and an inch (2.5 cm.) broad. Its border on the inner side is not defined; for here the fascia lata ascends under the femoral vessels, and is continuous with the iliac fascia of the pelvis.* But the outer or iliac border is clearly defined. This lies in front of the femoral vessels, is crescent-shaped, with the concave upper end towards the os pubis, and is called the *falciform process*, whilst

its deeper fibres are known as *Burns' ligament*. The lower horn of the crescent curves under the saphena vein with a well-defined border, and on being traced upwards becomes less well-marked until it is gradually lost in the fascia on the inner side of the

* On the inner side of the femoral vessels the pubic portion of the fascia is attached to the linea ilio-pectinea.

opening. The upper horn, *Hey's ligament*,* arches over the femoral vein, and then descending slightly is continued uninterruptedly into Gimbernat's ligament—*i.e.*, into that part of the crural arch which is inserted into the linea ilio-pectinea. The upper horn deserves especial attention, because it forms the upper boundary of the aperture through which a femoral hernia takes place; and, being chiefly concerned in the constriction of the rupture, must be divided for its relief. This may be easily ascertained by introducing the little finger under the crural arch, on the inner side of the femoral vein—in other words, into the femoral ring (see the arrow, Fig. 214). Feel how the upper horn of the crescent would gird the neck of a hernia, and that its tension is greatly influenced by the position of the limb; for if the thigh be bent and brought over to the other side, the tension of all the parts is materially lessened.†

Cribriform Fascia. The *cribriform fascia* is so called because it is perforated with numerous apertures for the passage of the superficial vessels and lymphatics. It is a thin membranous covering over the saphenous opening, and is prolonged from the outer edge of the opening over the sheath of the femoral vessels, and adheres on the inner side to the fascia lata, over the pectineus muscle. Some anatomists describe this fascia as a portion of the deeper layer of the superficial fascia; others consider it as a thin prolongation of the fascia lata itself across the opening. Its chief surgical importance is derived from the fact that it forms one of the coverings of a femoral hernia.

The cribriform fascia must now be removed on one side so as to display the saphenous opening, which will appear as represented in Fig. 214.

ANATOMY OF THE PARTS CONCERNED IN FEMORAL HERNIA.

The anatomy of the parts concerned in femoral hernia cannot be thoroughly understood without the assistance of special dissections. The following demonstration therefore takes for granted that the student has the opportunity of seeing the parts, not only on their femoral, but also on their abdominal side.

* The upper horn is sometimes called *Hey's ligament*, after the surgeon who first drew attention to it. (*Observations in Surgery*, by W. Hey, F.R.S. London, 1810.)

† We must always bear in mind that, though the crural arch and the fascia attached to it have received particular names, they are not, on that account, distinct and separate; but all are intimately connected, and portions merely of one continuous expansion. Thus all the parts are kept in a condition of mutual tension, which depends very much on the position of the thigh.

The different parts of the subject should be examined in the following order:—

- a. The formation of the crural arch.
- b. The arrangement of the parts as they pass under the arch.
- c. The sheath of the femoral vessels.
- d. The crural canal and ring.
- e. The practical application of the subject.

**Poupart's Ligament
or Crural Arch.**

The lower border of the aponeurosis of the external oblique muscle extends from the anterior superior spine of the ilium to the spine of the os pubis, and forms over the bony excavation beneath the *crural arch* or *Poupart's ligament*. (It is marked by the dark line in Fig. 214.) The direction of the arch is at first somewhat oblique, but towards its inner half becomes nearly horizontal. In consequence of its intimate connection with the fascia lata of the thigh, the line of the arch describes a gentle curve with the convexity downwards. The arch is attached to the spine of the os pubis, and also for some distance along the linea ilio-pectinea (Fig. 214). This additional attachment, called *Gimbernat's ligament*, is of importance, for it is frequently the seat of stricture in femoral hernia.

**Gimbernat's Liga-
ment.**

The best view of Gimbernat's ligament is obtained from within the abdomen, it being only necessary to remove the peritoneum. It is that portion of the aponeurosis of the external oblique muscle which is inserted into the linea ilio-pectinea for about an inch (2.5 cm.) in length. It is placed nearly horizontally in the erect posture, and is triangular with its apex at the os pubis and its base directed outwards. In front, it is continuous with the crural arch; behind, it is inserted into the linea ilio-pectinea; externally, it is continuous with the fascia lata through Hey's ligament (Fig. 214). Its length is from three-quarters of an inch to one inch (18 mm. to 2.5 cm.); but it is usually longer in the male than in the female.

On putting your finger into the femoral ring, you feel the sharp and wiry edge of this ligament; observe, too, that as the body lies on the table, the plane of the ligament is perpendicular, and therefore that it *recedes from the surface*.

An incision should now be made through the fascia lata along the entire length of Poupart's ligament; another also through the fascia vertically, from the anterior superior iliac spine down the thigh for about four inches (10 cm.), and the fascia lata carefully dissected downwards and inwards from the subjacent structures. This will expose the structures as they pass under Poupart's ligament in their course down the thigh.

Arrangement of the
Parts which pass
under the Arch.

The crural arch transmits from the abdomen into the thigh (proceeding in order from the outer side) the following objects shown in Fig. 215: 1. The external cutaneous nerve. 2. The iliacus with the anterior crural nerve lying on it near its inner border. 3. The femoral artery resting on the psoas muscle. 4. The crural branch of the genito-crural nerve. 5. The femoral vein. 6. The crural sheath surrounding the femoral vessels, formed in front by the fascia transversalis, behind by the fascia iliaca. 7. The lymphatics passing upwards through the femoral canal. 8. The pectineus. These muscles and vessels fill up the space beneath the crural arch, except on the inner side of the femoral vein, where a

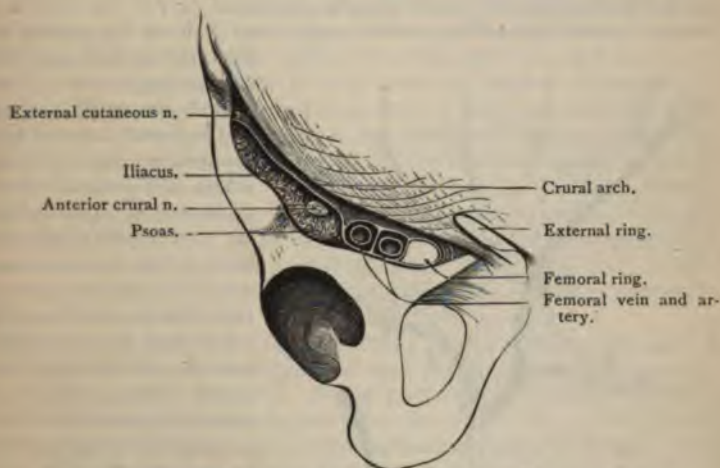


FIG. 215.—POSITION OF PARTS UNDER THE CRURAL ARCH (VERTICAL SECTION).

space is left for the passage of the lymphatics: this is called the *crural* or *femoral ring*. The muscles are separated from the vessels by a strong vertical fibrous partition passing from the arch to the bone, which is nothing more than a continuation of the sheath of the psoas. The artery, too, is separated from the vein by a similar, although a much weaker partition, and there is a third close to the inner side of the vein. These three partitions not only keep all the parts in their right place, but confine the arch down to the bone, and prevent its being uplifted by any protrusion between it and the muscles and vessels. This, coupled with the close attachment of the fascia iliaca to the crural arch, explains why a

femoral hernia rarely takes place in any other situation than on the inner side of the femoral vein.*

**Sheath of the
Femoral Vessels.**

The femoral vessels descend beneath the crural arch, enclosed in a funnel-shaped membranous sheath. This sheath appears to be derived immediately from the arch itself, but it is really formed *in front* by a prolongation from the fascia transversalis of the abdomen. This prolongation, uniting with the continuation from the fascia iliaca (to join the fascia lata) *behind* the femoral vessels, forms a funnel, with the wide part uppermost, into which the femoral vessels enter. This is the funnel-shaped sheath of the femoral vessels.

The fascia transversalis, descending over the femoral vessels, forms the *front part* of their sheath; the *hind part* of the sheath is formed by the fascia iliaca, which runs down behind the vessels to

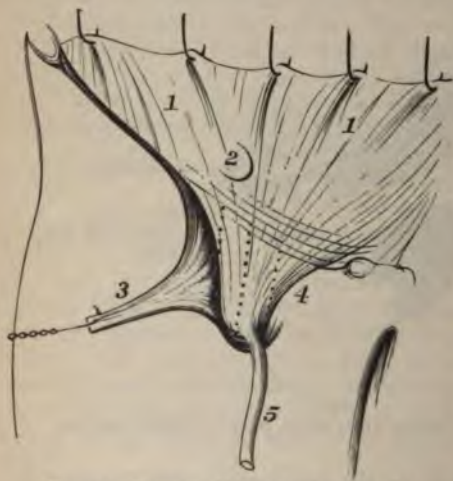


FIG. 216.—DIAGRAM OF THE SHEATH OF THE FEMORAL VESSELS.

1, 1. Fascia transversalis. 2. Internal ring. 3. Crural arch reflected. 4. Sheath of the femoral vessels. 5. Saphena vein.

join the pubic portion of the fascia lata. The sheath descends as low as the lower horn of the saphenous opening, where it is gradually lost upon the external cellular coat (tunica adventitia) of the femoral vessels. The outer part of the sheath, in front, is perforated by the crural branch of the genitocrural nerve, and the superficial arteries of the groin; the inner part, by the saphena vein and some lymphatic vessels.

The sheath of the femoral vessels is divided into three compartments separated from each other by partitions: the outer is occupied by the

femoral artery; the middle, by the femoral vein; the inner is the crural canal, into which a femoral hernia descends.

* If the partitions from any cause yield, or become slack, then a rupture may descend in front of the vessels, or even (though this is rare) on the outer side of the artery.

The *deep crural arch* is the thickened band of fibres connected with the front of the crural sheath; the fibres run in the same direction as the crural arch, but quite independently of it, as shown in Fig. 216; these bands lie over the neck of the sac of a femoral hernia, and are often the seat of the stricture.

Practically, the sheath is important for many reasons:—

1. A femoral hernia descends within it. 2. It constitutes, therefore, one of the coverings, *fascia propria*, of the hernia. 3. It contains within its substance the *deep crural arch*, which not infrequently forms the stricture of a femoral hernia, and has, therefore, to be divided before the intestine can be returned.

**Crural Canal and
Femoral Ring.**

The hollow under the crural arch is completely occupied by the structures before mentioned, except for a small triangular space, forming the inner compartment of the femoral sheath, called the *crural canal*. The canal is on the inner side of the femoral vein, and is from a quarter to half an inch (6 mm. to 13 mm.) in length. Its base commences above in the femoral ring, and its apex ends below at the saphenous opening. *In front*, it has Poupart's ligament and the falciform process of the iliac portion of the fascia lata, and is formed by the fascia transversalis; *behind*, it is formed by the fascia iliaca; *internally*, it is formed by the junction of the fascia transversalis and the fascia iliaca, and is in relation with the base of Gimbernat's ligament; *externally*, it is separated from the femoral vein by the septum of fascia which divides the middle from the inner compartment of the crural sheath.

The *femoral ring* is the upper opening of the crural canal, and is bounded, *in front*, by the superficial and deep crural arches; *behind*, by the horizontal ramus of the os pubis, the pectineus, and the pubic portion of the fascia lata; on the *outer side*, by the fasciæ septum separating it from the vein; on the *inner side*, by the thin, wiry edge of Gimbernat's ligament, the conjoined tendon of the internal oblique and transversalis, the fascia transversalis, and the fibres of the deep crural arch. In the undisturbed condition of the parts there is no gap; it is only a weak place, which, when a hernia escapes through it, feels like a ring: hence the name of *femoral ring*.*

The femoral ring is surrounded on all sides by unyielding structures. This accounts for the little benefit afforded by the warm bath in cases of strangulation. Sir W. Lawrence was in the habit of

* The femoral ring is naturally occupied by a little fat and cellular membrane, by lymphatic vessels, and often by a small lymphatic gland. But we have never met with anything deserving the name of a diaphragm or membranous septum, such as is described by Cloquet as the *septum crurale*, and is, surgically, of no importance.

saying that he never saw a strangulated femoral hernia where the warm bath was of any avail.

Practical Application of the Subject. From what has been said, the student ought now to understand—1, at what aperture a femoral hernia escapes from the abdomen; 2, the course which it takes, and its relations to the surrounding parts; 3, the proper mode of attempting the reduction; 4, the structure and arrangement of its coverings; and 5, the probable seat of stricture.

The hernia escapes from the abdomen through the femoral ring—that is, under the weak part of the crural arch, between the femoral vein and Gimbernat's ligament. Here is the mouth of the hernial sac, or that part of it which communicates with the abdomen. It descends for a short distance nearly perpendicularly, and projects as a small tumour in front of the pectineus muscle. Its progress downwards, however, is soon arrested, partly by the very close adhesion of the subcutaneous structures to the lower margin of the saphenous opening; partly by the flexion of the thigh. Consequently, if the hernia increases in size, it usually rises over the crural arch, where the subcutaneous tissue offers less resistance; and the bulk of the hernia extends outwards towards the ilium, assuming more or less of an oblong form, with the long axis parallel to the crural arch. Since, then, the body of the hernia forms a very acute angle with the neck, the right mode of attempting its reduction is to draw it, first down from the groin, and then to make pressure on it backwards in the direction of the femoral ring.

Coverings of a Femoral Hernia. The *coverings* of a femoral hernia are as follows: It first protrudes before it the *peritoneum*, technically called the hernial sac.*

The sac is covered by more or less fat, according to the condition of the patient, called the *subperitoneal fat*. It next pushes before it the *sheath of the femoral vessels*, which forms an investment more or less thick. In front of this is the *cribriform fascia*. Lastly, there is the *subcutaneous tissue and skin*.

Seat of Stricture. The *seat of stricture* is usually at the femoral ring, and the position of the neighbouring blood-vessels indicates that the proper direction in which to divide the stricture is either directly inwards, through Gimbernat's ligament, as recommended by Sir W. Lawrence, or upwards, through Hey's ligament, as recommended by Sir A. Cooper.†

* In some cases the fascia propria so much resembles the hernial sac that it is not easy to distinguish between them. Generally speaking, they are separated by a small quantity of fat.

† The operation recommended by Sir A. Cooper is that usually performed now; because, if Gimbernat's ligament be divided, its cut edges often retract to such an extent that no truss can possibly retain the hernia when the patient assumes the erect posture.

There is no risk of wounding an artery, supposing the vessels to take their ordinary course. But it occasionally happens (Fig. 217) that the obturator artery runs *above* (in the recumbent position) the femoral ring; in such a case, the neck of the sac would be encircled by a large blood-vessel. From the examination of two hundred bodies, the chances are about seventy to one against this unfavourable distribution. But the possibility of it has given rise to *this rule* in practice—not to cut deeply in any one place through the stricture, but rather to notch it in several. By this proceeding we are much less likely to wound the abnormal artery, because it does not run at the base of Gimbernat's ligament, but about $\frac{1}{8}$ of an inch (3 mm.) from the margin of it.

Such is an outline of the anatomy of the parts concerned in a

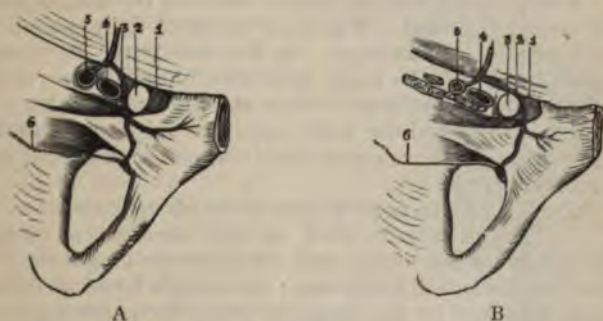


FIG. 217.—VIEW OF THE DIFFERENT DIRECTIONS WHICH AN ABNORMAL OBTURATOR ARTERY MAY TAKE. (SEEN FROM ABOVE.)

- A. 1. Gimbernat's Ligament 2. Femoral ring. 3. Abnormal obturator artery. 4. External iliac vein. 5. External iliac artery. 6. Diminutive obturator artery arising from its normal source. B. 1. Gimbernat's ligament. 2. Abnormal obturator artery. 3. Femoral ring. 4. External iliac vein. 5. External iliac artery. 6. Diminutive obturator artery.

femoral hernia. The normal anatomy in each case being similar, it might be supposed that all operations for the relief of this kind of hernia would be straightforward and pretty much alike; but this is very far from being the case; indeed, surgeons agree that they never operate without the expectation of meeting some peculiarity.

The fascia must now be removed from the
Dissection. ^a front of the thigh without disturbing the subjacent muscles from their relative positions. The mass of muscles on the inner side of the thigh consists of the adductors; that in the middle, of the extensors; the long thin muscle crossing obliquely in front from the outer to the inner side is the sartorius. In the

middle are seen the femoral vessels, and the anterior crural nerve emerging beneath the crural arch.

Sartorius.

This, a narrow, flat muscle (Fig. 218), *arises* from the anterior superior spine of the ilium, and from the ridge below to the extent of an inch (2.5 cm.). It passes obliquely like a strap over the front of the thigh towards the inner side, and then descends almost perpendicularly on the inner side of the thigh as far as the knee, where it terminates in a flat tendon which expands, and is *inserted* into the inner and front part of the tibia just below its tubercle. The tendon appears all the wider on account of its broad connection with the fascia of the leg, which extends as low as the internal malleolus. The broad insertion of this muscle lies anterior to and covers the tendinous insertions of the gracilis and semi-tendinosus, and between them is a bursa. A large bursa * is interposed between the tendon and the internal lateral ligament. The chief *action* of the muscle is to fix the pelvis steadily on the thigh. It first bends the leg upon the thigh, and then bends the thigh upon the abdomen. It crosses one leg over the other, as tailors sit when at work. If the leg be the fixed point, it will bend the trunk upon the thigh and rotate the pelvis inwards. Its nerve comes from the middle cutaneous branch of the anterior crural.

Scarpa's Triangle.

In consequence of the oblique direction of the upper third of the sartorius, a triangle is formed, which has this muscle and the adductor longus for its two sides, and the crural arch for its base; the triangle is called *Scarpa's*. †

Its floor is formed by the iliacus, the psoas, the pectineus, and the adductor longus, with sometimes the adductor brevis between the borders of the two latter muscles. The contents of this important space should be carefully displayed, and their relative positions well studied. This triangle contains all the parts which pass under the crural arch, namely, from without inwards, the external cutaneous nerve, close to the anterior spine of the ilium; the iliacus and psoas; the anterior crural nerve and its divisions, especially the long saphenous nerve; the crural branch of the genito-crural nerve, the common femoral artery with its two large divisions, the superficial femoral and the profunda, which run down, nearly parallel to each other, the latter being the more external and giving off the internal and external circumflex arteries; the femoral vein, joined by the profunda vein and the internal saphena, and the pectineus muscle with the deep external pudic artery.

* In persons, females especially, who are in the habit of riding, this bursa sometimes becomes enlarged.

† So called in compliment to the Italian anatomist who first tied the femoral in it for popliteal aneurism.

The triangle is important in a surgical point of view, since it is in this space that the femoral artery is usually ligatured for popliteal aneurism. The guide to the artery is the inner border of the sartorius. The situation at which this muscle crosses over the femoral artery varies from one and a half to four and a half inches (3.8 to 11.3 cm.) below Poupart's ligament; so that no rule can be laid down as to the exact situation where the artery disappears beneath the sartorius. The best way to find the inner border of the muscle during life is to make the patient put it in action.

Adductor Muscles. A strong group of muscles, called the *adductors*, extends along the inner side of the thigh, from the pelvis to the femur. Their two most important actions are to cooperate in balancing the pelvis steadily on the thigh, as in standing on one leg, and (if the fixed point be reversed) to draw together or adduct the thighs, at the same time rotating the thigh externally. They are five in number, and are supplied, with one exception—the pectineus—by the same nerve, namely, the obturator. They are termed, respectively, the gracilis, adductor longus, pectineus, adductor brevis, and adductor magnus. The innermost is the gracilis; to clean it properly it should be stretched by separating one thigh from the other.

Gracilis.

This long, flat muscle *arises* by a broad, ribbon-like tendon, two to three inches (5 to 7.5 cm.) in breadth, from the os pubis close to the symphysis, and from the inner margin of the rami of the os pubis and ischium (Fig. 219). It descends almost perpendicularly on the inner side of the thigh, and terminates in a thin, round tendon which subsequently spreads out, and is *inserted* into the inner side of the upper part of the tibia

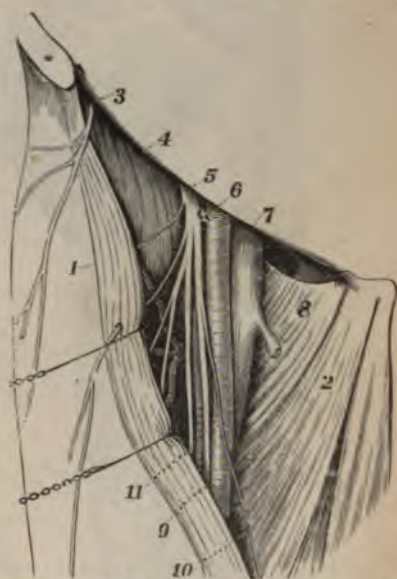

FIG. 218.—DIAGRAM OF SCARPA'S TRIANGLE.

1. Sartorius. 2. Adductor longus. 3. External cutaneous n. 4. Iliacus internus. 5. Anterior crural n. 6. Femoral artery. 7. Femoral vein. 8. Pectineus. 9. Long saphenous n. 10. Internal cutaneous n. 11. Nerve to vastus internus. 12. Middle cutaneous n.

below the tubercle, immediately behind the sartorius and above the semi-tendinosus. The tendon plays over the internal lateral

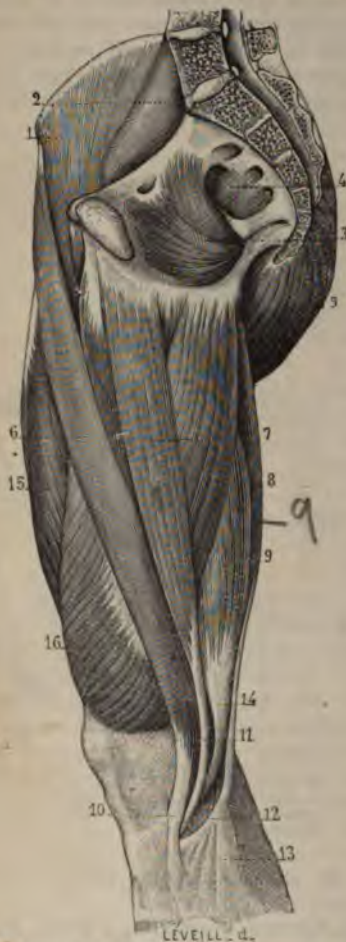

FIG. 219.—INTERNAL MUSCLES OF THE THIGH.

1. Iliacus. 2. Psoas magnus. 3. Obturator internus. 4. Pyramidalis. 5. Gluteus maximus. 6. Sartorius. 7. Gracilis. 8. Semi-tendinosus. 9. Semi-membranosus. 10. Tendon of the sartorius and its fibrous expansion. 11. Tendon of the gracilis. 12. Tendon of the semi-tendinosus. 13. Common fibrous expansion. 14. Tendon of the semi-membranosus. 15. Rectus femoris. 16. Vastus internus.

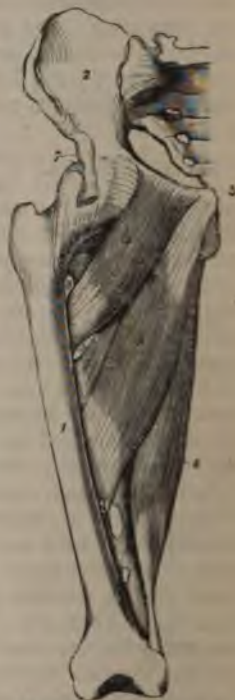

FIG. 220.—PECTINEUS AND ADDUCTORS.

1. Femur. 2. Os iliopectineum. 3. Pubis. 4. Pectineus. 5. Adductor longus. 6. Lower or long portion of the adductor magnus. 7. Tendon of origin of the rectus femoris. 8. Vascular foramina. 9. Hunter's canal.

ligament of the knee-joint, and there is a bursa common to it and the semi-tendinosus to diminish friction. This muscle assists in fixing the pelvis and in adducting the thigh; it further helps to bend the knee. Its nerve comes from the anterior division of the obturator.

Adductor Longus.

This triangular muscle lies between the gracilis and the pectineus, and *arises* by a round tendon from the front of the body of the os pubis below the crest (Fig. 220). As it descends, the muscle becomes broader, and passing downwards, outwards, and backwards, is *inserted* by a broad aponeurosis into the middle third of the inner margin of the linea aspera of the femur. It forms with the sartorius the triangular space called Scarpa's triangle, above described. It rests upon the adductor brevis and magnus, the profunda vessels, and the anterior branches of the obturator vessels and nerve. It is supplied by the anterior division of the obturator nerve.

Pectineus.

This muscle lies on the same plane, but external to the adductor longus, from which it is separated by a slight interval, in which may be seen the adductor brevis and the anterior division of the obturator nerve (Fig. 220). It *arises* from the linea ilio-pectinea, from the triangular surface of the os pubis in front of the line, and from the fascial prolongation of Gimbernat's ligament covering the muscle; it passes downwards, outwards, and backwards, and is *inserted* into the upper part of the ridge leading from the lesser trochanter to the linea aspera. It lies upon the capsular ligament of the hip-joint, the adductor brevis, the obturator vessels and nerve, and the obturator externus. Its nerve comes from the anterior crural which runs under the femoral vessels to enter it close to its outer border; sometimes also from the obturator, and the accessory obturator if present (p. 461).

By separating the contiguous borders of the pectineus and the adductor longus, the adductor brevis is exposed with the anterior division of the obturator artery and nerve lying upon it. To obtain a complete view of it, the pectineus and adductor longus must be reflected from their origins and turned downwards. The obturator nerve supplies all the adductors. It leaves the pelvis through the upper part of the obturator foramen, and soon divides into an anterior and posterior branch; the *anterior* runs in front of the adductor brevis and supplies the hip-joint, the adductor longus, the gracilis, and sometimes the adductor brevis and the pectineus; the *posterior* runs behind the adductor brevis, and supplies it as well as the obturator externus, the adductor magnus, and the knee-joint.

The student should now, before the parts are disturbed, examine the femoral artery as it passes down along the centre of Scarpa's

triangle; its further course will be described later on, as well as the branches which come off from it.

**Course and Relations
of the Femoral
Artery.**

The *femoral artery* is a continuation of the external iliac. Passing beneath the crural arch at a point midway between the spine of the ilium and the symphysis pubis, it descends along the front and inner side of the thigh. At the junction of the upper two-thirds with the lower third of the thigh, it passes through an opening in the tendon of the adductor magnus, and, entering the ham, takes the name of popliteal. A line drawn from the point indicated, of the crural arch to the adductor tubercle on the internal condyle, corresponds with the course of the artery. Its distance from the surface increases as it descends. Immediately under, and for a short distance below the crural arch, it is supported by the inner border of the psoas; lower down it runs in front of the pectineus, but separated from it by the profunda vessels; still lower down it lies upon the adductor longus, and then upon the adductor magnus.

That part of the artery which extends from the crural arch to the giving off of the profunda is called the common femoral artery; its continuation beyond the profunda is termed the superficial femoral; and it is the latter vessel which is ligatured for aneurism of the popliteal artery.

In the *upper third of the thigh*, the artery is situated in Scarpa's triangle, and is comparatively superficial, having *in front* the skin, superficial fascia and fat, inguinal glands, deep fascia, the fascia lata, the crural branch of the genito-crural nerve, and the sheath of the femoral vessels. About the *middle third* it is more deeply seated, and is covered in addition by the sartorius, and lower down by a tendinous aponeurosis, which stretches from the adductor longus and magnus over to the vastus internus. This, which forms part of Hunter's canal, will be examined presently.

The femoral artery in Scarpa's triangle *lies upon* the psoas, the two branches of the anterior crural nerve to the pectineus, the profunda vein, and the pectineus; to its *outer side* it has the anterior crural nerve (separated from it by a few fibres of the ilio-psoas), the profunda artery, and the long saphena nerve; to its *inner side* it has the femoral vein.

Adductor Brevis. This muscle *arises* from the front surface of the body of the os pubis below the spine, and from its descending ramus for about an inch (2.5 cm.), between the gracilis and the obturator externus; it widens as it descends outwards and backwards, and is *inserted* behind the pectineus into the whole length of the ridge leading from the lesser trochanter to the linea aspera. Behind, it rests upon the posterior division of the

obturator vessels and nerve and the adductor magnus. Its nerve is derived from the obturator. By reflecting it from its origin the following muscle is exposed.*

Adductor Magnus. This muscle arises from the lower part of the descending ramus of the os pubis between the adductor brevis and obturator externus, from the margin of the ascending ramus of the ischium, and from the lower and anterior part of the tuberosity of the ischium (Fig. 221). Its fibres spread out, and are *inserted* behind the other adductors into the lower part of the linea quadrati into the ridge leading from the great trochanter to the linea aspera, also into the whole length of the linea aspera, and the ridge leading from it to the inner condyle; while those fibres which arise from the tuberosity of the ischium pass vertically downwards, and are inserted by a rounded tendon into the adductor tubercle on the inner condyle of the femur. Between the muscular fibres of the middle and lower thirds of the insertion of this muscle, the femoral artery passes to the back of the thigh. The upper fibres pass transversely outwards to their insertion, while the lower fibres descend nearly vertically. In front of the muscle are the adductor longus and brevis, the vastus internus, the obturator nerve and artery, and the profunda artery; above it are the internal circumflex artery, the obturator externus, and the quadratus femoris; behind it, the biceps, semi-tendinosus and semi-membranosus, the great sciatic nerve, and the gluteus maximus. Its nerve comes from the posterior division of the obturator and the great sciatic. Observe that all the adductor muscles are inserted into the femur by flat tendons more or less connected.

About the junction of the upper two-thirds with the lower third of the thigh the femoral artery passes through an oval opening in the tendon of the adductor magnus,—Hunter's canal.

Psoas Magnus and Iliacus. These muscles have been fully described in the dissection of the abdomen (p. 453).

Tensor Fasciæ Femoris. This muscle is situated at the upper and outer part of the thigh (Fig. 222). It *arises* from the anterior part of the external lip of the crest of the ilium, and from the surface below the anterior superior spine. It descends with a slight inclination backwards, and is *inserted* at the junction of the upper with the middle third of the thigh, between two layers of the strong aponeurosis, generally described as part of the fascia lata, which is continued downwards to the head of the tibia, and is called

* Beneath the adductor brevis, and running parallel with the upper border of the adductor magnus, is seen the obturator externus. But the description of this muscle is deferred till the dissection of the external rotators of the thigh.

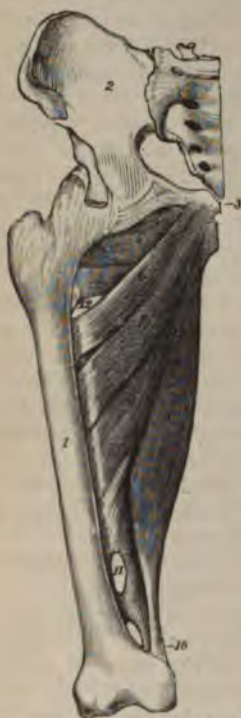

FIG. 221.—ADDUCTOR MAGNUS AND BREVIS.

1. Femur. 2. Os innominatus. 3. Pubis. 4. Obturator externus. 5. Superior portion of the adductor magnus. 6, 7. Adductor brevis. 8. Middle portion of the adductor magnus, almost entirely covered by the adductor brevis. 9. Inferior portion of the adductor magnus. 10. Tendon attached to the internal condyle. 11. Hunter's canal. 12. Vascular foramen for the circumflex vessels.



FIG. 222.—ANTERIOR MUSCLES OF THE THIGH.

1. Iliac bone. 2. Psoas magnus. 3. Tensor fasciæ femoris. 4. Band of fibrous tissue (or sheath) by which the muscle is attached to the forepart of the external tuberosity of the tibia. 5. Sartorius. 6. Rectus femoris. 7. Vastus externus. 8. Vastus internus. 9. Gracilis. 10. Adductor longus. 11. Pectineus.

the *ilio-tibial band* (p. 563).* Its chief use is to fix the pelvis steadily on the thigh, and to rotate the thigh inwards; in this last action it co-operates with the anterior fibres of the *gluteus medius*, with which it is almost inseparably connected. Anyone may convince himself of this by placing his hand on the hip and rotating the thigh inwards. Both these muscles are supplied by the same nerve—the superior gluteal.

To form an adequate idea of the strength, extent, and connections of the aponeurosis on the outer side of the thigh, it should be separated from the *vastus externus* muscle upon which it lies. There is no difficulty in doing so, for it is united to the muscle by an abundance of loose connective tissue. † With a little perseverance the aponeurosis can be traced to the *linea aspera*, the head of the tibia, and the fibula, completely protecting the outer side of the knee-joint.

**Extensor Muscles or
Quadriceps Extensor.**

The powerful fleshy muscles occupying the front of the thigh, and situated between the *tensor fasciæ* on the outer side, and the adductors on the inner, are the extensors of the leg. One of them, the *rectus*, arises from the pelvis; the other arises from the shaft of the thigh-bone by three portions, called, respectively, the *crureus*, the *vastus internus*, and *externus*. All are supplied by the anterior crural nerve.

To see the origins of the *rectus femoris*, dissect between the origin of the *sartorius* and the *tensor fasciæ*; in doing so, avoid injuring the branches of the external circumflex artery.

Rectus Femoris. This bipenniform muscle *arises* from the pelvis by two strong tendons, which soon unite at an acute angle: one—the straight tendon—is round, and arises from the anterior inferior spine of the ilium; the other—the reflected tendon—is flat, and comes from the rough surface of the ilium, just above the acetabulum (Figs. 220, 7, and 222). The muscle descends along the front of the thigh and is *inserted* into the common extensor tendon, which will be presently examined. The structure of this muscle is remarkable. A tendon runs down the centre, and the muscular fibres are inserted on either side of it, like the vane on the shaft of a feather. Notice also that the surface of the upper part of the *rectus* is aponeurotic in front and muscular behind, while the reverse is seen at the lower part not far from its insertion. Its nerve comes from the anterior crural.

* The deeper of these two layers runs up to be strongly connected with the tendon of the *rectus* and the front of the capsule of the hip-joint.

† When this tissue becomes the seat of suppuration, the pus is apt to extend all down the outside of the thigh, not being able to make its way to the surface by reason of the dense fascia.

Triceps Extensor. This mass of muscle invests like a cloak the greater part of the front and sides of the shaft of the femur; therefore, the whole of it cannot be seen without completely dissecting the thigh. It consists of an outer, middle, and inner portion, called, respectively, the vastus externus, the crureus, and the vastus internus.

The *vastus externus* arises (Fig. 222, 7) by a strong, glistening aponeurosis from the outer side of the base of the great trochanter, from the upper third of the anterior intertrochanteric ridge, from the rough line leading from the greater trochanter to the linea aspera external to the gluteus maximus, from the outer lip of the linea aspera nearly down to the external condyle, and also slightly from the external intermuscular septum. From this origin the fibres pass downwards, forwards, and inwards, and end in a flattened tendon, which is inserted into the outer border of the patella to form part of the common extensor tendon, to be presently described.

The *vastus internus* and *crureus* should be described as one muscle, for they are inseparably connected (Fig. 222, 8). They arise conjointly by an aponeurosis commencing a short distance below the inner two-thirds of the anterior intertrochanteric ridge, from the upper three-fourths of the front and inner surfaces of the shaft of the femur, from the entire length of the inner lip of the linea aspera, and from the internal intermuscular septum. The outer bundle of muscular fibres—the *crureus*—passes vertically downwards; the inner—the *vastus internus*—descends forwards and outwards, and both are inserted by a common aponeurosis into the upper and the inner borders of the patella. The muscular fibres of the vastus internus extend lower than those of the vastus externus.

A few of the deeper fibres of the crureus are inserted into the fold of the synovial membrane of the knee-joint which rises above the patella. These are described as a distinct muscle, under the name of the *sub-crureus*. Their use is to raise the synovial membrane, so that it may not be injured by the play of the patella. Since the triceps is connected to the lower part of the shaft of the femur only by loose connective tissue, there is nothing to prevent the distension of the synovial membrane, in cases of inflammation, to the extent of several inches above the patella.

Common Extensor Tendon. The tendon of the rectus, gradually expanding, becomes connected on its under surface with the tendon of the crureus, and on either side with that of the vasti, and is firmly fixed into the upper part and sides of the patella. From this bone the common extensor tendon—the *ligamentum patellæ*—descends over the front of the knee-joint, and is inserted into the rough part of the tubercle of the tibia. Be-

sides this, the lower fibres of the vasti terminate on a sheet-like tendon, which runs wide of the patella on either side, and is directly inserted into the sides of the head of the tibia and fibula, so that the knee is completely protected all round. The patella is a large sesamoid bone, interposed to facilitate the play of the tendon over the condyles of the femur: it not only materially protects the joint, but adds to the power of the extensor muscles by increasing the angle at which the tendon is inserted into the tibia.

To facilitate the play of the extensor tendon there are two bursæ. One is placed between the ligamentum patellæ and the smooth part of the tubercle of the tibia, the other between the crureus and the lower part of the femur. This last is of considerable size. In early life it is, as a rule, distinct from the synovial membrane of the knee-joint; but after a few years a wide communication frequently exists between them.

Action of the Extensor Muscles. The extensor muscles of the thigh are among the most powerful in the body. Great power of extending the knee is one of the essential conditions of the erect attitude. Without it, how could we rise from the sitting position? When erect, how could we walk, run, or spring? The rectus, by taking origin from the pelvis, gains a double advantage: it acts upon two joints simultaneously, bending the thigh while it extends the knee, as when we advance the leg in walking; it also contributes to balance the pelvis on the head of the thigh-bone, and thus prevents the body from falling backwards. We cannot have a better proof of the power of the extensor muscles than when the patella is broken by their sudden contraction—an injury which sometimes happens when a man, slipping backwards, makes a violent effort to recover his balance.

Bursa over the Patella. The skin over the patella is exceedingly loose, and in the subcutaneous tissue is a bursa of considerable size. Since this bursa is apt to enlarge and inflame in females who are in the habit of kneeling at their work, it is generally called the housemaid's bursa. The bursa is not seated precisely over the patella, but extends some way down the ligamentum patellæ; indeed, in some cases it is entirely confined to this ligament. This corresponds with the position of the tumour which the bursa occasions when enlarged. Generally speaking, in subjects brought for dissection, the wall of the bursa is more or less thickened, and its interior intersected by numerous fibrous cords, remnants of the original cellular structure altered by long-continued friction. Again, the wall of the bursa does not always form a complete sac; sometimes there is a wide opening in it: this explains the rapidity with which inflammation, in some cases, extends from the bursa into the surrounding areolar tissue.

Below the bursa is a layer of fascia lata, and under this is a network of arteries. The immediate covering of the bone, or what may be called its periosteum, is a strong expansion derived from the extensor tendon. This is interesting for the following reason: in ordinary fractures of the patella from muscular action the tendinous expansion over it is torn also; the ends of the bone gape widely, and never unite except by ligament. But in fractures from direct mechanical violence, the tendinous expansion, being entire, maintains the fragments in apposition, so that there is commonly a bony union.

The remaining part of the femoral artery can now be examined after the sartorius has been cut through near its middle and both ends reflected. This part of its course corresponds to the middle third of the thigh, and is contained in Hunter's canal.

Femoral Artery in Hunter's Canal.

In front of the artery are the skin, superficial and deep fasciæ, the long saphena vein, the sartorius, the long saphenous nerve, and the aponeurotic layer forming the anterior boundary of Hunter's canal: to its *outer side*, are the femoral vein and the vastus internus; to its *inner side*, are the adductor longus, the adductor magnus, and the sartorius; *behind* it, are the adductor longus, the femoral vein, and the adductor magnus. The artery and vein lie close together, and are enclosed in a common sheath.

Hunter's Canal.

In the middle third of the thigh, the femoral artery is contained in a tendinous canal* beneath the sartorius, called *Hunter's canal*. This canal at its upper part is rather indistinct; but it gradually becomes stronger towards the opening in the tendon of the adductor magnus. Its boundaries are formed by the tendons of the muscles between which the artery runs. On the inner side are the tendons of the adductor longus and magnus; on the outer side is the tendon of the vastus internus; in front, the canal is completed by an aponeurotic expansion thrown obliquely across from the adductors to the vastus internus, as shown in Fig. 223. In a horizontal section the canal appears triangular. The adaptation of this shape to the exigencies of the case is manifest when we reflect that the muscles keep the sides of the triangle always tight, and thereby prevent any compression of the vessels.



FIG. 223.—SECTION THROUGH HUNTER'S CANAL.

1. Vastus internus. 2. Adductor longus. 3. Aponeurosis thrown across.

* Called Hunter's canal, because it was in this part of its course that John Hunter first tied the femoral artery for aneurism of the popliteal, in St. George's Hospital, A. D. 1785. The particulars of this interesting case are published in the *Trans. for the Improvement of Med and Chir. Knowledge*.

Hunter's canal contains not only the femoral artery and vein, but the internal saphenous nerve. The vein lies behind and to the outer side; the nerve crosses over the artery from the outer to the inner side.

A ligature can be placed around the artery, in the upper third of the thigh, with comparative facility; not so easily in the middle third. The artery is tied for an aneurism of the popliteal, just where the sartorius begins to overlap it, for three reasons: (1) it is more accessible; (2) the coats of the artery at this distance are less likely to be diseased; (3) the origin of the profunda is sufficiently far off to admit of the formation of a clot. An incision beginning about three inches (7.5 cm.) below the crural arch should be made about three inches (7.5 cm.) long over the line of the artery. The muscular fascia should be divided on a director to the same extent. Then, by gently drawing aside the inner border of the sartorius, the artery is seen inclosed in its sheath with the vein. An opening should be made into the sheath, which must be carefully separated from the artery to an extent sufficient to allow the passage of the aneurismal needle. The needle should be turned round the artery from within outwards, great care being taken not to injure the vein. The nerves to be avoided are: the long saphenous, which runs along the outer side of the artery, and the internal cutaneous, which crosses obliquely over it.

Having already traced the superficial branches of the femoral artery in the groin, namely, the superficial epigastric, the external pudic, and the superficial circumflexa ilii (p. 559), we pass on now to the profunda.

Profunda Artery and Branches.

The *profunda femoris*, the chief branch of the femoral, is the proper nutrient artery of the muscles of the thigh, and is considered as a division, rather than a branch, of the common femoral artery. It is given off from the outer and back part of the femoral, from one and a half to three inches (3.8-7.5 cm.) below the crural arch, lying to the outer side of the artery for about two inches (5 cm.) and then runs down behind the femoral till it reaches the tendon of the adductor longus; here the profunda passes behind the adductor, and, piercing the adductor magnus as a small branch, is finally lost in the hamstring muscles.* In most subjects the profunda, for a short distance after its origin, lies rather on the outer

* The point at which the profunda is given off below the crural arch varies very much even in the two limbs of the same body. We have measured it in 19 bodies, or 38 femoral arteries. It varied from half an inch to 3 inches (13 mm. to 7.5 cm.). In 22 cases the profunda came off between 1½ and 2 inches (3.8-5 cm.); in 9 this distance was exceeded; in 7 this distance was less.

side of the femoral and on a deeper plane, on the iliacus: in this situation it might be mistaken for the superficial femoral itself—indeed, such an error has occurred in practice. It soon, however, gets behind the femoral, and lies upon the pectineus, the adductor brevis and magnus; it is separated from the femoral artery, at first, by their corresponding veins; lower down, by the adductor longus.

The branches of the profunda generally arise in the following order: (1) the internal circumflex; (2) the external circumflex; (3) the perforating.

The *internal circumflex* is given off from the inner and back part of the profunda, and then sinks deeply into the thigh between the psoas and pectineus. At the lower border of the obturator externus it divides into two branches: one—the *ascending*—supplies the muscles in its neighbourhood, namely, the pectineus, psoas, adductors, gracilis, and obturator externus, anastomosing with the obturator artery; the other—the *descending*—passes down to behind the adductor brevis to supply it and the adductor magnus; the continuation of the artery called the *transverse* will be seen in the dissection of the back of the thigh, between the adductor magnus and the quadratus femoris. This latter sometimes gives off a small branch to the hip-joint, which runs through the notch in the acetabulum to the ligamentum teres; it afterwards anastomoses with the sciatic, the external circumflex, and superior perforating arteries, forming the *crucial anastomosis*.

The *external circumflex artery* comes off from the outer side of the profunda, runs transversely outwards beneath the sartorius and rectus between the branches of the anterior crural nerve, and then subdivides into three sets of branches, ascending, transverse, and descending. The *ascending* run up to the outer side of the ilium, beneath the tensor fasciæ and gluteus medius, supply these muscles, and anastomose with the terminal branches of the gluteal and deep circumflex iliac arteries. The *transverse* pass directly outwards over the crureus, then enter the vastus externus, and get between the muscle and the femur. They anastomose with the sciatic, the internal circumflex, the gluteal, and the perforating arteries. The *descending*, two or more in number, of considerable size, run down between the rectus and crureus, and supply both these muscles: one branch, larger than the rest, runs down in the substance of the vastus externus, along with the nerve to that muscle, and anastomoses with the superior articular branches of the popliteal.

The *perforating branches* of the profunda are so named because they pass through the adductors to supply the hamstring muscles. There are generally four. The *first* passes between the pectineus and the adductor brevis, then pierces the adductor magnus, and communicates with the internal and external circumflex, the sciatic, and second perforating arteries. The *second*, the largest, passes through the tendons of the adductor brevis and magnus, divides into an ascending and a descending branch, which anastomose respectively with the first and third perforating arteries. It usually furnishes the nutrient artery of the femur. The *third*, given off below the adductor brevis, passes through the tendon of the adductor magnus.

The *fourth*, or terminal branch, passes through the tendon of the adductor magnus, and supplies the hamstring muscles, and anastomoses with the perforating and articular arteries. They not only supply the hamstring muscles—namely, the biceps, semitendinosus, and semimembranosus—but the vastus externus, and even the gluteus maximus. The perforating arteries anastomose with one another, with the internal and external circumflex, and with the sciatic arteries.

Muscular branches, from four to seven in number, are dis-

tributed by the superficial femoral to the sartorius and the vastus internus.

The *anastomotica magna* arises from the femoral artery just before it leaves its tendinous canal. It emerges through the canal, and runs in front of the tendon of the adductor magnus in company with the long saphenous nerve to the inner side of the knee. Here it divides into two branches: one, the *superficial*, accompanies the saphenous nerve beneath the sartorius, and is subsequently distributed to the skin; the other, the *deep*, enters the vastus internus, ramifies over the capsules, and communicates with the other articular arteries.*

Arterial Inosculations.

If the common femoral were tied above the origin of the profunda, how would the circulation be carried on? The gluteal, the ilio-lumbar, and the circumflex iliac communicate with the ascending branch of the external circumflex; the obturator and sciatic communicate with the internal circumflex (Fig. 224); the *arteria comes nervi ischiatici* communicates with branches from the lower perforating and popliteal arteries. Again, how is the circulation maintained when the superficial femoral is tied below the profunda? The descending branch of the external circumflex and the perforating branches of the profunda communicate with the articular branches of the popliteal and the tibial recurrent.†

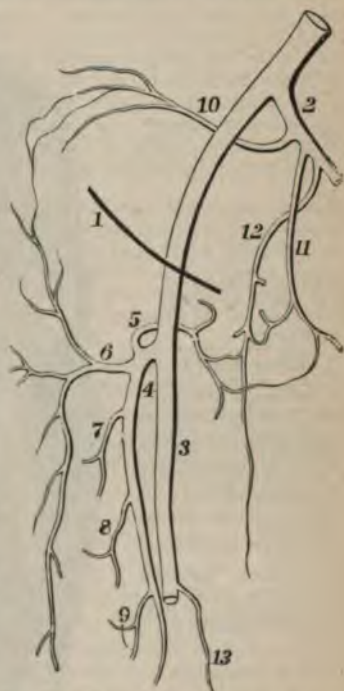


FIG. 224.—PLAN OF THE INOSCULATIONS OF THE CIRCUMFLEX ARTERIES.

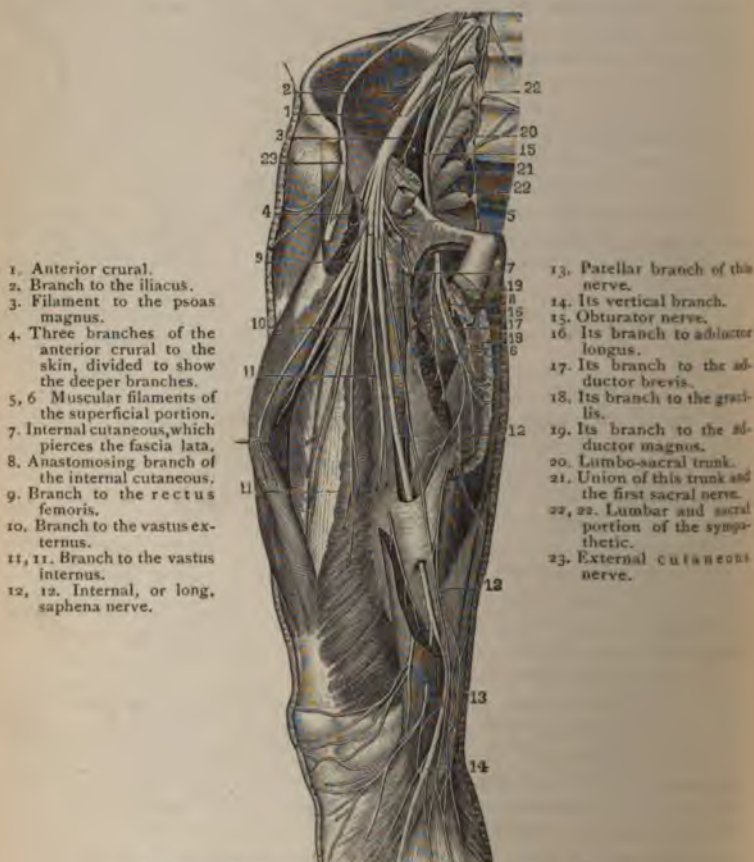
1. Crural arch. 2. Internal iliac. 3. Superficial femoral. 4. Profunda. 5. Internal circumflex. 6. External circumflex. 7. First perforating. 8. Second ditto. 9. Third ditto. 10. Gluteal. 11. Obturator. 12. Sciatic. 13. Anastomotica magna.

* In its course down the thigh the femoral artery gives off a branch of considerable size for the supply of the vastus internus. We may trace this branch through the substance of the vastus down to the patella, where it joins the network of vessels on the surface of that bone.

† Read the account of the dissection of an aneurismal limb by Sir A. Cooper, *Med. Chir. Trans.*, vol. ii., 1811.

Anterior Crural Nerve.

The anterior crural nerve is the largest branch of the lumbar plexus (p. 461). It comes from the third and fourth lumbar nerves, also by a small fasciculus from the second. It passes beneath the crural arch,



1. Anterior crural.
2. Branch to the iliacus.
3. Filament to the psoas magnus.
4. Three branches of the anterior crural to the skin, divided to show the deeper branches.
- 5, 6 Muscular filaments of the superficial portion.
7. Internal cutaneous, which pierces the fascia lata.
8. Anastomosing branch of the internal cutaneous.
9. Branch to the rectus femoris.
10. Branch to the vastus externus.
- 11, 11. Branch to the vastus internus.
- 12, 12. Internal, or long, saphena nerve.

13. Patellar branch of this nerve.
14. Its vertical branch.
15. Obturator nerve.
16. Its branch to adductor longus.
17. Its branch to the adductor brevis.
18. Its branch to the gracilis.
19. Its branch to the adductor magnus.
20. Lumbo-sacral trunk.
21. Union of this trunk and the first sacral nerve.
22. Lumbar and sacral portion of the sympathetic.
23. External cutaneous nerve.

FIG. 225.—NERVES ON THE ANTERIOR PART OF THE THIGH.

lying in the groove between the iliacus and psoas, about a quarter of an inch to the outer side of the artery, and soon divides into branches, some of which are cutaneous, but the greater number supply the extensor muscles of the thigh. The cutaneous branches,

already described (p. 561), and the long saphenous nerve, are given off from the *superficial* part of the trunk; the muscular from the *deep* part.

The *long saphenous nerve*, the largest of the cutaneous branches, descends close to the outer side of the femoral artery, and enters the tendinous canal with it in the middle third of the thigh. In the canal it crosses over the artery to its inner side. The nerve leaves the artery just before it becomes popliteal, and then runs in company with the *anastomotica magna* to the inner side of the knee, where it becomes superficial, between the gracilis and the sartorius. In the middle third of the thigh it gives off a small branch which communicates beneath the fascia lata with the internal cutaneous and obturator nerves; and lower down another branch is distributed to the skin over the patella. Its further relations will be seen in the dissection of the leg and foot.

The *muscular branches* are to be traced to the sartorius, rectus, crureus, and subcrureus; the branch to the vastus externus accompanies the descending branch of the external circumflex artery, and sends a filament to the knee-joint; that to the vastus internus runs parallel with, but external to, the long saphenous nerve, and supplies filaments to the knee-joint. One branch, often two, passes under the femoral artery and vein to enter the anterior surface of the pectineus.

The *obturator nerve*, also a branch of the lumbar plexus, arising from the second, third, and fourth lumbar nerves (p. 461), supplies the adductor muscles. It enters the thigh through the upper part of the obturator foramen above the corresponding artery, and immediately divides into two branches, of which one passes in front of, the other behind, the adductor brevis. The *anterior* branch subdivides for the supply of the gracilis, the adductor longus, and sometimes the adductor brevis and pectineus; it, moreover, sends a filament to the hip-joint, another to the femoral artery, and a third forms a plexiform communication at the lower border of the adductor longus with the internal cutaneous and long saphenous nerves. The *posterior* branch supplies the obturator externus, the adductor brevis and magnus. In some bodies you can trace a filament of this nerve through the notch of the acetabulum into the hip-joint, and another, which runs near the popliteal artery, into the back part of the knee-joint. We have frequently seen cutaneous branches from the obturator on the inner side of the thigh. This is interesting practically, since it helps to explain the pain often felt on the inner side of the knee in disease of the hip-joint.

The *accessory obturator nerve*, when present, comes either from the obturator nerve or from the third and fourth lumbar nerves. Descending, it runs between the horizontal ramus of the os pubis and the pectineus, and supplies a branch to this muscle, also a filament of communication to the anterior branch of the obturator, and a third branch to the hip-joint.

The *obturator artery*, after passing through the foramen, divides into two branches, an *internal* and an *external*, which form a circle

round the obturator membrane. These supply the external obturator and adductors of the thigh, and inosculate with the internal circumflex artery (p. 584). The latter branch sometimes gives off the small artery to the ligamentum teres of the hip-joint.

DISSECTION OF THE FRONT OF THE LEG.

About an inch (2.5 *cm.*) below the patella is the prominent tubercle of the tibia, to which the ligamentum patellæ is attached; on each side of this is a depression, filled with more or less fat. About the same distance below the outer tuberosity of the tibia is the head of the fibula, situated far back, and to it can be traced the tense tendon of the biceps. The crest of the tibia is easily felt in front, commencing above at the outer tuberosity, and passing down nearly vertically, gradually inclining to the inner side so that it is continuous below with the front of the internal malleolus. Internal to the crest is the subcutaneous internal surface of the tibia, and externally is the interval between the tibia and the fibula, which is filled up by the extensor muscles. The lower fourth of the fibula is subcutaneous, ending in a well-marked prominence, the external malleolus, which, it should be observed, descends lower than the internal malleolus. The student should notice well the tendons which surround the ankle-joint, which are easily recognizable under the skin; thus, behind, the tendo Achillis stands out prominently, having a deep depression on each side; on the outer side, the tendons of the peronei longus and brevis, are felt, the latter being the anterior. Running round the inner ankle we can only feel the tibialis posticus close to the tibia, and next to it the flexor longus digitorum; in front of the ankle, but bound down by the anterior annular ligament, can be felt, from within outwards, the strong tendon of the tibialis anticus, the extensor proprius hallucis, and the long extensor of the toes with the peronæus tertius.

The foot should be turned inwards, and fixed in this position. An incision must be made from the knee, down the front of the leg, over the ankle, along the top of the foot to the great toe; a second, at right angles to the first, on either side of the ankle; a third, across the bases of the toes. Reflect the skin from the front and sides of the leg and foot.

Cutaneous Veins and Nerves. Having traced the internal saphena vein (p. 560) to the inner side of the knee, follow it down the inner side of the leg, in front of the inner ankle* to the dorsum of the foot. On the dorsum of the

* The French commonly bleed from the internal saphena vein as it crosses over the inner ankle, this being a convenient and safe place for venesection.

foot notice that the principal veins form an arch, with the convexity forwards, as on the back of the hand. This arch receives the veins from the toes. From the inner side of the arch the *internal saphena* originates; from the outer side, the external saphena. The latter vein commences on the outer side of the arch on the dorsum, runs behind the external ankle, along the outer border of the tendo Achillis up the back of the calf of the leg, between the two heads of the gastrocnemius, and finally pierces the deep fascia at the lower part of the popliteal space, to join the popliteal vein. The external saphenous nerve accompanies this vein, as the long saphenous nerve does the internal saphena vein.

Long Saphenous Nerve. The skin on the inner side of the leg is supplied by the long or internal saphenous nerve (p. 587). It becomes subcutaneous on the inner side of the knee, between the gracilis and sartorius (Fig. 225, 12). Here it meets the saphena vein, and accompanies it down the leg, distributing its branches on either side, till it is finally lost on the inner side of the foot and the great toe. The largest branch curves round the inner side of the knee, just below the patella, to supply the skin in this situation. It pierces the sartorius close to the knee, and forms, with branches from the internal, middle, and external cutaneous nerves, the *plexus patellæ*.

The *internal cutaneous nerve* supplies the skin of the upper and inner aspect of the leg, and joins the internal saphenous nerve.

The skin on the front and outer parts of the upper half of the leg is supplied by *cutaneous branches* from the *external popliteal* or *peroneal* nerve; the skin of the lower half by its *external cutaneous branch*, as follows:—

External Cutaneous Branch of the Peroneal Nerve. This branch of the peroneal nerve comes through (Fig. 229, 2) the fascia about the lower third of the outer side of the leg, and, descending over the front of the ankle, divides into two. Trace them, and you will find that the *inner* and smaller supplies the inner side of the great toe, and the contiguous sides of the second and third toes; towards its termination it communicates with the long saphenous and anterior tibial nerves. The *outer* distributes branches to the outer side of the third toe, both sides of the fourth, and the inner side of the fifth toe, and joins the short or external saphenous nerve.

The outside of the little toe is supplied by the external saphenous nerve, which runs behind the outer ankle with the corresponding vein.

The contiguous sides of the great and second toes are supplied by the termination of the anterior tibial nerve.*

* Such is the most common distribution of the nerves to the upper surface of the toes. But deviations from this arrangement are frequent.

Muscular Fascia and Annular Ligaments. This is remarkably thick and strong. Besides its general purpose of forming sheaths for the muscles, and straps for the tendons, it gives origin, as in the forearm, to muscular fibres, so that it cannot be removed near the knee without leaving the muscles ragged. The fascia, continuous above with the fascia lata, is attached to the head of the tibia and the fibula; it is connected on the inner side with the expanded tendons of the sartorius, gracilis, and semi-tendinosus; on the outer side with that of the biceps; consequently, when these muscles act, it is rendered tense. Following it down the leg, you find that it is attached to the edge of the tibia, and that it becomes stronger as it approaches the ankle, to form the ligaments which confine the tendons in this situation. Of these ligaments, called *annular*, there are three, as follows:—

a. The *anterior annular ligament* extends obliquely across the front of the ankle-joint, and confines the extensor tendons of the ankle and toes. It consists of two converging straps—one oblique, the other horizontal, which join and are continued on as a common band, like the letter < placed transversely; the upper or oblique binds down the tendons in front of the lower end of the tibia; the lower or oblique the tendons which lie over the tarsus. The common band is attached to the external malleolus, cuboid, and os calcis; it is continued horizontally inwards for a short distance, and in front of the ankle splits into two fasciculi; the upper or oblique ascends to be attached to the tibia; the lower or horizontal passes inwards to be attached to the internal malleolus, the scaphoid, and the internal cuneiform. Beneath the upper fasciculus, enclosed in two synovial sheaths, run the tibialis anticus on the inner side, and the extensor longus digitorum and peroneus tertius on the outer side; the extensor proprius hallucis and the anterior tibial vessels lying behind the ligament, but not having any synovial sheath. Beneath the lower fasciculus are three synovial sheaths—an inner one for the tibialis anticus, a middle one for the extensor proprius hallucis, and an outer one for the extensor longus digitorum and peroneus tertius. It is the strain of this ligament which occasions the pain in sprains of the ankle.

b. The *external annular ligament* extends from the outer malleolus to the os calcis, and confines the tendons of the peronei muscles, which are enclosed in a common synovial sheath.

c. The *internal annular ligament* is a strong fasciculus of ill-defined fibrous tissue which extends from the inner malleolus to the os calcis, where it becomes continuous with the plantar fascia and the tendinous origin of the abductor hallucis. It binds down the flexor tendons of the foot and toes, and as these pass round the

**Extensor Proprius
Hallucis.**

This muscle (Fig. 226, 5) lies partly concealed between the tibialis anticus and the extensor longus digitorum. It *arises* from rather more than the middle third of the anterior surface of the fibula, and from the interosseous membrane. The fibres terminate in a penniform manner on the tendon, which runs over the ankle, between the tendons of the tibialis anticus and the extensor longus digitorum, along the top of the foot to the great toe, where it is *inserted* into the base of the last phalanx. It has a special pulley beneath the horizontal portion of the anterior annular ligament lined by a synovial membrane, which accompanies it as far as the metatarsal bone of the great toe. It is supplied by the anterior tibial, a branch of the peroneal nerve.

Now examine the course, relations, and branches of the anterior tibial artery. Since it lies deeply between the muscles, it is necessary to separate them from each other; this is easily done by proceeding from the ankle towards the knee.

**Course and Relations
of the Anterior
Tibial Artery.**

The *anterior tibial artery* is one of the two branches into which the popliteal divides at the lower border of the popliteus. It comes at first horizontally forward about $1\frac{1}{4}$ inch (3.1 cm.) below the head of the fibula, between the two heads of the tibialis posticus, above the interosseous membrane, and then descends, lying in rather more than the first half of its course upon the interosseous membrane, afterwards along the front of the tibia. It runs beneath the anterior annular ligament over the front of the ankle, where it takes the name of the dorsal artery of the foot. Thus, a line drawn from the head of the fibula to the interval between the first and second metatarsal bones would nearly indicate its course. In the upper third of the leg it lies deeply between the tibialis anticus and the extensor longus digitorum; in the lower two thirds, between the tibialis anticus and the extensor proprius hallucis. In *front of the ankle* the artery is crossed by the extensor proprius hallucis, and lies between the tendon of this muscle and the inner tendon of the extensor longus digitorum.

The artery is accompanied by the anterior tibial nerve (a branch of the peroneal), which runs for some distance upon its fibular side, then in front of it, and lower down is again situated on its outer side. It is accompanied by two veins, one on each side, which communicate at intervals by cross branches.

The branches of the anterior tibial are as follows:—

a. The *recurrent tibial* branch ascends close by the outer side of the head of the tibia, through the tibialis anticus, to the front of the knee-joint, where it anastomoses with the other articular arteries derived from the popliteal, and with the *anastomotica magna*.

**Extensor Longus
Digitorum.**

This muscle lies along the fibular side of the preceding (Fig. 226, 4). It *arises* from the external tuberosity of the tibia, from the upper three-fourths of the anterior surface of the shaft of the fibula, from the interosseous membrane, from the fascia of the leg and the intermuscular septa. Its fibres terminate in a penniform manner upon a long tendon situated on the inner side of the muscle; this tendon descends in front of the ankle and divides into four slips, which pass to the four outer toes. They diverge from each other, and are *inserted* into the toes thus: On the base of the first phalanx each tendon (except that of the little toe) is joined on its outer side by the corresponding tendon of the extensor brevis (11), and a little further on by a fibrous expansion from the interosseous and lumbrical muscles. The united tendons then expand, cover the dorsal surface of the first phalanx, and at the articulation between this and the second phalanx split into three fasciculi; the middle one is inserted into the base of the second phalanx; the two lateral ones running on and reuniting are inserted into the base of the third phalanx. Its nerve comes from the anterior tibial.

Immediately below the ankle the anterior annular ligament forms a pulley through which the tendon of this muscle plays. It is like a sling, of which the two ends are attached to the os calcis, while the loop serves to confine the tendon. The play of the tendon is facilitated by a synovial membrane, which is prolonged for a short distance along each of its four divisions. Besides its chief action, this muscle extends the ankle-joint.*

Peroneus Tertius. This is a portion of the preceding (Fig. 226, 6). Its fibres *arise* from the lower fourth of the anterior surface of the shaft of the fibula, the interosseous membrane, and the intermuscular septum between it and the peroneus brevis (8), and terminate on their tendon like barbs on a quill. The tendon passes through the same synovial pulley with the long extensor of the toes, and expanding considerably is *inserted* into the tarsal end of the metatarsal bone of the little toe. It is not always present. It is supplied by a branch of the anterior tibial nerve. This muscle extends the foot and draws the outer border of the foot upwards.

The peroneus tertius and the tibialis anticus are important muscles in progression. They raise the toes and foot from the ground. Those who have lost the use of these muscles are obliged to drag the foot along the ground, or to swing the entire limb outwards in walking.

* There is often a large bursa between the tendon of the extensor longus digitorum and the outer end of the astragalus. This bursa sometimes communicates with the joint of the head of the astragalus.

skin, superficial and deep fasciæ, the venous arch across the dorsum, and the innermost tendon of the short extensor of the toes; on its *outer side*, it has the extensor longus digitorum, and the anterior tibial nerve on its *inner side*, the extensor proprius hallucis. The dorsal artery gives off the following branches:—

a. The *tarsal* branch arises near the scaphoid bone, passes outwards in an arched direction beneath the extensor brevis digitorum towards the outside of the foot, supplies the bones and joints of the tarsus, and inosculates with the external malleolar, the peroneal, the metatarsal, and the external plantar arteries.

b. The *metatarsal* branch generally runs towards the outside of the foot, in front of and parallel with the tarsal artery, beneath the short extensor tendons, near the bases of the metatarsal bones, and gives off the three *outer dorsal interosseous arteries*. These pass forwards over the corresponding interosseous muscles, supply them, and then subdivide to supply the contiguous sides of the upper surfaces of the toes. The outer interosseous branch, in addition to giving off a branch to the fourth interosseous space, gives off a small branch to the outer side of the little toe. They receive, at the back of each interosseous space, the posterior perforating branches of the plantar arch, and at the front of each interosseous space they receive the anterior perforating branches from the plantar digital arteries.

c. The *dorsalis hallucis* is, strictly speaking, the artery of the first interosseous space. It is the continuation of the dorsal artery of the foot, after it has given off the communicating branch to the sole, and runs forwards to supply *digital branches* to the sides of the great toe and the inner side of the second toe.

Peronei Muscles.

These muscles are situated on the outer side of the fibula, and are named, respectively, peroneus longus and brevis.

Peroneus Longus.

This *arises* from the head and the outer surface of the fibula along its upper two-thirds, from the deep fascia which covers it, and the intermuscular septa. The fibres terminate in a penniform manner upon a tendon, which runs with the peroneus brevis, in a groove behind the external malleolus, then along the outer side of the os calcis, and, lastly, through a groove on the under surface of the os cuboides deep into the sole. It crosses the sole obliquely forwards and inwards, and is *inserted* into the tarsal end of the metatarsal bone of the great toe, and usually into the internal cuneiform bone. In its course through these several bony grooves the tendon is confined by a fibrous sheath, lined by a synovial membrane. In removing the metatarsal bone of the great toe, if possible, leave the attachment of this tendon, which is usually inserted by means of a sesamoid bone. Its nerve comes from the peroneal.

Peroneus Brevis.

This muscle lies beneath the preceding. It *arises* from the lower two-thirds of the outer surface of the fibula, internal to the preceding muscle, and from the intermuscular septa. It terminates on a tendon which runs behind the external malleolus, through the same sheath with the

b. Muscular branches, in its course down the leg, and others which pierce the interosseous membrane, and communicate posteriorly with branches of the posterior tibial and peroneal arteries.

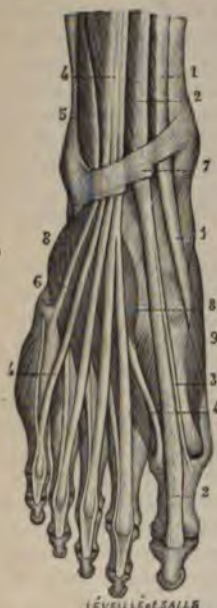

FIG. 327.—EXTENSOR TENDONS OF THE TOES.

- 1, 1. Tendon of the tibialis anticus. 2, 2. Tendon of the extensor proprius hallucis. 3. Very slender division of this tendon attached to the 1st phalanx of the great toe. 4, 4. Extensor longus digitorum. 5. Peroneus tertius. 6. Its tendon attached to the 5th metatarsal. 7. Annular ligament. 8, 8. Commencement of the tendon and of the extensor brevis digitorum. 9. Adductor hallucis.

Dorsal Artery of the Foot.

This artery, the continuation of the anterior tibial, runs over the instep to the back of the interval between the first and second metatarsal bones, where it divides into two branches—one, the dorsalis hallucis, runs along the dorsal aspect and the first interosseous space; the other, the communicating, sinks into the sole and joins the deep plantar arch. On the dorsum of the foot the artery *lies upon* the astragalus, the scaphoid, and the internal cuneiform bones, separated, however, from them by their dorsal ligaments; *in front*, the artery has the

c. The malleolar branches, *external* and *internal*, ramify over the ankle: the *external*, descending beneath the tendon of the extensor longus digitorum and peroneus tertius, ramifies on the external malleolus, inosculating with the anterior peroneal and the tarsal arteries; the *internal* passes beneath the extensor proprius hallucis and the tibialis anticus, and anastomoses with the posterior tibial, with its internal calcanean branch, and with the internal plantar artery. They supply the joint, the articular ends of the bones, and the sheaths of the tendons around them.

Extensor Brevis Digitorum.

This muscle is situated on the dorsum of the foot, beneath the long extensor tendons of the toes. It *arises* from the outer part of the os calcis, from the external calcaneo-astragaloid ligament, and from the anterior annular ligament. The fibres run obliquely over the foot, and terminate in four tendons, which pass forwards to the four inner toes. The inner one and the largest is *inserted* by an expanded tendon into the base of the first phalanx of the great toe; the others *join* the fibular side of the long extensor tendons to be inserted with them into the second and unguinal phalanges. The tendon of the great toe crosses over the dorsal artery of the foot. It is supplied by a branch of the anterior tibial nerve.

skin, superficial and deep fasciæ, the venous arch across the dorsum, and the innermost tendon of the short extensor of the toes; on its *outer side*, it has the extensor longus digitorum, and the anterior tibial nerve on its *inner side*, the extensor proprius hallucis. The dorsal artery gives off the following branches:—

a. The *tarsal* branch arises near the scaphoid bone, passes outwards in an arched direction beneath the extensor brevis digitorum towards the outside of the foot, supplies the bones and joints of the tarsus, and inosculates with the external malleolar, the peroneal, the metatarsal, and the external plantar arteries.

b. The *metatarsal* branch generally runs towards the outside of the foot, in front of and parallel with the tarsal artery, beneath the short extensor tendons, near the bases of the metatarsal bones, and gives off the three outer *dorsal interosseous arteries*. These pass forwards over the corresponding interosseous muscles, supply them, and then subdivide to supply the contiguous sides of the upper surfaces of the toes. The outer interosseous branch, in addition to giving off a branch to the fourth interosseous space, gives off a small branch to the outer side of the little toe. They receive, at the back of each interosseous space, the posterior perforating branches of the plantar arch, and at the front of each interosseous space they receive the anterior perforating branches from the plantar digital arteries.

c. The *dorsalis hallucis* is, strictly speaking, the artery of the first interosseous space. It is the continuation of the dorsal artery of the foot, after it has given off the communicating branch to the sole, and runs forwards to supply *digital branches* to the sides of the great toe and the inner side of the second toe.

Peronei Muscles. These muscles are situated on the outer side of the fibula, and are named, respectively, peroneus longus and brevis.

Peroneus Longus. This *arises* from the head and the outer surface of the fibula along its upper two-thirds, from the deep fascia which covers it, and the intermuscular septa. The fibres terminate in a penniform manner upon a tendon, which runs with the peroneus brevis, in a groove behind the external malleolus, then along the outer side of the os calcis, and, lastly, through a groove on the under surface of the os cuboïdes deep into the sole. It crosses the sole obliquely forwards and inwards, and is *inserted* into the tarsal end of the metatarsal bone of the great toe, and usually into the internal cuneiform bone. In its course through these several bony grooves the tendon is confined by a fibrous sheath, lined by a synovial membrane. In removing the metatarsal bone of the great toe, if possible, leave the attachment of this tendon, which is usually inserted by means of a sesamoid bone. Its nerve comes from the peroneal.

Peroneus Brevis. This muscle lies beneath the preceding. It *arises* from the lower two-thirds of the outer surface of the fibula, internal to the preceding muscle, and from the intermuscular septa. It terminates on a tendon which runs behind the external malleolus, through the same sheath with the

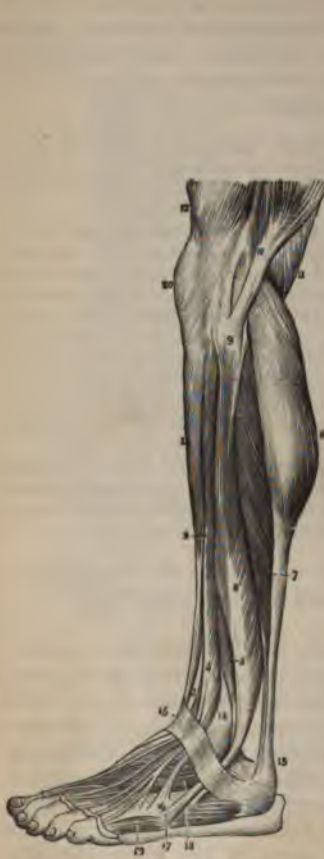

FIG. 228.—MUSCLES OF THE FIBULAR REGION.

1. Tibialis anticus. 2. Extensor longus digitorum. 3. Tendon of the extensor proprius hallucis. 4. Peroneus tertius. 5. Peroneus brevis. 6. Peroneus longus. 7. Soleus. 8. External head of the gastrocnemius. 9. Head of the fibula. 10. Tendon of the biceps. 11. Semi-membranosus. 12. Tendon of the rectus femoris. 13. Tendo-achillis. 14. External malleolus. 15. Annular ligament. 16. Insertion of the peroneus tertius. 17. Insertion of the peroneus brevis. 18. Extensor brevis digitorum. 19. Abductor minimi digiti. 20. Patella.

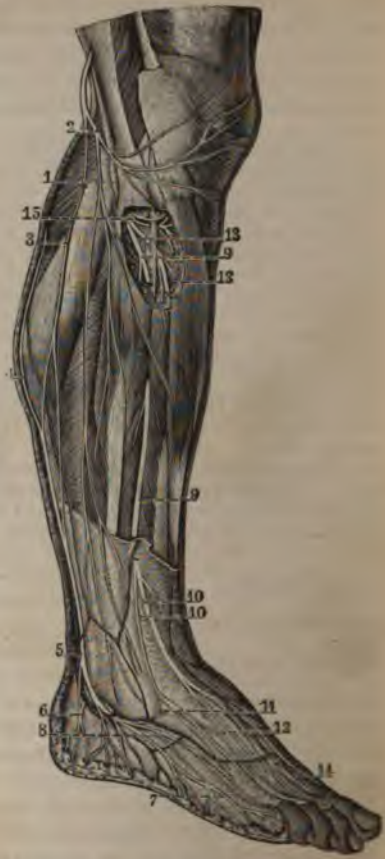

FIG. 229.—PERONEAL OR EXTERNAL POPLITEAL NERVE.

1. External popliteal or peroneal. 2. Cutaneous branch. 3. Communi-cans peronei. 4. External saphena. 5. Trunk formed by the union of the external saphena with the accessory of the cutaneous. 6. Calcanean branch. 7. Terminal branch going to 5th toe. 8. Terminal branch to 4th and 5th toes. 9, 9. Musculo-cutaneous. 10, 10. Its terminal branches. 11. Anastomosis of the musculo-cutaneous with the external saphena. 12. Anastomosis of the internal and external branches of the musculo-cutaneous. 13. Anterior tibial. 14. Terminal branch of anterior tibial, supplying deeper structure great and index toes and anastomosing with the musculo-cutaneous.

peroneus longus, then proceeds along the outside of the foot, and is *inserted* into the dorsal surface of the tarsal end of the metatarsal bone of the little toe. On the outside of the os calcis there is a ridge which separates the tendons of the peronei. Each has a distinct sheath. The short tendon runs above, the long one below, the ridge. Its nerve is from the musculo-cutaneous branch of the peroneal nerve.

The *action* of the peronei is to raise the outer side of the foot.* This movement regulates the bearing of the foot in progression, so as to throw the principal part of the weight on the ball of the great toe. Its action is well exemplified in skating. Again, supposing the fixed point to be at the foot, they tend to prevent the body from falling on the opposite side, as when we balance ourselves on one leg.

Peroneal or External Popliteal Nerve.

Near the inner side of the tendon of the biceps flexor of the leg is a large nerve, the *external popliteal* or *peroneal*, a branch of the great sciatic. By reflecting the upper part of the peroneus longus, you will find that this nerve runs round the outer side of the fibula immediately below its head, and, piercing the origin of the peroneus longus, divides into two main branches—the anterior tibial and the musculo-cutaneous nerves. It gives off several branches as follows: 1. *Articular branches*, two in number to the knee-joint, which pass in with the external articular arteries, and a third which accompanies the tibial recurrent artery. 2. *Cutaneous branches*, two or more, supply the skin on the back and outer aspect of the leg, and one, the *communicans peronei*, which joins the external saphenous to supply the dorsal aspect of the outer side of the little toe: this will be seen later on in the dissection of the back of the leg. 3. The *anterior tibial*, which accompanies the corresponding artery and supplies the muscles between which it runs—namely, the tibialis anticus, extensor longus digitorum, extensor proprius hallucis, and peroneus tertius; also the extensor brevis digitorum. 4. The *musculo-cutaneous* (p. 589), which comes through the fascia between the peroneus longus and the extensor longus digitorum. 5. *Branches*, which supply the peronei longus, and brevis, muscles.

If, then, the peroneal nerve were divided in the popliteal space, the result would be paralysis of the tibialis anticus, the extensors of the toes, long and short, and all the peronei.

* In distortion of the foot outwards, called talipes valgus, it is generally necessary to divide the tendons of the peronei.

DISSECTION OF THE GLUTEAL REGION.

The body having been placed on its face, the pelvis is to be raised to such a height by blocks beneath it, that the lower extremities hang down over the end of the table. Then rotate the thighs inwards as much as possible, and cross them.

Surface Marking. The bony prominences are very marked and prominent; they are, on the outer side, the great trochanter, and, on the inner, the posterior superior spine of the ilium, the spines of the sacral vertebræ, which are continued on to the coccyx. Between the latter bone and the great trochanter is the rounded tuberosity of the ischium, which in the erect position is covered by the gluteus maximus, but is uncovered by it when the femur is flexed. Notice a transverse curved fold of the skin extending from the coccyx to the base of the great trochanter, which does not, as it might be thought, correspond with the lower border of the gluteus maximus, which is much lower. The fact is important to bear in mind in operations for stretching the great sciatic nerve, for the relief of sciatica or other affections of the nerve or its branches. The buttock is convex towards its inner part, and in health presents on its outer side a hollow behind the great trochanter, which usually becomes lost in hip-joint disease. The back of the thigh is convex, and towards its lower part it presents a flattening, corresponding to the lozenge-shaped hollow of the popliteal space, so that the tendons and muscles forming its boundaries can be easily distinguished.

The incision through the skin should commence at the coccyx, and be continued in a semicircular direction along the crest of the ilium. Another incision should be made from the coccyx downwards and outwards for about six inches (15 cm.) below the great trochanter. In reflecting the skin, notice the thick cushion which the subcutaneous adipose tissue forms over the tuberosity of the ischium, and the peculiar manner in which the fat is enclosed in meshes formed by dense connective tissue. A large bursa is often formed between this cushion and the bone.

Cutaneous Nerves. These are derived from the following sources:—*Branches* from the posterior divisions of the *first and second lumbar nerves* descend over the crest of the ilium, near the origin of the erector spinæ, to supply the skin over the gluteus maximus as far as the great trochanter (Fig. 130).

Branches from the posterior branches of the *three upper sacral nerves* pass downwards and outwards to supply for a short distance the integument over the sacrum and coccyx.

The *lateral branch* of the *twelfth dorsal nerve* descends vertically

over the crest of the ilium, near to its anterior part, and supplies the integument of the front of the gluteal region.

The *iliac branch* of the *ilio-hypogastric nerve* passes over the crest of the ilium, between the posterior branches of the lumbar nerves and the preceding nerve, and supplies for a short distance the skin of the buttock.

The *external cutaneous nerve* distributes cutaneous branches to the lower and outer part of the buttock over the great trochanter.

Cutaneous branches from the *lesser sciatic nerve* proceed upwards from beneath the lower border of the gluteus maximus to supply the skin over the lower part of this muscle.

Gluteal Muscles. Three powerful muscles are situated in the region of the buttock, one above the other, named, according to their size, the gluteus maximus, medius, and minimus. The fascia covering the gluteus maximus is comparatively thin, posteriorly, where it is attached to the sacrum, coccyx, and ilium; but anteriorly it is very dense and glistening, and gives origin to the fibres of the gluteus medius, and lower down becomes continuous with the fascia lata.*

Gluteus Maximus. This is the largest muscle of the body, and is covered by a fascia, which sends prolongations inwards deeply between the muscular bundles (Fig. 230). Its great size is characteristic of man, in reference to his erect position. Its texture is thick and coarse. It *arises* from the posterior fifth of the crest of the ilium, and from the rough surface below it, from the lower part of the sacrum, the coccyx, and the great sacro-sciatic ligament. The fibres descend obliquely forwards, and are *inserted* thus: The anterior two-thirds terminate on a strong broad aponeurosis which plays over the great trochanter, and joins the fascia lata on the outside of the thigh (Fig. 213, p. 563); the remaining third is inserted into the femur, along the gluteal ridge leading from the linea aspera to the base of the great trochanter.

This muscle *extends* the thigh-bone upon the pelvis, and is therefore one of those most concerned in raising the body from the sitting to the erect position, and in maintaining it erect. It propels the body in walking, running, or leaping, and rotates the thigh outwards. It is supplied with blood by the gluteal and

* As the fascia leaves the lower border of the gluteus maximus it divides, one portion going, as stated, to the fascia lata and the other being firmly attached to the tuberosity of the ischium and to the tendon of the muscle at its lower margin; the fascia then, becoming more delicate, proceeds upwards, forming the internal covering of the muscle. As the sciatic nerve emerges it hugs close to the tuberosity; the fascia, therefore, makes a tentorium posteriorly which is always tensed when the gluteus maximus is in action. (A. H.)

sciatic arteries; with nerves from the lesser sciatic, and the sacral plexus.

**What is seen
beneath the
Gluteus Maximus.**

The gluteus maximus should be reflected from its origin. The best way is to begin at the front border, which overlaps the gluteus medius. The dissection is difficult, and he who undertakes it for the first time is almost sure to injure the subjacent parts. The numerous vessels which enter its under surface must be divided before the muscle can be reflected. This having been accomplished, the following objects will be exposed:—

The muscle covering the ilium is the gluteus medius. At the posterior border of this are the several objects which emerge from the pelvis through the great sciatic notch—namely, the pyriformis muscle, above which is the trunk of the gluteal vessels and nerve, and below which are the greater and lesser sciatic nerves, the arteria comes nervi ischiatici, the long pudendal nerve, the sciatic vessels, the pudic vessels and nerve, the nerve to the obturator internus, and the coccygeus. Coming through the lesser sciatic notch, is the tendon of the obturator internus, and attached to it are the gemelli muscles, one above, the other below it. Extending from the tuber ischii transversely outwards to the great trochanter is the quadratus femoris, and, below this, is seen the upper part of the adductor magnus. The origins of the semi-membranosus, biceps, semi-tendinosus, and of the adductor magnus, from the tuber ischii, are also seen; as well as the great sacro-sciatic ligament, which passes upwards to the sacrum, and is pierced by the coccygeal branch of the sciatic artery. The great trochanter is exposed, together with a small portion of the vastus externus; and where the tendon of the gluteus maximus plays over the trochanter major, there is a large bursa, simple or multilocular. Lastly, the side of the sacrum, the coccyx, part of the crest of the ilium, the tuberosity of the ischium, are brought into view.

Gluteus Medius.

This muscle, covered behind by the gluteus maximus, and in front by the fascia lata, *arises* from the surface of the ilium, between the crest and the upper curved line; also from the strong fascia which covers it towards the front. The fibres converge to a tendon, which is *inserted* into the oblique line on the upper and outer surface of the great trochanter: some of the anterior fibres—in immediate connection with the tensor fasciæ—terminate on the aponeurosis of the thigh. Between its insertion and the bone is a bursa.

Reflect the gluteus medius to see the third gluteal muscle. The line of separation between them is marked by a large branch of the gluteal artery.

Gluteus Minimus.

This muscle *arises* from the surface of the ilium below the upper and lower curved lines, and as far back as the margin of the great sacro-sciatic notch. Its fibres pass over the capsule of the hip-joint, and converge to a tendon which is *inserted* into a depression on the front part of the

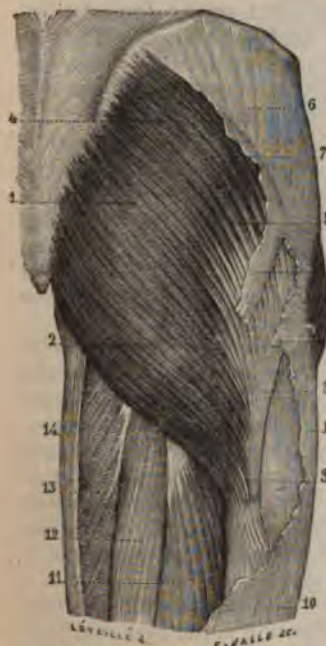

FIG. 230.—GLUTEUS MAXIMUS MUSCLE.

1. Gluteus maximus. 2. Its inferior part.
3. Serrated tendon attached to the gluteal ridge leading to the linea aspera. 4. Superior part of the muscle. 5, 5. Commencement of the tendon of insertion. 6. Superior part of the fascia lata. 7. Dividing of this fascia at the superior border of the gluteus maximus. 8. Portion of the fascia which is adherent to the tendon. 9. Inferior extremity of the tensor fascia femoris. 10, 10. Fascia lata. 11. Biceps. 12. Semi-tendinosus. 13. Semi-membranosus. 14. Gracilis.

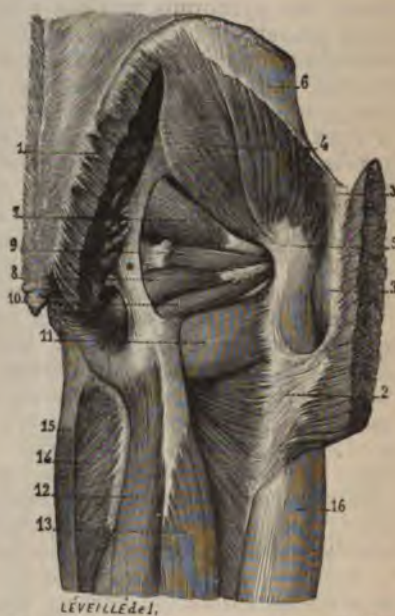

FIG. 231.—MUSCLE BENEATH THE GLUTEUS MAXIMUS.

1. Origin of gluteus maximus divided. 2. Its insertion into the oblique line. 3, 3. Its insertion into the fascia lata. 4. Gluteus medius. 5. Its insertion. 6. Fascia lata, showing continuity with insertion of the gluteus maximus. 7. Piriformis. 8. Obturator internus. 9. Gemellus superior. 10. Gemellus inferior. 11. Quadratus femoris. 12. Semi-membranosus. 13. Biceps. 14. Adductor magnus. 15. Gracilis. 16. Vastus externus.

great trochanter, a bursa being interposed. This muscle and the preceding are supplied by the superior gluteal nerve, a branch of the lumbo-sacral cord. The chief action of this and the preceding muscle is to assist in balancing the pelvis steadily on the thigh, as

when we are standing on one leg ; with the fixed point at the ilium, they are abductors of the thigh. The anterior fibres of the gluteus medius co-operate with the gluteus minimus and the tensor fasciæ in *rotating the thigh inwards*.

Gluteal Vessels and Nerves. The *gluteal artery* is the largest branch of the internal iliac (p. 495). Emerging from the pelvis through the great sciatic foramen between the pyriformis and the gluteus medius, it divides into two large branches for the supply of the gluteal muscles. Of these, the *superficial* proceeds forwards between the gluteus maximus and medius, both of which they supply, and eventually anastomose with the posterior sacral and sciatic arteries; the other—the *deep*—after a short course, divides into two branches: one—the *superior*—curves forwards along the origin of the gluteus minimus, towards the anterior part of the ilium, to anastomose with the ascending branches of the external circumflex and the circumflex iliac arteries; the other—the *inferior branch*—crosses obliquely over the gluteus minimus towards the insertion of this muscle, and anastomoses with the external and internal circumflex arteries.

The nerve which accompanies the gluteal artery is the *superior gluteal nerve*, a branch of the lumbo-sacral cord. It passes out above the pyriformis, and divides into two branches—a superior and an inferior branch; the *superior branch* accompanies the corresponding branch of the gluteal artery, and supplies the gluteus medius and minimus; the *inferior branch* accompanies the inferior branch of the gluteal artery, and distributes filaments to the gluteus medius and minimus, and the tensor fasciæ femoris. In some subjects it sends a branch to the gluteus maximus; but this muscle is chiefly supplied by the lesser sciatic nerve.

A surgeon ought to be able to cut down and tie the gluteal artery as it emerges from the pelvis. The following is the best rule* for finding it:—

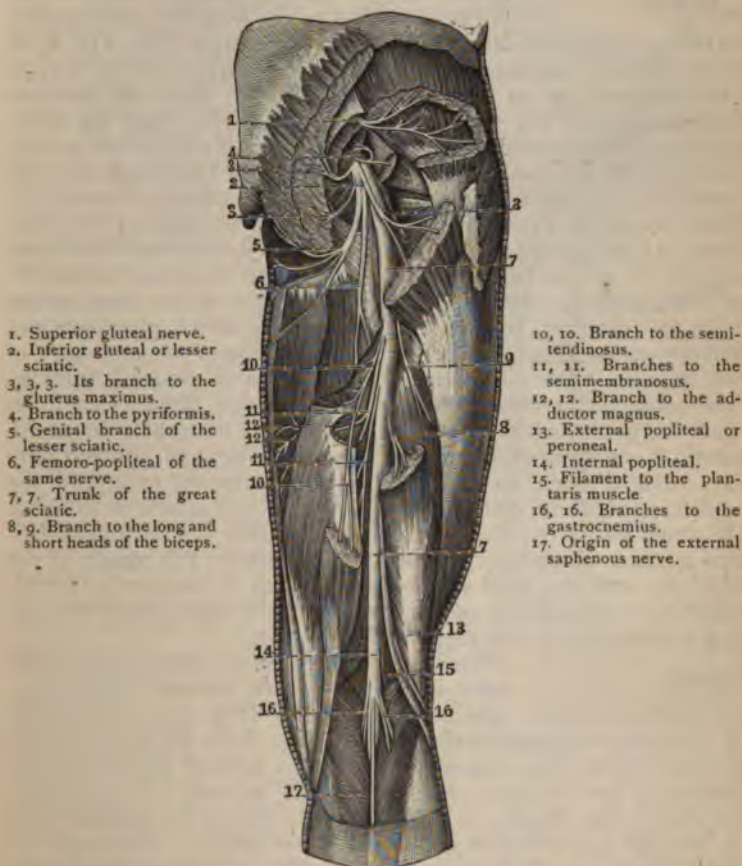
Draw a line from the posterior superior spine of the ilium to the trochanter major, rotated inwards. The junction of the upper with the middle third of this line lies over the artery as it emerges from the upper border of the great sciatic notch.

Now examine the series of muscles which rotate the thigh outwards—namely, the pyriformis, the obturator internus, the gemelli, the quadratus femoris, and the obturator externus.

Pyriformis. This muscle lies immediately below and parallel with the lower fibres of the gluteus medius (Fig. 231, 7). It *arises* within the pelvis by three fleshy

* The operation of tying the gluteal artery was first performed by John Bell. See his *Principles of Surgery*, vol. i., p. 421.

fasciculi from the second, third, and fourth segments of the front surface of the sacrum between the foramina for the sacral nerves, from the margin of the great sacro-sciatic notch, and from the great sacro-sciatic ligament. The fibres, passing horizontally out-



1. Superior gluteal nerve.
2. Inferior gluteal or lesser sciatic.
- 3, 3, 3. Its branch to the gluteus maximus.
4. Branch to the piriformis.
5. Genital branch of the lesser sciatic.
6. Femoro-popliteal of the same nerve.
- 7, 7. Trunk of the great sciatic.
- 8, 9. Branch to the long and short heads of the biceps.

- 10, 10. Branch to the semitendinosus.
- 11, 11. Branches to the semimembranosus.
- 12, 12. Branch to the adductor magnus.
13. External popliteal or peroneal.
14. Internal popliteal.
15. Filament to the plantaris muscle.
- 16, 16. Branches to the gastrocnemius.
17. Origin of the external saphenous nerve.

FIG. 232.—THE GREAT SCIATIC NERVE, WITH ITS COLLATERAL AND TERMINAL BRANCHES.

wards, converge to a tendon, which is *inserted* into the upper border of the great trochanter. Its nerve comes from the sacral plexus. Its action is that of an abductor and an external rotator

of the femur; and, if the femur be the fixed point, it steadies the pelvis on the femur, and when the pelvis has been drawn backwards, it will bring it forwards.

**Obturator
Internus.**

This muscle, of which little more than the tendon can be seen at present, *arises* within the cavity of the pelvis, from the inner surface of the ischium, bounded posteriorly by the margin (Fig. 231, 8) of the great sacro-sciatic notch and the articular surface for the sacrum, and superiorly by the brim of the true pelvis; from the obturator membrane, and the obturator fascia; in front, from the inner surface of the descending ramus of the os pubis and the ascending ramus of the ischium. The fibres are directed backwards and outwards, and terminate on four tendons which converge towards the lesser sacro-sciatic notch; pass through the foramen of the same name at nearly right angles, as round a pulley, and then unite into a single tendon to be inserted into the top of the great trochanter, in front of the pyriformis. Divide the tendon about three inches from its insertion, to see the four tendons which play over the smooth cartilaginous surface on the inner side of the tuberosity of the ischium. There is a large synovial bursa to diminish friction. The nerve to this muscle comes from the sacral plexus (sometimes from the pudic) within the pelvis; it emerges from the great sacro-sciatic foramen, winds round the spine of the ischium, and re-enters the pelvis through the lesser sacro-sciatic foramen to supply the muscle on its inner surface. The action of this muscle is to rotate the femur outwards; but, in the sitting position, it loses this action, and becomes an abductor of the thigh. Between the capsule of the hip-joint and the tendon a synovial bursa is commonly found, which not infrequently communicates with the bursa placed between the tendons and the tuberosity of the ischium.

Gemelli.

These small muscles are accessory to the obturator internus, and are situated, one above, the other below it. The *gemellus superior* (Fig. 231), the smaller of the two, and occasionally absent, *arises* from the outer surface of the spine of the ischium; the *gemellus inferior* from the upper and back part of the tuberosity of the ischium. Their fibres, attached to the tendon of the obturator internus, are *inserted* with it into the upper border of the great trochanter. The nerves to these muscles come from the sacral plexus; that to the superior gemellus from the lower part of the plexus; that to the inferior gemellus comes out through the great sacro-sciatic foramen, passes beneath the superior gemellus and obturator internus to enter the muscle on its deep aspect; this branch also distributes a filament to the quadratus femoris, and another to the hip-joint.

**Quadratus
Femoris.**

This quadrilateral muscle *arises* (Fig. 231, 11) from the ridge on the outer border of the tuber ischii. Its fibres run horizontally outwards, and are *inserted* into the back of the great trochanter, into the greater part of the linea quadrati. The lower border of the quadratus femoris runs parallel with the upper edge of the adductor magnus; in fact, it lies on the same plane. Between these muscles is generally seen a terminal branch of the internal circumflex artery. Its nerve, as previously described, comes from the sacral plexus, and enters its deep surface.

**Obturator
Externus.**

To see this muscle, reflect the quadratus femoris from its origin. It *arises* from the outer surface (Fig. 221, 4) of the body of the os pubis, from the front surface of the rami of the os pubis and ischium, which form the inner border of the obturator foramen, from the inner two-thirds of the outer surface of the obturator membrane, and from the tendinous arch over the obturator vessels. Its fibres converge to a tendon which runs horizontally outwards over a groove on the ischium, and, running across the back of the hip-joint, is *inserted* into the deepest part of the trochanteric fossa of the femur. Its nerve is a branch of the posterior division of the obturator nerve. This muscle has *in front* of it the adductor longus and brevis, the pectineus, the psoas and iliacus, the neck of the femur, and the capsular ligament; *above* it are the capsular ligament and the inferior gemellus; *below* it are the adductor magnus and quadratus femoris; *behind* it are the obturator membrane and the quadratus femoris.

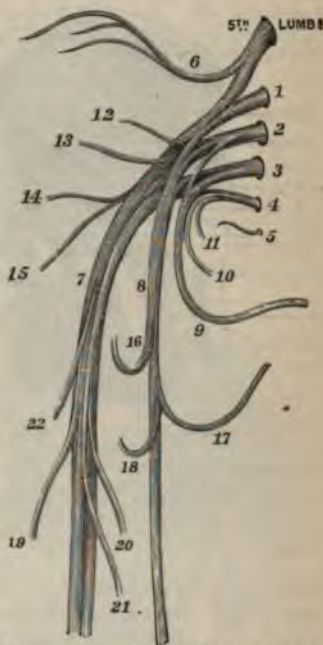


FIG. 233.—PLAN OF THE SACRAL PLEXUS AND BRANCHES.

1, 2, 3, 4, 5. Sacral nn. 6. Superior gluteal n. 7. Great sciatic n. 8. Lesser sciatic n. 9. Pudic n. 10. N. of obturator internus. 11. N. of levator ani. 12. N. of pyriformis. 13. N. of gemellus superior. 14. N. of gemellus inferior. 15. N. of quadratus femoris. 16. N. of gluteus maximus. 17. Long pudendal n. 18. Cutaneous n. of the buttock. 19. N. of the long head of the biceps. 20. N. of semi-tendinosus. 21. N. of semi-membranosus. 22. N. of short head of the biceps.

Great Sciatic Nerve.

being three-quarters of an inch (18 mm.) in breadth, and supplies

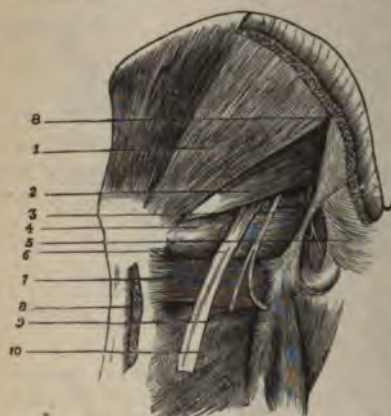


FIG. 234.—DEEP MUSCLES OF THE GLUTEAL REGION.

1. Gluteus medius. 2. Pyriformis. 3. Lesser sciatic nerve. 4. Obturator internus, with the two gemelli. 5. Coccygeus. 6. Great sciatic nerve. 7. Quadratus femoris. 8. Gluteus maximus. 9. The semitendinosus and biceps. 10. Adductor magnus.

peroneal (or external popliteal). It is accompanied by a branch of the sciatic artery, called the *comes nervi ischiatici*.* The nerve distributes branches to the hamstring muscles and the adductor magnus, and sends two or more small branches to the hip-joint which pierce the posterior part of the capsular ligament (Fig. 232).

Small Sciatic Nerve.

This comes from the lower part of the sacral plexus. It leaves the pelvis below the pyriformis, with the great sciatic nerve, but on the inner side of it, and in company with the sciatic artery. It descends behind the gluteus maximus, and becomes cutaneous at its lower border. The muscular branches which it gives off are one or more—*inferior gluteal*—which enter the under surface of the gluteus maximus near its lower border.

* The *arteria comes nervi ischiatici* runs generally by the side of the nerve, but sometimes in the centre of it. This artery becomes one of the chief channels by which the blood reaches the lower limb after ligature of the femoral. See in the Museum of the Royal College of Surgeons a preparation in which the femoral was tied by John Hunter fifty years before the man's death.

This large nerve, formed by the union of the last lumbar and the four upper sacral nerves (Fig. 233), is the largest nerve in the body, it descends over the external rotator muscles of the thigh, along the interval between the tuber ischii and the great trochanter, but rather nearer to the former; so that, in the sitting position, the nerve is protected from pressure by this bony prominence. The nerve does not descend quite perpendicularly, but rather obliquely forwards upon the adductor magnus, parallel with the great sacro-sciatic ligament, and below the middle of the thigh divides into the internal popliteal and the

Emerging from the pelvis through the great sacro-sciatic foramen below the pyriformis, it descends over the external rotator muscles of the thigh, along the interval between the tuber ischii and the great trochanter, but rather nearer to the former; so that, in the sitting position, the nerve is protected from pressure by this bony prominence. The nerve does not descend quite perpendicularly, but rather obliquely forwards upon the adductor magnus, parallel with the great sacro-sciatic ligament, and below the middle of the thigh divides into the internal popliteal and the

All its other branches are cutaneous, and are divided into an ascending and internal group; the *ascending branches* turn round the lower border of the gluteus maximus, and supply the skin of the buttock; the *internal branches* supply the skin on the inner and posterior aspect of the thigh in its upper part; and one branch, larger than the rest, called the *inferior pudendal*, turns inwards towards the perineum to supply the skin of that region and the scrotum, communicating with the inferior hæmorrhoidal and superficial perineal nerves. The continued trunk runs down the back of the thigh beneath the muscular fascia, as low as the upper part of the calf, with the external saphenous vein, supplying the skin all the way down, and communicates with the short saphenous nerve.

Sciatic Artery.

This, one of the terminal branches of the internal iliac, courses along the inner aspect of the sacral plexus and pyriformis, behind the pudic artery, while this vessel is still within the pelvis. It emerges from the pelvis between the pyriformis and coccygeus, and is then seen in the gluteal region coming out between the pyriformis and superior gemellus. It then descends between the tuber ischii and the great trochanter, along the inner side of the great sciatic nerve.

It gives off: (1) within the pelvis, branches to the muscles which form the muscular floor of the pelvis; to the rectum, the bladder, prostate and vesiculæ seminales; (2) external to the pelvis, it gives off: *a*, a *coccygeal branch*, which runs inwards through the great sacro-sciatic ligament, then ramifies in the gluteus maximus, and on the back of the coccyx; *b*, the *comes nervi ischiatici*, which accompanies the great sciatic nerve for a short distance, and then enters its substance; *c*, the *inferior gluteal branches*, which enter the gluteus maximus; *d*, *articular branches*, which pierce the posterior capsule of the hip-joint; *e*, *muscular branches* to the several external rotators and the hamstring muscles, and which inosculate with the external and internal circumflex, gluteal, obturator, and first perforating arteries.

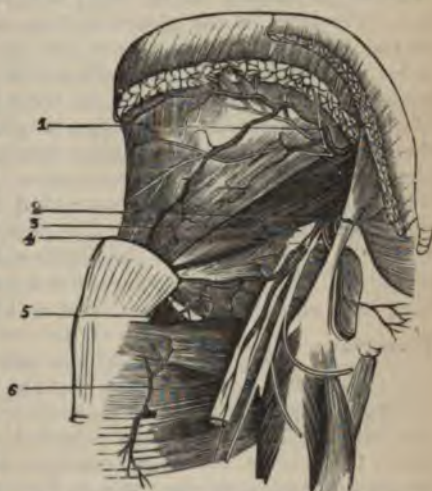

FIG. 235.—THE ARTERIES OF THE GLUTEAL REGION.
1. Gluteal artery and nerve. 2. Pudic artery and nerve, and nerve to obturator internus. 3. Great sacro-sciatic nerve. 4. Sciatic artery. 5. Internal circumflex artery. 6. The first perforating artery.

Pudic Artery and Nerve.

The course of this artery and nerve has been fully described (p. 497). Observe now that they pass over the spine of the ischium accompanied by the nerve to the obturator internus, and that in a

thin subject it is possible to compress the artery against the spine. The rule for finding it is this: rotate the foot inwards, and draw a line from the top of the great trochanter to the base of the coccyx; the junction of the inner with the outer two-thirds gives the situation of the artery.*

Popliteal Space: its Boundaries. It is advisable to examine the popliteal space at this stage of the dissection, in order that the various parts may be carefully made out with as little disturbance as possible of their mutual relations.

Surface Marking. The popliteal space is a lozenge-shaped hollow at the back of the knee-joint, extending as high as the junction of the middle with the lower third of the femur, and as low as the upper sixth of the tibia. The hollow is most apparent when the knee is flexed, as then the tendinous boundaries stand out in bold relief; it is almost lost when the leg is extended. The tendon on the outer side is that of the biceps, diverging to the head of the fibula; on the outer side, and below, are the plantaris and outer head of the gastrocnemius, which are not well defined; on the inner side, above, we can feel three tendons in the following order from within outwards—the semitendinosus, the semimembranosus and the gracilis; below, on their inner side, is the inner head of the gastrocnemius. The upper angle of this space is formed by the diverging biceps and semitendinosus; the lower angle by the converging heads of the gastrocnemius. Passing from above downwards in the middle of the space, and in the following order, are the internal popliteal nerve, the popliteal vein and artery; and along the inner border of the biceps can be felt the external popliteal nerve. Filling up the hollow is a quantity of soft fat, with some lymphatic glands, and on the bone rest the articular arteries.

Dissection. A vertical incision must be made along the middle of the ham, extending from six inches (15 cm.) above, to three inches (7.5 cm.) below the knee; transverse incisions should be made at each extremity of the vertical, so that the skin may be conveniently reflected. In doing so, care must be taken to preserve the cutaneous branch of the lesser sciatic nerve, which descends over the space to the back of the leg.

The muscular fascia covering the space is very strong, and strengthened by numerous transverse fibres. It is pierced by the posterior saphena vein, which passes in to join the popliteal vein.

The fascia having been reflected, the muscles and tendons constituting the boundaries of the popliteal space are to be cleaned. The boundaries of the space can now be seen to be formed, as before

* Mr. Travers succeeded in arresting hæmorrhage from a sloughing ulcer of the glans penis by pressing the pubic artery with a cork against the spine of the ischium.

stated, above, by the divergence of the hamstring muscles to reach their respective insertions; below, by the converging heads of the gastrocnemius; its shape is therefore that of a lozenge. Above, it is bounded on the inner side by the semitendinosus, semimembranosus, gracilis, and sartorius; on the outer side, by the biceps; below, it is bounded on the inner side by the internal head of the gastrocnemius; on the outer, by the external head of this muscle and the plantaris.

The space is occupied by a quantity of fat, which permits the easy flexion of the knee; and in this fat are found the popliteal vessels and nerves, in the following order: nearest to the surface are the nerves; the artery lies close to the bone, the vein being superficial to the artery (Fig. 236).

**Great Sciatic
Nerve.**

Along the outer border of the semimembranosus, and covered by the long head of the biceps, is the great sciatic nerve, which, after giving off branches to the three great flexor muscles and the adductor magnus, divides, about the lower third of the thigh (higher or lower in different subjects), into two large nerves—the peroneal or external popliteal and the internal popliteal.

The *peroneal nerve* runs close by the inner side of the tendon of the biceps,* and subsequently in the groove between this muscle and the outer head of the gastrocnemius, towards the head of the fibula. As it passes round the joint it gives off *two articular* (Fig. 229) branches to the outer side of the knee, which accompany the external superior and inferior articular arteries, and a *recurrent articular* branch, which runs with the recurrent tibial artery to the front of the knee. It supplies also two or three *cutaneous branches* to the posterior and outer surfaces of the leg, as far as its middle third.

The *communicans peronei* (Fig. 236) is a small branch given off as the nerve passes over the gastrocnemius; it crosses the outer head of this muscle and joins the external saphenous, which runs down the back of the calf, and behind the external malleolus, to supply the outer side of the foot and little toe.

Below the head of the fibula we have already traced the division of the peroneal into the anterior tibial, and the musculo-cutaneous nerves (p. 597).

The *internal popliteal nerve*, the larger of the two divisions of the great sciatic nerve, accompanies the popliteal artery, and, at the lower border of the popliteus, it is continued under the name of

* The nerve is, therefore, very liable to be injured in the operation of dividing the outer hamstring. In the diagram the nerve is not near enough to the tendon, their connections having been severed.

the posterior tibial. The nerve in the popliteal space lies superficial to and rather external to the artery, and gives off four or five *muscular branches* which supply the two heads of the gastrocnemius, the plantaris, the soleus, and the popliteus; *three articular branches*, two accompanying the internal superior and inferior articular arteries, the third piercing the back of the capsule accompanied by the azygos artery; and the *short or external saphenous*, which

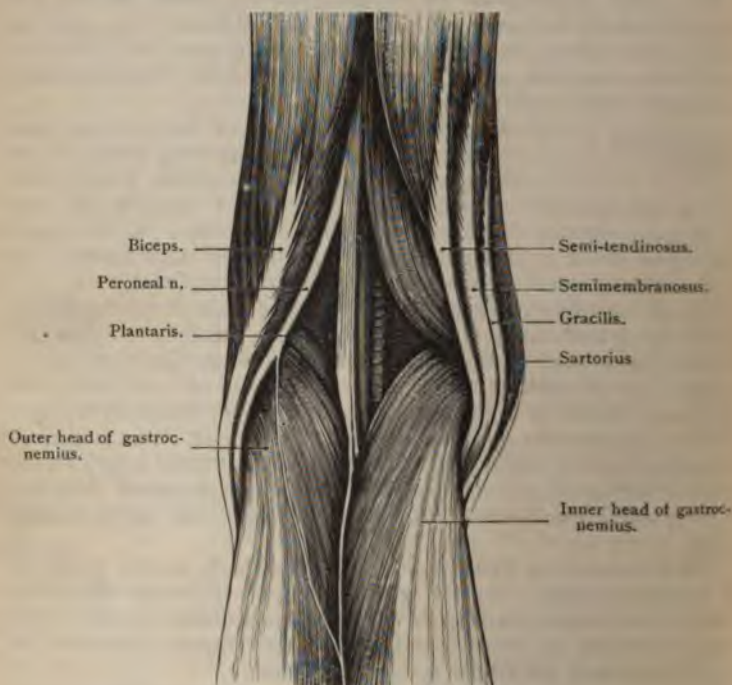


FIG. 236.—LEFT POPLITEAL SPACE.

descends in the groove between the two heads of the gastrocnemius, is joined about the middle of the leg by the *communicans peronei*, and then, running down behind the outer malleolus in company with the external saphena vein, is distributed to the outer side of the foot and the little toe. The continuation of the internal popliteal nerve, as posterior tibial, supplies all the flexor muscles on the back of the leg and the sole of the foot.

Popliteal Vessels. By clearing out all the fat, we observe that the popliteal vessels enter the ham through an aperture in the adductor magnus, and descend close to the back part of the femur, and the back of the knee-joint. At first they are partially overlapped (in muscular subjects) by the semimembranosus; indeed, the outer border of this muscle is a good guide to the artery in the operation of tying it. The *popliteal artery* lies upon the triangular surface at the back of the lower third of the femur; then, upon the ligamentum posticum Winslowii; and, lastly, upon the popliteus, at the lower border of which it divides into the anterior and posterior tibial.

Superficial to the artery are the semimembranosus, a considerable amount of fat, the gastrocnemius, the plantaris, the soleus, the popliteal vein, and the internal popliteal nerve; *internally*, it has the semimembranosus, the internal condyle of the femur, and the inner head of the gastrocnemius; *externally*, it has the biceps, the external condyle, the outer head of the gastrocnemius, and the plantaris.

The artery gives off the *external and internal superior articular arteries*; lower down, the *external and internal inferior articular arteries*, the *superior and inferior muscular branches*, the *azygos*, and *cutaneous branches*. The description of these branches of the popliteal will be deferred till later, until the muscles of the calf have been reflected.

The articular branches which come from the popliteal are given off at right angles to that vessel; and besides these it gives off the *sural*, which supply the muscles of the calf, and the *azygos artery*; close to the vessel is the articular branch of the obturator nerve, which supplies the knee-joint.

The *popliteal vein* lies superficial to the artery, and rather to its outer side. It receives the short saphena vein. Its coats are remarkably thick, and on transverse section resemble those of an artery of a similar size.

Lymphatic Glands. Two or more lymphatic glands are situated one on each side of the artery. They deserve attention, because, when enlarged, their close proximity to the artery may communicate a pulsation which might be mistaken for an aneurism.

DISSECTION OF THE BACK OF THE THIGH.

This incision should be continued along the remainder of the back of the thigh, and the skin reflected. The fat should be removed, and the cutaneous branches

Dissection. derived from the external and internal cutaneous nerves, and the small sciatic, should be carefully sought out.

Cutaneous Nerves and Veins. The skin on the middle of the back of the thigh is supplied by the small sciatic nerve, which runs down beneath the deep fascia as far as the middle third; then pierces it, and runs down as far as the middle third of the calf, distributing branches on each side.

On the outer side, a few cutaneous branches from the *posterior division* of the *external cutaneous nerve* supply the skin as far as the middle third; on the inner side are small branches from the small sciatic and the internal cutaneous nerves as low as the knee-joint.

The subcutaneous veins at the back of the thigh are very small; here they would be liable to pressure. But near the popliteal space there is a vein, called the *external* or *short saphena*. It comes up the back of the calf, and joins the popliteal vein after perforating the strong fascia covering the space.

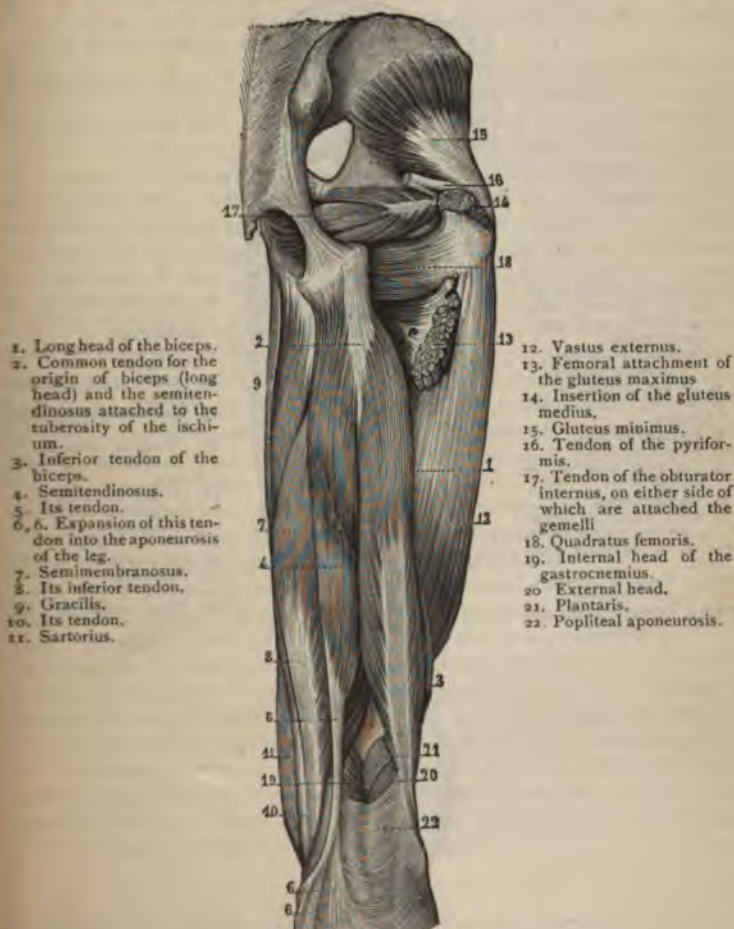
Muscular Fascia. Respecting this, remark that its fibres run chiefly in a transverse direction, that it becomes stronger as it passes over the popliteal space, and that here it is connected with the tendons on either side. Remove it, to examine the powerful muscles which bend the leg, called the hamstrings.

Hamstring Muscles. There are three of these, and all arise by strong tendons from the tuber ischii. One, the biceps, passes downwards and outwards to be inserted into the head of the fibula; the other two—namely, the semitendinosus and semimembranosus—descend inwards and are inserted into the tibia. The divergence of these muscles towards their respective insertions occasions the space termed the *popliteal*, which is occupied by soft fat, the popliteal vessels, nerves, and lymphatic glands.

Biceps. This muscle has two origins, a long and a short. The *long head* arises, by a strong tendon, from the back part of the tuber ischii in common with the semitendinosus; the *short head*, by fleshy fibres, from the outer lip of the linea aspera of the femur between the vastus externus and the adductor magnus, and from the external intermuscular septum: this origin begins at the linea aspera, just below the insertion of the gluteus maximus, and continues nearly down to the external condyle. It joins the long head of the muscle, and both terminate on a common tendon, which is *inserted* into the outer side of the head of the fibula, by two portions separated by the external lateral ligament of the knee-joint. It also gives off a strong expansion to the fascia of the leg. The tendon covers part of the external lateral ligament of the knee-joint, and a small bursa intervenes.

The biceps is not only a flexor of the leg, but rotates the leg, when bent, outwards. It is the muscle which in chronic disease of the knee dislocates the leg outwards and backwards, and at the same times rotates it outwards. Each head of the biceps is supplied by the great sciatic nerve. The short head is sometimes supplied by the peroneal.

Semitendinosus. This *arises*, in common with the biceps, from the back part of the tuber ischii by muscular fibres and also from the inner border of the tendon of the biceps



LÉVEILLE D.
FIG. 237.—HAMSTRING MUSCLES.

for about three inches (7.5 cm.). The muscle passes downwards and inwards, and terminates in the middle of the thigh in a long

round tendon, which rests upon the semimembranosus, and is *inserted* into the upper part of the inner surface of the tibia by an

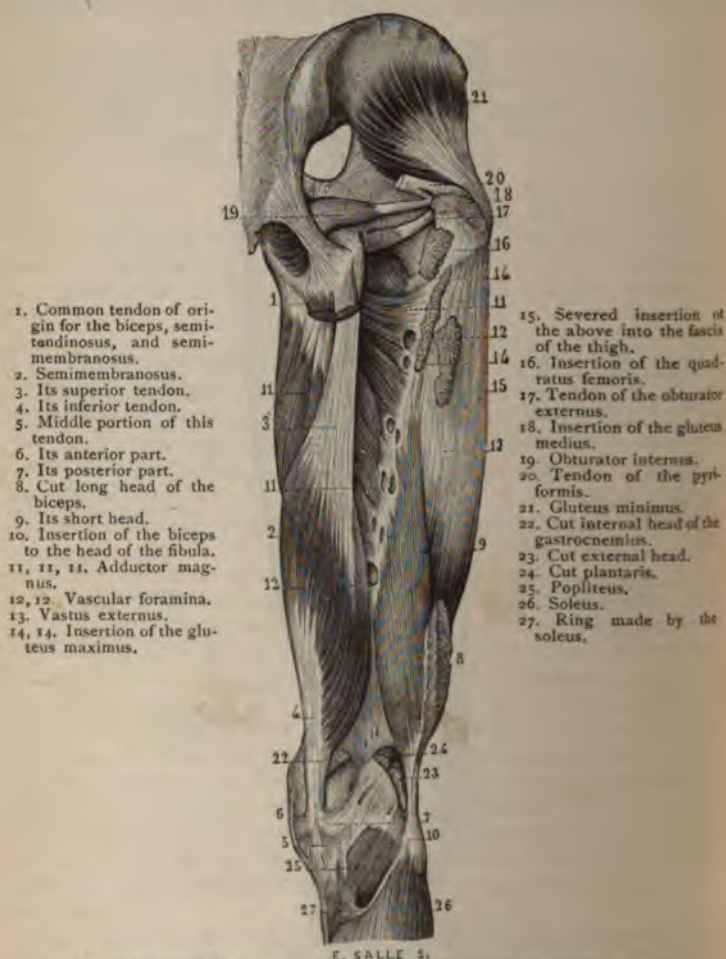


FIG. 238.—SHORT HEAD OF THE BICEPS AND SEMIMEMBRANOSUS, MUSCLES.

expanded tendon, below the tendon of the gracilis, and behind that of the sartorius. Like them, it plays over the internal lateral liga-

Semitendinosus.

This *arises*, in common with the biceps, from the back part of the tuber ischii by muscular fibres and also from the inner border of the tendon of the biceps

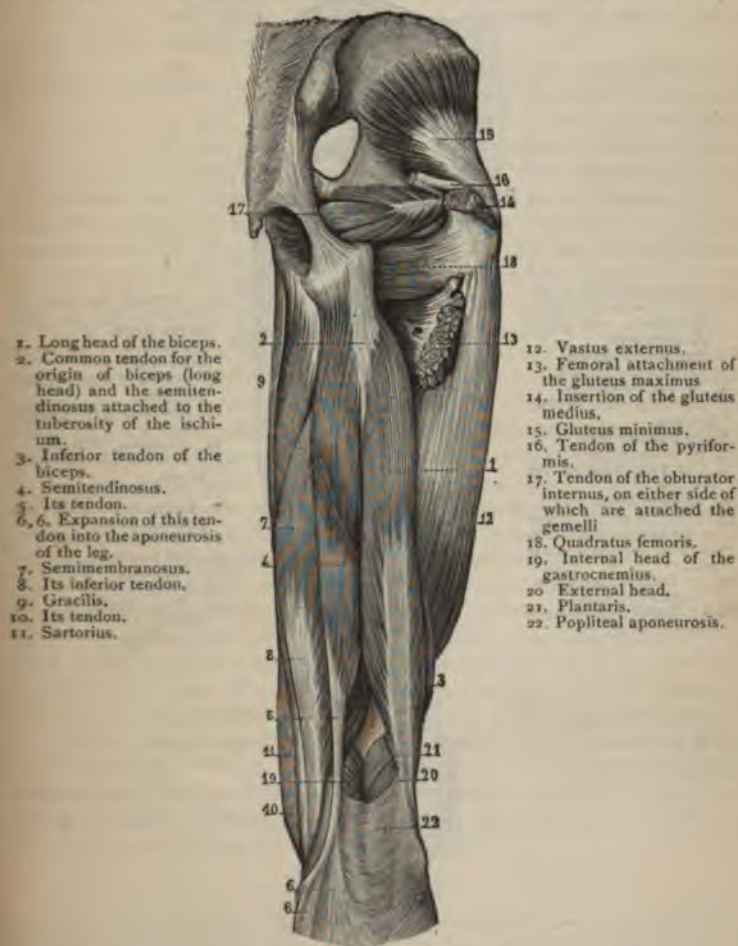

FIG. 237.—HAMSTRING MUSCLES.

for about three inches (7.5 cm.). The muscle passes downwards and inwards, and terminates in the middle of the thigh in a long

Action of the Hamstring Muscles.

These muscles produce two different effects, according as their fixed point is at the pelvis or the knee. With the fixed point at the pelvis, they bend the knee; with the fixed point at the knee, they take a very important part in maintaining the body erect. For instance, if, when standing, the body be bent at the hip, and the muscles in question

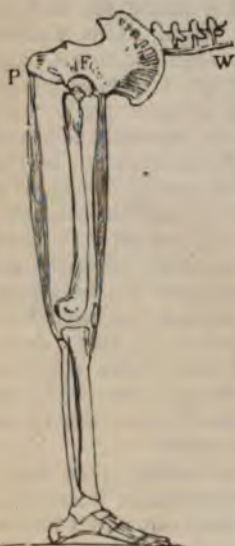

FIG. 239.

be felt, it will be found that they are in strong action, to prevent the trunk from falling forwards; they, too are the chief agents concerned in bringing the body back again to the erect position. In doing this, they act upon a lever of the first order, as shown in Fig. 239; the acetabulum being the fulcrum *F*, the trunk *w*, the weight to be moved, and the power *P* at the tuber ischii.

To put the action of the muscles of the thigh on the pelvis in the clearest point of view, let us suppose we are standing upon one leg: the bones of the lower extremity represent a pillar which supports the weight of the trunk on a ball-and-socket joint; the weight is nicely balanced on all sides, and prevented from falling by four groups of muscles. In front, are the rectus and sartorius; on the inner side, the adductors; on the outer side, the gluteus medius and minimus; behind, the hamstrings and gluteus maximus.

When the knee is semi-flexed, the semimembranosus can also rotate the leg inwards, thus assisting the popliteus; the biceps can also in the same position of the knee rotate the leg slightly outwards.

The hamstring muscles are supplied with blood by the perforating branches of the profunda, which come through the tendon of the adductor magnus close to the femur, and by muscular branches from the popliteal artery. Their nerves are derived from the great sciatic.

Great Sciatic Nerve.

This nerve descends from the gluteal region upon the adductor magnus, and, after being crossed by the long head of the biceps, runs along the outer border of the semimembranosus down the popliteal space. The great sciatic divides into its two terminal divisions at a variable distance from its exit through the great sciatic foramen, sometimes high up, occasionally lower down than usual. The further course of this nerve has already been described (p. 609).

Deferring the course, relations, and branches of the popliteal artery till this vessel is exposed throughout its whole course, pass on now to the dissection of calf.

DISSECTION OF THE BACK OF THE LEG.

The back of the leg gradually narrows from above downwards so as to form a long cone; the upper half is

Surface Marking. The back of the leg is convex and fleshy, corresponding to the gastrocnemius and the soleus muscles; the lower half suddenly diminishes, so that the posterior borders of the tibia and fibula can be easily felt extending to their respective malleoli. In a well-developed subject with not much fat the two heads of the gastrocnemius can be seen through the skin, the inner head being the broader and lower of the two; the tendon into which they are inserted (*tendo Achillis*) rapidly narrows to be attached to the posterior and upper part of the tuberosity of the *os calcis*. On the inner and outer sides of the lower part of this tendon there is a well-defined vertical groove, bounded laterally by the tibia and fibula. In cases of synovial disease of the ankle-joint these grooves are lost, so that instead of a depression there is a convexity. In these grooves can be felt the tendons passing round the ankle behind the malleoli; on the inner side are the *tibialis posticus*, *flexor longus digitorum*, and *flexor longus hallucis*; on the outer side are the *peronei longus* and *brevis*.

Continue the incision down the center of the calf to the heel, where a transverse incision must also be made. The skin should now be reflected, taking care of the subcutaneous veins and nerves.

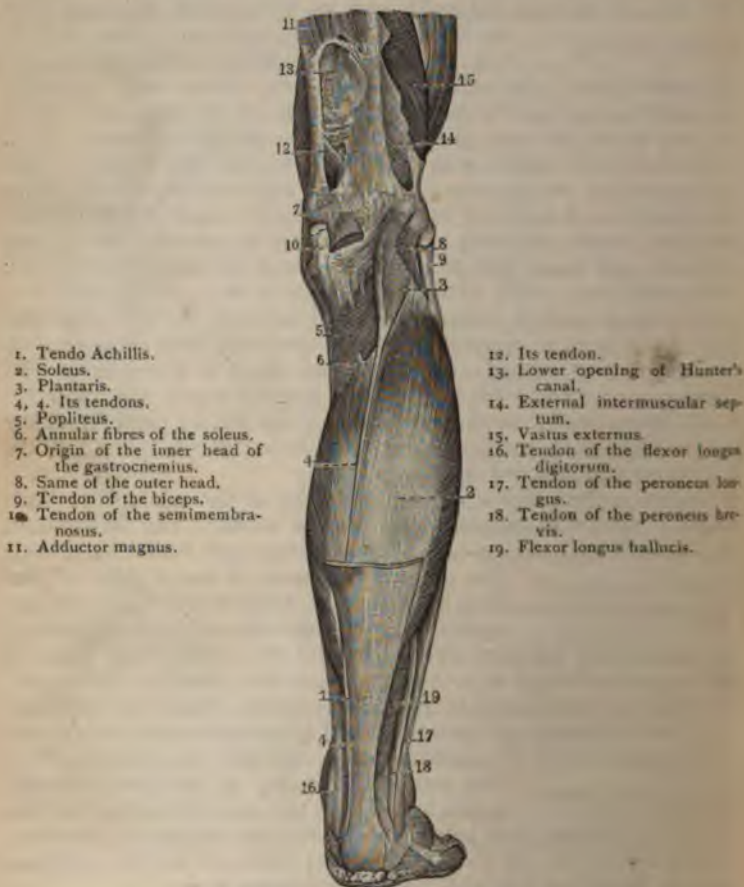Short or Posterior Saphena Vein. The large vein seen in the middle of the back of the leg is called the *short or posterior saphena*. It commences on the outer side of the dorsum of the foot, ascends behind the outer ankle, where it has a communication with the deep veins, and then runs up the calf between the two bellies of the gastrocnemius, receiving numerous veins in its course, and being guarded by several valves. It eventually passes through the muscular fascia, and joins the popliteal vein.

Cutaneous Nerves. The back of the leg is supplied by cutaneous nerves: in the middle, above, by the small sciatic nerve, and below, by the short or external saphenous; on the outer side, by the *communicans peronei*; and on the inner side, by branches from the internal saphenous nerve.

Short or External Saphenous Nerve. The *short saphenous nerve** is derived from the internal popliteal nerve (Figs. 229-236), and passes down beneath the deep fascia

* This nerve is sometimes called the *communicans poplitei*, and does not take the name of short saphenous nerve till its junction with the *communicans peronei* (p. 609).

between the two heads of the gastrocnemius to the middle of the calf, where it pierces the fascia. Here it is joined by a branch from the peroneal nerve (*communicans peronei*); it then descends



1. Tendo Achillis.
2. Soleus.
3. Plantaris.
- 4, 4. Its tendons.
5. Popliteus.
6. Annular fibres of the soleus.
7. Origin of the inner head of the gastrocnemius.
8. Same of the outer head.
9. Tendon of the biceps.
10. Tendon of the semimembranosus.
11. Adductor magnus.

12. Its tendon.
13. Lower opening of Hunter's canal.
14. External intermuscular septum.
15. Vastus externus.
16. Tendon of the flexor longus digitorum.
17. Tendon of the peroneus longus.
18. Tendon of the peroneus brevis.
19. Flexor longus hallucis.

FIG. 240.—MUSCLES OF THE CALF.

with the short saphena vein, usually on its fibular side, and is finally distributed to the outer side of the foot and the little toe.

To expose the muscles of the calf, reflect the muscular fascia by incisions corresponding to those made through the skin.

**Muscles of the
Calf.**

The great flexor muscle of the foot consists of two portions: the superficial one, called the gastrocnemius, *arises* from the lower end of the femur; the deep one, called the soleus, *arises* from the tibia and fibula. They are attached to one thick tendon, called the tendo Achillis, which is *inserted* into the os calcis.

Gastrocnemius.

This muscle arises by two strong tendinous heads from the back of the condyles of the femur (Fig. 240). The inner head is the larger, longer, and more muscular, and *arises* from a depression at the upper and back part of the internal condyle, and, for a short distance, by fleshy fibres from the line leading from the linea aspera to the internal condyle; the outer head from the back and upper part of the external condyle above the popliteus, and also from the line leading to the linea aspera. The two parts of the muscle descend, distinct from each other, and form the two bellies of the calf, of which the inner is rather the lower. Both *terminate*, rather below the middle of the leg, on the broad commencement of the tendo Achillis.

The gastrocnemius should be divided transversely near its attachment to the tendo Achillis, and reflected upwards from the subjacent soleus, as high as its origin. By this proceeding you observe that the contiguous surfaces of the muscles are covered by a glistening tendon, which receives the insertion of their fibres, and transmits their collected force to the tendo Achillis.

Observe also the large sural vessels and nerves (branches of the popliteal) which enter the mesial aspect of each head of the muscle. To facilitate the play of the inner tendon over the condyle, there is a bursa, which generally communicates with the knee-joint; and in the substance of the outer tendon is commonly found a small piece of fibro-cartilage. Lastly, between the gastrocnemius and soleus is the tendon of the plantaris.

Plantaris.

This small muscle* arises from the rough line leading from the linea aspera to the outer condyle of the femur, and from the posterior ligament of the knee-joint. It descends close to the inner side of the outer head of the gastrocnemius, having a fleshy belly for about two inches (5 cm.), and terminates, a little below the knee, in a long, thin tendon, which can be traced down the inner border of the tendo Achillis to the calcaneum. This muscle is occasionally absent. Its nerve comes from the internal popliteal.

* This is the representative of the palmaris longus of the forearm. In man it is lost on the calcaneum, but in monkeys, who have prehensile feet, it is the proper tensor muscle of the plantar fascia. It is remarkably strong in bears and plantigrade mammals.

Soleus.

This muscle arises by tendinous fibres from the head and from the upper third of the posterior surface of the fibula, from the oblique ridge on the back of the tibia,* from about the middle third of the inner border of this bone, and from an aponeurotic arch thrown over the posterior tibial vessels. The muscular fibres bulge out beyond the gastrocnemius, and terminate on a broad tendon, which, gradually contracting, forms a constituent part of the tendo Achillis. The muscle lies upon the flexor longus digitorum, the tibialis posticus, the flexor longus hallucis, and the posterior tibial vessels and nerve. The soleus is supplied with blood by several branches from the posterior tibial; also by a large branch from the peroneal. Its nerve comes from the internal popliteal and enters the top of the muscle. This is an important muscle in a surgical point of view, for two reasons—(1) by reflecting its tibial origin, we can reach the posterior tibial artery; (2) by reflecting its fibular origin we can reach the peroneal.

The *tendo Achillis*, the common tendon of the gastrocnemius and soleus, begins about the middle of the leg, and is at first of considerable breadth, but it gradually contracts and becomes thicker as it descends. The narrowest part of it is about one inch and a half (3.8 cm.) above the heel; here, therefore, it can be most conveniently and safely divided for the relief of club-foot. There is no risk of injuring the deeper-seated parts, because they are separated from the tendon by a quantity of fat. Its insertion is into the under and back part of the tuberosity of the os calcis. The tendon previously expands a little; between it and the bone is a bursa of considerable size.

The *action* of the gastrocnemius and soleus is to raise the body on the toes. Since the gastrocnemius passes over two joints, it has the power (like the rectus) of extending the one while it bends the other, and it is, therefore, admirably adapted to the purpose of walking. For instance, by first extending the foot it raises the body; and then, by bending the knee, it transmits the weight from one leg to the other. Supposing the fixed point to be at the heel, the gastrocnemius is also concerned in keeping the body erect, for it keeps the tibia and fibula perpendicular on the foot, and thus counteracts the tendency of the body to fall forwards.

The *tendo Achillis*, in pointing the toes, acts upon a lever of the *first* order. The fulcrum is at the ankle-joint, *F* (Fig. 241); the resistance, *w*, at the toes; the power at the heel, *P*. All the

* The tibial and fibular origins of the soleus constitute what some anatomists describe as the two heads of the muscle. Between them descend the popliteal vessels, protected by a tendinous arch.

conditions are those of a lever of the first order. The power and the weight act in the *same* direction on *opposite* sides of the fulcrum. In raising the body on tiptoe, the tendo Achillis acts as a lever of the second order; the fulcrum being then at the ball of the great toe, and the weight of the body at the ankle.

Course and Relations of the Popliteal Artery.

After passing through the opening in the tendon of the adductor magnus, the femoral artery takes the name of *popliteal*. It descends nearly perpendicularly behind the knee-joint, between the origins of the gastrocnemius, as far as the lower border of the popliteus, where it divides into the anterior and posterior tibial. In its descent it *lies*, first, upon the lower part of the femur, and here it is slightly overlapped by the semimembranosus; next, it lies upon the posterior ligament of the knee-joint; and, lastly, upon the popliteus. At its lower part the artery is covered, at first by the semimembranosus, the popliteal vein, the internal popliteal nerve, and a considerable amount of fat; then, lower down, by the gastrocnemius and soleus, and it is crossed by the plantaris. The vein closely accompanies the artery, and is situated superficially with regard to it, and rather to its outer side in the first part of its course. The internal popliteal nerve runs also in a similar direction with the vein, but is still more superficial and to the outer side (Fig. 236).

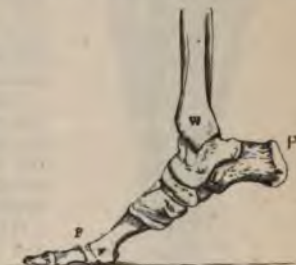

FIG. 241.

The vessels and the nerve are surrounded by fat, and one or two lymphatic glands are generally found in the immediate neighbourhood of the artery, just above the joint.

The branches of the popliteal artery are—the *articular*, the *sural*, and the *cutaneous*.

There are five *articular branches* for the supply of the knee-joint and the articular ends of the bones; the two *superior*—*external* and *internal*—run, one above each condyle, close to the bone; the two *inferior*—*external* and *internal*—run below the joint.

1. The *superior external articular* artery runs above the external condyle, passes beneath the biceps, and through the intermuscular septum: it then divides into a superficial and a deep branch; the superficial supplies the vastus externus, and then forms part of the patellar arterial plexus; the deep branch keeps close to the femur and supplies the knee, forming an arch above the joint with a branch from the anastomotica magna.

2. The *superior internal articular* artery runs above the internal condyle, under the tendon of the adductor magnus and vastus internus, and divides into two branches, a superficial and a deep, which take a corresponding course to those on the outer side.

Soleus.

This muscle arises by tendinous fibres from the head and from the upper third of the posterior surface of the fibula, from the oblique ridge on the back of the tibia,* from about the middle third of the inner border of this bone, and from an aponeurotic arch thrown over the posterior tibial vessels. The muscular fibres bulge out beyond the gastrocnemius, and terminate on a broad tendon, which, gradually contracting, forms a constituent part of the tendo Achillis. The muscle lies upon the flexor longus digitorum, the tibialis posticus, the flexor longus hallucis, and the posterior tibial vessels and nerve. The soleus is supplied with blood by several branches from the posterior tibial; also by a large branch from the peroneal. Its nerve comes from the internal popliteal and enters the top of the muscle. This is an important muscle in a surgical point of view, for two reasons—(1) by reflecting its tibial origin, we can reach the posterior tibial artery; (2) by reflecting its fibular origin we can reach the peroneal.

The *tendo Achillis*, the common tendon of the gastrocnemius and soleus, begins about the middle of the leg, and is at first of considerable breadth, but it gradually contracts and becomes thicker as it descends. The narrowest part of it is about one inch and a half (3.8 cm.) above the heel; here, therefore, it can be most conveniently and safely divided for the relief of club-foot. There is no risk of injuring the deeper-seated parts, because they are separated from the tendon by a quantity of fat. Its insertion is into the under and back part of the tuberosity of the os calcis. The tendon previously expands a little; between it and the bone is a bursa of considerable size.

The *action* of the gastrocnemius and soleus is to raise the body on the toes. Since the gastrocnemius passes over two joints, it has the power (like the rectus) of extending the one while it bends the other, and it is, therefore, admirably adapted to the purpose of walking. For instance, by first extending the foot it raises the body; and then, by bending the knee, it transmits the weight from one leg to the other. Supposing the fixed point to be at the heel, the gastrocnemius is also concerned in keeping the body erect, for it keeps the tibia and fibula perpendicular on the foot, and thus counteracts the tendency of the body to fall forwards.

The *tendo Achillis*, in pointing the toes, acts upon a lever of the *first* order. The fulcrum is at the ankle-joint, *F* (Fig. 241); the resistance, *w*, at the toes; the power at the heel, *P*. All the

* The tibial and fibular origins of the soleus constitute what some anatomists describe as the two heads of the muscle. Between them descend the popliteal vessels, protected by a tendinous arch.

conditions are those of a lever of the first order. The power and the weight act in the *same* direction on *opposite* sides of the fulcrum. In raising the body on tiptoe, the tendo Achillis acts as a lever of the second order; the fulcrum being then at the ball of the great toe, and the weight of the body at the ankle.

Course and Relations of the Popliteal Artery.

After passing through the opening in the tendon of the adductor magnus, the femoral artery takes the name of *popliteal*. It descends nearly perpendicularly behind the knee-joint, between the origins of the gastrocnemius, as far as the lower border of the popliteus, where it divides into the anterior and posterior tibial. In its descent it *lies*, first, upon the lower part of the femur, and here it is slightly overlapped by the semimembranosus; next, it lies upon the posterior ligament of the knee-joint; and, lastly, upon the popliteus. At its lower part the artery is covered, at first by the semimembranosus, the popliteal vein, the internal popliteal nerve, and a considerable amount of fat; then, lower down, by the gastrocnemius and soleus, and it is crossed by the plantaris. The vein closely accompanies the artery, and is situated superficially with regard to it, and rather to its outer side in the first part of its course. The internal popliteal nerve runs also in a similar direction with the vein, but is still more superficial and to the outer side (Fig. 236).



FIG. 247.

The vessels and the nerve are surrounded by fat, and one or two lymphatic glands are generally found in the immediate neighbourhood of the artery, just above the joint.

The branches of the popliteal artery are—the *articular*, the *sural*, and the *cutaneous*.

There are five *articular branches* for the supply of the knee-joint and the articular ends of the bones; the two *superior*—*external* and *internal*—run, one above each condyle, close to the bone; the two *inferior*—*external* and *internal*—run below the joint.

1. The *superior external articular* artery runs above the external condyle, passes beneath the biceps, and through the intermuscular septum: it then divides into a superficial and a deep branch; the superficial supplies the vastus externus, and then forms part of the patellar arterial plexus; the deep branch keeps close to the femur and supplies the knee, forming an arch above the joint with a branch from the anastomotica magna.

2. The *superior internal articular* artery runs above the internal condyle, under the tendon of the adductor magnus and vastus internus, and divides into two branches, a superficial and a deep, which take a corresponding course to those on the outer side.

3. The *inferior external articular artery* runs under the gastrocnemius, over the popliteus, then, passing beneath the external lateral ligament and the tendon of the biceps, it reaches the patella, where it breaks up into branches anastomosing with the other articular arteries, and the recurrent branch of the anterior tibial artery.

4. The *inferior internal articular artery* runs between the tuberosity of the tibia and the internal lateral ligament, and supplies the inner and anterior part of the joint.

5. The *azygos artery* is given off from the deep aspect of the popliteal, pierces the ligamentum posticum Winslowii, to supply the crucial ligaments and the synovial membrane.

The several articular arteries form over the front and sides of the joint a network of vessels, which anastomose, superiorly, with the descending branch of the external circumflex and the *anastomotica magna*; inferiorly, with the anterior tibial recurrent; and also among themselves. It is mainly through these channels that the collateral circulation is established in the leg after ligation of the superficial femoral.

The *sural arteries* proceed one to each head of the gastrocnemius, and are proportionate in size to the muscle; one or two branches are distributed to the soleus. These arteries are accompanied by branches of the internal popliteal nerve for the supply of the muscles.

The *superior muscular branches* supply the vasti and hamstring muscles, and inosculate with the perforating and articular arteries.

Cutaneous arteries pass down between the gastrocnemius and the skin supplying the integument of the calf, as far as the middle of the leg.

Popliteal Vein.

This vein is formed by the junction of the *venæ comites* of the anterior and posterior tibial arteries, and is situated superficial to the artery. It crosses obliquely from the inner to the outer side of the artery, and is continued upwards as the femoral. It receives in the popliteal space the short saphena, the articular, and sural veins. It is usually provided with four valves. The insertion of the tendon of the semimembranosus into the head of the tibia, and its several connections (described p. 615), should now be fully examined.

Popliteus.

This triangular muscle *arises* (Fig. 240, 5) within the capsule of the knee-joint, from a depression on the outside of the external condyle, and from the posterior ligament of the knee, by a thick tendon, which runs beneath the external lateral ligament and the tendon of the biceps. The muscular fibres gradually spread out,

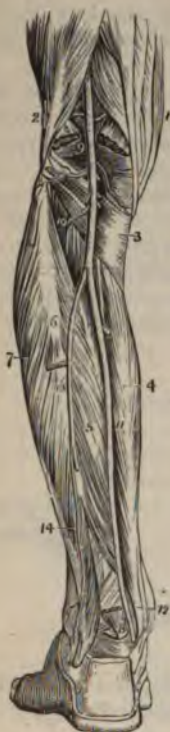

FIG. 242.—POPLITEAL AND POSTERIOR TIBIAL ARTERIES.

1. Tendons of the inner hamstring.
2. Tendon of the biceps.
3. Popliteus m.
4. Flexor longus digitorum.
5. Tibialis posticus.
6. Fibula, with flexor longus hallucis removed.
7. Peroneus longus and brevis.
8. Lower part of the flexor longus hallucis.
9. Popliteal artery.
10. Anterior tibial artery.
11. Posterior tibial artery.
12. Flexor and posterior tibial tendons.
13. Peroneal artery dividing into two branches.
14. Posterior peroneal artery.

and are *inserted* into the triangular surface of the tibia above the soleal ridge on the bone, and into the aponeurotic expansion covering the muscle. It is supplied by a branch of the internal popliteal nerve, which enters its deep surface. Its action is to flex the leg, and then to rotate the tibia inwards. The tendon plays over the articulation between the tibia and fibula; and a bursa intervenes, which generally communicates by a wide opening with the knee-joint. The tendinous origin grooves the external semilunar cartilage, and has an investment from the synovial membrane of the knee.

Reflect the soleus from its origin, and remove it from the deep-seated muscles, observing at the same time the numerous arteries which enter its under surface. This done, notice the deep fascia which separates the superficial and the deep layers of muscles and which binds down the deep muscles. It is attached to the margins of the tibia and the fibula on either side, increases in strength towards the ankle, and form an *internal annular ligament* which confines the tendons and the vessels and nerves in their passage into the sole of the foot.

The deep fascia should now be removed from the deep muscles, which must be cleaned in the course of their muscular fibres.

There are three: the **Deep Muscles on the Back of the Leg.** flexor longus digitorum on the tibial side; the flexor longus hallucis on the fibular; the tibialis posticus upon the interosseous membrane, between and beneath them both.

Flexor Longus Digitorum. This *arises* from the posterior surface of the tibia, commencing below the popliteus, and extending to within four inches (10 cm.) of the lower end of

of the bone, also from the fascial septum between it and the tibialis posticus. The fibres terminate on a tendon which is placed on the tibial side of the muscle, and it runs through a groove behind the inner ankle, lined by a special synovial sheath. It enters the sole

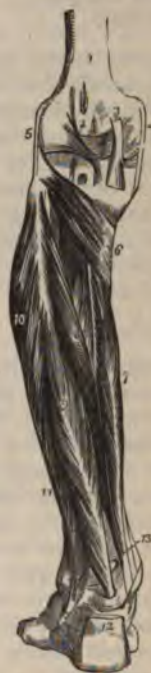

FIG. 243.—DEEP MUSCLES ON THE BACK OF THE LEG.

1. Femur. 2. Posterior ligament (Winslow's). 3. Tendon of semimembranosus dividing into three slips. 4. Internal lateral ligament of the knee-joint. 5. Long external lateral ligament. 6. Popliteus. 7. Flexor longus digitorum. 8. Tibialis posticus. 9. Flexor longus hallucis. 10. Peroneus longus. 11. Peroneus brevis. 12. Tendo Achillis. 13. Tendon of tibialis posticus.

and divides into four tendons, which are inserted into the ungual phalanges of the four outer toes. It is supplied by the posterior tibial nerve.

**Flexor Longus
Hallucis.**

This powerful muscle *arises* from the lower two-thirds of the posterior surface of the fibula, from the septum between it and the peronei, from the lower part of the interosseous membrane, and from the aponeurosis over the tibialis posticus. The fibres terminate on a tendon which runs through a groove on the back of the lower extremity of the tibia, then through the groove on the back of the astragalus, thence it passes through another groove on the under aspect of the sustentaculum tali, and is *inserted* into the ungual phalanx of the great toe. The chief action of this muscle is to raise the body on the tip of the great toe. It is essential to the propulsion of the body in walking. It is supplied by the posterior tibial nerve.

Tibialis Posticus.

This is so concealed between the two preceding muscles that it cannot be properly examined without reflecting them. It *arises* (Fig. 243, 8) by two processes from the interosseous membrane, between which the anterior tibial artery passes forwards, from the opposite surfaces, of the tibia and fibula for about their middle three-fifths, and from the aponeurosis covering it. In the lower part of the leg it passes between the tibia and the flexor longus digitorum. Its muscular fibres terminate on a tendon which comes into view a short distance above the inner ankle, and, running through the same groove with the tendon of the flexor longus digitorum, enters the sole, and is *inserted* into the scaphoid and internal cuneiform bones, and by fibrous prolongations into most of the tarsal and metatarsal bones. Its action is to bend and turn the foot inwards. It is supplied by the posterior tibial nerve. The precise situation of the tendon of the tibialis posticus is interesting, surgically, because the tendon has to be divided for the relief of talipes varus. It lies close to, and parallel with, the inner edge of the tibia, so that this is the guide to it. It is necessary to relax the tendon, while the knife is introduced between the tendon and the bone. Its synovial sheath commences about $1\frac{1}{2}$ inch (3.8 cm.) above the end of the internal malleolus, and is consequently opened in the operation.

Attention should now be directed to the *internal or posterior annular ligament*, which binds down the tendons behind the inner ankle.

It is attached to the internal malleolus and the inner border of the os calcis. It is continuous, above, with the deep fascia of the leg, below with the plantar fascia and the adductor hallucis. Be-

neath it are a series of compartments through which pass the tendons of the deep-seated muscles of the leg and the vessels into the sole of the foot. The relative positions of the structures passing under this ligament, proceeding from within outwards, are—the tendons of the tibialis posticus, and the flexor longus digitorum; the posterior tibial artery accompanied by its venæ comites; the posterior tibial nerve; and, lastly, the tendon of the flexor longus hallucis. Each of the tendons is lined by a separate synovial membrane, as they pass behind the inner ankle.

This artery is one of the branches into which the popliteal divides at the lower border of the popliteus. It descends (Fig. 242) between the superficial and the deep muscles at the back of the leg to the interval between the internal malleolus and the os calcis, and, entering the sole, divides beneath the abductor hallucis into the external and internal plantar arteries. It lies, first, for a short distance, upon the tibialis posticus, then, on the flexor longus digitorum; but behind the ankle it is in contact with the tibia, so that here it can be felt beating, and effectually compressed; and lastly on the back of the ankle-joint. In the upper part of its course, it runs nearly midway between the bones, and is covered by the gastrocnemius and soleus, and is crossed obliquely from within outwards by the posterior tibial nerve. To tie the artery, therefore, in this situation, is difficult; but in the lower part of its course it gradually approaches the inner border of the tibia, from which, generally speaking, it is not more than half or three-quarters of an inch (13 to 18 mm.) distant. Here, being comparatively superficial, it may easily be tied. Immediately behind the internal malleolus, it lies between the tendons of the flexor longus digitorum on the inner side, and the flexor longus hallucis on the outer. It has two venæ comites, which communicate at intervals. The posterior tibial nerve which accompanies the artery is at its upper third on its inner side, then crosses over it, and for the lower two-thirds of its course lies external to the artery. Its branches are as follows:—

a. Numerous muscular branches to the soleus, the peronei, and the deep muscles.

b. The peroneal (Fig. 242) is a branch of considerable size—often as large as the posterior tibial. Arising about an inch (2.5 cm.) below the division of the popliteal, it descends close to the interosseous border of the fibula, and then over the articulation between the tibia and fibula to the outer part of the os calcis, where it anastomoses with the malleolar and plantar arteries. All down the leg it is imbedded among the muscles—being covered; first by the soleus, afterwards by the flexor longus hallucis, by the fibres of which it is more or less surrounded. To both these muscles, to the latter especially, it sends numerous branches, and just above the ankle it gives off a constant one—the anterior peroneal—which passes through the interosseous membrane to the under aspect of the peroneus

tertius, then runs in front of the inferior tibio-fibular articulation, and inosculates with the other malleolar and tarsal arteries. The peroneal supplies the *nutrient* artery of the fibula.

c. The *communicating artery* passes transversely across the interosseous membrane about an inch (2.5 cm.) above the os calcis. It runs under the tendon of the flexor longus hallucis, and anastomoses with the peroneal artery.

d. The *internal calcanean* arteries, several in number, run down, ramifying over the posterior and inner aspect of the tendo Achillis and os calcis: they anastomose with the internal malleolar and peroneal arteries.

e. The *nutrient artery* to the tibia enters the bone about an inch (2.5 cm.) below the oblique line, the foramen through which it passes being directed away from the knee-joint.

The *posterior tibial veins*, formed by the junction of the external and internal plantar veins, accompany the artery as *venae comites*, and, after receiving the peroneal veins, join with the veins corresponding to the anterior tibial artery, at the lower border of the popliteus, to form the popliteal vein.

Posterior Tibial Nerve.

This is the continuation of the popliteal. It descends close to its corresponding artery, and, behind the inner ankle, divides into the external and internal plantar nerves. In the first part of its course the nerve lies superficial to the artery, and rather to its inner side; but lower down the nerve crosses the artery, and passes to its outer side, and lies to the inner border of the tendo Achillis. It supplies branches to the three deep-seated muscles, the branch to the flexor longus hallucis accompanying the peroneal artery; and a cutaneous branch—*calcaneo-plantar*—which pierces the internal annular ligament, and supplies the skin of the heel and the inner side of the sole of the foot.

THE DISSECTION OF THE SOLE OF THE FOOT.

The skin of the sole is remarkably thick, especially over the os calcis and the heads of the metatarsal bones.

Surface Marking. The sole of the foot is convex, and narrow behind, but gradually increases in breadth forwards to the clefts of the toes. The inner arch of the foot, extending from the inner tuberosity of the os calcis to the distal end of the first metatarsal bone, is well marked in a well-developed foot; along this arch can be distinguished the sustentaculum tali; about an inch (2.5 cm.) in front of this is the prominent tubercle of the scaphoid, and another inch (2.5 cm.) in front of this we can feel the articulation between the internal cuneiform and the base of the metatarsal bone of the great toe. The outer arch of the foot is neither so deep nor so long as the inner; it extends from the external tubercle of the os calcis to the base of the metatarsal bone of the little toe, and along it we can recognize the peroneal tubercle of the os calcis and the base of the fifth metatarsal bone. The transverse arch, between

the heads of the metatarsal bones, is not well marked through the skin, for it is obscured by the tense plantar fascia. The plantar fascia can be made tense by extending the foot, when its narrowest part is seen to be about one inch (2.5 cm.) in front of the os calcis. The course of the external plantar artery is indicated by a line drawn from the internal tubercle of the os calcis to the base of the fifth metatarsal bone; that of the internal plantar artery by a line drawn from the same tuberosity to the first interosseous space.

Dissection.

The foot should be firmly fixed to a block with the sole directed towards the dissector, and the toes either fastened by string or nailed to the block, so as to put the plantar fascia on the stretch. Make a perpendicular incision down the middle of the sole; another transverse one across the foot at the clefts of the toes, and continue the perpendicular incision along the middle of the toes to their terminations. Reflect the skin, and notice the peculiar structure of the subcutaneous tissue. It is composed of globular masses of fat, separated by strong fibrous septa, and forms elastic pads, especially marked at the heel, and at the ball of the great and the little toes, these being the points which form the tripod supporting the arch of the foot.

In removing the subcutaneous tissue from the ball of the great and the little toes, we often meet with bursæ, simple or multilocular. They are generally placed between the skin and the sesamoid bones, and have remarkably thick walls. Frequently an artery and nerve can be traced running directly through one of these sacs, which explains the acute pain produced by their inflammation.

Cutaneous Nerves.

In the fat the student must make out the *cutaneous branch* of the posterior tibial nerve, which supplies the skin of the sole of the foot and the heel; the remainder of the sole is supplied by small branches of the plantar nerves which come through the fascia, as in the palm of the hand.

Plantar Fascia.

This is a remarkably dense white and glistening ing fascia. It extends from the under and back part of the os calcis to the distal extremities of the metatarsal bones. It is divided into a strong central and two lateral less dense portions, from which prolongations pass deeply inwards, separating the lateral from the central muscles. The *middle portion*, covering the flexor brevis digitorum, is narrow behind, and, as it passes forwards towards the toes, is spread out, and strengthened by transverse fibrous bands. The *inner portion* is comparatively thin, and surrounds the abductor hallucis, becoming continuous posteriorly with the internal annular ligament. The *outer portion* is thicker than the inner, especially as it passes forwards to be attached to the proximal end of the fifth metatarsal bone. It covers the abductor minimi digiti. Both the inner and the outer portions are con-

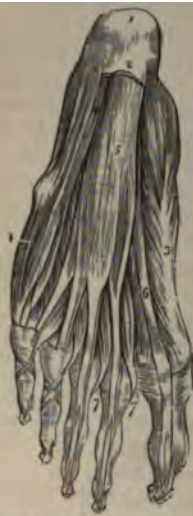

FIG. 244.—SUPERFICIAL MUSCLES OF THE SOLE OF THE FOOT.

1. Calcaneum. 2. Divided plantar fascia. 3. Abductor hallucis. 4. Abductor minimi digiti. 5. Flexor brevis digitorum. 6. Tendon of the flexor longus hallucis. 7. Tendons of the lumbricales. On the second and third toes, the tendons of the flexor longus digitorum are seen passing through the bifurcation of the tendons of the flexor brevis digitorum.

nect
 divis
 betw
 vesse
 in all
 In
 there
 run fi
 and a
 the h
 Th
 move
 the o
 plishe
 muscl
 Superf
 cles at
 calcis
 wards
 the flex
 inner s
 outer o
 Abducto
 internal
 plantar
 ligamen
 tum bet
 torum.

of the great toe, through the medium of the internal sesamoid bone. Its nerve comes from the internal plantar.

**Abductor Minimi
Digiti.**

This muscle lies on the outer border of the foot, and has a very strong *origin* from the under surface of the os calcis, from its external tubercle, from the plantar fascia, and from the external intermuscular septum between it and the flexor brevis digitorum. Some of its fibres terminate on a tendon which is inserted into the proximal end of the metatarsal bone of the little toe; but the greater part run on to a tendon which is *inserted*, with the flexor brevis minimi digiti, into the outer side of the first phalanx of the little toe. It is supplied by the external plantar nerve.

**Flexor Brevis
Digitorum.**

This muscle *arises* from the under surface of the os calcis, between the two preceding, from the deep surface of the plantar fascia and the intermuscular septa. It passes forwards and divides into four tendons, which run superficial to those of the long flexor. Cut open the sheath which contains them; follow them on to the toes, to see that each bifurcates over the first phalanx, to allow the long tendon to pass through; then the two slips, reuniting, are inserted into the sides of the second phalanx. The same arrangement prevails in the fingers. It is supplied by the internal plantar nerve.

The three superficial muscles should now be reflected by sawing off about half an inch (*13 mm.*) of the os calcis, and then turning it downwards with the muscles attached to it. This done, we bring into view the plantar vessels and nerves, and the second

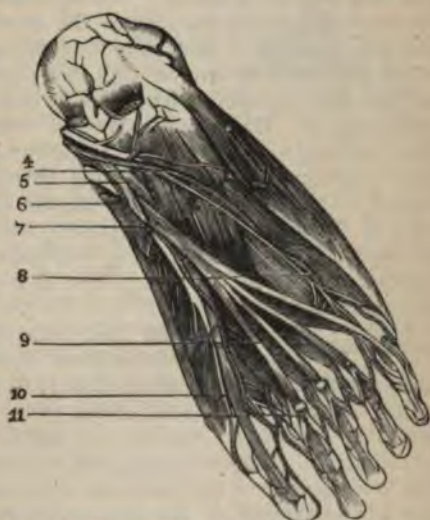

FIG. 245.—MUSCLES, VESSELS, AND NERVES OF THE SOLE OF THE RIGHT FOOT, AFTER REFLECTION OF THE FLEXOR BREVIS DIGITORUM.

1. Abductor minimi digiti. 2. Flexor accessorius. 3. Abductor hallucis. 4. External plantar artery and nerve. 5. Tendon of flexor longus hallucis. 6, 7. Internal plantar artery and nerve. 8. Flexor brevis minimi digiti. 9. Lumbricales. 10. Internal plantar nerve. 11. Tendons of the flexor brevis digitorum bifurcating for the passage of the tendons of the flexor longus digitorum.

tinuous with the fascia of the dorsum of the foot round the inner and outer borders of the foot, and with the central portion of the plantar fascia towards the centre of the sole.

Near the distal ends of the metatarsal bones, the central part divides into five portions: each of these subdivides into two slips, which embrace the corresponding flexor tendons, and are attached to the metatarsal bones and their connecting ligaments. Between the primary divisions of the fascia—that is, in a line between the toes—are seen the digital vessels and nerves. This arrangement is in all respects like that in the palm.

In the interdigital folds of the skin there are also ligamentous fibres, which run from one side of the foot to the other, and answer the same purpose as those in the hand (p. 340).

The plantar fascia must be partially removed to examine the muscles. Towards the os calcis its removal is not accomplished without some difficulty, since the muscles arise from it.

After the removal of the fascia three muscles are exposed. All arise from the os calcis and the fascia, and proceed forwards to the toes.* The central one is the flexor brevis digitorum, the one on the inner side is the abductor hallucis, and the outer one is the abductor minimi digiti.

Abductor Hallucis. This muscle arises (Fig. 244) from the internal tubercle of the os calcis, from the plantar fascia, from the internal annular ligament, and from the intermuscular septum between it and the flexor brevis digitorum. Its origin arches over the plantar vessels and nerves in their passage to the

sole. The fibres run along the inner side of the sole, and terminate on a tendon, which is *inserted* with the inner tendon of the flexor brevis hallucis into the inner side of the base of the first phalanx

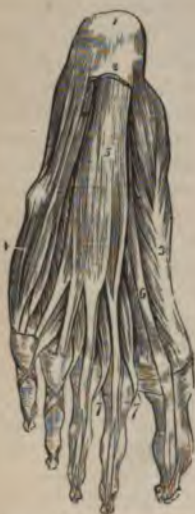

FIG. 244.—SUPERFICIAL MUSCLES OF THE SOLE OF THE FOOT.

1. Calcaneum. 2. Divided plantar fascia. 3. Abductor hallucis. 4. Abductor minimi digiti. 5. Flexor brevis digitorum. 6. Tendon of the flexor longus hallucis. 7, 7. Tendons of the lumbricales. On the second and third toes, the tendons of the flexor longus digitorum are seen passing through the bifurcation of the tendons of the flexor brevis digitorum.

* They are separated from each other by strong perpendicular partitions—intermuscular septa—which pass in from the plantar fascia.

artery; it passes forwards between the abductor hallucis and the flexor brevis digitorum to the base of the great toe, and then is continued along the inner side of that toe, where it terminates in small inosculation with the digital arteries. Its chief use is to supply the muscles between which it runs.

The *external plantar* is the principal artery of the sole, and alone forms the plantar arch (Figs. 245 and 246). It runs obliquely outwards across the sole towards the base of the fifth metatarsal bone, then, sinking deeply, it bends inwards across the bases of the metatarsal bones, and inosculates with the communicating branch of the dorsalis pedis in the first interosseous space. At first it lies between the os calcis and the abductor hallucis; it then passes between the flexor brevis digitorum and the flexor accessorius; still continuing its course forwards, it is placed between the flexor brevis digitorum and the flexor brevis minimi digiti, covered only with skin, fat, and plantar fascia, and, lastly, it lies deep beneath the flexor tendons, the lumbricales, the adductor hallucis, upon the interossei muscles. Deeply seated as it appears to be, that part of its curve near the fifth metatarsal bone lies immediately beneath the fascia.

The external plantar sends two or three *internal calcanean* branches to the skin of the heel—one round the outer edge of the foot, which anastomoses with the tarsal and metatarsal branches of the arteria dorsalis pedis, and also some cutaneous branches which emerge between the adjacent borders of the flexor brevis minimi digiti and the flexor brevis digitorum. It also gives off:—

The *digital arteries*, four in number, which arise from the deepest part of the arch. They supply both sides of the fifth, fourth, third, and the outer side of the second toes, and, running forwards along the interossei, divide at the clefts of the toes into two branches, which supply the contiguous sides of the adjacent toes. At the point of division the digital arteries send upwards through the front part of the three outer interosseous spaces, small branches, *anterior perforating*, which anastomose on the dorsum of the foot with the interosseous arteries.

The *posterior perforating* are three branches which perforate the back part of the three outer interosseous spaces, and inosculate with the dorsal interosseous arteries at each end of the spaces.

The *digital artery*, supplying the inner side of the great toe and the adjacent sides of the great and second toes, comes from the communicating branch of the dorsal artery of the foot which pierces the back of the first interosseous space to get to the sole of the foot. It is joined here by a branch from the external plantar artery.

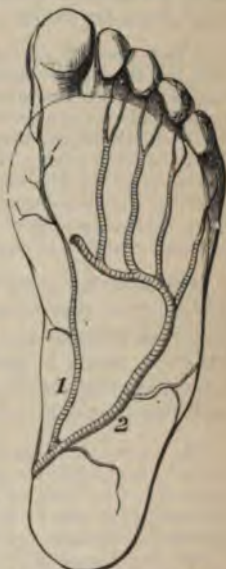

FIG. 246.—1. Internal plantar artery. 2. External plantar artery.

layer of muscles, *i.e.*, the long flexor tendon of the great toe, that of the other toes, and the flexor accessorius.

Tendon of the Flexor Longus Digitorum.

Musculus Accessorius.

Tracing this tendon into the sole, you find that an accessory muscle is attached to it. The *flexor accessorius* arises by muscular fibres from the inner concave side of the os calcis and the calcaneo-scapoid ligament, and by tendinous fibres from the outer side in front of the external tubercle, and from the long plantar ligament. Its fibres run straight forwards, and are inserted into the fibular side of the upper surface of the tendon, so that their action is not only to assist in bending the toes, but to make the common tendon pull in a straight line towards the heel, which, from its oblique direction, it could not do without the accessory muscle. The common tendon then divides into four, one for each of the four outer toes. These run in the same sheath with the short tendons, and, after passing through their divisions, are inserted into the bases of the unguis phalanges. Respecting the manner in which the tendons are confined by fibrous sheaths, and lubricated by a synovial lining, what was said of the fingers (p. 347) applies equally to the toes. The flexor accessorius is supplied by the external plantar nerve.

Lumbricales.

These four little muscles are placed between the long flexor tendons. Each, excepting the most internal, which is attached only to the inner side of the tendon going to the second toe, *arises* from the adjacent sides of two tendons, proceeds forwards, and then, sinking between the toes, terminates in an aponeurosis which passes round the inner side of the four outer toes, and *joins* the extensor tendon on the dorsum of the first phalanges of the toes. Concerning their use, refer to p. 348. The two outer lumbricales are supplied by the external, the two inner by the internal plantar nerve.

Now trace the long flexor tendon of the great toe. From the groove in the astragalus it runs along the groove in the lesser tuberosity of the os calcis, above, that is nearer to the bones than the tendon of the flexor longus digitorum, between the two heads of the flexor brevis hallucis, and then straight to the base of the last phalanx. It crosses the long flexor tendon of the toes, and the two tendons are connected by an oblique slip, so that we cannot bend the other toes without the great toe.

Plantar Arteries.

The posterior tibial artery, having entered the sole between the origins of the abductor hallucis, divides into the external and internal plantar arteries (Fig. 245).

The *internal plantar artery* is smaller than the external plantar

the first phalanx of the great toe. The inner tendon is inseparably connected with the abductor hallucis, the outer with the adductor hallucis. In each tendon there is a sesamoid bone. These bones not only increase the strength of the muscle, but, both together, form a pulley for the free play of the long flexor tendon, so that in

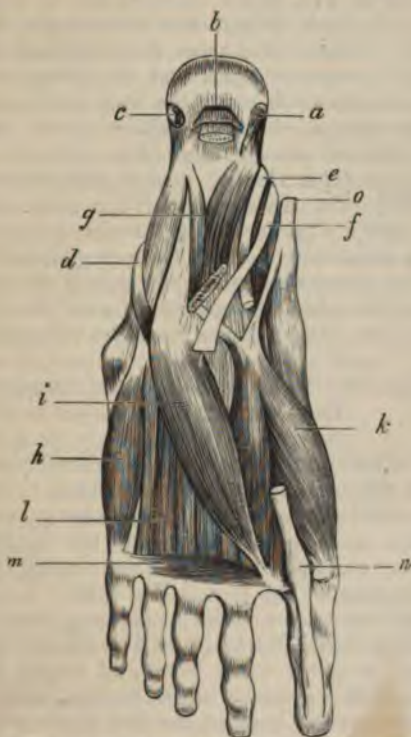

FIG. 247.—VIEW OF THE THIRD LAYER OF MUSCLES OF THE FOOT.

a. Abductor hallucis. *b.* Flexor brevis digitorum. *c.* Abductor minimi digiti. *d.* Tendon of peroneus longus. *e, n.* Flexor longus hallucis. *f.* Tendon of flexor longus digitorum. *g.* Flexus-accessorius. *h.* Flexor brevis minimi digiti. *i.* Adductor hallucis. *k.* Flexor brevis hallucis. *l.* Interossei. *m.* Transversalis pedis. *o.* Tibialis posticus.

walking the tendon is not pressed upon. Its nerve comes from the internal plantar (Fig. 247, *k*).

Adductor Hallucis. This very powerful muscle *arises* from the bases of the second, third, and fourth metatarsal bones, and from the sheath of the peroneus longus. Passing obliquely forwards and inwards across the foot, it is *inserted* through

Plantar Nerves.

The posterior tibial nerve divides, like the artery, into an external and internal plantar (Fig. 245).

The *internal plantar nerve* is the larger, and runs with its corresponding artery along the inner side of the foot between the abductor hallucis and the flexor brevis digitorum; in this part of its course it distributes *cutaneous branches* to supply the skin of the sole, *muscular branches* to the two above-named muscles, and *articular branches* to the joints of the tarsus and metatarsus.

It then gives off *four digital branches* which supply the three inner toes and a half, like the median in the palm; the *first* digital branch runs along the inner side of the great toe to its tip, and in its passage gives off a branch to the flexor brevis hallucis; the *second* divides into two branches, one which supplies the inner lumbricalis, and the other the contiguous borders of the great and second toes; the *third* sends a filament to the second lumbrical, and then bifurcates for the supply of the adjacent sides of the second and third toes; the *fourth*, after receiving a communicating filament from the external plantar nerve, is distributed to the contiguous sides of the third and fourth toes. These digital nerves send off small branches to supply the dorsum of the toes at the last phalanges.

The *external plantar nerve* passes obliquely forwards and outwards with the artery of the same name, passing between the flexor accessorius and the flexor brevis digitorum, to the former of which it sends a muscular branch; it then runs along the inner border of the abductor minimi digiti, supplies it, and then divides into two branches, a superficial and a deep.

The *superficial branch* sends one *digital branch* which supplies the flexor brevis minimi digiti, the plantar and dorsal interossei of the fourth space, and the outer side of the little toe; and another and larger *digital branch* which supplies the contiguous sides of the fourth and fifth nerves, and sends a communicating filament to the outer digital branch of the internal plantar nerve.

The *deep branch* accompanies the plantar arch deep into the sole of the foot, beneath the adductor hallucis, and furnishes branches to the plantar and dorsal interossei of all the interosseous spaces except the fourth, the adductor hallucis, the transversalis pedis, and the two outer lumbricales.

Third Layer of Muscles.

Having traced the principal vessels and nerves, divide them with the flexor tendons near the os calcis, and turn them down towards the toes, to expose the deep muscles in the sole. These are, the flexor brevis and adductor hallucis, the flexor brevis minimi digiti, and the transversalis pedis.

Flexor Brevis Hallucis.

This muscle *arises* by a pointed tendon from the cuboid bone, and from the fibrous prolongation of the tibialis posticus into the external cuneiform. It proceeds along the metatarsal bone of the great toe, and divides into two portions, which run one on each side of the long flexor tendon, and are *inserted* by tendons into the sides of

the first phalanx of the great toe. The inner tendon is inseparably connected with the abductor hallucis, the outer with the adductor hallucis. In each tendon there is a sesamoid bone. These bones not only increase the strength of the muscle, but, both together, form a pulley for the free play of the long flexor tendon, so that in

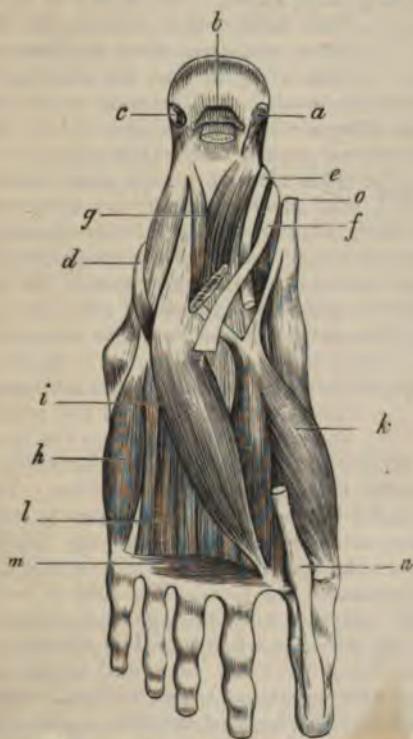

FIG. 247.—VIEW OF THE THIRD LAYER OF MUSCLES OF THE FOOT.

a. Abductor hallucis. *b.* Flexor brevis digitorum. *c.* Abductor minimi digiti. *d.* Tendon of peroneus longus. *e, n.* Flexor longus hallucis. *f.* Tendon of flexor longus digitorum. *g.* Flexus-accessorius. *h.* Flexor brevis minimi digiti. *i.* Adductor hallucis. *k.* Flexor brevis hallucis. *l.* Interossei. *m.* Transversalis pedis. *o.* Tibialis posticus.

walking the tendon is not pressed upon. Its nerve comes from the internal plantar (Fig. 247, *k*).

Adductor Hallucis. This very powerful muscle arises from the bases of the second, third, and fourth metatarsal bones, and from the sheath of the peroneus longus. Passing obliquely forwards and inwards across the foot, it is inserted through

the external sesamoid bone into the outer side of the base of the first phalanx of the great toe together with the inner head of the flexor brevis. This muscle greatly contributes to support the arch of the foot. Like the adductor of the thumb, it should be considered as an interosseous muscle. Its nerve is derived from the external plantar (Fig. 247, *i*).

**Flexor Brevis
Minimi Digiti.**

This little muscle rests on the fifth metatarsal bone, and *arises* from the base of the fifth metatarsal bone and the sheath of the peroneus longus; it proceeds forwards along the bone, and is *inserted* into the outer side of the base of the first phalanx of the little toe. It is supplied by the external plantar nerve (Fig. 247, *h*).

Transversalis Pedis.

This slender muscle runs transversely across the distal ends of the metatarsal bones. It *arises* by little fleshy slips from the inferior metatarso-phalangeal ligaments of the three outer toes and the transverse ligament of the metatarsus, and is *inserted* into the outer side of the first phalanx of the great toe with the adductor hallucis, of which it ought to be considered a part. Its nerve comes from the external plantar (Fig. 247, *m*).

The fourth layer of muscles consists of the interossei.

Interossei.

These muscles are arranged nearly like those in the hand. They occupy the intervals between the metatarsal bones, and are seven in number, four being on the dorsal aspect of the foot, three on the plantar. The four *dorsal interossei* arise each by two heads from the contiguous sides of the metatarsal bones, and are *inserted* into the bases of the first phalanges, and into the aponeurosis of the extensor communis digitorum on the dorsum of the toes. The first is inserted into the inner side of the second toe; the remaining three into the outer sides of the second, third, and fourth. The *plantar interossei*, three in number, arise from the inner sides and under surfaces of the third, fourth, and fifth metatarsal bones, and are *inserted* respectively into the inner sides of the bases of the first phalanges of the third, fourth, and fifth toes, and into the aponeurosis of the common extensor tendon.

The use of the interosseous muscles is to draw the toes to or from each other, and they do the one or the other according to the side of the phalanx on which they act. Now, if we draw a longitudinal line through the second toe, we find that all the dorsal muscles draw from that line, and the plantar towards it. This is the key to the action of them all. A more detailed account of these muscles is given in the dissection of the hand (p. 378). Between the tendons of the interossei—that is, between the distal ends of the metatarsal bones, there are bursæ which facilitate movement. They

sometimes become enlarged and occasion painful swellings between the roots of the toes. The flexor brevis minimi digiti, the transversalis pedis, and all the interossei, are supplied by the external plantar nerve.

Now trace the tendons of the peroneus longus and tibialis posticus. The tendon of the *peroneus longus* is the deepest in the sole. It runs through a groove in the cuboid bone obliquely across the sole towards its insertion into the outer side of the base of the metatarsal bone of the great toe and into the internal cuneiform bone; not infrequently it has a fasciculus of attachment into the second metatarsal bone. It is confined in a strong fibrous sheath, lined throughout by synovial membrane.

The tendon of the *tibialis posticus* may be traced over the internal lateral ligament of the ankle, and thence under the head of the astragalus to the tuberosity of the scaphoid, and the internal cuneiform bones. Prolongations are sent off to the cuneiform bones, to the cuboid, to the sustentaculum tali, and to the bases of the second, third, and fourth metatarsal bones. Observe that the tendon contributes to support the head of the astragalus, and that for this purpose it often contains a sesamoid bone. This is one of the many provisions for the maintenance of the arch of the foot.

DISSECTION OF THE LIGAMENTS.

The sacrum is united to the last lumbar vertebra in the same manner as one vertebra is to another, viz., by the prolongation of the anterior and posterior common ligaments, the intervertebral fibro-cartilage, the ligamenta subflava, supra- and interspinous ligaments, and the capsular ligaments. The student should, therefore, refer to the description of the ligaments of the spine (p. 284).

The *ilio-lumbar ligament* is very strong, and extends directly outwards from the tip of the transverse process of the last lumbar vertebra to the crest of the ilium (Fig. 248).

The *lumbo-sacral ligament* varies much in its extent and attachment, and passes from the anterior and lower border of the transverse process of the fifth lumbar vertebra to the lateral part of the base of the sacrum; the fibers as they descend obliquely outwards become frayed out, joining in part the anterior sacro-iliac ligament.

Ligaments of the
Sacrum and
Coccyx.

The sacrum is connected with the coccyx by means of an anterior and a posterior sacro-coccygeal ligament and by an intervertebral fibro-cartilage.

The *posterior sacro-coccygeal ligament* is a flattened fasciculus of

fibres extending from the lower margin of the sacral canal to the posterior surface of the coccyx; this ligament closes in the inferior termination of the sacral canal.

The *anterior sacro-coccygeal ligament* is a thin band of fibers passing along the front of the sacrum to the coccyx.

The *intervertebral disc* is a thin layer of fibro-cartilage, firm in the centre, thinner laterally and in front and behind, with occasionally a synovial membrane. Laterally, there are some irregular strands of fibers, the *lateral ligaments*, which extend from the lower lateral part of the sacrum to the transverse process of the coccyx.

The segments of the coccyx are in early life separated by interposed fibro-cartilages, which subsequently ossify; they have in front and behind a continuation of the anterior and posterior common ligaments.

The innominate bones are connected to each other in front, constituting the *symphysis pubis*; posteriorly, to the sacrum, forming the *sacro-iliac symphysis*.

Sacro-iliac Articulation.

This articulation is an example of that form of amphiarthrodial joints where the surfaces are covered with fibro-cartilage, with an incomplete synovial membrane. The articulation is formed between the auricular surfaces of the lateral portions of the sacrum and ilium. The anterior part of the bones forming this articulation is incrustated with articular cartilage, of which the shape is like that of the ear. Later in life these two surfaces are more or less connected by thin interarticular transverse fibers, so that the interval between them is very irregular, and frequently contains yellow, viscid material. In front of the articulation there is the anterior sacro-iliac ligament, and behind, the posterior sacro-iliac ligament.

The *anterior sacro-iliac ligament* consists of thin ligamentous fibres passing in front of the sacrum and ilium (Fig. 248).

The *posterior sacro-iliac ligament* (Fig. 249) is composed of fibers much stronger and more marked, which pass behind the articulation. It consists of two portions: the upper, or *horizontal*, extends from the upper two transverse tubercles of the sacrum, and is attached to the rough surface of the ilium above the auricular surface; the lower, or *oblique*, is a well-marked fasciculus of fibres, the *oblique sacro-iliac ligament*, passing from the posterior superior spine to the third segment of the sacrum.

Sacro-sciatic Ligaments.

These are two strong ligaments passing from the sacrum to the ischium.

The *great sacro-sciatic ligament* (Fig. 249, 2) is triangular and thick, but narrower in the middle than at either extremity. Its base is broad, and is attached to the posterior inferior iliac spine,

and to the sides of the sacrum and coccyx; rapidly narrowing, it descends obliquely outwards towards the tuberosity of the ischium, where it again expands to be attached to the inner margin of this bone. This attached portion is continued upwards for some distance as a prolongation, the *falciform process*, into the inner margin of the ramus of the ischium, where it becomes continuous with the obturator fascia, forming a protection for the pudic vessels and nerve.

The *lesser sacro-sciatic ligament* (Fig. 249, 3) lies in front of the

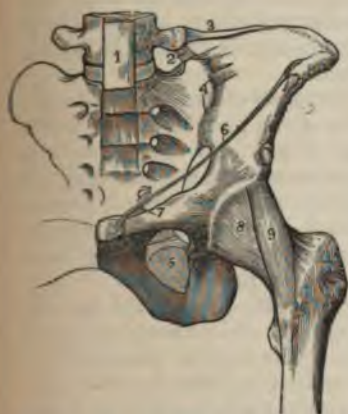

FIG. 248.—LIGAMENTS OF THE PELVIS AND HIP-JOINT.

1. Lower part of the anterior common ligament of the vertebrae, extending downwards over the front of the sacrum.
2. Lumbo-sacral ligament.
3. Lumbo-iliac ligament.
4. Anterior sacro-iliac ligament.
5. Obturator membrane.
6. Poupart's ligament.
7. Gimbernat's ligament.
8. Capsular ligament of the hip-joint.
9. Ilio-femoral or accessory ligament.

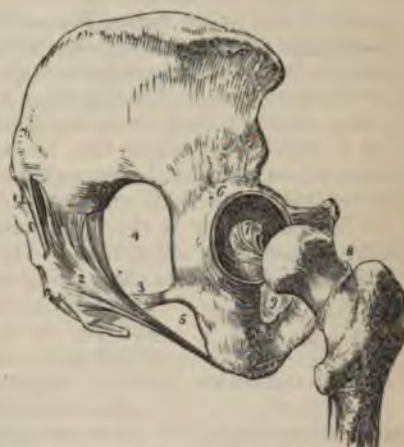

FIG. 249.—LIGAMENTS OF THE HIP-JOINT.
(Lateral view.)

1. Oblique sacro-iliac. The other portions of this ligament are not seen in this view.
2. Posterior sacro-sciatic (greater).
3. Anterior sacro-sciatic (lesser).
4. Great sacro-sciatic foramen.
5. Lesser sacro-sciatic foramen.
6. Cotyloid ligament.
7. Ligamentum teres.
8. Divided capsular ligament.
9. Obturator membrane only partly seen.

preceding ligament, and, like it, is triangular, though smaller and shorter. It passes from the sides of the sacrum and coccyx to the spine of the ischium, where it narrows considerably. The attachments of the sacro-sciatic ligaments to the sacrum and coccyx are more or less blended, and they not only serve to connect the bones, but also, from their great breadth, contribute to diminish the lower aperture of the pelvis.

Pubic Symphysis.

This is formed by the union of the pubic bones, in front, by means of an interposed

piece of fibro-cartilage. It is an amphiarthrodial articulation, and is secured by the following ligaments:—

The *anterior pubic ligament* consists of several layers of irregular superficial fibres which run obliquely and decussate with each other, and of deeper fibres which pass transversely across from one bone to the other, and are connected with the fibro-cartilage.

The *posterior pubic ligament* consists of fibres, less distinct than the anterior, which connect the two pubic bones posteriorly.

The *superior pubic ligament* passes across the upper surface of the pubic bones.

The *subpubic ligament* is very strong, and extends between the rami of the pubic bones, beneath the fibro-cartilage with which it is blended; it rounds off the pubic arch, and is situated between the two layers of the triangular ligament.

The *intermediate fibro-cartilage* is composed of two layers of cartilage, each attached to the inner border of the body of the os pubis by a number of nipple-like processes fitting into corresponding depressions on the bony surface. Between these cartilaginous plates there is a thick stratum of fibrous and fibro-elastic tissue. In the middle line at the upper and back part is usually a smooth cavity lined with epithelium. The cartilage acts as a buffer, and breaks the force of shocks passing through the pelvic arch.*

Ligaments of the Hip-joint.

This joint is secured by the form of the bones, and by the strength of the powerful muscles which surround it. Although an enarthrodial or ball-and-socket joint, its range of motion is somewhat limited; the disposition of its ligaments restricts its range of motion to those directions only which are most consistent with the maintenance of the erect attitude and the requirements of this part of the skeleton.

The ligaments of the hip-joint are—the capsular, the ilio-femoral, the ligamentum teres, the cotyloid, and the transverse.

Capsular Ligament. The *capsular ligament* (Fig. 248, 8) is attached above to the circumference of the acetabulum, a little external to the margin, also to the transverse ligament, and by a few fibres to the outer margin of the obturator foramen; below, to the anterior intertrochanteric ridge in front; above, to the root of the great trochanter, and to the middle of the neck behind, about half an inch (13 mm.) above the posterior intertrochanteric ridge. The anterior and upper part of the capsular ligament

* It must be remembered that ordinarily there is no motion in this joint, but that pregnancy occasionally causes a laxity in this joint which when marked causes great pain while walking. As this joint is now subjected to section in malformed pelvis or abnormality in the child, advantage may be taken of this relaxed condition in the operation. (A. H.)

is very thick and strong, composed chiefly of longitudinal fibres with a few deeply seated circular fibres, which are concealed by the superficial longitudinal bands. The posterior aspect of the capsular ligament is represented by a few sparsely scattered fibres. The front part of the ligament is rendered exceeding strong by several accessory ligaments, one of which, called the *ilio-femoral ligament*, extends from the anterior inferior iliac spine, and from a depression above the acetabulum, and then divides like the two arms of the inverted letter λ ; one, the inner and vertical, passes to the base of the lesser trochanteric; the outer, to the upper part of the anterior intertrochanteric line. In addition, there is at the lower and back part a broad ligament, the *ischio-capsular ligament*, whose fibres extend from the ischium to the inner part of the joint, close to the lesser trochanter; and a third accessory ligament, the *pubo-femoral*, consists of the thin fibres converging from the ilio-pectineal eminence, and the margin of the obturator foramen to the front and inner part of the capsular ligament.

The ilio-femoral ligament is very strong, and serves as a strap to prevent the femur being extended beyond a certain point, and limits rotation inwards and outwards.

The capsule is in relation, in front, with the iliacus and psoas muscles, from which it is separated by a synovial bursa. This bursa occasionally communicates by a rounded aperture with the synovial cavity of the hip-joint.

Open the capsule to ascertain its great thickness in front and its strong attachment to the bones. This exposes the cotyloid ligament and the ligamentum teres.

Ligamentum Teres. The *ligamentum teres* is exposed by drawing the head of the femur out of the socket. This ligament is somewhat flat and triangular. Its base, which is bifid, is attached below to the borders of the notch in the acetabulum, where it becomes continuous with the transverse ligament; its apex, to the fossa in the head of the femur. To prevent pressure on it, and to allow free room for its play, there is a gap at the bottom of the acetabulum. This gap is not crusted with cartilage like the rest of the socket, but is occupied by soft fat. The ligamentum teres is surrounded by the synovial membrane. An artery runs up with it to the head of the femur. It is a branch of the obturator, and enters the acetabulum through the notch at the lower part.

The chief use of the ligamentum teres is to assist in steadying the pelvis on the thigh in the erect position. In this position the ligament is vertical and quite tight (Fig. 250); it therefore prevents the pelvis from rolling towards the opposite side, or the thigh from being adducted beyond a certain point. Another purpose

served by this ligament is to limit rotation of the thigh, both inwards and outwards.

Cotyloid Ligament. The *cotyloid ligament* is an annular piece of fibro-cartilage which is attached all round the margin of the acetabulum. Its circumference is thicker than its free margin, which is very thin, so that on a transverse section the cartilage is triangular. Both its surfaces are covered with synovial membrane, and its attachment to the margin of the acetabulum is effected by oblique fibres passing from without inwards, and interlacing in all directions at an acute angle. The ligament is thicker

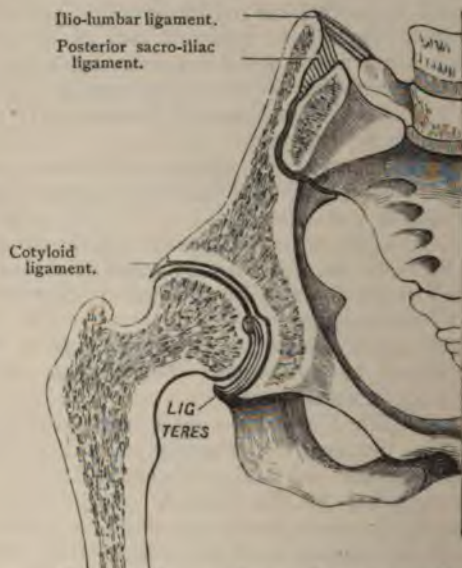


FIG. 250.—VERTICAL SECTION THROUGH THE HIP.

above and behind than elsewhere; it thus deepens the socket, and embraces the head of the femur like a sucker. It extends over the notch at the lower part of the acetabulum, being attached to a ligament, the *transverse*, which passes across the notch, and thus converts it into a foramen. Beneath the transverse ligament some of the vessels and nerves pass into the joint to supply it.

Transverse Ligament.

The *synovial membrane* extends from the cartilaginous border of the head, round the neck as far as the attachment of the capsular ligament, on the inner

surface of which it is reflected as far as the margin of the acetabulum. Thence it passes over the superficial surface of the cotyloid ligament, curves round its inner sharp border so as to line its deeper surface; it then covers the osseous surface of the acetabulum, and is finally continued as a tubular sheath over the ligamentum teres to the head of the femur. The synovial membrane, it will be seen, extends down to the base of the neck of the femur in *front*, but only two-thirds *behind*. Between the bottom of the acetabulum, as far as the cotyloid notch and the synovial membrane, is a collection of fat and connective tissue called the *gland of Havers*.

The ligaments of the hip-joint are so arranged that when we stand "at ease" the pelvis is spontaneously thrown into a position in which its range of motion is the most restricted; for the accessory ligaments of the capsule prevent it from being extended beyond a straight line, and the ligamentum teres prevents its rolling towards the opposite side. This arrangement economises muscular force in balancing the trunk.

The atmospheric pressure is, of itself, sufficient to keep the limb suspended from the pelvis, supposing all muscles and ligaments to be divided. When fluid is effused into the hip-joint the bones are no longer maintained in accurate contact; and it sometimes happens that the head of the femur escapes from its cavity, giving rise to a spontaneous dislocation.

The *movements at the hip-joint* are those of flexion, extension, abduction, adduction, rotation, and circumduction.

The *flexors* are, the ilio-psoas, the sartorius, the pectineus, the adductor longus and brevis, the gluteus medius and minimus.

The *extensors* are, the gluteus maximus, the biceps, semitendinosus, and the semimembranosus.

The *abductors* are, the upper fibres of the gluteus maximus, the gluteus medius and minimus, the pyriformis, and when the joint is flexed, the obturator internus and the two gemelli.

The *adductors* are, the three adductors, the pectineus, the gracilis, and the sartorius.

The *external rotators* are, the three adductors, the pectineus, the gluteus maximus, the posterior fibres of the gluteus medius, the obturator externus and internus, the gemelli, the quadratus femoris, the pyriformis, and the sartorius.

The *internal rotators* are, the ilio-psoas occasionally,* the tensor

* Although the ilio-psoas has been formerly classified as an external rotator, it can be readily demonstrated to be just the reverse. Attention has been called to this point in Morris' Anatomy, Amer. Ed., p. 366. (A. H.)

fasciæ femoris, the anterior fibres of the gluteus medius, and the gluteus minimus.

Circumduction is effected by the successive action of the different muscles in the order of their attachment into the femur.

The muscles in immediate relation with the hip-joint are, in front, the iliacus and psoas; on the outer side, the reflected tendon of the rectus, the gluteus minimus; behind, the pyriformis, gemellus superior, obturator internus, gemellus inferior, obturator externus, and quadratus femoris; on the inner side, the pectineus and obturator externus.

**Ligaments of the
Knee-joint.**

The knee-joint is a ginglymus or a hinge-joint, and the bones entering into its formation are, above, the condyles of the femur, below, the head of the tibia, and in front, the patella. Looking at the skeleton, one would suppose that it was very insecure; but this insecurity is only apparent, the joint being surrounded by powerful ligaments, and a thick capsule formed by the tendons of the muscles which act upon it.

First examine the tendons concerned in the protection of the knee-joint. In front is the ligamentum patellæ; on each side are the tendons of the vasti; on the outer side, in addition, it is strengthened by the strong ilio-tibial band; on the inner side there are also the tendons of the sartorius and gracilis; at the back of the joint are the tendons of the gastrocnemius and plantaris, with the semimembranosus and semitendinosus, in addition, on its inner part, and the tendons of the popliteus and biceps on its outer part. It deserves to be mentioned that the weakest part of the articulation is near the tendon of the popliteus, which arises *within* the joint; here, therefore, pus or fluid formed in the popliteal space may make its way into the joint, or vice versâ.

The ligaments of the joint may be divided into those outside the joint and those within it.

Those *outside* the joint are, the ligamentum patellæ, the internal lateral, the two external lateral, the posterior ligament, and the capsular ligament.

Those *within* the joint are, the two crucial, the two semilunar fibro-cartilages, the transverse, the coronary, the ligamenta alaria, and the ligamentum mucosum.

Ligamentum Patellæ. The *ligamentum patellæ* is a strong, thick, ligamentous band, about three inches (7.5 cm.) long, extending from the lower border of the patella to the tubercle of the tibia. Beneath it is found a considerable amount of fat, which separates the ligament from the joint, and in fat people forms a prominent elastic mass on each side of the ligament. There is a

synovial bursa between the ligamentum patellæ and the tuberosity of the tibia.*

Internal Lateral Ligament.

This is a broad, flat band, which extends from the inner condyle of the femur to the inner tuberosity and the inner aspect of the shaft of the tibia (Fig. 251). A few of the deeper fibres are attached to the inner semilunar cartilage, and serve to keep it in place. The inferior internal articular artery, and part of the tendon of the semimembranosus, pass underneath this ligament. In the several motions of the joint there is a certain amount of friction between the ligament and the head of the tibia, and consequently a small bursa is interposed.

External Lateral Ligaments.

The *long external lateral ligament* is a strong round band which extends from the outer condyle of the femur to the outer part of the head of the fibula. This ligament separates the two divisions of the tendinous insertion of the biceps. Beneath it pass the tendon of the popliteus and the inferior external articular artery.

The *short external lateral ligament* is situated posterior to, and runs parallel with the preceding ligament; it passes from the posterior and outer part of the condyle of the femur to the tip of the styloid process of the fibula; the tendon of the popliteus also lies beneath it.

Posterior Ligament.

This, which is generally called the *ligamentum posticum Winslowii*, covers the whole of the posterior surface of the knee-joint, and consists of two portions—one formed by a broad flat band of vertical fibres passing from the posterior surface of the femur between and above the condyles, to the posterior part of the tuberosity of the tibia; the other consists of an oblique tendinous expansion from the semimembranosus (p. 615), which passes upwards and outwards from the internal tuberosity of the tibia to the back of the outer

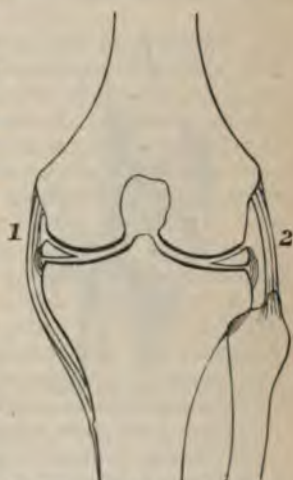


FIG. 251.—DIAGRAM OF THE SEMILUNAR CARTILAGES AND LATERAL LIGAMENTS OF THE KNEE.

1. Internal lateral ligament. 2. External lateral ligament.

* There are two oblique projections of ligamentous tissue from the sides of the patella extending to the head of the tibia. These are parts of the extensor tendon and act as accessories to the patellar ligament (Morris' Anat., Amer. Ed., p. 271). (A. H.)

condyle of the femur. It is pierced by numerous blood-vessels to supply the knee-joint, chiefly by the azygos artery and a branch from the obturator nerve (p. 587). This ligament not only closes and protects the joint behind, but prevents its extension beyond the perpendicular.

Capsular Ligament. The *capsular ligament* occupies the intervals between the other ligaments, and so completes the fibrous investment of the joint. It is materially strengthened

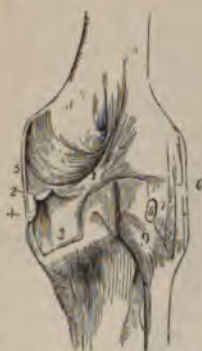

FIG. 252.—POSTERIOR VIEW OF THE LIGAMENTS OF THE KNEE-JOINT.

1. Oblique portion of the posterior ligament (Winslow's).
2. Tendon of the semimembranosus m. cut.
3. Process of this tendon which expands into fascia from which gives attachment to the popliteus muscle.
4. Process which passes under the internal lateral ligament.
5. Internal lateral ligament.
6. Long external lateral ligament.
7. Short external lateral ligament.
8. Tendon; the popliteus cut through.
9. Posterior tibio-fibular ligament.

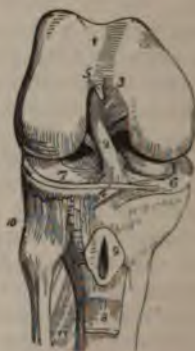

FIG. 253.—INTERNAL LIGAMENTS OF THE KNEE-JOINT (R.).

1. Condyles of the femur; five rest on the external, three rest on the internal condyle.
2. Anterior or external crucial ligament.
3. Posterior or internal crucial ligament.
4. Transverse ligament.
5. Attachment of the ligamentum mucosum; the remainder being removed.
6. Internal semilunar fibro-cartilage.
7. External semilunar fibro-cartilage.
8. Reflected ligamentum patellae.
9. Sub-patellae bursa opened.
10. Anterior superior tibio-fibular ligament.
11. Interosseous membrane.

by fibrous expansions from many of the tendons in connection with the articulation.

The joint should be opened above the patella. Observe the great extent of the fold which the synovial membrane forms above this bone.* It allows the free play of the bone over the lower part of the femur. The fold extends higher above the inner than the outer

* In performing operations near the knee, the joint should always be bent, in order to draw the synovial fold as much as possible out of the way.

condyle, which accounts for the form of swelling produced by effusion into the joint.

Crucial Ligaments. The *crucial ligaments*, so named because they cross like the letter X, extend from the mesial side of each condyle to the head of the tibia.

The *anterior or external ligament* (Fig. 253, 2), the smaller, ascends from the inner part of the fossa in front of the spine of the tibia, backwards and outwards to the inner and back part of the external condyle. It is attached to the tibia close to the anterior termination of the external semilunar cartilage.

The *posterior or internal ligament* (3), best seen from behind, extends from the back of the fossa behind the spine of the tibia, and from the posterior termination of the external semilunar cartilage, upwards, forwards, and inwards to the front of the inner condyle. The direction of this ligament is more vertical than the anterior one.

Interarticular or Semilunar Fibro-cartilages. Between the condyles and the articular surfaces of the tibia are two incomplete rings of fibro-cartilage (Fig. 253, 6, 7), shaped like the letter C. They serve to deepen the articular surfaces of the tibia; their mobility and flexibility enable them to adapt themselves to the condyles in the several movements of the joint; they distribute pressure over a greater surface and break shocks. They are thickest at the circumference, and gradually shelve off to a thin margin; thus they fit in between the bones, and adapt a convex surface to a flat one, as shown in Fig. 251. Their form is suited to the condyles, the inner being oval, the outer circular, and the synovial membrane covers both surfaces of the cartilages.

The *external semilunar fibro-cartilage* is nearly a circular ring of fibro-cartilage, its two extremities being firmly attached to the fossæ, one in front of and the other behind the spine of the tibia; they are enclosed by the two extremities of the internal cartilage.

On its outer border it presents a groove for the tendon of the popliteus; its anterior border gives off a transverse fibrous fasciculus, the transverse ligament (Fig. 253, 4), which passes across to be connected with the anterior border of the internal cartilage. The anterior extremity of the fibro-cartilage is connected with the anterior crucial ligament; the posterior is attached partly into the outer side of the inner tuberosity in front and behind the posterior crucial ligament, and partly into the anterior crucial ligament.*

* Of the two cartilages the external has the greater freedom of motion, because in rotation of the knee the outer side of the tibia moves more than the inner. Consequently, it is not in any way connected to the external lateral ligament; so far from this, it is separated from it by the tendon of the popliteus, of which the play is facilitated by a bursa communicating freely with the joint. For this reason the external cartilage is more liable to dislocation than the internal.

The *internal semilunar fibro-cartilage* (6) forms about two-thirds of an oval ring, and is narrower in front than behind. Its anterior extremity is pointed, and is attached to the tibia internal to the anterior crucial ligament; its posterior extremity to the pit behind the spine immediately in front of the posterior crucial ligament.

The *transverse ligament* (4), already alluded to, is a thin fibrous fasciculus in front of the anterior crucial ligament, and connects the anterior borders of the semilunar fibro-cartilages.

The *coronary ligaments* are two ligaments which connect the circumference of the two semilunar cartilages to the borders of the tibial tuberosities. The external ligament is the weaker of the two, so that the external cartilage is the more moveable.

Synovial Membrane.

The synovial membrane is very extensive, the most extensive in the body. It lines the posterior surface of the quadriceps tendon, and the aponeuroses of the vasti, and is reflected on to the femur a variable distance above the incrusting cartilage; traced from the femur, we find that it lines the inner surface of the capsular ligament as far as the circumference of the tibia; thence it is reflected over the upper surfaces of the semilunar cartilages, round their inner concave margins to get to their under surfaces, from which the membrane passes to cover the articular surface of the head of the tibia. It forms tubular prolongations round the crucial ligaments, and below the patella a slender band of the synovial membrane proceeds backwards to the space between the condyles, and is called the *ligamentum mucosum*. Two lateral folds, extending from the sides of the mucous ligament, pass upwards and outwards to the sides of the patella; these are termed the *ligamenta alaria*. These are not true ligaments, but merely remnants of the partition which, in the early stage of the joint's growth, divided it into two equal portions.

Outside the synovial membrane there is always fat, especially under the ligamentum patellæ. Its use is to fill up vacuities, and to mould itself to the several movements of the joint.

The movements which the knee-joint permits are those of flexion and extension, together with rotation outwards and inwards. In order completely to master its various movements, the student should examine the movements first as between the femur and the patella, and then as between the condyles of the femur and the articular surface of the tibia crowned by its two semilunar cartilages.

The articular surface of the patella glides upon the femoral condyles in extension and in flexion. If this surface of the patella be examined, it will be seen that each lateral facet is subdivided by two indistinct transverse ridges into three very shallow transverse

zones; each of these zones rests upon a definite part of the trochlear surface of the femur in the different stages of extension or flexion; thus, in extreme extension, the lower zones of the patella rest upon the upper border of the trochlear surface; in mid-flexion, the middle zones alone rest on the femur; and in nearly extreme flexion, the upper zones lie on the lower part of the femoral condyles. In addition to the six shallow facets just described, there is a seventh, which is seen on the inner margin.

The respective points of the attachment of the ligaments are such that, when the joint is extended, all the ligaments are tight, to prevent extension beyond the perpendicular; thus muscular force is economized. But when the joint is bent the ligaments are relaxed enough to admit a slight rotatory movement of the tibia.

This movement is more free outwards than inwards, and is effected, not by rotation of the tibia on its own axis, but by rotation of the outer head round the inner. Rotation outwards is produced by the biceps; rotation inwards by the popliteus and semimembranosus.

The crucial ligaments, though placed inside the joint, answer the same purposes as the coronoid process and the olecranon of the elbow. They make the tibia *slide* properly forwards and backwards. In extension, the anterior crucial ligament is tight, as are also the lateral ligaments; in flexion, the posterior ligament becomes tight, and consequently limits flexion. They also conjointly limit excessive rotation. They not only prevent dislocation in front or behind, but they prevent lateral displacement, since they cross each other like braces, as shown in Fig. 254.

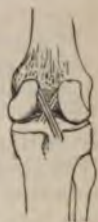

FIG. 254.—CRUCIAL LIGAMENTS OF THE KNEE.

Superior Tibio-fibular Articulation.

This is an arthrodial or gliding joint, and is formed by the flat oval surfaces of the upper part of the tibia and fibula. It is secured by an anterior and a posterior tibio-fibular ligament.

The *anterior superior tibio-fibular ligament* is a strong flat ligament whose fibres pass obliquely downwards and outwards from the external tuberosity of the tibia to the head of the fibula.

The *posterior superior ligament* passes in the same direction as the anterior, only being placed behind the joint.*

The *synovial membrane* occasionally communicates with that of the knee-joint.

*A capsular ligament is described by many authors attached close to the articular margins of the tibia and fibula, extending a little behind and below the margin of the latter. (A. H.)

Interosseous Membrane.

The contiguous borders of the tibia and fibula are connected by the interosseous membrane. The purpose of it is to afford additional surface for the attachment of muscles. Its fibres pass chiefly downwards and outwards from the tibia to the fibula, but a few fibres cross like the letter X. The anterior tibial artery comes forwards above the interosseous membrane through an oval space about an inch (2.5 cm.) below the head of the fibula. Lower down there is an aperture for the anterior peroneal artery. It is, moreover, pierced here and there by small blood-vessels.

Inferior Tibio-fibular Articulation.

The lower extremities of the tibia and fibula are firmly connected, for it is essential to the security of the ankle-joint that there should be little or no movement between the two bones.

The *anterior inferior ligament* passes between the adjacent borders of the two bones; it is narrow above but broader below, and consists of oblique fibres which pass downwards and outwards.

The *posterior inferior ligament* is stronger and narrower than the anterior, and its fibres pass horizontally from the outer malleolus to the posterior border of the tibia, above the articular surface.

The *transverse ligament* is the lower part of the preceding, and may be usually recognized as a distinct narrow fasciculus.

The *inferior interosseous ligament* consists of strong short fibres connecting the contiguous surfaces of the two bones, and continuous above with the interosseous membrane.

The *synovial membrane* of this joint is an extension upwards of that of the ankle-joint.*

Ankle-joint.

From the form of the bones, it is obvious that the angle is a ginglymus or hinge-joint; consequently, its security depends upon the great strength of its lateral ligaments. The hinge, however, is not so perfect but that it admits of a slight rotatory motion, of which the centre is on the fibular side, and therefore the reverse of that in the case of the knee.

The ligaments of the ankle-joint comprise the anterior, the posterior, the internal, and the external lateral ligaments.

The *anterior ligament* is a thin loose membranous ligament, attached above to the tibia, and below to the astragalus in front of their articular surfaces, and is sufficiently loose to permit the necessary range of motion.

The *posterior ligament* is a thin disconnected membranous ligament, attached above to the posterior inferior tibio-fibular ligament, to the external malleolus internal to the peroneal groove; and below to the posterior surface of the astragalus from the internal to the external ligaments of the ankle-joint.

* The movement is one of gliding very limited upwards and downwards. (A. H.)

The *internal lateral ligament*, sometimes called, from its shape, *deltoid*, is exceedingly thick and strong, and compensates for the

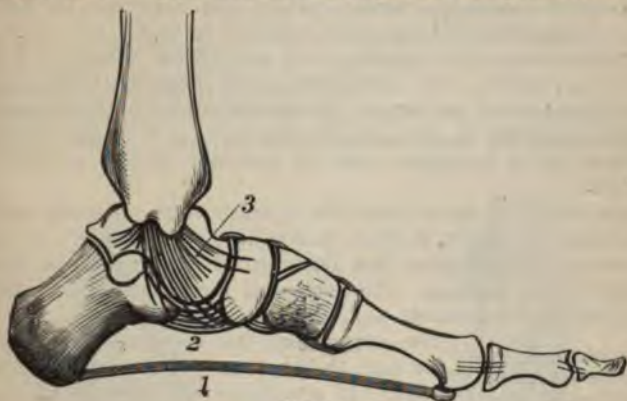


FIG. 255.

1. Plantar fascia. 2. Calcaneo-scapoid ligament which supports the head of the astragalus.
3. Internal lateral ligament, called from its shape deltoid.

comparative shortness of the internal malleolus (Fig. 255). The great strength of it is proved by the fact that, in dislocation of the ankle inwards, the summit of the malleolus is more often broken off than the ligament is torn. The *superficial portion* of this ligament is attached above to the margin of the internal malleolus, and passing downwards radiates to be inserted into the scaphoid, the inner side of the astragalus, the sustentaculum tali, and the inferior calcaneo-scapoid ligament; the *deeper portion*, thick and strong, passes from the tip of the malleolus to the astragalus, close to its articular border.

The *external lateral ligament* consists of three distinct fasciculi—an anterior, a posterior, and a middle (Fig. 256). The *anterior fasciculus* passes from the front of the tip of the external malleolus, nearly horizontally forwards and inwards to the astragalus in front of its malleolar articular surface. The *middle fasciculus*, round and long, passes

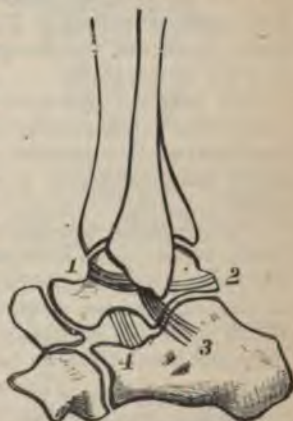

FIG. 256.—DIAGRAM OF THE EXTERNAL LATERAL LIGAMENT.

1. Anterior part. 2. Posterior part.
3. Middle part. 4. Interosseous ligament between the astragalus and os calcis.

obliquely downwards and backwards to the outer surface of the os calcis. The *posterior fasciculus* passes from the posterior part of the external malleolus, nearly horizontally outwards, to the back of the astragalus below its upper articular surface.

Besides flexion and extension, the ankle-joint admits of a slight lateral movement, only permitted in the extended state, for the better direction of our steps. In adaptation to this movement the internal malleolus is shorter than the outer; it is not so tightly confined by its ligaments, and its articular surface is part of a cylinder.

Open the joint to see that the breadth of the articular surfaces of the bones is greater in front than behind. The object of this is to render the astragalus less liable to be dislocated backwards. Whenever this happens, the astragalus must of necessity become firmly locked between the malleoli.

Ligaments connecting the Bones of the Tarsus. The astragalus is the keystone of the arch of the foot, and supports the whole weight of the body. It articulates with the os calcis and the os scaphoides in such a manner as to permit the abduction and adduction of the foot, so useful in the direction of our steps.

Astragalo-calcanean Ligaments. The astragalus articulates with the os calcis by two surfaces separated by the deep interosseous groove, of which the posterior is concave, and the anterior convex. The articulations are strengthened by the three ligaments, the external and the posterior astragalo-calcanean, and the interosseous.

The *external astragalo-calcanean ligament* is a short, quadrilateral fasciculus, passing from the outer surface of the astragalus, in front of the anterior fasciculus of the external lateral ligament, almost directly downwards to the outer surface of the os calcis.

The *posterior astragalo-calcanean ligament* is a short oblique band, which passes from the posterior border of the astragalus to the upper border of the os calcis.

The *interosseous ligament*, a very thick strong band of fibres which descends vertically into the interosseous canal, and is the principal band of union between the two bones.

Astragalo-scaphoid Ligament. The anterior surface of the astragalus is broadly convex, fitting into the concave surface of the scaphoid bone. Superiorly the dorsal surfaces of the two bones are connected by a broad membranous ligament, *astragalo-scaphoid*, which passes obliquely across, blending externally with the external calcaneo-scaphoid, and below with the inferior calcaneo-scaphoid ligament.

**Calcaneo-scaphoid
Ligaments.**

In the skeleton the head of the astragalus articulates in front with the scaphoid, but the lower part of it is unsupported. This interval is bridged over by a very strong and slightly elastic ligament, which extends from the os calcis to the scaphoid (Fig. 257); this is the inferior calcaneo-scaphoid ligament.

The *inferior calcaneo-scaphoid ligament* is thick and strong, and passes horizontally forwards and inwards from the sustentaculum

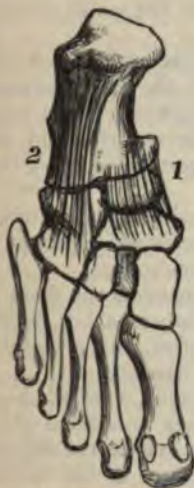

FIG. 257.—1. Calcaneo-scaphoid ligament. 2. Calcaneo-cuboid ligament.

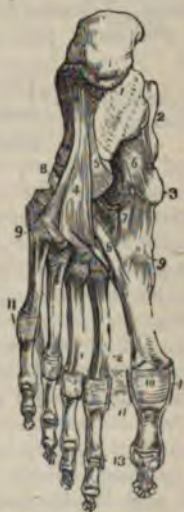

FIG. 258.—LIGAMENTS OF THE SOLE OF THE FOOT.

1. Os calcis. 2. Astragalus. 3. Tuberosity of the scaphoid. 4. Long calcaneo-cuboid lig. 5. Part of the short calcaneo-cuboid lig. 6. Calcaneo-scaphoid lig. 7. Plantar tarsal ligament. 8, 8. Tendon of the peroneus longus m. 9, 9. Plantar tarso-metatarsal lig. 10. Metatarso-phalangeal lig. 11, 11, 11. Lateral metatarso-phalangeal. 12. Transverse. 13. Lateral of the phalanges of the great-toe.

tali to the plantar surface of the scaphoid, where it is connected with the tendon of the tibialis posticus, and, superiorly, with the astragalo-scaphoid ligament. Thus the os calcis, scaphoid, and this ligament form a complete socket for the head of the astragalus; it is this joint, chiefly, which permits the abduction and adduction of the foot. In chronic disease of the ankle-joint, leading to much impairment of movement at this joint, the motion at the

astragalo-scaploid articulation is so great as to take the place of the ankle-joint. This ligament being slightly elastic, allows the keystone of the arch (the astragalus) a play, which is of great service in preventing concussion of the body. Whenever this ligament yields, the head of the astragalus falls, and the individual becomes gradually flat-footed. In this yielding of the ligament the head of the astragalus not only falls, but becomes also rotated inwards.

The *superior calcaneo-scaploid ligament* is short and triangular, lying in the hollow between the outer part of the astragalus and the os calcis; it passes forwards and upwards from the ridge on the anterior and outer part of the os calcis to the outer side of the scaphoid.

**Calcaneo-cuboid
Articulation.**

The os calcis articulates with the os cuboides nearly on a line with the joint between the astragalus and the scaphoid. The bones are connected together, on the dorsum, by the superior and internal calcaneo-cuboid ligaments, and on the plantar aspect by the long and short calcaneo-cuboid ligaments.

The *superior calcaneo-cuboid ligament* is a short quadrilateral band of fibres passing from the upper part of the dorsal aspect of the os calcis to the back and upper part of the os cuboides.

The *internal calcaneo-cuboid ligament* connects the front part of the ridge of the os calcis to the dorsal and inner part of the cuboid. It is sometimes called the *interosseous ligament*, and is closely associated with the superior calcaneo-scaploid ligament.

The *long calcaneo-cuboid ligament* (Fig. 258), a broad, long, and strong band of ligamentous fibres, is the more superficial of the two inferior calcaneo-cuboid ligaments. It is known as the *long plantar ligament*, and is attached to the under surface of the os calcis in front of the tuberosities, as far as the anterior tubercle; it passes forwards to the plantar aspect of the cuboid, being attached to the ridge, while some of its fibres extend to the bases of the second, third, and fourth metatarsal bones, and complete the canal for the tendon of the peroneus longus.

The *short calcaneo-cuboid ligament*, deeper than the former, is seen somewhat on its inner aspect, and is separated from it by some fat and connective tissue. It is very broad, and passes from the front of the tubercle of the os calcis, for about an inch in breadth, to the inner and posterior surface of the cuboid, behind the ridge.

The articulations between the cuboid and the scaphoid bones behind, and the three cuneiform bones in front, are maintained by dorsal, plantar, and interosseous ligaments.

The *dorsal* and the *plantar ligaments* consist of parallel fasciculi passing between the contiguous borders of the respective bones on their dorsal and plantar aspects.

The *interosseous ligaments*, three in number, are composed of transverse fibres (Fig. 259) connecting the rough non-articular surfaces of the contiguous bones; the first one is between the scaphoid and the cuboid; the second connects the internal and middle cuneiform bones; the third is between the middle and external cuneiform bones; and the fourth between the external cuneiform and the cuboid bones.

Though there is very little motion between any two bones, the collective amount is such that the foot is enabled to adapt itself accurately to the ground; pressure is more equally distributed, and consequently there is a firmer basis for the support of the body. Being composed, moreover, of several pieces, each of which possesses a certain elasticity, the foot gains a general springiness and strength which could not have resulted from a single bone.

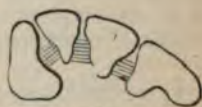

FIG. 259.—INTEROSSEOUS LIGAMENTS OF THE WEDGE-BONES.

Tarso-metatarsal Joints.

The tarsus articulates with the metatarsus in an oblique line which inclines backwards on its outer side. This line is interrupted at the joint of the middle cuneiform bone and the second metatarsal bone. Here there is a deep recess, so that the base of this metatarsal bone is wedged in between the internal and external cuneiform bones.

These joints are maintained in position, above, by the dorsal tarso-metatarsal ligaments, and, below, by the plantar ligaments. Interosseous ligaments also pass between the wedge-bones, maintaining them in their normal positions.

Synovial Membranes of the Tarsus.

Exclusive of the ankle-joint and the phalanges of the toes, the bones of the foot are provided with six distinct synovial membranes, namely—

1. Between the posterior articular surface of the os calcis and that of the astragalus.
2. Between the head of the astragalus and the scaphoid, and between the anterior articular surface of the astragalus and os calcis.
3. Between the os calcis and the os cuboides.
4. Between the inner cuneiform bone and the metatarsal bone of the great toe.
5. Between the scaphoid and the three cuneiform bones, and between these and the adjoining bones (the great toe excepted).
6. Between the os cuboides and the fourth and fifth metatarsal bones.

The tarso-metatarsal articulations are arthrodial joints.

Inter-metatarsal Articulations.

The metatarsal bones are connected at their proximal and distal ends by *dorsal* and *plantar ligaments*; those at the proximal extremities

are very strong, and are supplemented by interosseous ligaments, as in the metacarpus (p. 392). The movement between the proximal ends of the inter-metatarsal articulations is arthrodial or gliding.

The distal extremities of the metatarsal bones are united by a *transverse metatarsal ligament*; this extends from the great toe to the little toe on their plantar surfaces.

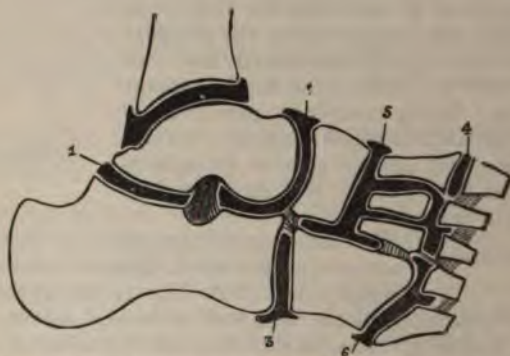


FIG. 260.—DIAGRAM OF THE ARTICULATIONS OF THE TARSUS AND THE TARSO-METATAEUS.
 1. Posterior calcaneo-astragaloid synovial cavity. 2. Calcaneo-scaphoid synovial cavity. 3. Calcaneo-cuboid synovial cavity. 4. Synovial cavity between metatarsal bone of great toe and internal cuneiform bone. 5. Common scapho-cuneiform, intercuneiform, and metatarsocuneiform synovial cavity. 6. Cubo-metatarsal synovial cavity.

Metatarso-phalangeal Articulations.

These are connected by a *plantar* and *two lateral ligaments*; the dorsal ligament being formed by the expansion of the tendon of the extensor longus digitorum. The movements which take place between the articulations are those of flexion, extension, abduction, and adduction.

Phalangeal Articulations.

These articulations have the same kind of ligaments as the preceding, and the movements are also nearly identical.

DISSECTION OF THE BRAIN.

Before passing on to the examination of the brain, the student should study the arrangement, the structure, and the uses of the three membranes by which the brain is enveloped.

The most external one, the *dura mater*, has been described (p. 31). The second, or intermediate one, is a serous membrane, termed the *arachnoid*; the third, the *pia mater*, is a vascular layer, and is in contact with the encephalon.

Arachnoid Membrane.

The *arachnoid membrane*, the second investment, constitutes the smooth polished membrane covering the surface of the brain, and is exposed after the removal of the *dura mater*. * This tunic was formerly considered by anatomists to be an example of an ordinary serous membrane, and was described as consisting of two layers—an external or parietal, which lined the inner surface of the *dura mater*, and an internal or visceral, which was reflected over the brain.

It is now regarded as consisting of one layer only, viz., the one which envelops the brain; the under aspect of the *dura mater* being covered only with a layer of flattened epithelium cells. The cavity which was formerly described as the cavity of the *arachnoid*, is now called the *subdural space*, and contains a very limited amount of fluid.

The *arachnoid membrane* is a colourless and transparent layer, and is spread uniformly over the surface of the brain, from which it is separated by the *pia mater*. It does not, like the *pia mater*, dip down into the furrows between the convolutions of the brain, and it is more or less connected with the *pia mater* by delicate connective tissue, the *subarachnoid*. On account of its extreme tenuity, and its close adhesion to the *pia mater*, the two membranes cannot be readily separated; but there are places, especially at the base of the brain, termed *subarachnoid spaces*, where the *arachnoid membrane* can be seen distinct from the subjacent *pia mater*. The two membranes can be artificially separated by blowing air beneath the *arachnoid* with a blow-pipe.

Subarachnoid Spaces and Fluid.

Wherever the *arachnoid membrane* is separated from the *pia mater*, a serous fluid (*cerebrospinal*) intervenes, contained in the meshes of

a very delicate areolar tissue. The spaces between these membranes are termed *subarachnoid*, and are very manifest in some places. For instance, there is one well-marked space in the longitudinal fissure, where the arachnoid does not descend to the bottom, but passes across the edge of the falx cerebri, a little above the corpus callosum. At the base of the brain there are two of considerable size: one, the *anterior subarachnoid space*, is situated between the anterior border of the pons Varolii, the middle, and the anterior cerebral lobes; the other, the *posterior subarachnoid space*, is placed between the cerebellar hemispheres and the medulla oblongata. The fluid in the subarachnoid space communicates with the fluid of the general ventricular cavities of the brain through an aperture (*foramen of Magendie*) in the fourth ventricle, close to its lower boundary; and also through an opening, on each side, behind the glosso-pharyngeal nerves. In the spinal cord, also, there is a considerable interval containing fluid between the arachnoid and the pia mater. The purpose of this fluid is, not only to fill up space, as fat does in other parts, but mechanically to protect the nerve-centres from the violent shocks and vibrations to which they would otherwise be liable.

The brain, therefore, may be said to be supported in a fluid, which insinuates itself into all the inequalities of the surface, and surrounds in fluid sheaths all the nerves as far as the foramina through which they pass. This fluid sometimes escapes through the ear, in cases of fracture through the base of the skull involving the meatus auditorius internus and the petrous portion of the temporal bone.

The arachnoid is supplied with filaments from the motor root of the fifth, the facial, and the spinal accessory nerves.

The *cerebro-spinal fluid* varies in amount from two drachms to two ounces (*7.3 c.cm. to 59. c.cm.*). It is a clear, limpid fluid, slightly alkaline, containing 98.5 parts of water, and 1.5 parts of solid matter. The cerebro-spinal fluid of the encephalon and that of the spinal cord communicate.

Pia Mater.

This, the immediate investing membrane of the brain, is extremely vascular, and composed of a minute network of blood-vessels held together by delicate connective tissue. It covers the cerebral surface, and dips into the fissures between the convolutions, forming a double layer. From its internal surface numerous vessels pass off at right angles into the substance of the brain.* The pia mater sends a prolongation through the transverse fissure into the lateral and third ventricles,

* Owing to these vessels, the pia mater, when placed in water, presents a flocculent, woolly appearance, and hence it is sometimes called *tomentum cerebri*.

forming the *velum interpositum* and the *choroid plexuses*, and also another along the roof of the fourth ventricle, forming the *tela choroidea inferior*. Upon the surface of the cerebellum the pia mater is thinner, not so vascular, and only sends prolongations down the larger sulci; on the pons Varolii and the medulla the membrane is more fibrous and much less vascular than elsewhere.

The pia mater is supplied with nerves by the third, fifth, sixth, facial, glosso-pharyngeal, pneumogastric, spinal-accessory, and sympathetic nerves, which chiefly accompany the blood-vessels forming the pia mater.

Arteries of the Brain.

The brain is supplied with blood by the two internal carotid and the two vertebral arteries.

Internal Carotid.

This artery enters the skull through the carotid canal in the temporal bone, and ascends very tortuously, by the side of the body of the

sphenoid, along the inner wall of the cavernous sinus. It appears on the inner side of the anterior clinoid process, and after giving off the ophthalmic, divides into an interior and middle cerebral, posterior communicating and anterior choroid arteries.

a. The *anterior cerebral artery* is given off from the internal carotid at the inner end of the fissure of Sylvius. It passes forwards and inwards to reach the longitudinal fissure between the hemispheres, curves round the front part of the corpus callosum, then runs backwards over its upper surface (under the name of the *artery of the corpus callosum*), and terminates in branches which anastomose with the posterior cerebral arteries. The anterior cerebral arteries of opposite sides run side by side, and supply the olfactory lobes, the optic nerves, the frontal lobes, the anterior perforated spaces, and the corpus callosum. At the base of the brain, as they enter the longitudinal fissure, they are connected by a short transverse branch, called the *anterior communicating artery* (Fig. 261).

b. The *middle cerebral artery*, the largest branch of the internal carotid, runs outwards deeply within the fissure of Sylvius, and divides into many branches distributed to the anterior and middle lobes. Near its origin it gives off a number of small arteries, which pierce the locus perforatus anticus to supply the corpus striatum.

c. The *posterior communicating artery*, unequal in size usually on the two sides, proceeds directly backwards to join the posterior cerebral; thus establishing at the base of the brain the free arterial inosculation called the CIRCLE OF WILLIS.

d. The *anterior choroid artery*, a small branch of the internal carotid, arises external to the posterior communicating artery. It runs backwards, and enters the fissure at the bottom of the middle horn of the lateral ventricle, to terminate in the choroid plexus of that cavity. It supplies, in addition, the hippocampus major and the corpus fimbriatum.

Vertebral Artery.

This artery, a branch of the subclavian in the first part of its course, enters the foramen in

the transverse process of the sixth cervical vertebra, and ascends through the transverse processes of the cervical vertebræ. It then winds backwards along the arch of the atlas, and enters the skull through the foramen by perforating the posterior occipito-atlantal

Olfactory bulb.

Second pair or optic
nerves.

Locus perforatus
anticus.

Tractus opticus.

Crus cerebri.

Third pair of nerves.

Fourth pair of
nerves.

Fifth pair of nerves.

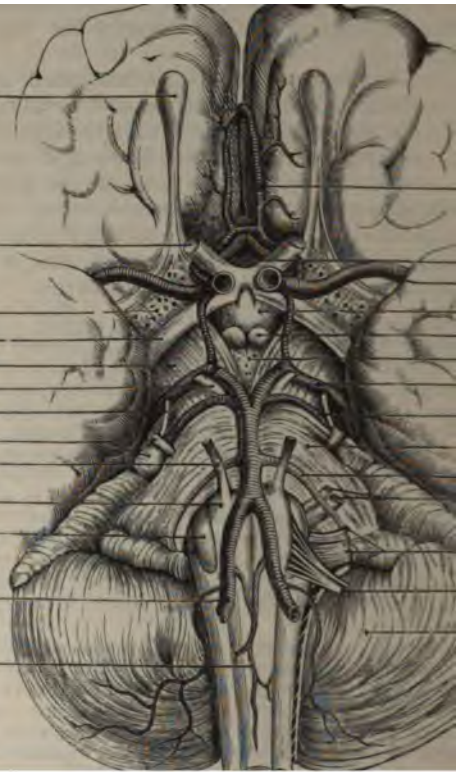Sixth pair of nerves.

Pyramid.

Olive.

Vertebral artery.

Anterior spinal a.



c. A *posterior meningeal branch*, distributed to the posterior fossa of the skull.
d. *Anterior posterior spinal arteries*, which are given off immediately before the vertebral arteries join to form the basilar, run along the median fissures of the front and the back surfaces of the spinal cord, and anastomose with the spinal branches of the ascending cervical arteries.

e. The *posterior inferior cerebellar artery*, sometimes a branch of the basilar, but more frequently of the vertebral, passes backwards between the spinal-accessory and the pneumogastric nerves, to the under surface of the cerebellum. It divides into two branches: an outer, which ramifies on the lower surface of the cerebellum as far as its outer border; and an inner, which passes to the vallicula between the two hemispheres, and supplies branches to the fourth ventricle.

The *basilar artery*, formed by the junction of the two vertebral, in its course along the pons, gives off on each side:—

a. *Transverse branches* which pass outwards on the pons: one, the *internal auditory*, enters the meatus auditorius internus with the auditory nerve, to be distributed to the internal ear on each side.

b. The *anterior inferior cerebellar*, which supplies the front part of the lower surface of the cerebellum, and anastomoses with the other cerebellar arteries.

c. The *superior cerebellar arteries*, given off near the bifurcation of the basilar, are distributed to the upper surface of the cerebellum, and anastomose with the inferior cerebellar; branches are supplied to the pineal body, the valve of Vieussens, and the velum interpositum.

d. The *posterior cerebral arteries* are the two terminal branches into which the basilar artery divides. They run outwards and backwards, in front of the third cranial nerve, and wind round the crura cerebri to the under surface of the posterior cerebral lobes, where they divide into numerous branches for the supply of the brain, anastomosing with the anterior and middle cerebral arteries. Shortly after their origins they receive the two posterior communicating arteries from the internal carotids. Each gives off small branches to the posterior perforated space, and also the small *posterior choroid artery*, which, passing beneath the posterior border of the corpus callosum and fornix, is distributed to the velum interpositum and choroid plexus.

Circle of Willis. This important arterial inosculation (Fig. 261) takes place between the branches of the two internal carotid and the two vertebral arteries. It is formed, laterally, by the two anterior cerebral, the two internal carotid, and the two posterior communicating arteries; in front, it is completed by the anterior communicating artery; behind, by the two posterior cerebral. The tortuosity of the large arteries before they enter the brain serves to mitigate the force of the heart's action; and the circle of Willis provides a free supply of blood from other vessels, in case any accidental circumstance should stop the flow of blood through any of the more direct channels.*

* In many of the long-necked herbivorous quadrupeds a provision has been made in the disposition of the internal carotid arteries, for the purpose of equalising the force of the blood supplied to the brain. The arteries, as they enter the skull, divide into several branches, which again unite and form a remarkable network of arteries, called by Galen, who first described it, the '*rete mirabile*.' The object

Peculiarities of the Cerebral Circulation.

Besides the circle of Willis, there are other peculiarities relating to the circulation of the blood in the brain: namely, the length and tortuosity of the four great arteries as they enter the skull; their passage through tortuous bony canals; the spreading of their ramifications in a very delicate membrane, the pia mater, before they enter the substance of the brain; the minuteness of the capillaries, and the extreme thinness of their walls; the formation of the venous sinuses (p. 34), which do not accompany the arteries; the chordæ Willisii in the superior longitudinal sinus; the absence of valves in the sinuses; and the confluence of no less than six sinuses, forming the *torcular Herophili*, at the internal occipital protuberance.

General Division of the Brain.

The mass of nervous substance contained within the cranial cavity, comprised under the common term brain (*encephalon*), is divided into four parts. The *cerebrum* forms the largest portion, and occupies the whole of the upper part of the cranial cavity; its base resting on the anterior and middle fossæ and the tentorium cerebelli. It is connected with the pons Varolii by two white nerve-masses, the *crura cerebri*, and with the cerebellum by two white cords, the *crura cerebelli*. The *cerebellum*, or smaller brain, occupies the space between the tentorium cerebelli and the inferior occipital fossæ. The *pons Varolii* is the quadrilateral mass of white fibres which rests upon the basilar process of the occipital bone. The *medulla oblongata* is the portion below the pons, which is continuous below with the spinal cord and rests upon the lower part of the basilar process of the occipital bone.

The result of a large number of observations shows that the weight of the brain averages in males $49\frac{1}{2}$ oz. (*1374.8 grm.*), and in females about 44 oz. (*1245.2 grm.*); although it has been known to weigh as much as 64 oz. (*1711.2 grm.*), as in the case of Cuvier's brain, and as little as 23 oz. (*655.5 grm.*), in the case of an idiot's brain.

The average specific gravity of the brain is about 1036; that of the white matter being 1040, and that of the grey 1034.

The relative proportion of the amount of white to grey matter is, 64 per cent. of white substance to 36 per cent. of grey matter.

The weight of the encephalon varies greatly in different subjects, and although its weight seems to bear some proportionate relation

of this evidently is to moderate the rapidity with which the blood would otherwise enter the cranium in the different positions of the head, and thus preserve the brain from those sudden influxions to which it would under other circumstances be continually exposed.

c. A *posterior meningeal branch*, distributed to the posterior fossa of the skull.
d. *Anterior posterior spinal arteries*, which are given off immediately before the vertebral arteries join to form the basilar, run along the median fissures of the front and the back surfaces of the spinal cord, and anastomose with the spinal branches of the ascending cervical arteries.

e. The *posterior inferior cerebellar artery*, sometimes a branch of the basilar, but more frequently of the vertebral, passes backwards between the spinal-accessory and the pneumogastric nerves, to the under surface of the cerebellum. It divides into two branches: an outer, which ramifies on the lower surface of the cerebellum as far as its outer border; and an inner, which passes to the vallicula between the two hemispheres, and supplies branches to the fourth ventricle.

The *basilar artery*, formed by the junction of the two vertebral, in its course along the pons, gives off on each side:—

a. *Transverse branches* which pass outwards on the pons: one, the *internal auditory*, enters the meatus auditorius internus with the auditory nerve, to be distributed to the internal ear on each side.

b. The *anterior inferior cerebellar*, which supplies the front part of the lower surface of the cerebellum, and anastomoses with the other cerebellar arteries.

c. The *superior cerebellar arteries*, given off near the bifurcation of the basilar, are distributed to the upper surface of the cerebellum, and anastomose with the inferior cerebellar; branches are supplied to the pineal body, the valve of Vieussens, and the velum interpositum.

d. The *posterior cerebral arteries* are the two terminal branches into which the basilar artery divides. They run outwards and backwards, in front of the third cranial nerve, and wind round the crura cerebri to the under surface of the posterior cerebral lobes, where they divide into numerous branches for the supply of the brain, anastomosing with the anterior and middle cerebral arteries. Shortly after their origins they receive the two posterior communicating arteries from the internal carotids. Each gives off small branches to the posterior perforated space, and also the small *posterior choroid artery*, which, passing beneath the posterior border of the corpus callosum and fornix, is distributed to the velum interpositum and choroid plexus.

Circle of Willis. This important arterial inosculation (Fig. 261) takes place between the branches of the two internal carotid and the two vertebral arteries. It is formed, laterally, by the two anterior cerebral, the two internal carotid, and the two posterior communicating arteries; in front, it is completed by the anterior communicating artery; behind, by the two posterior cerebral. The tortuosity of the large arteries before they enter the brain serves to mitigate the force of the heart's action; and the circle of Willis provides a free supply of blood from other vessels, in case any accidental circumstance should stop the flow of blood through any of the more direct channels.*

* In many of the long-necked herbivorous quadrupeds a provision has been made in the disposition of the internal carotid arteries, for the purpose of equalising the force of the blood supplied to the brain. The arteries, as they enter the skull, divide into several branches, which again unite and form a remarkable network of arteries, called by Galen, who first described it, the '*rete mirabile*.' The object

and is occupied by a process of pia mater. The posterior runs along the floor of the fourth ventricle as a shallow median groove.

The surface of the medulla is marked out on each side into four longitudinal columns, which receive the following names, from before backwards: the *anterior pyramids*, the *lateral tracts* and the *olivary bodies*, the *restiform bodies*, and the *posterior pyramids*.

The *anterior pyramids* are two columns of white matter, narrow below, but increasing gradually in breadth as they ascend towards the pons. At this part they become constricted, and may be traced through the pons into the *crura cerebri*. The fibres of which they are in the main composed are derived from the anterior columns of the spinal cord, and consist therefore of motor fibres. On separating the pyramids about an inch (2.5 cm.) below the pons, bundles of nerves are seen decussating across the anterior fissure (Fig. 262). This decussation, which consists of three or four bundles on each side, involves only the inner fibres of the pyramid; the outer fibres ascend through the pons without crossing. The decussating fibres are the continuations upwards of the deep fibres of the lateral pyramidal tract and the lateral columns of the cord, which here come forwards to the surface, and push aside the anterior pyramids. Thus it will be seen that the thickness of the anterior pyramids is mainly due to these decussating bundles; that the fibres on the outer side of the pyramids are those continued upwards from the anterior column of the cord; that the inner part is made up of the fibres of the lateral tract of the opposite side.

This decussation explains the phenomenon of *cross paralysis, i. e.*, when one side of the brain is injured, the loss of motion is manifested on the opposite side of the body.*

The *olivary bodies* are the two oval eminences, about $\frac{2}{3}$ of an inch (1 cm.) long, situated on the outer side of the upper part of the anterior pyramids, from which they are separated by a shallow depression. They do not ascend quite as high as the pons, for there is a deep groove between them. They consist externally of white matter; and at their lower part some white fibres may be observed arching round from the anterior median fissure, constituting the *arciform fibres* of Rolando. In the groove between the anterior pyramids and these bodies are seen the fasciculi of the hypoglossal nerve emerging from the medulla, and in the groove behind the olive emerge the roots of the glossopharyngeal, the pneumogastric, and spinal-accessory nerves.

The *lateral tracts*, situated on the outer side of the anterior

* The phenomenon of *cross paralysis of sensation* is explained by the fact, made out by Brown-Séquard, that the paths of sensory impressions cross each other in the grey matter of the cord.

pyramids, are the continuations upwards of the lateral columns of the spinal cord. As described, the greater number of their fibres pass across the anterior median fissure to the opposite anterior pyramid; but some ascend as far as the lower border of the olivary body, where they divide, a few passing in front of, but the larger part passing behind this body in their course to the brain.

The *restiform bodies* are the broadest and thickest of the columns of the medulla. They are situated to the outer side and behind the lateral tracts and the olivary bodies. They are the continuations upwards of the posterior columns of the spinal cord, and as they ascend, they diverge and pass into the cerebellum, con-

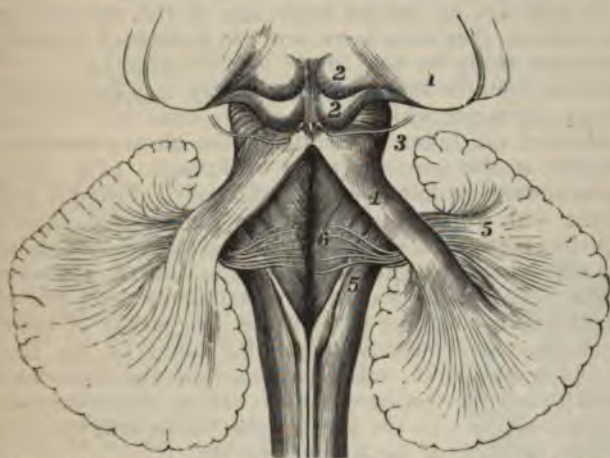

FIG. 263.—DIAGRAM OF THE FOURTH VENTRICLE AND RESTIFORM BODIES.

1. Thalamus opticus. 2. Nates and testes, or corpora quadrigemina. 3. The origin of fourth nerve. 4. Processus cerebelli ad testes. 5. Restiform bodies diverging. 6. Origins of eighth or auditory nerve.

stituting its inferior peduncles (Fig. 263). Owing to this divergence, the grey matter of the medulla is exposed, so that the floor of the fourth ventricle (of which the restiform bodies and the posterior pyramids assist in forming the lateral boundaries) is mainly composed of grey matter. Near the commencement of each restiform body there is easily recognizable an eminence interposed between the restiform body and the groove which separates it from the lateral tract; this eminence, narrow at first, is known as the *funiculus of Rolando*, but it soon enlarges to form a considerable prominence, called the *tubercle of Rolando*. The restiform body on a transverse section is wedge-shaped, and hence it is

sometimes called the *funiculus cuneatus*; near the level where the two bodies diverge, each presents an enlargement, known as the *cuneate tubercle*. The restiform bodies consist, as before said, of white fibres derived from the posterior and lateral columns of the cord; in its interior is some grey matter continuous with that in the posterior part of the cord.

The *posterior pyramids* (*funiculi graciles*) are two slender white columns on each side of the posterior median fissure, and are the continuations upwards of the posterior median columns of the spinal cord. Ascending, they diverge and thus form the apex of the fourth ventricle. At their point of separation the posterior pyramids enlarge and form the *clava*, after which they rapidly taper off and run up on the inner side of the restiform bodies, which, however, they soon leave, and are continued upwards into the cerebrum, along the floor of the fourth ventricle.

Emerging from the anterior median fissure may be noticed some superficial transverse white fibres, which cross over the anterior pyramids and the lower extremity of the olivary bodies; these are known as the *arciform fibres* of Rolando (Fig. 262), and they pass upwards to join the restiform body. They are probably connected with white fibres which run horizontally, constituting an imperfect septum between the two halves of the medulla, and may be seen when a longitudinal section is carefully made through its middle. The majority of these septal fibres enter the olivary bodies, and then emerging through the grey matter of the corpus dentatum, become continuous with the fibres of the restiform bodies and lateral tracts; others pass out from the posterior fissure and wind round the restiform bodies. These latter fibres are the *transverse striæ*, seen on the floor of the fourth ventricle, some of which form the roots of the auditory nerves.

The lower portion of the fourth ventricle can now be seen, bounded laterally by the diverging posterior pyramids and the restiform bodies, the floor being formed by the grey matter of the medulla. As only part, however, can be examined in the present stage, the full consideration of the fourth ventricle is deferred to a later stage in the dissection of the brain (p. 701).

**Minute Structure of Medulla Ob-
longata.** These are among the most complicated parts of the central nervous system. They contain white and grey matter intermixed. The white matter consists, in part, of the continuation upwards of the longitudinal fibres of the cord; in part, of horizontal fibres.

Anterior Pyramids. The anterior columns of the cord (Fig. 264), having reached the lower part of the medulla oblongata, are not continued straight through it, but diverge from each other, being reinforced by

the deep fibres of the lateral columns, which here cross over and form the decussation of the anterior pyramids. In their further progress the fibres of the anterior columns are arranged thus: some of them run up and form the outer portion of their own pyramid; some of them pass deeply beneath the pyramid to constitute the longitudinal fibres of the reticularis alba; these fibres are continued upwards into the cerebrum; some ascend beneath the olive to join the restiform body and thence to the cerebellum; another and larger fasciculus passes upwards, and, after embracing the olive, reunites to form a single bundle; this, joined by fibres (*olivary fasciculus*) from the olive, ascends under the name of the *fillet of Reil*, over the superior crus of the cerebellum, to pass to the corpora quadrigemina and the cerebral hemispheres (Fig. 264).

Lateral Tracts.

The *lateral columns* on reaching the medulla are disposed of in three ways, as follows:—some of its fibres, the *internal*, come forward between the diverging anterior columns, decussate in the middle line, and form part of the pyramid of the opposite side; others, the *external*, ascend with the restiform body (or tract) to the cerebellum; a third set, the *middle*, ascend beneath the olivary body, along the floor of the fourth ventricle (concealed by its superficial grey matter) as the *fasciculus teres*, and are continued along the upper part of the crus cerebri into the corpora quadrigemina and optic thalamus.

Olivary Bodies.

The *olivary bodies* are composed externally of white matter; but if a transverse section be made into them their interior presents an undulating line of yellowish-brown colour, called, from its zigzag shape, the *corpus dentatum* or the *nucleus of the olivary body*. It forms an interrupted circle, incomplete at its upper and inner side, so that it allows the entrance of a bundle of white fibres—*olivary peduncle*—from the medulla behind the anterior pyramid. The peduncular fibres pass in various directions: some pass into the grey matter; some pass through it and join the restiform body, under the name of the *internal arcuate fibres*; and some passing between the fibres over the olivary body, come to the surface and curve round it, forming the *external arcuate fibres*. Two other isolated grey nuclei may be recognized in this transverse section, one on the inner side of and the other behind the corpus dentatum: these, called the *accessory olivary nuclei*, are linear in shape, and are about $\frac{1}{2}$ of an inch (2 mm.) in length; the root-fibres of the hypoglossal nerve pass between the inner nucleus and the corpus dentatum, to emerge between the anterior pyramid and the olivary body.

The *posterior columns* are continued upwards under the name of the *restiform bodies* along the back of the medulla. At the apex of the fourth ventricle they diverge from each other and receive bundles of accessory fibres from the anterior pyramids and the lateral tracts, and are continued partly into the cerebellum, forming its *inferior crura*, and partly as the *fasciculi teretes* along the floor of the fourth ventricle into the cerebrum.

Restiform Bodies.

The *posterior columns* are continued upwards under the name of the *restiform bodies* along the back of the medulla. At the apex of the fourth ventricle they diverge from each other and receive bundles of accessory fibres from the anterior pyramids and the lateral tracts, and are continued partly into the cerebellum, forming its *inferior crura*, and partly as the *fasciculi teretes* along the floor of the fourth ventricle into the cerebrum.



FIG. 264.—DIAGRAM OF THE COURSE OF THE FIBRES THROUGH THE MEDULLA OBLONGATA.

1. Anterior column. 2. Lateral column.
3. Posterior column. 4. Posterior median column of the spinal cord. 5. Anterior pyramid. 6. Restiform body.
7. Posterior pyramid. 8. Fasciculus teres. 9. Inferior crus of the cerebellum. 10. To the corpora quadrigemina. 11. Crus cerebri.

Posterior Pyramids. The *posterior pyramids* are the continuations upwards of the posterior median columns of the spinal cord; and, like the restiform body, each divides into two fasciculi, one of which ascends and helps to form the inferior crus of the cerebellum, the other runs up with the *fasciculus tereus*.

Septum or Raphé. The horizontal fibres in the medulla oblongata were first accurately described by Stilling and Rolando, and subsequently by Clarke and others. Some of them form a *septum* and divide the medulla oblongata into symmetrical halves; some run longitudinally and others obliquely. The fibres which run from the dorsal to the ventral surface of the medulla—*fibræ rectæ*—pass outwards, in front, from the anterior median fissure, and are continuous with the superficial arched fibres of Rolando; while behind they are continuous with the fibres of the fasciculi graciles and their grey nuclei. The longitudinal fibres run vertically and are derived from the arcuate fibres and the *fibræ rectæ* which have altered their direction. The oblique fibres consist of the deep arcuate fibres which enter, or come out of the septum, and then pass to the outer part of the medulla. Some fibres, again, are transverse commissural fibres, and pass into the opposite anterior pyramid or the *formatio reticularis*,* and eventually assume a longitudinal direction.

Grey Matter of the Medulla. Although in the lower part of the medulla the grey matter in its interior is arranged in the same way as it is in the spinal cord, yet owing to the course of the decussating fibres of the lateral tracts which break up the anterior grey cornua in front, and to the diverging restiform bodies and posterior pyramids behind, the grey matter in the upper two-thirds of the medulla becomes altered both in appearance and in arrangement.

The grey matter of the anterior cornua soon loses its characteristic arrangement, as it becomes detached from the main part of the grey matter by the passage through it of bundles of white fibres of the medulla. At the lower part of the olivary body it is pushed backwards and outwards in consequence of the increase of the anterior pyramids and the olivary bodies, so as to lie in the lateral part of the medulla, just in front of the posterior horn, and constitutes a grey nucleus called the *nucleus lateralis*. The larger portion of the grey matter of the anterior cornua is intersected by white fibres and becomes broken up into an interlacement of fibres and nerve-cells, forming the *formatio reticularis*.

The grey matter of the posterior cornua becomes largely increased in the upper part of the medulla. At first the posterior cornua are pushed outwards by the restiform bodies, and subsequently by the posterior pyramids, so that they lie at right angles to the posterior median fissure. At the same time the *caput cornu posterioris* enlarges, and later on forms a prominent grey mass, the *tubercle of Rolando*, which becomes separated from the chief part of the grey matter by being intersected by transverse and longitudinal white fibres. Internal to the tubercle of Rolando, there are situated masses of grey matter in the restiform bodies and the posterior pyramids, constituting their nuclei. Higher up on a level with the middle of the olivary body we find internal to the grey matter of the posterior pyramid (*nucleus gracilis*) the nuclei of origin of the two portions of the pneumogastric nerve and of the hypoglossal nerve, the latter being nearest the middle line.

The central canal gradually approaches the posterior surface of the medulla, and above the middle of it opens out to form the median groove in the floor of

* The *formatio reticularis* comprises the anterior and lateral parts of the medulla, and consists of intersecting fibres which cross each other at right angles, some being longitudinal and some transverse in their direction.

the fourth ventricle. On each side of the groove we find a collection of grey matter which enlarges in the upper part and constitutes the *nucleus teres*.

The nuclei of the origins of the spinal accessory, the pneumogastric, and the glosso-pharyngeal nerves, will be described subsequently.

PONS VAROLII.

The *pons Varolii*, or *tuber annulare*, is the convex eminence of transverse white fibres (Fig. 262) which is situated at the base of the brain immediately above the medulla oblongata. It rests upon the basilar groove of the occipital and the sphenoid bones. Its *upper margin* is convex and well defined, and arches over the crura cerebri; the *lower*, also well defined, is nearly straight, being separated from the medulla by a transverse groove. *Laterally*, the pons becomes narrower, in consequence of its transverse fibres being more closely aggregated; these enter the anterior and under part of the cerebellum, constituting its *middle peduncle*. Along the middle runs a shallow groove, broader in front than behind, which lodges the basilar artery. If the pia mater be removed, we observe how the superficial fibres pass transversely to connect the two hemispheres of the cerebellum. Throughout the mammalia the size of the pons bears a direct ratio to the degree of development of the lateral lobes of the cerebellum; therefore it is larger in man than in any other animal.*

The pons consists of four layers of alternating transverse and longitudinal white fibres, intermingled with more or less grey matter, which is chiefly found on its upper surface, where it forms part of the floor of the fourth ventricle.

The *superficial layer* of white fibres is transverse, connecting the cerebellar hemispheres; the middle fibres pass transversely across, the inferior ascend slightly, while the superior pass backwards and outwards to enter the cerebellum.

The *second layer* consists of longitudinal fibres which are the continuation of the fibres of the medulla oblongata in their passage to the cerebrum. It is mainly composed of fibres derived from the anterior pyramids which pass up to form the superficial fibres, *crusta*, of the crura cerebri.

The *third layer* is formed of transverse fibres, which, from their peculiar arrangement take the name of *trapezium*; the fibres in their course outwards pass round in front of the superior olivary nuclei, then across the fasciculi of the facial nerves, and lastly in front of the ascending roots of the fifth nerves to enter the middle peduncle of the cerebellum.

The *deepest and uppermost layer* is composed of longitudinal nerve-fibres; those derived from the olivary fasciculi divide into two bundles, one ascending to the corpora quadrigemina, the other passing to the cerebrum; and those derived from the lateral and posterior columns of the cord, which, with a fasciculus from the fillet, form the fasciculi teretes in the floor of the fourth ventricle, and pass upwards to form the *tegmenta*, or deeper portions of the crura cerebri.

* Birds, reptiles, and fishes have no pons, as there are no lateral lobes to the cerebellum.

The grey matter is chiefly aggregated at the posterior part of the pons, and varies in thickness in different sections. Thus a section through the middle of the pons will show the following nuclei of grey matter, beginning from the central groove and passing outwards: a small intermediate portion of the facial nerve, the large nucleus of the sixth, the facial nerve, the large superior nucleus of the auditory nerve; while below we notice the superior olivary nucleus, the nucleus of the facial nerve, and externally the grey substance of Rolando, enclosing the ascending root of the fifth nerve.

The pons, like the medulla oblongata, has an imperfect median septum composed of horizontal fibres, some of which, at the anterior border, surround the crura cerebri.

THE CEREBRUM.

The *cerebrum* in man is so much more developed than the other parts of the encephalon that it completely overlies them, and forms by far the largest portion. It is oval in form and convex on its external aspect. It is divided in the middle line into two symmetrical parts, termed the *right* and *left hemispheres*, by the deep *longitudinal fissure*, which is occupied by the *falx cerebri* (p. 32).* The cerebrum is composed of numerous parts—viz., of certain internal ganglionic masses, the corpora striata, optic thalami, and corpora quadrigemina; of commissural white fibres, the fornix, corpus callosum, and the commissures of the third ventricle; of the pineal and pituitary bodies; and, lastly, of the two lateral hemispheres, which overlie and conceal the parts previously mentioned.

The cerebrum rests upon the anterior and middle fossæ of the base of the skull, and the tentorium cerebelli. There are three surfaces to each hemisphere: an *external* or convex; an *inner* or median; and an *inferior*, interrupted by the fissure of Sylvius.

By widely separating the two hemispheres at the longitudinal fissure (the brain being in its natural position), we discover that they are connected in the middle by the transverse white commissure, called the *corpus callosum*. In front of, and behind this mass, the longitudinal fissure extends to the base of the brain.

The cerebral hemispheres, viewed from above, form an ovoid mass, broader in front than behind, and convex to correspond with the vault of the calvarium. Their surface is mapped out by tortuous eminences termed *convolutions (gyri)*, separated from each other

* Examples are occasionally met with where the longitudinal fissure is not exactly in the middle line, the consequence of which want of symmetry is, that one hemisphere is larger than the other. Bichat (*Recherches physiologiques sur la Vie et la Mort*, Paris, 1829) was of opinion that this anomaly exercised a deleterious influence on the intellect. It was remarkable that the examination of his own brain after death went to prove the error of his theory.

by deep furrows (*sulci*), which extend to a variable depth. Many of the sulci are occupied by large veins in their course to the sinuses; others are filled with a subarachnoid fluid. The convolutions are folds of the brain, and their outer surface consists of grey matter, so that the extent of the grey substance is thus very largely increased; the grey matter here is called the *cortical substance*. The interior of the convolutions consists of white nerve substance. The convolutions are not symmetrical on both sides, although they follow a somewhat similar arrangement. The number, arrangement, and depth of the convolutions vary somewhat in different individuals, and, to a certain extent, may be considered an index to the degree of intelligence.*

The depth of the sulci between the convolutions varies in different brains, from an inch to half an inch (*2.5 cm. to 13 mm.*); hence it follows that two brains of equal size may be very unequal in point of extent of surface for the grey matter, and therefore in amount of intellectual capacity. Under the microscope the cortical layer is seen to consist of four layers—two of grey alternating with two of white—the external layer being always white. These layers are not equally thick in all situations, and in some parts six layers may be demonstrated, owing to the interpolation of a layer of white substance in the outer stratum: these are chiefly seen near the corpus callosum and in the occipital lobe.†

Some of the sulci, from their depth, regularity, and early period of development, are termed the *primary* or *interlobular fissures*, and map out the surface of the cerebrum into five lobes. Of these sulci there are three: the *fissure of Sylvius*, the *fissure of Rolando* or *central fissure*, and the *parieto-occipital fissure* (Fig. 265).

The *fissure of Sylvius* is seen on the base of the cerebrum, where it receives the lesser wing of the sphenoid bone. It begins outside the *locus perforatus anticus*, as a deep triangular depression—*vallecula Sylvii*—and then curves outwards as a deep cleft to the external surface of the cerebrum; it divides into two rami—an ascending or vertical, about an inch (*2.5 cm.*) in length, and a posterior or horizontal ramus, which passes backwards and slightly upwards, and

* Those who wish to investigate the cerebral convolutions in their simplest form in the lower classes of mammalia, and to trace them through their successive development and arrangement into groups as we ascend to the higher classes, should consult Leuret, *Anatomie comparée du Système Nerveux considérée dans ses Rapports avec l'Intelligence*, Paris, 1839; also Foville, *Traité de l'Anat. du Système Nerveux, &c.*, Paris, 1844. The convolutions of the human brain have been described by Ecker, *On the Convulsions of the human Brain*, 1873; and by Turner, *The Convulsions of the Human Brain topographically considered*, Edin. 1866.

† For an account of these laminae, see Lockhart Clarke, *Proceedings of the Royal Society*, 1863.

ends at the posterior third of the cerebrum by a bifid extremity. Within the fissure, near its commencement, a series of convolutions may be seen deeply placed; these are called the *gyri aperti*, or the *island of Reil*. In the fork between the two rami of the Sylvian fissure are several convolutions, which have been termed by Broca the *operculum of the insula*.

The *fissure of Rolando* or *central fissure* (Fig. 265, A) runs ob-

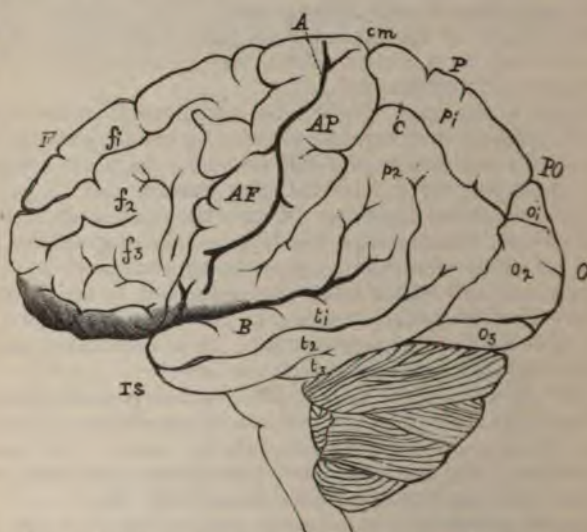

FIG. 265.—VIEW OF THE CONVOLUTIONS AND FISSURES OF THE EXTERNAL SURFACE OF THE BRAIN (LEFT SIDE).

A. Fissure of Rolando. B. Fissure of Sylvius. C. Inter-parietal fissure. P.O. Parieto-occipital fissure. C.M. Calloso-marginal fissure. F. Frontal lobe. P. Parietal lobe. O. Occipital lobe. T.S. Temporo-sphenoidal lobe. A.P. Ascending parietal convolution. A.F. Ascending frontal convolution. f_1, f_2, f_3 . Superior, middle, and inferior frontal convolutions, separated by the superior and inferior frontal sulci. p_1, p_2 . Superior and inferior parietal convolutions, separated by the inter-parietal fissure. o_1, o_2, o_3 . Superior, middle, and inferior occipital fissures. t_1, t_2, t_3 . Superior, middle, and inferior temporo-sphenoidal fissures.

liquely over the outer convex surface of the hemisphere. It commences close to the longitudinal fissure about its middle, from which it is separated by the marginal convolution. It then runs obliquely downwards and forwards, and terminates a little above the fork of the Sylvian fissure. As seen in Fig. 266, the two fissures form a V-shape, failing to be joined at the angle. The fissure is formed, in early foetal life, by a large vein, which subsequently atrophies, and is rarely bridged over.

The *parieto-occipital fissure* (Fig. 266, P.O.f.) is seen on the median surface of the hemisphere, towards its posterior part. It begins as a deep cleft on the median surface, about half an inch (13 mm.) behind the corpus callosum, then ascends nearly vertically, and ends on the external aspect of the cerebrum, about an inch (2.5 cm.) beyond the longitudinal fissure; this latter portion taking the name of the *external parieto-occipital fissure*.

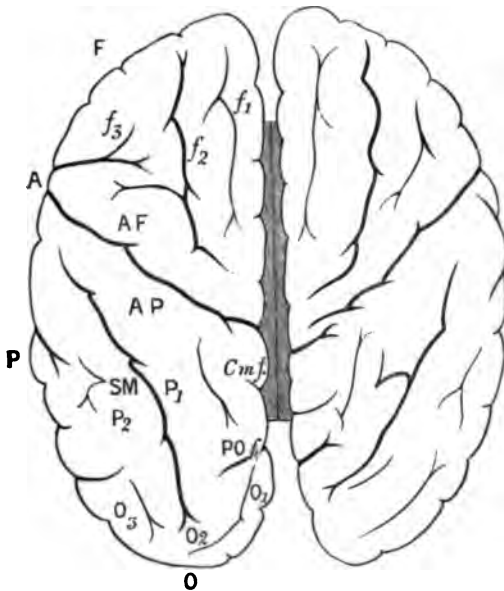


FIG. 266.—CONVOLUTIONS OF THE UPPER SURFACE OF THE BRAIN.

A. Fissure of Rolando. A.F. Ascending frontal convolution. A.P. Ascending parietal convolution. S.M. Supra-marginal convolution, below which is the angular gyrus. P.O.f. Parieto-occipital fissure. F. Frontal lobe. P. Parietal lobe. O. Occipital lobe. f_1, f_2, f_3 . Superior, middle and inferior frontal convolutions. P_1, P_2 . Superior and inferior parietal convolutions. O_1, O_2, O_3 . Superior, middle and inferior occipital convolutions. C.m.f. Callosal-marginal fissure.

The fissure of Sylvius is first seen about the middle of the third month of fetal life, and is caused by the extension backwards, and folding upon itself, of the mantle; the fissure of Rolando begins to be developed about the fifth month; and the parieto-occipital fissure between the third and fourth month of uterine life.

The primary fissures form the boundaries of the various lobes of which each hemisphere is composed.

The *frontal lobe* is that part of the front portion of the cerebrum, bounded behind by the fissure of Rolando, below by the

anterior part of the fissure of Sylvius, and on the median plane by the calloso-marginal fissure. Its inferior part rests on the anterior fossa, and is called the *orbital surface*, while its convex external surface is called the *frontal surface*.

The convolutions on its frontal surface are four in number: The *ascending frontal convolution* (Fig. 265, A.F.) which bounds, in front, the fissure of Rolando, and is usually connected above and below the fissure with the ascending parietal convolution; the union below forming the *operculum*, the union above part of the *paracentral lobule*; the upper and the lower union of these two convolutions thus shut off the fissure of Rolando from joining the fissure of Sylvius below, and the longitudinal fissure above.

The *superior, middle, and inferior frontal convolutions* (Fig. 265, f_1, f_2, f_3) course nearly horizontally; the *superior* runs along the margin of the longitudinal fissure, the *inferior* along the lower border of the lobe, arching over the ascending ramus of the Sylvian fissure; the *middle* is placed between these. In front of the ascending frontal convolution is a vertical fissure, *præcentral sulcus*, which prevents the frontal convolutions joining the former convolution.

The sulci which map out the frontal convolutions are two, the *superior and inferior frontal sulci*.

On the *orbital surface* there is a deep sulcus, the *tri-radiate sulcus*, whose rami pass forwards, outwards, and backwards, mapping this surface out into internal, anterior, and posterior orbital convolutions (Fig. 267, *Tr. s.*).

On this surface also we find the *olfactory lobe*, lodged in a deep cleft, the *olfactory sulcus* (Fig. 267, *Off. s.*), and although it will be described under the cranial nerves, it is strictly a cerebral lobe, for it is developed as a distinct outgrowth from the anterior cerebral vesicle; moreover, in early foetal life it possesses a cavity continuous with the general ventricular cavity of the brain.

The *parietal lobe* (Fig. 265, *p*) is placed between the fissure of Rolando and the external parieto-occipito fissure, and is bounded below by the horizontal limb of the fissure of Sylvius, and by a line continued from it to meet one passing down from the parieto-occipital fissure.

The convolutions of the parietal lobe are three: The *ascending parietal convolution* is bounded in front by the fissure of Rolando, and runs parallel with the ascending frontal convolution in front, which it joins above and below the fissure.

The *superior parietal convolution* (Fig. 265, *p*) is placed above the interparietal fissure, and courses horizontally backwards; posteriorly it runs beneath the parieto-occipital fissure, and is connected with the superior occipital convolution; this is known as the *first annectent convolution*; this convolution is also seen on the median

surface of the cerebrum. The *inferior parietal convolution* lies below the interparietal fissure, and consists of two portions: one, the *supra-marginal*, lies in front of the posterior ramus of the Sylvian fissure; the other, the *angular gyrus*, lies behind the fissure of Sylvius, and bends over the termination of the parallel sulcus; the angular convolution is connected behind with the occipital convolutions by the *second and third annectent convolutions*.

The *interparietal fissure* ascends at first nearly vertically, and then runs horizontally backwards from the ascending parietal convolution.

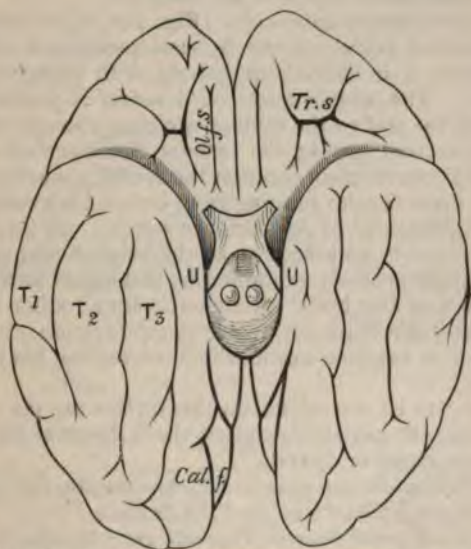


FIG. 267.—CONVOLUTIONS OF THE BASE OF THE CEREBELLUM.

Olf.s. Olfactory sulcus. *Tr.s.* Tri-radiate sulcus. *U.* Uncinate convolution. *Cal.f.* Calcarine fissure. *T₁*, *T₂*, *T₃*. Superior, middle, and inferior temporo-sphenoidal convolutions.

The *occipital lobe* (Fig. 265, *o*) consists of the posterior part of the hemispheres behind, bounded in front by the external parieto-occipital fissure, and by a line continued from it.

The convolutions on the external surface are three:

The *superior, middle, and inferior occipital convolutions* (Fig. 265, *o₁*, *o₂*, *o₃*) run nearly horizontally backwards, and are separated by the superior and inferior occipital fissures; anteriorly these convolutions are continuous with the parietal and temporo-sphenoidal convolutions, through the four *annectent gyri*. The first three have

been previously described; the lowest or fourth connects the inferior occipital with the inferior temporo-sphenoidal convolution.

There is usually a small, shallow, vertical fissure, the *transverse occipital*, which passes down behind the external parieto-occipital fissure.

On the median plane is the *cuneate lobule*, which forms part of the occipital lobe, and will be described further on.

The *temporo-sphenoidal lobe* is bounded in front and above by the fissure of Sylvius and its horizontal ramus, and forms that part of the hemisphere which occupies the middle cerebral fossa.

The convolutions of this lobe are three:—

The *superior temporo-sphenoidal* (Fig. 267, T₁) is bounded above by the horizontal ramus of the Sylvian fissure, and below by the parallel fissure; it is continuous behind with supra-marginal and angular gyri. The *middle temporo-sphenoidal* is joined behind to the angular gyrus and to the middle occipital convolution through the third annectent gyrus; the *inferior* is connected with the inferior occipital convolution through the fourth annectent gyrus.

There are three fissures running from before backwards, the *superior temporo-sphenoidal* or *parallel*, the *middle*, and the *inferior*.

The convolutions and fissures of the median and tentorial surfaces can only be properly examined by making an antero-posterior vertical section of the brain through the longitudinal fissure. As this would spoil the brain for future demonstration, the student is recommended to examine one in which this section has been already done.

The *fissures* to be examined on this surface are the calloso-marginal, the internal parieto-occipital, the calcarine, the collateral, and the hippocampal or dentate.

The *convolutions* are the præcuneus, the cuneate, the uncinata, the marginal, the gyrus fornicatus, and the dentate.

The *calloso-marginal fissure* (Fig. 268 *cm.*) commences beneath the rostrum of the corpus callosum, curves in front and round the genu, and then runs nearly parallel with the anterior two-thirds of the corpus callosum; then, changing its direction, it ascends obliquely and terminates on the external aspect of the hemisphere, where it forms a deep notch immediately behind the fissure of Rolando.

The *internal parieto-occipital fissure*, PO, passes nearly vertically downwards and joins the calcarine fissure at an acute angle.

The *calcarine fissure*, c, begins close to the posterior border of the cerebrum, and then, running nearly horizontally forwards, is joined by the preceding fissure; it terminates a little below the posterior border of the corpus callosum. It corresponds with the hippocampus minor in the posterior horn of the lateral ventricle.

The *collateral fissure* (Fig. 268, *Cl.f.*) is situated below the calcarine fissure, and runs parallel with it. It separates the superior and inferior occipito-temporal convolutions, and causes the eminencia collateralis in the descending horn of the lateral ventricle.

The *hippocampal fissure* takes its origin in the posterior part of the gyrus fornicatus, and, passing downwards and forwards, it ends by forming the notch in the uncinatè gyrus. It corresponds to the hippocampus major.

The *præcuneus* or *quadrate lobule* (Fig. 268, P.C.), is bounded in front by the calloso-marginal fissure, behind by the internal

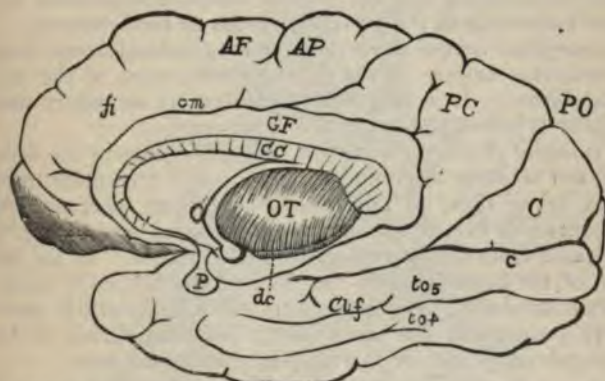


FIG. 268.—CONVOLUTIONS AND FISSURES OF THE MEDIAN AND TENTORIAL SURFACES OF RIGHT HEMISPHERE.

C.C. Corpus callosum. A.F. Ascending frontal convolution. A.P. Ascending parietal convolution. P.O. Parieto-occipital fissure. P.C. Præcuneus or quadrate lobe. C. Cuneus. c. Calcarine fissure. *Cl.f.* Collateral fissure. G.F. Gyrus fornicatus. *cm.* Calloso-marginal fissure. *f.* Superior frontal or marginal convolution. O.T. Optic thalamus. P. Pituitary body. *dc.* Dentate convolution. *to4.* Gyrus occipito-temporalis lateralis. *to5.* Gyrus occipito-temporalis medialis.

parieto-occipital fissure. It consists of numerous convolutions, and belongs to the parietal lobe.

The *cuneate lobule* (Fig. 268, *c*) is triangular in shape, and is situated between the converging internal parieto-occipital and calcarine fissures. It is part of the superior occipital convolution.

The *gyrus fornicatus* (Fig. 268, G.F.) begins in front of the locus perforatus anticus, and winds around the corpus callosum, keeping close to its upper surface. It curves around its posterior free border, and is continuous below with the uncinatè gyrus. Between this convolution and the corpus callosum is a well-marked furrow, which sometimes takes the name of the *ventricle of the corpus callosum*.

The part of the convolution that forms the boundary of this ventricle is termed the *labium cerebri*.

The *dentate convolution* (*fascia dentata*, Fig. 268, *dc*) is the grey convolution lying in the dentate fissure, and takes its name from the notched appearance it presents, owing to the arrangement of the choroid arteries as they pass in through the fissure into the descending horn of the lateral ventricle.

The *uncinate gyrus* (Fig. 267, *u*) is the anterior part of the superior occipito-temporal convolution, which ends in a peculiar hook-like process at the front of the temporo-sphenoidal lobe.

The *inferior occipito-temporal convolution* (Fig. 268, *to*₄) is situated between the collateral and the inferior temporo-sphenoidal fissures, and runs backwards to the posterior border of the cerebrum.

The *marginal convolution* skirts the longitudinal fissure from the *locus perforatus anticus* as far as the termination of the callosomarginal fissure. It is frequently indented by secondary furrows, and usually is joined to the *gyrus fornicatus*.

The *island of Reil*, or the *central lobe*, lies deeply in the fissure of Sylvius, not far from its commencement. It is triangular in shape, the apex being close to the anterior perforated spot, and from it radiate outwards five or six short convolutions (*gyri operati*), which are separated from the operculum by a deep fissure. In the normal position of the brain it forms the floor of the lenticular nucleus of the corpus striatum. It appears very early in foetal life, and is at first very prominent, but subsequently becomes closed in by the increasing development of the temporo-sphenoidal lobe.

The several objects seen at the base of the brain should now be examined, proceeding in order from the front (Fig. 269). In this description the cerebral nerves are omitted.

These will be examined hereafter.

In front we notice the triangular frontal lobes, separated from each other by the longitudinal fissure, and bounded behind by the fissure of Sylvius.

In the middle line, dividing the frontal lobes, is the longitudinal fissure. By gently separating these lobes, we expose the corpus callosum, or the great transverse commissure which connects the two hemispheres of the cerebrum. Continued backwards and outwards on each side from the corpus callosum to the fissure of Sylvius is a white band, the peduncle of the corpus callosum. Extending from the corpus callosum to the optic commissure is a thin grey layer, the *lamina cinerea*. Between the frontal and temporo-sphenoidal lobes is the fissure of Sylvius, which lodges the middle cerebral artery. The optic commissure, formed by the union of the two optic tracts, is seen in the middle line behind the

**Nomenclature of the
Parts at the Base
of the Brain.**

lamina cinerea. At the root of the fissure of Sylvius is the locus perforatus anticus.* Immediately behind the optic commissure is a slight prominence of grey matter, the tuber cinereum; from this descends a conical tube of reddish colour, the infundibulum, to the apex of which is attached the pituitary body. Behind the tuber

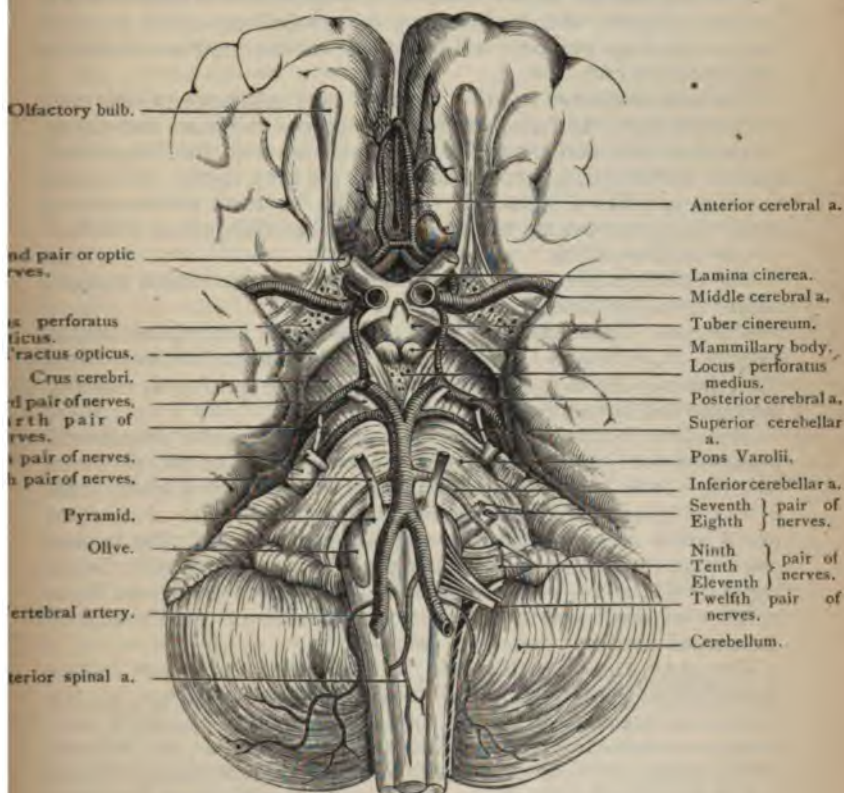


FIG. 269.

cinereum are two round white bodies, the corpora albicantia. Posterior to these is the locus perforatus posticus, which is bounded behind by the pons, and laterally by the two diverging crura cere-

* Called *perforatus* from its being perforated by a number of blood-vessels for the supply of the corpus striatum.

bri, two round cords of white substance which emerge from the anterior border of the pons. Winding round the outer side of each crus is a soft white band, the optic tract.

Examine now in detail the various objects above enumerated, most of which are shown in Fig. 269.

The *longitudinal fissure* is visible in front, where it separates the two frontal lobes, and, by lifting up the cerebellum, it can be seen behind dividing the occipital lobes. It can be more satisfactorily examined later on.

The *lamina cinerea* is a thin layer of grey substance, which runs backwards from the termination of the corpus callosum, and passes above the optic commissure to be connected with the tuber cinereum. Laterally, it is continuous with the grey matter of the two anterior perforated spots. If the lamina be torn, which is very easily done, an opening is made into the anterior part of the floor of the third ventricle.

The *olfactory lobe* lies in its own sulcus on the orbital surface, nearer its mesial aspect.

The *optic commissure* is placed immediately behind the lamina cinerea. It is formed by the junction in the middle line of the two optic tracts. From it the two optic nerves can be traced, running forwards and outwards.

The *locus perforatus anticus* is a shallow triangular depression, placed to the inner side of the commencement of the fissure of Sylvius. It is bounded in front by the two diverging white roots of the olfactory lobe, and behind by the optic tract. It is composed partly of grey substance, and is continuous with the lamina cinerea on the inner side. Crossing it is seen a broad white band, the *peduncle of the corpus callosum*. This space is pierced by a number of small apertures for the transmission of small vessels to the corpus striatum; hence its name.

The *tuber cinereum* (Fig. 269) is a prominence of grey matter immediately behind the optic commissure, and in front of the corpora albicantia. It forms part of the floor of the third ventricle, and from it a conical tube of reddish colour, the *infundibulum*, descends to the posterior lobe of the pituitary body. There is a large collection of grey matter on the outer side of the tuber cinereum, and internal to the optic tract, called the *basal optic ganglion*, from which fibres pass to the corresponding optic tract.

The *pituitary body* occupies the sella turcica, is of a reddish-brown colour, and consists of two lobes. Of its two lobes the anterior and larger, is concave posteriorly, to receive the posterior lobe, and weighs from five to ten grains ($\frac{3}{2}$ to $\frac{7}{2}$ gm.). The two lobes consist of different structure, and differ in their development; the *posterior* is developed downwards from the third

ventricle, and is hollow; subsequently there is a large increase of connective-tissue structure and blood-vessels in it, so that the cavity is usually obliterated. The *anterior* is darker, and is surrounded by a connective-tissue capsule; on section it resembles in structure the thyroid gland, being composed of reticular tissue, with numerous cavities filled with nucleated cells and granular matter; it is originally developed as a prolongation from the ectoderm of the buccal cavity, from which it soon becomes isolated.

The *corpora albicantia* (*mammillaria*) are two round white bodies, situated behind the tuber cinereum. Each is formed by the curl upon itself of the anterior crus of the fornix, called the *bulb of the fornix*, which then turns backwards and upwards to end in the optic thalamus. They contain within them some grey matter, and up to the seventh month of foetal life they form one mass.

The *locus perforatus posticus* (*pons Tarini*) is a depression of grey matter placed between the diverging crura cerebri and behind the corpora albicantia. Its surface is penetrated by small vessels which supply the optic thalami. From its grey substance some white fibres emerge and turn round over the crura cerebri to enter the white medullary portion of the cerebellum.

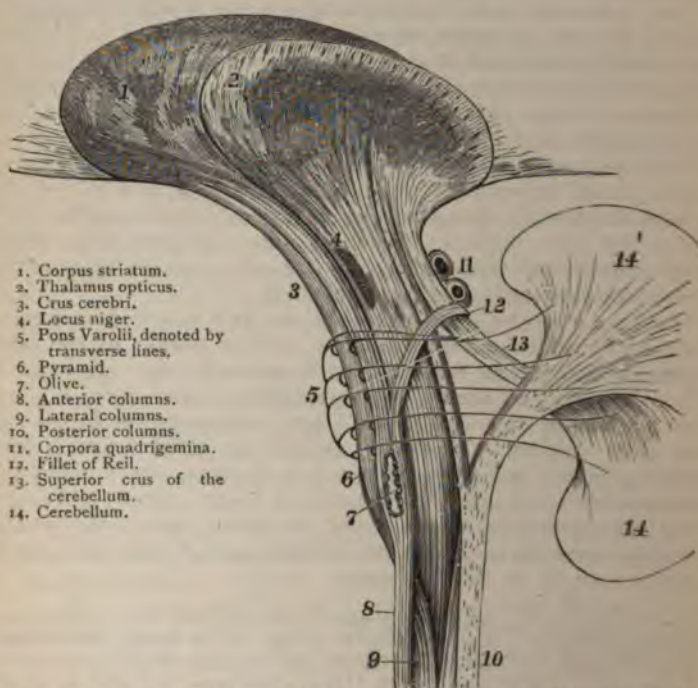
The *crura cerebri* (Fig. 269) are the two rounded masses of white matter which emerge from the anterior border of the pons Varolii, and then pass forwards and outwards to enter the anterior and inner aspect of the temporo-sphenoidal lobes. Each is about three-quarters of an inch (18 mm.) long, and is rather broader in front than behind. On the inner side the third nerve is seen emerging from a groove (*oculo-motor*) in the crus, which marks the division of the crus into two portions, an upper (dorsal) and larger called the *tegmentum*, and a lower or ventral, called the *crusta*. The optic tract curves round the anterior part of each crus, and is adherent to it by its anterior border.

Structure of the Crura Cerebri.

These are composed of longitudinal fibres, derived from the pyramids, from part of the lateral and restiform columns of the medulla, and from the grey matter in the pons Varolii. If one of the crura be divided longitudinally, there is found in the middle of it a layer of dark-coloured nerve-substance, called *locus niger*, which separates the crus into an upper and lower stratum of fibres. The lower stratum (*crusta*) is tough and coarse, and consists of the continuation of the fibres proceeding from the pyramid and the pons. The upper stratum (*tegmentum*) is much softer and finer in texture; it is composed of the fibres proceeding from the lateral and restiform columns; also from the superior crus of the cerebellum. Tracing the fibres of the crus cerebri into the cerebral hemisphere, we find that its lower fibres ascend chiefly through the corpora striata, its upper fibres through the thalami optici. In passing through these ganglia, the crus receives a large addition to its fibres; these branch out widely towards all parts of the hemisphere, in order to reach the cortical substance on the surface.

Origin of the
Cerebral Nerves.

The *cerebral nerves* are given off in pairs, named the first, second, third, etc., according to the order in which they appear, beginning from the front. There are twelve pairs. Some are nerves of special sense—as the olfactory, the optic, the auditory; others are nerves of common sensation—as the larger root of the fifth, the glosso-pharyngeal, and the pneumogastric; others, again, are nerves of



1. Corpus striatum.
2. Thalamus opticus.
3. Crus cerebri.
4. Locus niger.
5. Pons Varolii, denoted by transverse lines.
6. Pyramid.
7. Olive.
8. Anterior columns.
9. Lateral columns.
10. Posterior columns.
11. Corpora quadrigemina.
12. Fillet of Reil.
13. Superior crus of the cerebellum.
14. Cerebellum.

FIG. 270.—DIAGRAM OF THE COURSE OF THE FIBRES THROUGH THE MEDULLA AND PONS.

motion—as the third, the fourth, the smaller root of the fifth, the sixth, the facial, the spinal accessory, and the hypoglossal.

First Pair or
Olfactory Nerves.

These (Fig. 271, 1) are from their early development outgrowths from the cerebral lobes, and not, strictly speaking, nerves. The nerve is triangular on section, the apex of the triangle being lodged in a straight furrow (*olfactory sulcus*) in the orbital surface of the frontal lobe. It proceeds straight forwards, and terminates in

the olfactory bulb, which lies on the cribriform plate of the ethmoid bone.

The olfactory lobe is oval, of a reddish-grey colour and very soft consistence, owing to the large amount of grey matter contained in it. It gives off from its under surface about twenty branches, which pass through the foramina in the cribriform plate.* For description of these, see p. 270.

The nerve arises by three roots—an outer and an inner, composed of white matter, and a middle, composed of grey (Fig. 271).

The *outer root* passes backwards and outwards as a thin white line, along the outer side of the locus perforatus anticus, to the commencement of the fissure of Sylvius.

Its deeper origin has been traced to a nucleus of grey matter in the anterior part of the temporo-sphenoidal lobe.

The *inner root* passes backwards and inwards to the posterior extremity of the internal convolution of the frontal lobe, and thence may be traced to the gyrus fornicatus.

The *middle or grey root* arises from the grey matter of the sulcus in which the nerve is lodged, and from the grey matter of the locus perforatus anticus in the fork between the two white roots; this is

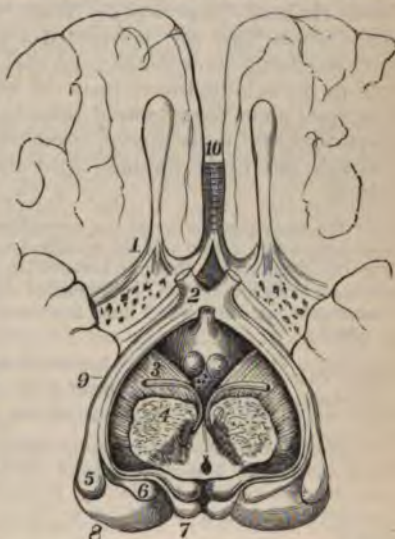


FIG. 271.—DIAGRAM OF THE ORIGINS OF THE OLFACTORY AND OPTIC NERVES.

1. Olfactory lobe. 2. Optic n. 3. Crus cerebri.
4. Section of crus to show locus niger. 5. Corpus geniculatum externum. 6. Corpus geniculatum internum. 7. Corpora quadrigemina. 8. Thalamus opticus. 9. Tractus opticus. 10. Corpus callosum.

* The olfactory nerve and its ganglion, as stated above, are integral parts (the prosencephalic lobe) of the brain. What in human anatomy is called the origin of the nerve is, in point of fact, the crus of the olfactory lobe, and is in every way homologous to the crus cerebri or cerebelli. In proof of this, look at the enormous size and connections of the crus in animals which have very acute sense of smell. Throughout the vertebrate kingdom there is a strict ratio between the sense of smell and the development of the olfactory lobes. Again, in many animals these lobes are actually larger than the cerebral, and contain in their interior a cavity which communicates with the lateral ventricles. According to Tiedemann, this cavity exists even in the human fetus at an early period.

called the *tuber olfactorium*. It contains white fibres in its interior, which have been traced to the corpus striatum.

**Second Pair or
Optic.**

The *optic tracts* arise from the anterior lobes (*notes*) of the corpora quadrigemina, the corpora geniculata, and the posterior part of the optic thalami (Fig. 271). They wind round the crura cerebri, with which they are connected by their anterior borders, and, after receiving some fibres from the basal optic nucleus (p. 679), join in the middle line to form the *optic commissure*. This commissure rests upon the sphenoid bone in front of the sella turcica, and from it each optic nerve, invested by its fibrous sheath, passes through the optic foramen into the orbit and terminates in the retina.

At the commissure some of the nerve-fibres cross from one side to the other. This decussation affects only the middle fibres of the nerve; the outer fibres pass from one optic tract to the optic nerve of the same side; the inner fibres pass from one optic tract round to the optic tract of the opposite side; while in front of the commissure are fibres which pass from one optic nerve to its fellow (Fig. 274, p. 686).

**Third Pair or
Motores Oculorum.**

The apparent origin of the *third nerve* is from the inner side of the crus cerebri, immediately in front of the pons.

Some of its roots, however, pass through the locus niger and the tegmentum of the crus, to reach a nucleus of large yellow cells beneath the iter a tertio ad quartum ventriculum (*Aqueduct of Sylvius*), extending forwards as far as the posterior commissure, and behind as far as the nucleus of the fourth nerve (see below).

It runs forwards through the cavernous sinus, and, passing through the sphenoidal fissure in two divisions, supplies all the muscles of the orbit except the superior oblique and the external rectus.

**Fourth Pair or
Trochlear Nerves.**

The *fourth nerve* has its deep origin from a nucleus of grey matter in the floor of the aqueduct of Sylvius, beneath the corpora quadrigemina, and almost continuous superiorly with the yellow nucleus of the third nerve. The nerve fibres then run backwards, upwards, and inwards in the lateral wall of the Sylvian aqueduct, and reach the anterior part of the valve of Vieussens, where they cross over to the opposite side.

The nerve then emerges from the valve of Vieussens close to the middle line, and, winding round the crus cerebri, enters the orbit through the sphenoidal fissure and supplies the superior oblique.

**Fifth Pair or Tri-
geminal Nerves.**

The *fifth nerve* is the largest of all the cranial nerves, and consists of two roots, a larger or sensory, and a smaller or motor. It has its apparent origin from the outer side of the pons Varolii, and a few of the transverse fibres of this body separate the two roots of the fifth.

The *motor or smaller root* consists of fibres which take origin from an oval grey nucleus (*motor nucleus*) situated in the front part of the floor of the fourth ventricle, internal to its lateral boundary; in their passage forwards the fibres are joined by filaments from the descending root of the fifth, which arise from the grey matter in the lateral wall of the aqueduct of Sylvius, beneath the anterior lobes of the corpora quadrigemina. It also receives some fibres from the raphé. The *sensory and larger root* arises by fibres having their origin chiefly in the *superior sensory nucleus*, which is situated external to the motor nucleus, and partly by fibres known as the ascending fibres, which may be traced far down in the medulla from a mass of nerve-cells in connection with the grey tubercle of Rolando and its upward prolongation.

The two divisions of the nerve proceed forwards over the apex of the petrous portion of the temporal bone; here is developed, upon the sensory root, the Gasserian ganglion. The root then divides into three branches—the *ophthalmic*, which passes through the sphenoidal fissure; the *superior maxillary*, which passes through the foramen rotundum; the *inferior maxillary*, which passes through the foramen ovale. They all confer common sensation upon the parts they supply, which comprise the entire face and sides of the head. The small motor root passes beneath the ganglion, with which it has no connection, and accompanies the inferior maxillary division, to be distributed to the muscles of mastication.

**Sixth Pair or
Abducentes.**

The *sixth nerve* emerges from the transverse groove between the pons and the anterior pyramid (Fig. 269), with both of which it is connected.

Its deep origin can be traced to an oval grey mass of nerve-cells in the fasciculus teres in the floor of the fourth ventricle, close to the median groove and in front of the transverse striæ. The nerve fibres pass downwards from their origin through the pons parallel with the septum, and emerge from the transverse groove as before stated.

It leaves the skull through the sphenoidal fissure, and, passing between the two heads of the external rectus, is distributed to this muscle.

**Seventh Pair or
Facial Nerves.**

The *facial nerve* or *portio dura* (Fig. 269) has its apparent origin from the groove between the pons and the restiform tract, and behind the olivary body.

Its deep origin may be traced to an elongated mass of grey substance, placed deeply in the floor of the fourth ventricle, between the motor nucleus of the fifth and the transverse striæ. From this origin its fibres run upwards, backwards, and inwards to the floor of the fourth ventricle, and wind round the nucleus of the sixth, so as to course superficial to it in the fasciculus teres. The nerve then makes a sharp bend upon itself, and passes downwards and outwards through the pons between the superior olivary nucleus and the ascending root of the fifth nerve. A small separate fasciculus of this nerve—*pars intermedia*—lies between it and the auditory nerve, and forms connections with both; it arises from the lateral column of the cord.

The nerve enters the meatus auditorius internus. For the further description of the portio dura, see p. 64.

**Eighth Pair or
Auditory Nerves.**

The *auditory nerve* emerges from the same groove as the preceding nerve, and is situated immediately beneath it, being separated from it only by the pars intermedia.

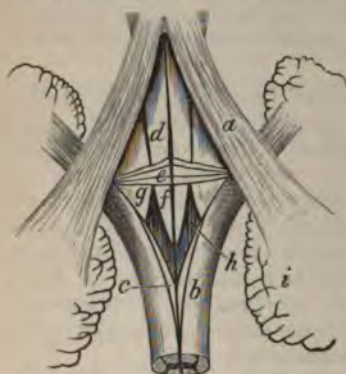

FIG. 272.—VIEW OF THE FLOOR OF THE FOURTH VENTRICLE.

- a, Superior peduncles of the cerebellum. b, Restiform tracts. c, Posterior pyramids. d, Fasciculus teres: external to it is the superior fovea. e, Striæ acusticæ. f, Fasciculus teres. g, Tuberculum acusticum. h, Inferior fovea. i, Cerebellum.

Its deep origin is principally from the *inner auditory nucleus*, situated in the floor of the fourth ventricle, under the tuberculum acusticum; this nucleus extends from beneath the acoustic tubercle to the middle of the anterior half of the floor, passing beneath the transverse striæ; on its inner side, below, is the vagal nucleus; on its outer side is the restiform body; from this nucleus the fibres pass outwards, and, on curving round the restiform body, are joined by some filaments from the transverse striæ. A few of the filaments of the auditory nerve come from another nucleus situated in front of the medullary striæ and external to the preceding nucleus, and which gets larger as it passes upward.

These two bundles unite, and the nerve passes outwards and enters the meatus auditorius internus in company with the portio dura. It divides at the bottom of the meatus into cochlear and vestibular branches, which are distributed to the internal ear.

Ninth Pair or Glosso-pharyngeal Nerves. The *glosso pharyngeal nerve* arises apparently by several filaments from the restiform body below the auditory nerve.

Its deep origin is from a nucleus in the inferior fovea of the fourth ventricle, continuous behind with the vagal nucleus, and covered in front by the inner auditory nucleus.

The glosso-pharyngeal nerve passes through the middle compartment of the foramen jugulare, and is distributed to the mucous membrane of the pharynx and back of the tongue (p. 259).

Tenth Pair or Pneumogastric Nerves. The *pneumogastric nerve* arises from a grey nucleus (divided into two by a bundle of white fibres), which is placed between the glosso-pharyngeal nucleus in front and the spinal-accessory nucleus behind, in the inferior fovea.

The fibres, about twelve in number, pass through the medulla, and emerge from the restiform body, below the glosso-pharyngeal,

and join to form a single nerve. This passes through the foramen jugulare, separated from the preceding by a septum of dura mater, and is distributed to the pharynx, larynx, the heart and lungs, the oesophagus and stomach.

Eleventh Pair or Spinal Accessory Nerves.

The *spinal accessory nerve* is composed of two parts: an upper or accessory portion, which arises from the medulla below the vagus, and a lower or spinal portion, which arises from the spinal cord.

The accessory fibres may be traced to the grey nucleus, which is connected in front with the vagal nucleus, and lies close to the median sulcus of the fourth ventricle, extending to the apex of the calamus scriptorius and along the side of the central canal; the spinal portion may be traced below to the tractus intermediolateralis and anterior cornu, and above to the posterior cornu, arising by slender filaments as low down as the fifth or sixth cervical vertebra.

The spinal portion ascends behind the ligamentum denticulatum, through the foramen magnum, into the skull, and joins the accessory part. The *nervus accessorius* then passes through the foramen jugulare with the two preceding nerves; its accessory portion joins the pneumogastric nerve, and its spinal portion supplies the sternomastoid and the trapezius. The course and distribution of this nerve has been described in the dissection of the head and neck.

The Twelfth or Hypoglossal Nerves.

The *hypoglossal nerve* arises by several filaments from the medulla, which emerge from the groove between the anterior pyramid and the olivary body.

Its fibres may be traced to a long grey nucleus which forms an eminence in the floor of the fourth ventricle, in front and to the inner side of the vagal nucleus.

The filaments are collected into two fasciculi, which pierce the dura mater through two apertures and join in the anterior condylar foramen; it is distributed to the muscles of the tongue and the depressor muscles of the os hyoides and larynx.

Dissection of the Brain.

The brain should now be laid on its base. We first notice a median fissure, separating the cerebrum into two symmetrical hemispheres; this is the *longitudinal fissure*. By gently separating the hemispheres we see that the fissure extends in front and behind to the base, but that in the middle there is at the bottom a white band of nerve-substance, which is the great transverse commissure of the cerebrum, and termed the *corpus callosum*, upon which are seen the two anterior cerebral arteries.

Slice off the hemispheres to about half an inch (13 mm.) above the level of the corpus callosum. The cut white surface presents an oval appearance and is called the *centrum ovale minus*. The

white substance is surrounded by a tortuous layer of grey matter about one-eighth of an inch (*3.3 mm.*) in thickness. This grey substance consists of four layers—two of grey alternating with two of white, the most external layer being white. In some places, chiefly at the base of the brain, six layers have been demonstrated. The white substance is spotted with red dots (*puncta vasculosa*); these are due to the escape of blood from the divided vessels. The corpus callosum is now seen to be overlaid on each side by the gyrus fornicatus; the border is termed the *labium cerebri*, and the space between the gyrus and the corpus callosum is called the *ventricle of the corpus callosum*.

Now slice off the hemisphere down to the level of the corpus

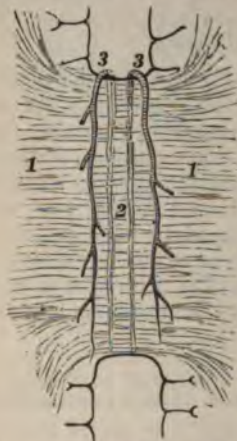


FIG. 273.—UPPER SURFACE OF CORPUS CALLOSUM.

1, 1. Lineæ transversæ. 2. Raphé. 3, 3. Anterior cerebral a.



FIG. 274.—DIAGRAM OF LAMINA CINEREA.

1, 1. Peduncles of corpus callosum. 2. Lamina cinerea. 3. Commissure of optic nerves.

callosum, when a section is made of the white substance, called the *centrum ovale majus*. The corpus callosum is now well exposed.

Corpus Callosum. This stratum of white substance, consisting of transverse commissural fibres, is the chief connecting medium between the two hemispheres, and is called the *great transverse commissure* of the cerebrum; and moreover on each side forms the roof of the lateral ventricles. Its surface is slightly arched from before backwards; it is about four inches (*10 cm.*) long and one inch (*2.5 cm.*) in its greatest breadth, which is behind. It is rather nearer to the front than to the back part of the brain, and it is thicker at the ends than in the middle, and

thicker behind than in front. A shallow groove called the *raphe* runs along the middle of the upper surface (Fig. 273); in a fresh brain, two longitudinal white tracts, named *striae longitudinales*, or the *nerves of Lancisi*, run parallel to it; and external to these again are two other longitudinal fibres, *striae longitudinales laterales*. The surface of the corpus callosum is marked by transverse lines which indicate the course of its fibres; these are the *lineae transversae* of the old anatomists. The anterior cerebral arteries proceed along the surface of the corpus callosum to the back of the brain.

The anterior part of the corpus callosum turns downwards and

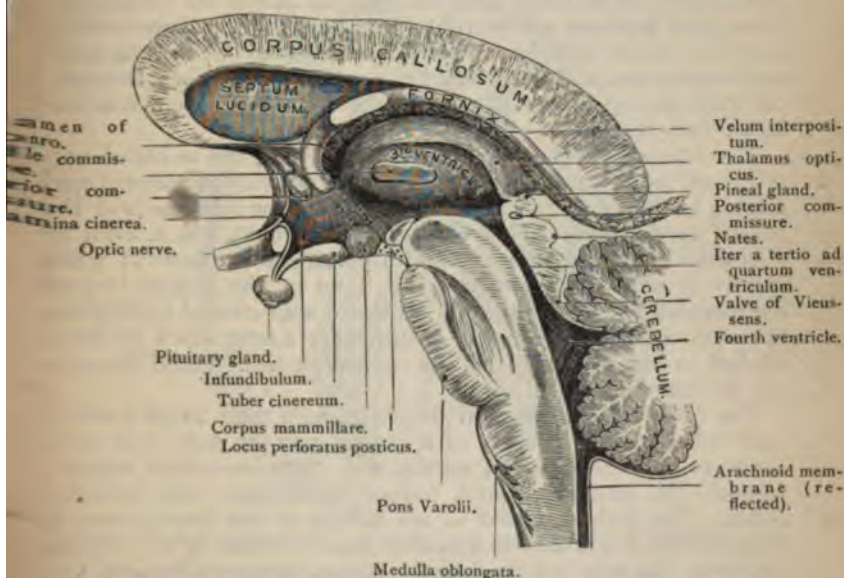


FIG. 275.—VERTICAL SECTION THROUGH THE CORPUS CALLOSUM, AND PARTS BELOW.

backwards, forming a bend called its *genu*. The inferior part of this bend—*rostrum*—becomes gradually thinner and narrower, and terminates in two peduncles, which diverge from each other and are lost, one in each fissure of Sylvius. Between these crura is placed the lamina cinerea (Fig. 271, p. 681). The posterior part of the corpus callosum terminates in a thick, round border—the *splenium*—which is free, and beneath it the pia mater enters the interior of the ventricles. A satisfactory view cannot be obtained of the arch formed by the corpus callosum, of its terminations in front and behind, and of the relative thickness of its different parts, without

making a perpendicular section through a fresh brain, as shown in the preceding figure.*

Connected with the under surface of the posterior part of the corpus callosum is the fornix, which separates from it in front, the two structures, being connected by a vertical septum—the *septum lucidum* (Fig. 275).

Lateral Ventricles. A longitudinal incision should be made on each side through the corpus callosum about half an inch (13 mm.) from its median raphé. Care must be taken not to cut too near the middle line, in order to preserve the delicate partition which descends from the under surface of the corpus callosum, and separates the ventricles from each other. Two cavities, called the *lateral ventricles*, will thus be exposed, one in each cerebral hemisphere, and they should afterwards be laid open throughout their whole extent. Their general form should be first examined; then the several objects seen in them.

The *lateral ventricles* are two serous cavities, one in each hemisphere of the brain. They are occasioned by the enlargement and folding backward of the cerebral lobes over the other parts of the central nervous axis. They contain a serous fluid, which, even in a healthy brain, sometimes exists in considerable quantity; when greatly in excess it constitutes one form of the disease termed hydrocephalus. The ventricles are lined with ciliated epithelium, laid upon a layer of neuroglia (*ependyma*); a term which has been applied to that peculiarly delicate connective tissue found throughout the brain and spinal cord.

The ventricles are crescentic in shape, with their backs towards each other. Each consists of a central part or *body*, and three horns or *cornua*—*anterior*, *middle*, and *posterior*—which extend, respectively, into the frontal, temporo-sphenoidal, and occipital lobes. The body, situated in the middle of the hemisphere, is triangular in shape, and is separated from its fellow by the *septum lucidum*. Its roof is formed by the corpus callosum (Fig. 277, 1); internally, it is bounded by the *septum lucidum* (Fig. 275); on the floor, beginning from the front, are seen the *corpus striatum*, the *tentia semicircularis*, the *optic thalamus*, the *choroid plexus*, and the *corpus fimbriatum* of the *fornix* (Fig. 276).

The *anterior horn* extends into the frontal lobe, and as it passes forwards it diverges slightly from its fellow of the opposite side. It is triangular in shape; its roof and anterior wall are formed by

* The corpus callosum is more or less developed in all mammalia, but is absent in birds, reptiles, and fish. It has been absent in the human subject without any particular mental deficiency. See cases recorded by Reil, *Archiv für die Phys. u. xi.*, and Wenzel, *De penitiori Struct. Cereb.*, p. 302.

the corpus callosum, and it curves round the anterior extremity of the corpus striatum.

The *posterior horn* can be traced into the occipital lobe, where it passes at first backwards and outwards, and then, narrowing to a point, converges towards its fellow. Its roof is formed by the fibres of the corpus callosum as they pass backwards and outwards from the splenium; on its floor are seen on the inner side an eminence, the *hippocampus minor*, and external to it a triangular flat surface, called the *pes accessorius* or *eminencia collateralis*.*

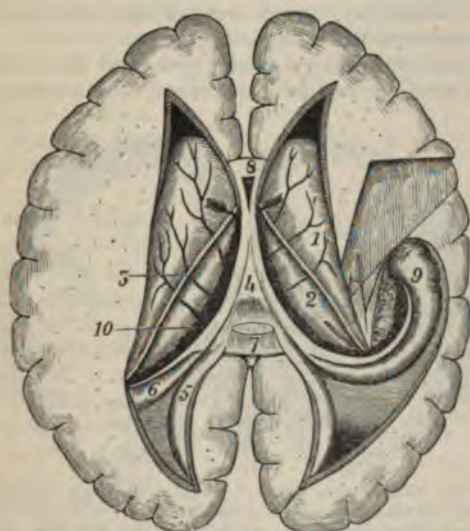


FIG. 276.—VIEW OF THE LATERAL VENTRICLES FROM ABOVE AFTER THE REMOVAL OF THE CORPUS CALLOSUM.

1. Corpus striatum. 2. Optic thalamus. 3. Tænia semicircularis. 4. Fornix. 5. Hippocampus minor. 6. Hippocampus major, with the eminentia collateralis behind it. 7. The corpus callosum (cut through). 8. Fifth ventricle. 9. Pes Hippocampi. 10. Choroid plexus.

The *middle* or *descending horn* runs into the temporo-sphenoidal lobe, descends towards the base of the brain, making a curve, at first backwards and outwards, then downwards and forwards, and lastly inwards; the initial letters of which make the memorial word

* The posterior horns are not always equally developed in both hemispheres, and sometimes they are absent in one or both.

In the carnivora, ruminantia, solipeda, pachydermata, and rodentia, the lateral ventricles are prolonged into the largely developed olfactory lobes. This is the case in the human fetus only at an early period.

"*body*." Its roof is formed by the fibres of the corpus callosum, partly by the posterior narrow extremity of the corpus striatum, with the tænia semicircularis, and the rounded extremity of the optic thalamus. On its floor are the *hippocampus major*, a large rounded white eminence which follows the curve of the cornu; the *pes hippocampi*, the expanded paw-like extremity of the former; the *eminentia collateralis* on the outer side of the hippocampus major, and part of which is seen in the posterior horn; the *corpus fimbriatum* of the fornix, attached to the anterior concave border of the hippocampus major; the *fascia dentata*, a crimped edge of grey matter under the corpus fimbriatum; the *choroid plexus*, and the outer part of the *transverse fissure*.

The various structures seen in the body and horns of the lateral ventricle will be described later on, when they are fully exposed.

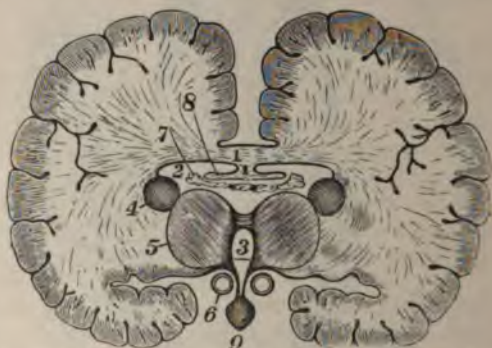

FIG. 277.—TRANSVERSE VERTICAL SECTION THROUGH THE BRAIN.

1. Corpus callosum. 2. Lateral ventricle. 3. Third ventricle. 4. Corpus striatum. 5. Thalamus opticus. 6. Corpus mamillare. 7. Choroid plexus. 8. Fornix. 9. Pituitary gland.

Appearance on Perpendicular Section. If a vertical transverse section is made across the middle of the brain, the lateral ventricles would appear as represented in Fig. 277. Observe that the roof and the floor are almost in actual contact, unless separated by ventricular fluid. Together with the third or middle ventricle, their shape slightly resembles the letter T. Such a section shows well the radiating fibres of the corpus callosum, the fornix, and the velum interpositum beneath it; also the beginning of the transverse fissure at the base of the brain, between the crus cerebri and the temporo-sphenoidal lobe.

If the corpus callosum be slightly raised, a thin vertical median septum, *septem lucidum*, will be seen, extending from the under aspect of this body to the upper surface of the fornix.

Septum Lucidum.

This is a thin and almost translucent partition which descends vertically in the middle line from the under surface of the corpus callosum, and separates the anterior part of the lateral ventricles from each other. It is attached above to the corpus callosum, below to the reflected part of the corpus callosum and fornix (Fig. 275). It is not of equal depth throughout. Its broadest part is in front and corresponds with the knee of the corpus callosum. It becomes narrower behind, tapering to a thin point, where the corpus callosum and the fornix become continuous. The septum consists of two layers, which enclose a space called the *fifth ventricle* or the *ventricle of the septum* (Fig. 276). Each layer consists of grey matter inside and of white matter outside; the former representing the cortical, the latter the medullary substance of the brain. The cavity is not lined with epithelium, as is the case with those ventricles developed from the cerebral vesicles.*

Cut transversely through the corpus callosum about its middle, with the septum lucidum, and turn forwards the anterior half. In this way the ventricle of the septum will be exposed. By turning back the posterior half of the corpus callosum a view is obtained of the fornix. This proceeding requires care, or the fornix will be reflected also, since these two arches of nerve-substance are here so closely connected.

Fornix.

The *fornix* is a layer of white matter, extending in the form of an arch (whence its name) from before backwards, beneath the corpus callosum. It is the great longitudinal white commissure, and lies over the velum interpositum (Fig. 278). Viewed from above, it is triangular with the base backwards, and is called the *body*; from its anterior narrow

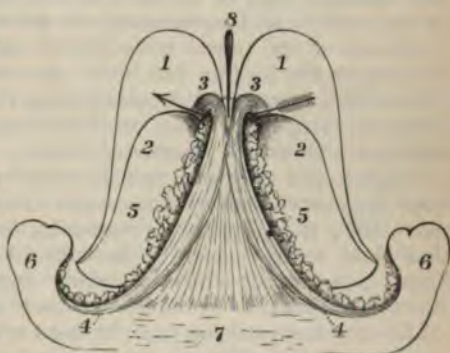


FIG. 278.—DIAGRAM OF THE FORNIX.

(The arrow is passed through the foramen of Monro.)

1, 1. Corpora striata. 2, 2. Thalami optici. 3, 3. Anterior crura of fornix bending down to join the corpora mamillaria. 4, 4. Posterior crura of the fornix joining the hippocampi. 5, 5. Choroid plexus. 6, 6. Hippocampi majores. 7. Corpus callosum cut through. 8. Ventricle of septum lucidum.

* The development of the septum lucidum commences about the fifth month of fetal life, and proceeds from before backwards, *pari passu* with the corpus callosum and the fornix. It is developed from the lower part of the great longitudinal fissure, but becomes shut off from it in the process of development.

part are given off the *two anterior crura*, and from its posterior and outer part the *two posterior crura*.

The *body* is the broad triangular part with the narrow portion in front. The posterior broad part is connected with the corpus callosum; in front of this it arches downwards, so as to leave the corpus callosum, to which, however, it is still connected by the septum lucidum. Its lateral free edges rest on the choroid plexuses, and are seen on the floor of the lateral ventricles.

The *anterior pillars* or *crura* proceed from the front narrow part of the body, one on each side of the mèsial line. As they pass forwards the crura diverge slightly, and descend through a mass of grey matter in the sides of the third ventricle towards the base of the brain, where, making a sudden bend upon themselves, they form the corpora mammillaria, from which they may be traced backwards and upwards, each to the anterior nucleus of the optic thalamus of its own side. As they descend, the anterior crura are joined by the peduncles of the pineal body, by the tænia semicircularis, and by fibres from the septum lucidum. Immediately behind and below the anterior crura is a triangular passage, through which the choroid plexuses of opposite sides are continuous with each other. This aperture is called the *foramen of Monro*. Strictly speaking, it is not a foramen, but only an interval caused by the anterior crus arching over the groove between the corpus striatum and optic thalamus on each side; it establishes a communication between the two lateral and third ventricles, and is in shape like the letter Y, the passage from each lateral ventricle passing downwards and inwards, and meeting below, to be continued as a single passage for a short distance before opening into the third ventricle.

The *posterior pillars* or *crura* are continued downwards and outwards from the thickened free borders of the body of the fornix, and are at first connected to the under surface of the corpus callosum. Each leaves the body at the posterior and outer angle as a thin flat white band resting on the choroid plexus and the pulvinar of the optic thalamus, and curving downwards and outwards, becomes intimately connected with the concave border of the hippocampus major as far down as the pes hippocampi, gradually tapering to a point at its termination. The free border of the posterior crus is known as the *tænia hippocampi* or the *corpus fimbriatum*; and on raising this up we expose an indented layer of grey matter, the *fascia dentata*, which is the free border of the cortical substance of the cerebrum.*

* The fornix and septum lucidum are absent in fish; they are merely rudimentary in reptiles and birds; but all mammalia have them in greater or less perfection, according to the degree of development of the cerebral hemispheres.

The fornix should now be cut through transversely, and its two portions reflected backwards and forwards respectively. On the under surface of the posterior portion are seen fibres, passing transversely, belonging to the corpus callosum, and forming what is termed the *lyra*.

Between the fornix and the upper surface of the cerebellum is the *transverse fissure*, or *fissure of Bichat*, through which the pia mater enters the ventricles. The fissure extends from the middle downwards on each side to the base of the brain, as far as the end of the descending horn. It is of a horse-shoe shape, with the concavity directed forwards. The upper boundary of that part of the transverse fissure which extends into the middle horn is sometimes called the *free margin of the hemisphere*.

The contents of the lateral ventricles should now be examined more in detail.

Corpus Striatum.

The *corpus striatum* is so called because, when cut into, it presents alternate layers of a white and grey substance. It is a large ovoid mass of grey substance, part of which forms an eminence in the body of the lateral ventricle (the intraventricular portion); but the larger part (extraventricular portion) is embedded in the white substance of the cerebrum. The *intraventricular portion*, called the *nucleus caudatus*, is pear-shaped, broad in front, and when traced backwards is found to taper gradually to a point on the outside of the optic thalamus (Fig. 279). Its surface is of a pinkish-grey colour, and is crossed by numerous small veins (*venæ corporis striati*) which open into the *venæ Galeni*. When a horizontal cut is made into it, it shows a thin layer of white substance covering a mass of grey streaked with white. The *extraventricular portion*, or *nucleus lenticularis*, can only be seen on a horizontal section being made outwards; the section reveals a biconvex mass of grey matter, separated from the nucleus caudatus by a broad band of white substance, the *internal capsule*, and corresponds with the island of Reil. Running parallel with the outer border of the nucleus lenticularis, but separated from it by a thin layer of white substance, the *external capsule*, is a wavy streak of grey matter, the *claustrum*, of variable thickness. Outside the claustrum is another layer of white matter, and then we see the indented convolutions of the island of Reil. If a vertical transverse section be made through the nucleus lenticularis, it appears triangular and intersected by two white lines, which divide it into three parallel grey bands. Beneath the lenticular nucleus is a mass of gray matter, called the *nucleus amygdalæ*, which causes an elevation at the apex of the roof of the middle horn.

Tænia Semicircularis.

The *tænia semicircularis*, or *stria terminalis*, is a narrow semi-transparent band of longitudinal white fibres, which lies in the groove

between the corpus striatum and the optic thalamus (Fig. 279, 3). In front, it is connected with the anterior crus of the fornix, and descends with it to the corpus mammillare; it passes backwards and outwards, and behind it is lost in the white substance of the middle horn of the lateral ventricle. Several veins from the corpus striatum pass underneath the tænia semicircularis to join the venæ Galeni. The upper surface of the tænia is firmer in structure than its deeper part, and is called the *horny band* of Tarinus.

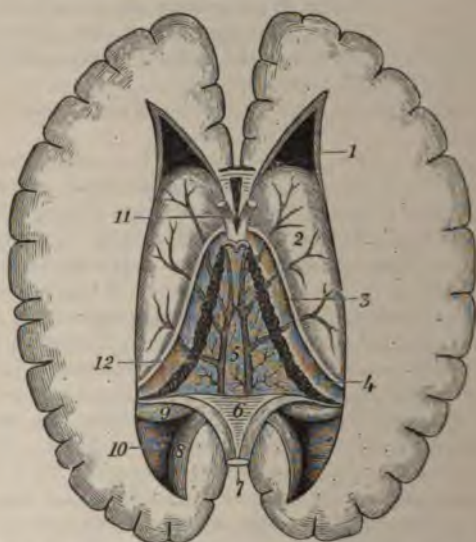


FIG. 279.—VIEW OF THE LATERAL VENTRICLES AND THE VELUM INTERPOSITUM AFTER REFLECTING THE FORNIX.

1. Anterior horn. 2. Corpus striatum. 3. Tænia semicircularis. 4. Optic thalamus. 5. Velum interpositum, with the venæ Galeni. 6. Lyra. 7. The posterior half of the fornix turned backwards. 8. Hippocampus minor. 9. Hippocampus major. 10. Eminentia collateralis. 11. Fifth ventricle. 12. Choroid plexus.

Hippocampus Major. The *hippocampus major* is an elongated convex eminence of grey matter, covered with white, and is situated in the posterior part of the descending horn. It extends to the bottom of the horn, following its curve, where it becomes somewhat expanded and indented on the surface, so as to resemble the paw of an animal, whence its name, *pes hippocampi*. Attached to the front concave border of the hippocampus is the posterior crus of the fornix. It corresponds to the hippocampal fissure, which itself is filled with grey matter, which forms the fascia dentata.

Hippocampus Minor. The *hippocampus minor*, called also *calcar avis* and *ergot*, is a rounded eminence, smaller than the preceding, occupying the inner curved wall of the posterior horn. It consists of white matter externally, and corresponds to the calcarine fissure. Between the hippocampus major and minor is a triangular smooth surface, called the *pes accessorius*, or *eminentia collateralis*, and is found in the posterior and the descending horn. This corresponds to the collateral fissure.

Velum Interpositum and Choroid Plexus. The *velum interpositum*, which supports the fornix, should now be examined. This is a layer of pia mater which penetrates into the ventricles through the transverse fissure, beneath the posterior border of the corpus callosum, as shown in Fig. 279. The shape of this vascular membrane is like that of the fornix, and its borders project beneath that body and form the red convoluted fringes called the *choroid plexuses*. These plexuses consist almost entirely of tortuous ramifications of minute blood-vessels, and are covered with vascular villi. The villi themselves are covered with large spheroidal epithelial cells. In front the plexuses communicate with each other through the foramen of Monro; behind, they descend into the middle horns of the lateral ventricles, and become continuous with the pia mater at the base of the brain. From the under surface of the velum two small vascular processes are prolonged into the third ventricle, forming the *choroid plexuses* of that cavity.

Venæ Galeni. Along the centre of the velum run two large veins, called *venæ Galeni*, which return the blood from the ventricles into the straight sinus.

The velum interpositum, with the choroid plexuses, must now be removed to expose the following structures shown in Fig. 281 (p. 698):—1. A full view of the *optic thalamus*. 2. Between the optic thalami is the *third ventricle*, a deep vertical fissure, situated in the middle line. 3. Behind the fissure is the *pineal body*, a vascular structure, about the size of a pea. From this body may be traced forwards two slender white cords, called its *peduncles*, or *striae pineales*—one along the inner side of each optic thalamus. 4. Passing transversely across the third ventricle are *three commissures*—anterior, middle, and posterior, connecting the opposite sides of the brain. 5. Immediately behind the pineal body are four elevations, two on each side, called the *corpora quadrigemina*, or *nates* and *testes*. 6. These bodies are connected with the cerebellum by two bands, one on each side, termed the *processus a cerebello ad cerebrum* or *ad testes*. 7. Between these cords extends a thin layer of grey substance, called the *valve of Vieussens*, beneath which lies the fourth ventricle.

Thalamus Opticus. This, called also the *posterior cerebral ganglion*, is the convex oval elevation seen immediately behind the corpus striatum and tænia semicircularis. Superficially it is covered with a thin layer of white, but internally it is composed of grey substance. The under surface rests upon the tegmentum of the crus cerebri, and forms part of the roof of the middle horn of the lateral ventricle; externally it is bounded by a broad band of white substance derived from the crista, which forms the internal capsule, already described. Externally, the optic thalamus is bounded by the tænia semicircularis; superficially, it is covered by the choroid plexus and the fornix; internally, it forms the lateral boundary of the third ventricle, and has, running along it, the peduncle of the pineal body; posteriorly, it overlaps the sides of the corpora quadrigemina, and forms a prominence in the roof of the middle horn, where it receives the crus cerebri. The upper surface of the thalamus is divided into two portions by an oblique shallow groove, passing from before backwards; the anterior and outer portion forms a prominent convex surface, called the *anterior tubercle*, which is covered with the epithelium of the lateral ventricle; the posterior and inner portion is pointed in front, and posteriorly enlarges to form a prominent rounded eminence, the *posterior tubercle* or *pulvinar*, and is not lined with epithelium.* Beneath the posterior part of the thalamus are two small oval eminences, termed the *corpora geniculata, internum* and *externum*. These consist of small accumulations of grey matter, beneath the white; the outer one being situated external to and above the internal, and to the outer side of one of the roots of the optic tract (Fig. 271, p. 681). From each of these bodies proceeds a white band to join the root just referred to, and from the junction of these three roots (*brachia*) the optic tract has its commencement. A narrow band of white substance connects the external one with the nates, and a similar band connects the internal one with the testes.†

Third Ventricle. The *third ventricle* is the long narrow fissure between the optic thalami, and reaches down to the base of the brain. Its *roof* is formed by the fornix and the velum interpositum, the under aspect of which is lined by the epithelium covering the general ventricular cavities, and is reflected from the velum and choroid plexuses on to the optic thalami; the *floor*, which increases in depth in front, is formed by certain parts at the base of the brain, found within the interpeduncular space,

* There is a triangular depression between the pulvinar and the peduncle of the pineal body, which has received the name of the *trigonum habenulæ*.

† These bands are faintly marked in man, but are more apparent in the lower animals.

iz., the locus perforatus posticus, corpora mammillaria, tuber cinereum, infundibulum, and lamina cinerea, all of which are best seen in a vertical section (Fig. 280). In *front*, it is bounded by the anterior crura of the fornix and the anterior commissure; *laterally*, by the optic thalami and the peduncles of the pineal body; *behind*, by the posterior commissure and the *iter a tertio ad quartum ventriculum*, which is a long canal beneath the corpora quadrigemina, connecting the third with the fourth ventricle.

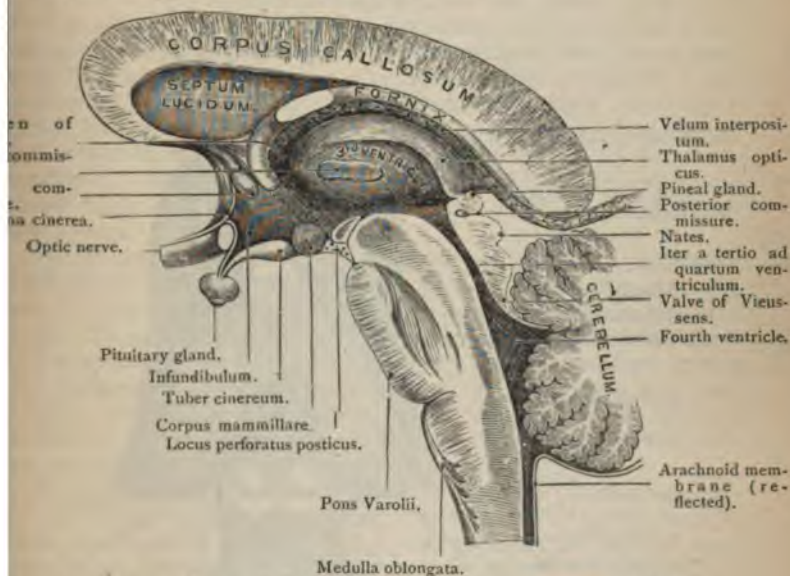


FIG. 280.—VERTICAL SECTION THROUGH THE CORPUS CALLOSUM, AND PARTS BELOW.

Passing across the third ventricle are seen three commissures, the anterior, middle, and posterior. The *middle commissure* may be seen by gently separating the optic thalami, and is about half an inch (13 mm.) in breadth. This is composed entirely of grey substance, and, in most brains, owing to its softness, generally torn before it can be examined.* The *anterior com-*

* The soft commissure does not appear to be a very essential constituent part of the brain. It is not found before the ninth month of foetal life, and in some instances, according to our observations, is never developed. Wenzel states that it is absent in about one out of seven subjects (*De penitiori Struct. Cerebri Hom. et Ruf. Tübingen, 1812.*)

Anterior. *missure* is a round white cord, which lies immediately in front of the anterior crura of the fornix, and connects the corpora striata. This commissure may be traced on each side through the corpora striata, below the nuclei lenticulares, extending backwards far into the temporo-sphenoidal lobes. Situated immediately in front of, and rather below the pineal body,

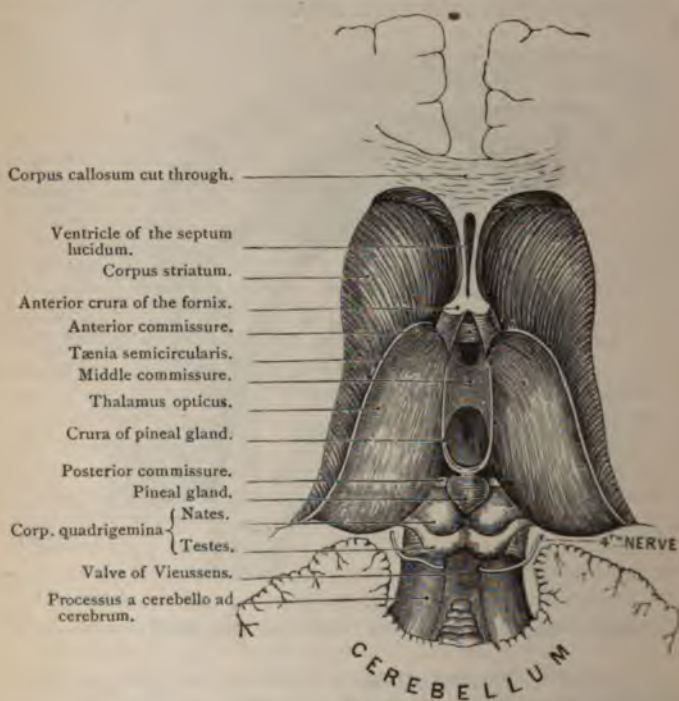


FIG. 281.

Posterior. is another thin round white cord called the *posterior commissure*. Its fibres pass into the substance of the hemispheres and connect the optic thalami. Its fibres are derived from the fillet which comes from the tegmentum of the crus cerebri.

The third ventricle communicates with the lateral ventricles by the two openings of the foramina of Monro, with the fourth ventricle through the iter a tertio ad quartum ventriculum, and in

front of its floor by a conical cavity, *iter ad infundibulum*, with the infundibulum.

The third ventricle is covered with an epithelial lining continuous with that of the lateral ventricles through the foramina of Monro; after covering the walls of the third ventricle it lines the aqueduct of Sylvius to pass to the fourth ventricle.

Pineal Body or Gland.

The *pineal body* (conarium) is a very vascular oval body, situated immediately in front of the corpora quadrigemina (Fig. 281). It is about the size of a cherry-stone, and is firmly connected with the under surface of the velum, and is apt to be separated from its normal position when that membrane is reflected. It is connected to the cerebrum by two white crura, the *peduncles of the pineal body*, which extend forwards, one on the inner side of each optic thalamus along their upper margin, and terminate by joining the anterior crura of the fornix. The peduncles join together behind in front of the pineal body, and are connected with the front of the posterior commissure.

The pineal body consists of numerous small follicles filled with cells, which are separated by connective tissue, so that in structure it much resembles that of the anterior lobe of the pituitary body. In its interior it contains, besides some viscid fluid, more or less gritty particles (*acervulus cerebri*), consisting of phosphate and carbonate of lime, and phosphate of magnesia and ammonia. Besides the calcareous particles, these follicles contain corpora amylacea; and, when abundant, this sabulous matter is found on the peduncles of the pineal body.

The pineal body is larger in the female than in the male subject, and is largest of all in the child. It is found in all mammalia, birds, and reptiles, in the same typical position, but its functions are entirely unknown.

Corpora Quadrigemina.

The *corpora quadrigemina* are four round eminences, situated two on each side, behind the pineal body, and are separated from each other by a crucial depression. Though white on their surface, they contain grey matter in their interior for the purpose of giving origin to the optic tract. Laterally, they are continued outwards as two convex white cords, the *anterior* and *posterior brachia*. The anterior brachium passes between the corpora geniculata, and is continued on into the optic tract, of which it may be considered its direct root; the posterior brachium passes forwards and outwards, and is lost beneath the corpus geniculatum internum. They are situated above the *iter a tertio ad quartum ventriculum*. The anterior pair are called the *nates*, and are larger and darker than

the posterior pair, which take the name of *testes*. A more appropriate term for these bodies would be the optic lobes.*

The corpora quadrigemina are developed very early in foetal life, and are at first only two in number, one on each side of the mesial line; but about the seventh month a transverse groove is apparent, thus mapping out the four bodies.†

Processus a Cerebello ad Cerebrum. By gently drawing back the overlapping cerebellum, two broad white cords are seen, which pass backwards, diverging from each other, from the optic thalami and the corpora quadrigemina to the cerebellum (Fig. 281). These are the *processus a cerebello ad cerebrum*, or *superior peduncles of the cerebellum*. They connect the cerebrum and cerebellum, and rest upon the *crura cerebri*. Below they pass to the inferior vermiform process, and to the white matter within the corpus dentatum.

Valve of Vieussens. The triangular space between the superior peduncles is occupied by a thin layer of grey matter, which covers over the anterior part of the fourth ventricle. This layer is called the *valve of Vieussens*, or the *anterior or superior medullary velum*; it is narrow in front and broad posteriorly, where it is connected with the central portion of the cerebellum. Along the mesial line of its upper surface there is an irregular ridge, the *frænulum*, which becomes lost towards its lower part; the lower part is overlapped by a corrugated lobule of grey matter from the anterior part of the cerebellum, and is called the *linguetta laminosa*.

Iter a Tertio ad Quartum Ventriculum, or Aqueduct of Sylvius. The third ventricle is connected with the fourth by a canal (Fig. 280) large enough to admit a probe, which runs downwards and backwards beneath the posterior commissure and the corpora quadrigemina. It is about half an inch (13 mm.) in length, and its shape varies in different

* Eminences homologous to the corpora quadrigemina are found in all vertebrate animals; they are the mesocephalic lobes; they always give origin to the optic nerves, and their size bears a direct relation to the power of sight. They are relatively smaller in man than in any other animal. In birds there are only two eminences, and these are very large, especially in those far-seeing birds which fly high, as the eagle, falcon, vulture, etc., who acquire acute sight to discern their prey at a distance.

† On making a transverse vertical section through the nates, we find that there is a superficial thin layer of white fibres (*stratum zonale*); beneath this is a crescentic layer of grey matter (*stratum cinereum*); deeper than this is a thick biconvex mass of grey matter, with nerve filaments and nerve cells (*stratum opticum*); and lowest of all is an arched layer of white nerve fibres derived from the fillet (*stratum lemnisci*).

parts of its course; in the lower being T-shaped, and in the upper part shield-shaped, on transverse section. In its walls is a large amount of grey matter, in which are the nuclei of origin of the third, fourth, and upper part of the fifth cranial nerves. It is lined with ciliated columnar epithelium. This passage, together with the third and fourth ventricles, are persistent parts of the central canal, which in early fœtal life extended down the middle of the cerebro-spinal axis. It subsequently becomes much encroached upon by the large increase of grey substance in the process of development.

Fourth Ventricle.

The fourth ventricle is the space situated between the cerebellum behind and the posterior surface of the medulla oblongata and pons Varolii in front. It is the dilated portion of the primordial canal alluded to in the last paragraph. If viewed in a vertical section, as represented in the diagram (Fig. 280), it appears triangular, with its base forwards; but if seen from behind, it is a lozenge-shaped space, the long axis being antero-posterior (Fig. 282).

The *upper wall* or *roof* of the fourth ventricle is formed by the valve of Vieussens, and by the front of the inferior vermiciform process, with the two amygdalæ; *laterally* it is bounded, in front by the processus a cerebello ad cerebrum, and behind by the diverging posterior pyramids and restiform bodies; *below*, by the continuation of the arachnoid membrane on to the posterior surface of the spinal cord, in which there is an aperture called the *foramen of Magendie*; *in front* its floor is formed by the medulla oblongata and pons Varolii. The pia mater is prolonged for a short distance into the lower part of the cavity, and forms the *choroid plexus* of the *fourth ventricle*.

The anterior wall is diamond-shaped, pointed above and below, while laterally the space broadens out into an angular point, between the cerebellum and the medulla, called the *lateral recess*. Below, the ventricle is bounded by the restiform bodies and posterior pyramids diverging like the branches of the letter V to form

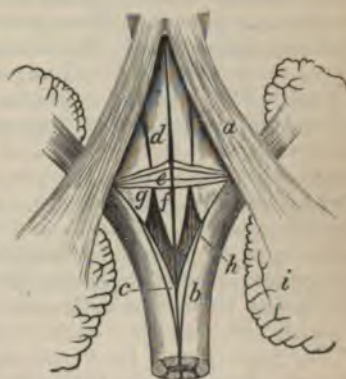

FIG. 282.—FLOOR OF THE FOURTH VENTRICLE.

a. Processus a cerebello ad cerebrum. b. Restiform bodies. c. Fasciculi graciles. d. Fasciculus teres, externally is the fovea superior. e. Medullary striæ. f. Fasciculus teres. g. Tuberculum acusticum. h. Fovea inferior. i. Cerebellum.

the *inferior peduncles* of the *cerebellum*; the divergence of these cords, with the median furrow, was called by the older anatomists the *calamus scriptorius*, from its fancied resemblance to a writing pen. At the termination of the posterior pyramid there is a slight overhanging thickening turning over the restiform body at the lateral recess, of which it forms the lateral boundary; it is called the *ligula* or *tania*. We find also a similar thickening, partly of the lining membrane and partly of nerve-matter, arching over the apex of the *calamus scriptorius*, known as the *obex*.

The *floor*, formed by the posterior surface of the medulla and pons, is marked by a median groove passing from the apex of the *calamus scriptorius* to the *iter*. It is divided into two portions, a lower and an upper, by some transverse white fibres called the *striæ acusticæ* or *medullares*, which emerge from the median groove and pass outwards over the inferior cerebellar peduncle to join part of the roots of the auditory nerves. The lower part of the floor, on each side, is mapped out into three surfaces by a triangular depression, *fovea inferior* (Fig. 282, *h*), having its apex at the transverse striæ, and its base below at the posterior pyramids. On the outer side of the fovea there is a convex triangular surface, with its base upwards (Fig. 282, *g*), called the *tuberculum acusticum*; on the inner side of the fovea and bounded internally by the median groove, is the rounded triangular surface which marks the commencement of the *fasciculus teres*. Towards the base of the inferior fovea there is a dark surface of grey matter called the *ala cinerea*, which becomes raised into an eminence (*eminentia cinerea*).

The upper part of the fourth ventricle is that portion between the acoustic striæ and the *iter a tertio ad quartum ventriculum*. The median groove is still continued upwards, although it becomes fainter, and on each side of it is the parallel rounded eminence, the *fasciculus teres*. Outside this *fasciculus* is a triangular depression, the *fovea superior*; and passing upwards under cover of the superior cerebellar peduncle, we notice a depression of grey substance, called the *locus ceruleus*.

The lower part of the fourth ventricle is developed from the metencephalic, the upper part from the ependecephalic portion of the posterior primary vesicle.*

Structure of the
Cerebrum.

The white substance of the cerebrum consists of medullated fibres, which are, as a rule, smaller than those in the spinal cord. The

* Tiedemann proposed to call the fourth ventricle the first, because in the *firmus* it is formed sooner than any of the others; because it exists in all vertebrated animals, whereas the lateral ventricles are absent in all osseous fishes; and because the ventricle of the *septum lucidum* is absent in all fishes, in reptiles, and in birds.

general arrangement of the fibres may be classified under three heads: 1. The diverging or peduncular fibres. 2. The transverse commissural fibres; and 3. The longitudinal fibres.

The *diverging* or *peduncular fibres* are derived partly from the crusta, and partly from the tegmentum of the crus cerebri. Those from the crusta pass forwards and outwards between the nucleus caudatus and nucleus lenticularis with the internal capsule; and in front of the ganglia the fibres radiate outwards in all directions, called the *corona radiata*. Most of these fibres pass indirectly to the cortical portion of the cerebrum; some proceed direct to the cortex, through the grey ganglionic structure, amongst which are the *pyramidal tract*, passing to the grey matter in the neighbourhood of the fissure of Rolando, and the *direct sensory tract* to the cortex of the occipital lobe. The fibres from the tegmentum are joined by others from the processus a cerebello ad cerebrum, and the corpora quadrigemina, and pass under the optic thalamus, and probably through this body, and radiate outwards, joining the corona radiata to proceed to the temporo-sphenoidal, post-parietal, and occipital lobes.

The *transverse commissural fibres* connect the two hemispheres, and are the corpus callosum, the anterior and posterior commissures.

The *longitudinal fibres* consist of the fornix, the striæ longitudinales of the corpus callosum, the tæniæ semicirculares, the gyrus fornicatus, the gyrus uncinatus, and the peduncles of the pineal body.

THE CEREBELLUM.

The *cerebellum* is that portion of the encephalon situated in the occipital fossa, beneath the posterior lobes of the cerebrum, from which it is separated by the tentorium. It measures in its transverse diameter from three and a half to four inches (8.8 to 10 cm.), in its antero-posterior diameter two to two and a half inches (5 to 6.3 cm.), and two inches (5 cm.) in its vertical diameter. Its form is ellipsoidal, with the long axis transverse. When the arachnoid membrane and the pia mater are removed, it is noticed that its surface is darker, and not arranged in tortuous convolutions like those of the cerebrum. It is covered externally with grey matter, and consists of a multitude of thin laminæ disposed in a series of nearly parallel concentric curves, with the concavity forwards. By a little dissection it is easy to separate some of the laminæ from each other, and to see that the intervening fissures increase in depth from the centre towards the circumference.

The cerebellum consists of two *lateral hemispheres* united by an intermediate portion, the *vermiform process*, the upper aspect of

which takes the name of the *superior vermiform process*, the inferior that of the *inferior vermiform process*. Comparative anatomy proves that this is the fundamental part of the cerebellum, the lateral masses not being developed in the vertebrate series until after the

birds. In man the lateral masses form by far the largest part of the cerebellum.

The two hemispheres on their under aspect are convex and separated from each other by a deep fossa, the *vallecula*; and, behind, this is continued so as to form a deep notch beneath the posterior borders of the cerebellum.

The upper surface is separated from the lower by a deep fissure named the *great horizontal*, which extends along the free border of each hemisphere.

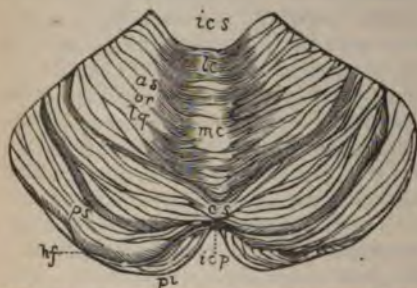


FIG. 283.—SUPERIOR SURFACE OF THE CEREBELLUM.
ics. Incisura cerebelli anterior. *icp*. Incisura cerebelli posterior. *as or lg*. The anterior superior or quadrate lobe. *ps*. The posterior superior lobe. *pi*. The posterior inferior lobe. *hf*. The great horizontal fissure. *lc*. The lobulus centralis. *mc*. Monticulus cerebelli. *cs*. Commissura simplex.

Upper Surface.

The *upper surface* of the cerebellum slopes on each side, having a ridge along the middle line, called the *superior vermiform process*. This process presents three eminences, an anterior, middle, and posterior, which are named respectively, the *lobulus centralis*, the *monticulus cerebelli*, and the *commissura simplex*. The hemispheres are separated posteriorly by a deep notch, the *incisura cerebelli posterior*, which receives the falx cerebelli; and anteriorly by a broader notch, the *incisura cerebelli anterior*, which lodges the pons Varolii. On this surface of the cerebellum are two lobes, one of which, the *quadrate*, is situated on its external and anterior aspect; the other, the *posterior* or *crescentic*, is placed along its posterior border.

Under Surface.

On the *under surface* of the cerebellum its division into two hemispheres is clearly perceptible. The deep furrow between them is called the *vallecula*. The front part of it is occupied by the medulla oblongata. To examine the surface of the valley, the medulla must be raised, and the hemispheres separated from each other. Along the middle line of the vallecula is the *inferior vermiform process*, which is the under surface of the original part of the cerebellum. Traced forwards, this process terminates in the *nodule*, which projects into the fourth ventricle, and is called the *laminated tubercle* of Malacarne; traced backward, it ends in a small conical projection, called the

pyramid; between these is a tongue-like body, called the *uvula*, which is connected with the adjacent amygdalæ by an indented grey ridge, named the *furrowed band*. Passing from the nodule to the flocculus is a thin valve-like fold of white matter, which together take the name of the *posterior or inferior medullary velum*. Its anterior crescentic margin is free, and its posterior is attached to the furrowed band.* To see this satisfactorily, the tonsils must be carefully separated from each other.

Each hemisphere presents on its under surface certain secondary lobes, to which different names have been applied (Fig. 284). That portion which immediately overlies the side of the vallecule

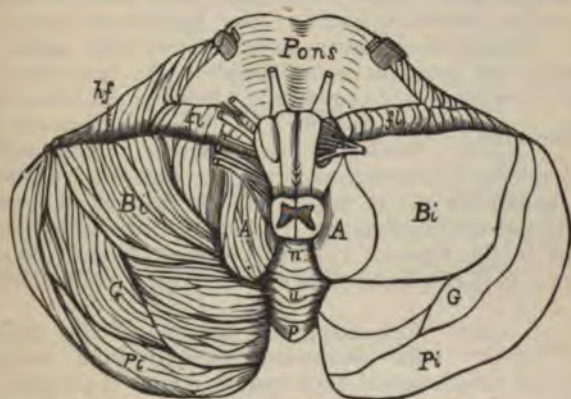


FIG. 284.—INFERIOR SURFACE OF THE CEREBELLUM.

A. The amygdala. Bi. The bivalent lobe. G. The slender lobe. Pi. The posterior inferior lobe. Hf. The great horizontal fissure. f. The flocculus. n. The nodule situated in the vallecule. u. The uvula situated in the vallecule. p. The pyramid situated in the vallecule.

is called the *tonsil (amygdala)*; this is connected with the uvula by an indented layer of grey matter, called the *furrowed band*. At the anterior part of each hemisphere, near the middle line, is a little lobe named the *flocculus or subpeduncular lobe*.

In addition to the amygdalæ and flocculi, already mentioned, other lobes have been described on the under surface of the cerebellum. Thus, there is the *digastric lobe*, situated external to the amygdala; and behind this are successively the *slender* and the *posterior inferior lobes* (Fig. 284).

Peduncles of the
Cerebellum.

The cerebellum is connected with the cerebro-spinal axis by the three *peduncles or crura*—a superior, middle, and inferior. With the medulla oblongata it is connected by means of the restiform tracts;

* These are sometimes called the *valves of Tarini*.

these are called the *processus a cerebello ad medullam*, or its *inferior peduncles*; with the cerebrum it is connected by means of the *processus e cerebello ad cerebrum* or *ad testes*; these are called its *superior peduncles*. The lateral portions of the pons constitute its *middle peduncles*.

Internal Structure. To examine the internal structure of the cerebellum, a longitudinal section must be made through the thickest part of one of its hemispheres. There is then seen in the centre a large nucleus of white substance, from which branches radiate into the grey substance in all directions, and upon which the grey cortical substance is deposited (*laminæ*).

The *laminæ*, about twelve in number, have branches from them at right angles, secondary *laminæ*; and, from these again, tertiary *laminæ*. This racemose arrangement of the white matter in the substance of the grey has been likened to the branches of a tree deprived of its leaves and is generally known as the *arbor vitæ*.

Corpus Dentatum. In the centre of the white substance of each hemisphere is a nucleus of grey matter, the *corpus dentatum*, consisting of a zigzag line of yellowish-grey colour, incomplete at its upper and inner part, and enclosing within it some white substance. From its centre white fibres may be traced to the superior cerebellar peduncles and the valve of Vieussens. It is displayed either by a vertical or by a horizontal section.

Functions. Respecting the function of the cerebellum, the deductions derived from comparative anatomy and physiological experiments render it probable that it is the co-ordinator of muscular movements—*e. g.*, in walking, flying, and swimming.

The encephalon is originally developed from three primary vesicles, from which the following parts are, in the later stages, severally developed:—

1. Anterior vesicle,	{	Prosencephalon,	{	Cerebral hemispheres, corpora striata, corpus callosum, fornix, lateral ventricles, olfactory lobe.
		Thalamencephalon,		{
2. Middle vesicle,	{	Mesencephalon,	{	Corpora quadrigemina, crura cerebri, aqueduct of Sylvius, optic nerve.
3. Posterior vesicle,	{	Epencephalon,	{	Cerebellum, pons Varolii, front part of the fourth ventricle.
		Metencephalon,		{

The component parts of the encephalon begin to be developed at different periods of foetal life, and the ages at which they generally begin to appear are given as follows:—

POSTERIOR VESICLE.

	<i>Part.</i>	<i>Month.</i>
<i>metencephalon,</i>	Medulla oblongata,	Third
	Restiform bodies,	Third to fourth
	Anterior pyramids,	Fifth
	Olivary bodies,	Sixth
	Striæ acusticæ,	After birth
<i>encephalon,</i>	Cerebellum,	Second, end of
	Inf. cerebellar ped.,	Third
	Middle " "	Fourth
	Corpus dentatum,	Fourth
	Superior cereb. ped.,	Fifth
	Valve of Vieussens,	Fifth
	Lobes of cerebellum,	Fifth
	Folia,	Sixth
	Flocculus,	Seventh
	Post. medullary velum,	Seventh
Amygdalæ,	Eighth	

MIDDLE VESICLE.

<i>metencephalon,</i>	Corpora quadrigemina,	Fourth
	Fillet,	Fourth
	Corpora quadrig.: Vertical groove,	Sixth
	Transverse,	Seventh

ANTERIOR VESICLE.

<i>metalamencephalon,</i>	Optic thalami,	Second to third	
	Anterior commissure,	Third	
	Posterior commissure,	Third, end of	
	Pineal body,	Third to fourth	
	Optic tracts,	Third to fourth	
	Peduncles of pineal body,	Third to fourth	
	Middle commissure,	Ninth?	
	<i>metencephalon,</i>	Island of Reil,	Earliest of all
		Corpora striata,	Third
		Corpus callosum,	Third, end of
Fornix,		Fourth to fifth	
Sulci, primitive:			
Fissure of Sylvius,		Middle of third	
Parieto-occipital,		Third	
Dentate,		Third	
Calcarine,		Third	
Sulci, secondary:			
Rolando,	Fifth to sixth		
Parallel,	Fifth		
Interparietal,	Sixth, end of		
Calloso-marginal,	Sixth, end of		

	<i>Part.</i>	<i>Month.</i>
<i>Proencephalon,</i> (cont.)	Sulci, secondary :	
	Collateral,	Sixth, end of
	Frontal,	Seventh
	Hippocampus major,	Fourth to fifth
	Convolutions,	Fourth to fifth
	Convolutions develop rapidly,	Seventh to eighth
Septum lucidum,	Fifth	

The cerebral hemispheres enlarge at first slowly, but later they develop much more rapidly; the extent to which they reach backwards in the various periods of intra-uterine life is as follows :—

- To the optic thalami at third month,
- To the corpora quadrigemina at fourth month,
- To the greater part of cerebellum at sixth month,
- To the posterior border of cerebellum at seventh month.

DISSECTION OF THE SPINAL CORD.

To examine, in situ, the spinal cord covered with its membranes, the arches of the vertebræ must be sawn through and removed.* It is then noticed that the cord does not occupy the whole cavity of the spinal canal. The dura mater does not adhere to the vertebræ, and does not form their internal periosteum, as in the skull. Between the bones and this membrane a space intervenes, which is filled with a soft reddish-looking fat, with watery cellular tissue, and the ramifications of a plexus of veins.

Spinal System of Veins. The spine is remarkable for the number of large and tortuous veins which ramify about it inside and outside the vertebral canal (Fig. 285). They are :—

1. The *dorsi-spinal* or *posterior external veins*, which form a tortuous plexus outside the spinous, transverse, and articular processes, and the arches of the vertebræ; they communicate with corresponding veins above and below, and they send off branches, which pass through the ligamenta subflava and intervertebral foramina, and end in the plexus inside the vertebral canal. They join the vertebral veins in the cervical region, the intercostal in the dorsal, and the lumbar and sacral veins below.

2. The *veins of the bodies of the vertebræ* (*venæ basis vertebrarum*) emerge from the backs of the bodies, and empty themselves into the transverse vein connecting the two anterior longitudinal spinal veins.

3. The *anterior longitudinal spinal veins*, two in number, one on each side, are very large tortuous veins, which extend along the whole length of the spinal canal. They communicate by transverse

* A curved saw will work better than a straight one. (A. H.)

branches, passing beneath the posterior common ligament, opposite the body of each vertebra, where they receive the *venæ basis vertebrarum*. They are larger in the dorsal and lumbar regions, and communicate externally with the vertebral, the intercostal, the lumbar, and the sacral veins.

4. The *posterior longitudinal spinal veins*, like the anterior, run along the whole length of the spinal canal. They form a tortuous venous plexus, situated inside the vertebral arches, and communicate in front with the anterior longitudinal veins by cross branches at frequent intervals, and externally with the vertebral, intercostal, lumbar, and sacral veins by branches through the intervertebral foramina.

The anterior and posterior longitudinal spinal veins are situated



FIG. 285.—DIAGRAM OF THE SPINAL VEINS. (VERTICAL SECTION.)

1. Anterior external veins. 2. Dorsi-spinal veins. 3. Posterior longitudinal spinal veins.
4. Anterior longitudinal spinal veins.

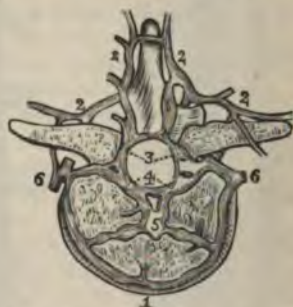

FIG. 286.—DIAGRAM OF THE SPINAL VEINS. (TRANSVERSE SECTION.)

1. Anterior external veins. 2. Dorsi-spinal veins. 3. Posterior longitudinal spinal veins.
4. Anterior longitudinal spinal veins. 5. Internal veins of the body of the vertebra. 6. Lateral veins.

between the spinal canal and the dura mater of the spinal cord, and are called the *meningo-rachidian veins*.

5. The *medullary-spinal* or *proper veins of the spinal cord* lie within the dura mater. They form a fine plexiform arrangement of veins over both surfaces of the cord, and can with difficulty be injected from the other spinal veins. This complicated system of veins discharges itself through the intervertebral foramina in the several regions of the spine, as follows:—In the cervical, into the vertebral veins; in the dorsal, into the intercostal veins; in the lumbar, into the lumbar veins. None are provided with valves, hence they are liable to become congested in diseases of the spine.

The membranes of the spinal cord, though the same in number and continuous with those of the brain, differ from them in certain respects, and require separate notice.

Dura Mater.

The *dura mater* of the cord is a tough fibrous membrane, like that of the brain, but does not adhere to the bones, being separated from them by fat, loose areolar tissue, and the plexus of veins described above. Moreover,

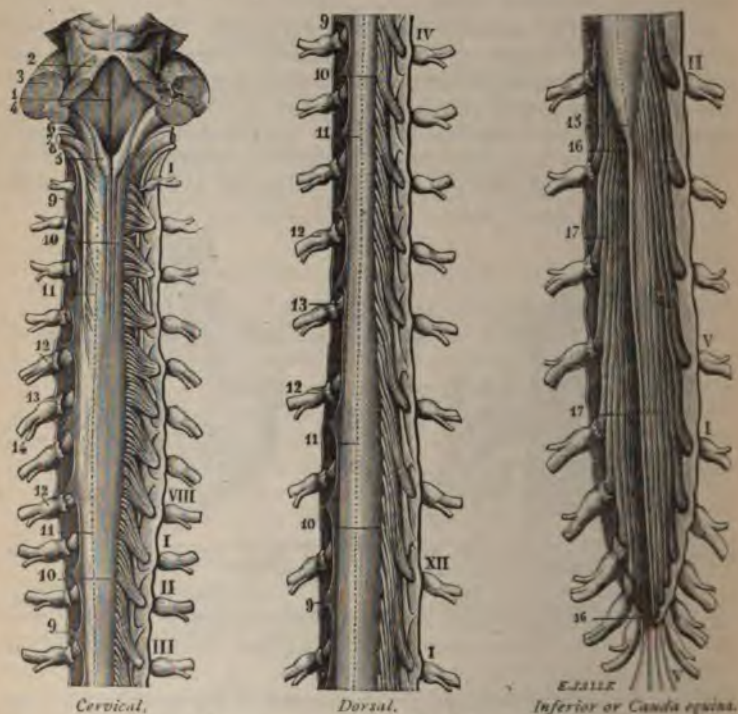


FIG. 287.—MEMBRANES OF THE CORD AND NERVES GIVEN OFF.

1. Floor of the fourth ventricle. 2. Processus a cerebello ad cerebrum ad testes. 3. Process to the pons. 4. Process to the medulla. 5. Mammillated swelling of the posterior column. 6. Glosso-pharyngeal n. 7. Pneumogastric n. 8. Spinal portion of the spinal accessory exposed on the left side by the removal of the posterior roots of the spinal nerves. 9. Ligamentum denticulatum. 10, 10. Posterior roots of spinal nerves. 11, 11. Postero-lateral groove in which are placed these roots. 12, 12. Ganglion. 13. Anterior roots of the spinal nerves. 14. Divisions of the ganglion into two nerves. 15. Terminal extremity of the spinal cord. 16, 16. Coccygeal ligament or *filum terminale*. 17, 17. Cauda equina. The posterior cords have been removed on the left side. I, VIII. Cervical nerves. I, XII. Dorsal nerves. I, V. Lumbar nerves. I, V. Sacral nerves.

such adhesion would impede the free movements of the vertebrae upon each other. It is attached firmly above to the margin of the foramen magnum, and by slender tissue to the posterior common ligament, and may be traced downwards as a sheath as

far as the second bone of the sacrum, from which it is prolonged as a fibrous cord to the coccyx, where it becomes continuous with the periosteum. It forms a complete canal or bag (*theca*) which surrounds loosely the spinal cord, and is relatively larger in the cervical and lumbar regions than in the dorsal. On each side are two openings in the dura mater for the anterior and posterior roots of the spinal nerves, and the membrane is prolonged over the trunk of each spinal nerve. These prolongations accompany the nerves only as far as the intervertebral foramina, and are there blended with the periosteum. The inner surface of the dura mater is covered with a layer of polygonal cells, so that it is smooth and secerning; this was formerly described as the parietal layer of the arachnoid membrane.

Cut through the nerves which proceed from the spinal cord on each side, and remove the cord with the dura mater entire. Then lay it flat on the table and slit up the dura mater along the middle of the front of the cord to examine the arachnoid membrane.

It will be seen that the functions of the dura mater of the cord are not identical with those of encephalon, since it does not form an internal periosteum to the bones of the spinal canal, nor does it send in partitions to support the cord, and it does not split to form venous sinuses.

Arachnoid Membrane.

The *arachnoid membrane of the cord* is a continuation from that of the brain, and is reflected over the spinal nerves as they pass from the cord to the apertures in the dura mater. This membrane invests the cord and is in contact by its superficial aspect with the dura mater, there being an interval between them called the *sub-dural space*, although in some situations they are more or less connected by connective-tissue bands. On its deeper surface it is in contact with the pia mater, but is loosely connected with it by delicate areolar tissue, so that there is a considerable interval between them (*subarachnoid space*), which is occupied by a transparent watery fluid (*cerebro-spinal fluid*) contained in the meshes of the subarachnoid tissue. The separation between the arachnoid and the pia mater varies in different parts, and is greatest in the lowest part of the cord.

Cerebro-spinal Fluid.

This *cerebro-spinal fluid* cannot be demonstrated unless the cord be examined very soon after death, and before the removal of the brain.* The nerves proceeding from the cord are loosely surrounded

* The existence and situation of the cerebro-spinal fluid were first discovered by Haller, *Element. Phys.* vol. iv, p. 87, and subsequently more minutely investigated by Magendie, *Recherches Phys. et Cliniques sur le Liquide Cephalo-rachi-*

by a sheath of the arachnoid; but this only accompanies them as far as the dura mater, where the two are continuous.* The cerebro-spinal fluid of the cord communicates with that of the brain, and also with the general ventricular cavity through an aperture in the lower boundary of the fourth ventricle, called the *foramen of Magendie*.

Pia Mater.

The pia mater of the cord is the protecting membrane which immediately invests it. It is very different in structure from that of the brain, since it does not constitute a membrane in which the arteries break up, but serves rather to support and strengthen the cord; consequently, it is much less vascular, more fibrous in its structure, and more adherent to the substance of the cord. It sends down thin folds into the anterior and posterior median fissures of the cord, and is prolonged upon the spinal nerves, forming their investing membrane or "neurilemma."

Along the anterior median fissure may be traced a well-marked fibrous band, formed by the pia mater, which has been named the *linea splendens*.

Below the level of the second lumbar vertebra the pia mater is continued as a slender filament, called the *filum terminale*, or *central ligament*, which runs down in the middle of the bundle of nerves into which the spinal cord breaks up. About the level of the third sacral vertebra it becomes continuous with the dura mater of the cord, and is then prolonged as far as the base of the coccyx. The spine of the third sacral vertebra marks the level to which the

âien, in-4°, avec atlas: Paris, 1842. This physiologist has shown that if, during life the arches of the vertebræ are removed in a horse, dog, or other animal, and the dura mater of the cord punctured, there issue jets of a fluid which had previously made the sheath tense. The fluid communicates, through the fourth ventricle, with that in the general ventricular cavity. The collective amount of the fluid varies from 1 to 2 oz. (29.5 to 59 c.cm.) or more. It can be made to flow from the brain into the cord, or *vice versâ*. This is proved by experiments on animals, and by that pathological condition of the spine in children termed *spina bifida*. In the latter instance, coughing and crying make the tumor swell, showing that fluid is forced into it from the ventricles. Again, if pressure be made on the tumor with one hand and the fontanelles of the child examined with the other, in proportion as the spinal swelling decreases, so is the brain felt to swell up, accompanied by symptoms resulting from pressure on the nervous axis generally. See some remarks very much to the point by Sir George Burrows, *On Diseases of the Cerebral Circulation*, p. 50, 1846.

* It is well to note, in operations on the vertebral column for the relief of pressure upon the cord, after the dura has been opened and no fluid is seen, that adhesions exist above that point, owing to inflammatory deposits in the arachnoid, which are easily relieved by the introduction of a probe above and below the point of operation, when the fluid appears in the wound, the arachnoid then being free. (A. H.)

cerebro-spinal fluid descends in the vertebral canal. It is supplied with nerves from the sympathetic and from the posterior roots of the spinal nerves.

Ligamentum Denticulatum.

From each side of the cord along its whole length there runs a fibrous band, *ligamentum denticulatum*, which gives off a series of processes to steady and support the cord. They are triangular, their bases being attached to the cord, and their points to the inside of the dura mater (Fig. 288). There are from eighteen to twenty-two of them on each side, and they lie between the anterior and posterior roots of the spinal nerves. The first process passes between the vertebral artery and the hypoglossal nerve; the last is found at the termination of the cord. It is composed of fibrous tissue, and is covered with nucleated cells continuous with the arachnoid membrane.*

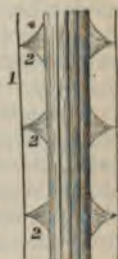


FIG. 288.—DIAGRAM OF THE LIGAMENTUM DENTICULATUM.

1. Dura mater. 2, 2, 2. Ligamentum denticulatum.

SPINAL CORD.

The *spinal cord* (*medulla spinalis*) is that part of the cerebro-spinal axis contained in the vertebral canal, and is enclosed within a sheath of dura mater (*theca vertebralis*), which is separated from the canal by a plexus of veins and connective tissue. It is the continuation of the medulla oblongata, and extends from the foramen magnum down to the lower border of the first lumbar vertebra, where it terminates in a conical point, *conus medullaris*, after having given off a large bundle of nerves, termed the *cauda equina*, for the supply of the lower limbs.

It is from fifteen to eighteen inches (37.5 to 40 cm.) in length, and is about an ounce and a half (43 gm.) in weight. Its lower extremity from the *conus medullaris* is continued downwards as a thin silvery cord, the *filum terminale*, which descends along the posterior aspect of the *cauda equina*. It passes down within the sheath as far as the second sacral vertebra, and then, piercing the dura mater, becomes attached to the periosteum of the canal at the back of the coccyx.† In its upper part, the *filum terminale* contains some grey nerve-substance. It is a prolongation of the pia

* Vide Axel Key and Retzius; Max Schultz's *Archives*, 1873.

† The explanation of this is, that, at an early period of foetal life the length of the cord corresponds with that of the vertebral canal; but after the third month the lumbar and sacral vertebrae grow away from the cord, in accordance with the more active development of the lower limbs. See Tiedemann, *Anatomie und Bildungsgeschichte des Gehirns im Fetus des Menschen*, &c.; Nürnberg, 1816.

mater of the cord, and in many subjects there is a continuation of the central canal of the cord in its upper half.

The cord is not of uniform dimensions throughout. It presents a considerable enlargement in the lower part of the cervical region (Fig. 287, p. 710); another in the lower part of the dorsal, from which proceed the large nerves to the upper and lower limbs, respectively. The upper or cervical enlargement, which is the larger, extends from the third cervical to the first dorsal vertebra, and is largest at the sixth cervical vertebra; the lower, or lumbar, extends from the twelfth dorsal vertebra and is largest opposite the last dorsal vertebra.*

The cord is divided into two symmetrical halves by a median longitudinal fissure in front and behind (Fig. 289). The *anterior fissure* is the more distinct and wider, and penetrates about one-third of the substance of the cord; deeper in the lower than in the upper part of the cord. It contains a fold of pia mater, with many

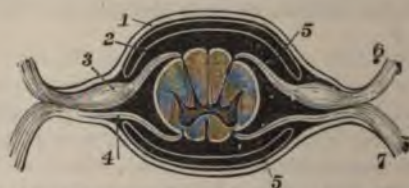

FIG. 289.—DIAGRAM OF A TRANSVERSE SECTION THROUGH THE SPINAL CORD AND ITS MEMBRANES.

1. Dura mater. 2. Arachnoid membrane. 3. Ganglion on posterior root of spinal nerve. 4. Anterior root of spinal nerve. 5, 5. Seat of sub-arachnoid fluid. 6. Posterior branch of spinal nerve. 7. Anterior branch of spinal nerve.

blood-vessels for the supply of its interior. At the bottom of this fissure is a transverse layer of white substance, named the anterior white commissure, connecting the two anterior halves of the cord. The *posterior fissure* is much less apparent than the anterior, and is better marked in the upper and the lower parts of the cord. It does not contain a fold of pia mater, but contains a thin septum of connective tissue with blood-vessels. It can be traced to a greater depth than the anterior, and reaches down as far as the *posterior grey commissure* of the cord.

Besides the anterior and posterior fissures is another superficial lateral groove, from which the posterior roots of the spinal nerves emerge; this is termed the *postero-lateral groove* (Fig. 289). This leads down to the posterior horn of the grey matter in the interior

* In very early foetal life these enlargements do not exist, and only make their appearance with the development of the extremities.

of the cord. There is sometimes described an *antero-lateral groove*, corresponding to the line whence the anterior roots of the spinal nerves emerge; but this is not really a groove, although it serves to map out each half of the cord into three longitudinal portions: a posterior, a lateral, and an anterior column. On each side of the posterior median fissure, in the cervical region, is a slender column, called the *posterior median column*, which is separated from the posterior column by a shallow furrow.* The anterior column is continuous with the anterior pyramid; the lateral column with the lateral tract of the medulla; the posterior column with the restiform body; and the posterior median column with the posterior pyramid.

Internal Structure. A transverse section through the cord (Fig. 289) shows that, externally, it is composed of white nerve-substance, and that its interior contains grey matter, arranged in the form of two crescents, with their backs to each other. Each crescent is placed in its corresponding half of the cord, and is connected with its fellow across the centre by a portion called the *posterior or grey commissure*. The *posterior horns* are long and narrow, and extend to the postero-lateral groove, where they are connected with the posterior roots of the spinal nerves. At their extremities they taper to a point, the *apex cornu posterioris*, and near their bases they present a constriction, the *cervix cornu*, beyond which they slightly enlarge to form the *caput cornu*. The outline of the grey matter of the posterior horns at their commencement is indefinite and frayed out, which is especially noticeable in the cervical region, and is called the *processus reticularis*; at their apices the grey matter is semitransparent in appearance, and hence is known as the *substantia gelatinosa*. In the centre of the concavity of the posterior horn is a rounded projection, most marked in the upper dorsal region, termed the *tractus intermedio-lateralis*, the continuation of which has been traced upwards through the medulla oblongata. The *anterior horns* are short and thick, and come forwards towards the attachment of the anterior roots of the nerves, but do not reach the surface. Separating the grey commissure from the anterior median fissure is the *anterior or white commissure*.

On making transverse sections through different regions of the spinal cord, the grey substance is seen to vary in shape and in amount (Fig. 290); in the cervical region, the anterior cornua are thick and short, the posterior are long and slender; in the dorsal, the anterior and posterior cornua are both thin; in the lumbar, the anterior and posterior cornua are large and broad; in the lower part of the cord the grey matter is arranged in a central mass.

* The posterior median column is said by Foville to be present along the whole length of the cord.

Running along the centre of the cord in its whole length is a minute canal, the *central canal*, just visible to the naked eye. Below, in the *conus medullaris*, it ends in a dilated cul-de-sac, of the shape of the letter T; above it opens out at the *calamus scriptorius* into the fourth ventricle. It is lined with cylindrical ciliated epithelium. This central canal is interesting, as it is the remains of the cavity formed by the spinal cord at the earliest period of its development.*

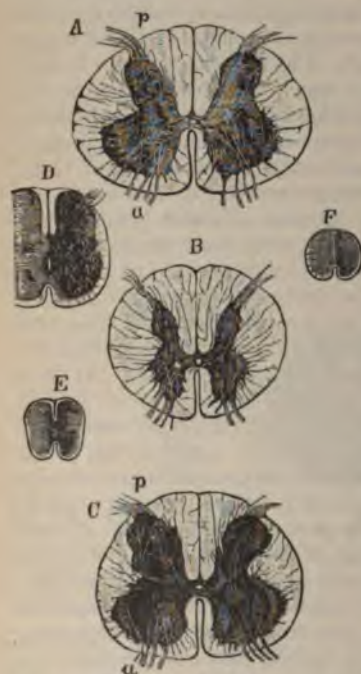


FIG. 290.—TRANSVERSE SECTIONS OF THE SPINAL CORD IN DIFFERENT REGIONS.

A. Through the middle of the cervical. B. The dorsal. C. The lumbar enlargement. D. Upper part of the *conus medullaris*. E. At the 3rd sacral vertebra. F. At coccyx. A, B, C. Enlarged twice. D, E, F. Thrice. a. anterior. p. Posterior root.

Spinal Nerves.

Thirty-one pairs of nerves arise from the spinal cord, namely, eight in the cervical region, twelve in the dorsal, five in the lumbar, five in the sacral, and one in the coccygeal. Each nerve is formed by the junction of two series of roots, one from the front, which is the *motor root*, the other from the back of the cord, which is the *sensory and larger root*. The two roots pierce the *dura mater* separately and then converge to the corresponding intervertebral foramen to form a single nerve, composed of motor and sensory filaments.

The filaments composing the *posterior roots* are finer, but their fasciculi are thicker and more numerous than the anterior.† They proceed from the posterolateral fissure, and previous to their union with the anterior roots are collected into two bundles which pass through a

ganglion. The *ganglion* is of an oval form, bilobate on its external extremity, and lies in the intervertebral foramen; each fasciculus of the posterior root enters the corresponding lobe of the ganglion. The ganglia of the first and second cervical nerves are

* The central canal is well seen in fishes, birds, and reptiles.

† This does not apply to the first cervical nerve, in which the anterior root exceeds the posterior in size.

placed upon the arches of the atlas and axis respectively; the ganglia of the sacral and coccygeal nerves are situated within the spinal canal. The *anterior roots* arise from the antero-lateral column, are smaller than the posterior roots, but like them divide into two fasciculi as they approach the ganglion on the posterior root.

The compound nerve formed by the junction of the two roots, external to the ganglion of the posterior, divides, outside the intervertebral foramen, into an anterior and posterior (dorsal) branch (Fig. 289, p. 714).

The fibres of the anterior roots, after entering the antero-lateral column, pass through the white fibres to enter the grey matter; here they pass in all directions, the larger number passing upwards and downwards, and some decussating with corresponding filaments of the opposite side, through the anterior white commissure; some also pass upward vertically through the lateral column. The fibres of the posterior roots enter the *caput cornu posterioris* through the postero-lateral groove, and then pass upwards and downwards in the grey matter, chiefly of the posterior horn; but some curve round to enter the anterior horn, while others pass to the opposite side through the posterior grey commissure.

**Variation in the
Length of the Roots.**

The direction and length of the roots of the nerves vary in the different regions of the spine, owing to the respective parts of the cord from which they arise not being opposite to the foramina through which the nerves leave the spinal canal (Fig. 287, p. 710). In the upper part of the cervical region the origins of the nerves and their point of exit are nearly on the same level; therefore the roots proceed transversely, and are very short. Lower down, however, the obliquity and length of the roots gradually increase, so that the roots of the lower dorsal nerves are at least a vertebra higher than the foramina through which they emerge. Again, since the cord itself terminates at the lower border of the first lumbar vertebra, the lumbar and sacral nerves must descend from it almost perpendicularly

Cauda Equina.

through the lower part of the spinal canal. To this bundle of nerves the old anatomists have given the name of *cauda equina*, from its resemblance to a horse's tail.

To sum up briefly, it appears that the spinal cord consists of two symmetrical halves, separated in front and behind by a deep median fissure; that the two halves are connected at the bottom of the anterior fissure by an anterior or white commissure, at the bottom of the posterior fissure by the posterior or grey commissure; that each half of the cord is divided into three tracts or columns of longitudinal white nerve-fibres—an anterior, a lateral, and a posterior—the boundaries between them being the respective lines of origin of the

roots of the spinal nerves; that the interior of the cord contains grey matter disposed in the form of two crescents, placed with their convexities towards each other, and connected by a transverse bar of grey matter, which constitutes the posterior commissure.

Blood-vessels of the Cord. The cord is supplied with blood by—1. The *anterior spinal* artery, which commences at the medulla oblongata by a branch from the verte-

bral of each side, and then runs down the middle of the front of the cord. Other branches are derived from the vertebral, ascending cervical, intercostal, and lumbar arteries, which pass through the intervertebral foramina, and assist in keeping up the size of this anterior artery. 2. The *posterior spinal* arteries, which proceed also from the vertebral intercostal, and lumbar arteries, and ramify somewhat irregularly on the back of the cord.

On the posterior part of the bodies of the vertebræ, the spinal arteries of opposite sides communicate by numerous transverse branches along the entire length of the spine, thus resembling the arrangement of its venous plexuses.

Functions of the Spinal Cord. The spinal cord performs, at least, three functions:—1. It is the general conductor of impressions to and from the brain. 2. It transfers impressions. 3. It is a centre of reflex action. *Sensory* impressions are conducted by the posterior roots of the spinal nerves to the cord, and are thence transmitted to the brain through the posterior columns and the grey matter of the cord. These impressions do not run up on the same side, for the fibres, immediately on entering the grey matter, cross over to the opposite side to reach the brain; so that if the posterior column of the *right* side be divided, the *left* leg, and not the right, would be deprived of sensation. *Motor* impulses are conveyed along the antero-lateral columns and the grey matter in them, and carry the commands of the will from the brain to the muscles. The crossing of the motor fibres takes place in the medulla oblongata, at the decussation of the anterior pyramids, so that they run in the corresponding half of the cord as far as their point of decussation. Division, therefore, of one half of the cord below this point, causes paralysis of motion on the same side of the body. The cord is, moreover, concerned in the conduction of impressions to and from the *vaso-motor centre* of the medulla oblongata, which determines the varying conditions of the blood-vessels. The cord also transfers impressions: this is more manifest in disease than in health; a well-marked example of transference is, that pain is felt at the knee in cases of disease of the hip-joint. The spinal cord has probably no power of originating impressions, in other words, it is *not automatic*.

DISSECTION OF THE EYE.

Since the eye in the human subject cannot be obtained sufficiently fresh for anatomical purposes, the student should examine the eye of the sheep, bullock, or pig. The conjunctiva should be removed, together with the loose connective tissue which unites it to the sclerotic coat.

Conjunctiva. The *conjunctiva* is the mucous membrane which covers the ocular surface of the eyelids and the anterior part of the globe. It presents different characters in the various situations over which it is reflected, and is described as the palpebral, the sclerotic, and the corneal portions.

The *palpebral portion* is thicker than the other portions, is very vascular, and is provided with fine papillæ abundantly supplied with nerves. As described p. 51, it is continuous with the mucous membrane of the lachrymal sac through the canaliculi, and lines the Meibomian glands and the ducts of the lachrymal gland. The columnar epithelium which lines the palpebral conjunctiva becomes at the margins of the eyelids more stratified and continuous with the flattened cells of the skin of the eyelid. It forms at the inner canthus a reduplicated fold, the *plica semilunaris*, and is reflected from the eyelids of the globe, its angle of reflection being called the *fornix conjunctivæ* and the folds into which this is thrown are termed the *superior* and *inferior palpebral folds*.

The *sclerotic conjunctiva* is loosely attached by submucous tissue to the sclerotic coat, so as not to impede the movements of the globe. It is thinner, and has no papillæ. It is transparent and nearly colourless, except when inflamed; it then becomes intensely vascular, and of a bright scarlet colour. The arteries are derived from the lachrymal and palpebral branches of the ophthalmic artery, and at the circumference of the cornea they form capillary loops which anastomose with each other. The lymphatics are well marked in the palpebral and sclerotic portions of the conjunctiva, and at the margin of the cornea they rapidly diminish in size and become connected with the cell-spaces in the cornea. An abundant supply of nerves is distributed to the membrane; their arrangement is in the form of plexuses as far as the margin of the cornea, where they terminate in "end-bulbs," described by Krause, resembling in many respects the central portion of Pacinian corpuscles.

The *corneal conjunctiva* is composed chiefly of epithelium ar-

ranged in layers, the deepest of which consists of columnar cells resting by their bases on the substantia propria of the cornea; superficial to these are two or three layers of polygonal cells, the deepest of which, called the *fingered cells of Cleland*, interdigitate with the columnar cells; and on the surface there is a layer of flattened squamous epithelial cells. This portion of the conjunctiva cannot be separated by dissection in recent eyes, but it possesses the same acute sensibility as the rest of the conjunctiva. Changes produced by inflammation of the conjunctiva often involve the cornea and render its texture thick and opaque.*

The eyeball is embedded in a large quantity of fat and delicate connective tissue; and surrounding it in its posterior three-fourths is a serous membrane, the *capsule of Tenon*, which allows of its free movement in the orbit.

The axes of the two eyeballs are nearly parallel with each other; thus they do not correspond with the axes of the orbits, nor of the optic nerves which enter the globes on their nasal aspect.

The human eye is nearly spherical and consists of segments of two spheres: a large posterior one, which corresponds with the sclerotic, and a small anterior one with the cornea. The antero-posterior diameter taken from the anterior corneal surface to the posterior sclerotic surface averages a little less than an inch, or accurately 24.27 mm.; the inner measurement taken from the inner surfaces of the above membranes 21.74 mm. The vertical diameter less than an inch by $\frac{1}{2}$ or 23.65 mm. The optic nerve enters about $\frac{1}{8}$ of an inch (3 mm.) to inside of the antero-posterior axis. The weight is 108 $\frac{1}{2}$ grains or 7.2 gm. The volume 6 c.cm., and the specific gravity 1.025. The antero-posterior diameter varies considerably up to the 21st year; is less in the female. This fact accounts for the varying degrees of near and far sight. The cornea is thicker in the child in the centre, but as age advances this decreases.

Coats and Humours of the Eye. The globe is composed of three concentric coats, arranged one within the other, which enclose certain transparent structures for the transmission of light. The external coat, consisting of the *sclerotic* and *cornea*, is fibrous, thick, and strong. The second coat, consisting of the *choroid*, the *iris*, and the *ciliary processes*, is composed of blood-vessels, muscular tissue, and pigment cells, and is very dark in colour. The third coat, called the *retina*, consists of the

* The facts of comparative anatomy confirm this view. In the serpent tribe, which annually shed the skin, the front of the cornea comes off with the rest of the external surface of the body. In the eel the surface of the cornea is often drawn off in the process of skinning. In some species of rodents which burrow under the ground like the mole, the eye is covered with hair, like other parts.

expansion of the optic nerve for the reception of the impression of the waves of light. The bulk of the interior is filled with a transparent humour, called the *vitreous body*. Embedded in the front of this, and just behind the pupil, is the crystalline lens, for the purpose of concentrating the rays of light. In front of the lens is placed a moveable curtain, called the *iris*, to regulate the amount of light which shall be admitted through a central aperture, the *pupil*, to the fundus of the eye. The space in which the iris is suspended is filled with a fluid, termed the *aqueous humour*.

Sclerotic Coat. The *sclerotic coat* is the white tough protecting coat of the eye which serves to maintain the form of the globe.* It covers the posterior five-sixths of the globe, the remaining anterior one-sixth being completed by the cornea. It is of dense white colour, except in front, where the tendons of the recti and obliqui are inserted into it. The thickest part of the sclerotic coat is at the back of the globe (Fig. 292); the thinnest is a short distance behind the cornea.† The back of the sclerotic is perforated by the optic nerve, which enters it about one-eighth of an inch (3 mm.) on the inner or nasal side of the axis of vision. The sheath of the optic nerve becomes continuous with the sclerotic, where it perforates this coat. The optic nerve at its entrance into the sclerotic is much constricted, and instead of passing through a single aperture in this coat, it enters it through a number of minute apertures, so that this membrane forms a porous lamina, called the *lamina cribrosa*. In the centre of the lamina cribrosa is an opening (*porus opticus*), larger than the rest, which transmits the arteria centralis retinae. Around the optic nerve the sclerotic is pierced by the ciliary arteries, veins, and nerves, for the supply of the choroid and iris. About a quarter of an inch (6 mm.) from the cornea the sclerotic receives the insertions of the recti muscles; ‡ here also it transmits the anterior ciliary arteries, which run forward along the tendons of these muscles, and form a vascular ring around the circumference of the cornea (Fig. 291).

Structure. The sclerotic is composed of connective tissue arranged in bundles, which run, some longitudinally, some transversely, and are intermingled with fine elastic

* The sclerotic coat of the eye in fishes is of extraordinary thickness and density; and in birds this coat is further strengthened by a circle of bony plates, fourteen or fifteen in number, arranged in a series round the margin of the cornea. Similar plates are found in some of the reptiles, and particularly in the fossil ichthyosauri and plesiosauri.

† The greatest thickness posteriorly is about the $\frac{1}{3}$ of an inch (1 mm.); its thinnest in front is about the $\frac{1}{50}$ of an inch (.5 mm.).

‡ There is, however, some variation, the internal rectus being nearest to the cornea; the other tendon about (1 mm.) $\frac{1}{20}$ of an inch farther back. (A. H.)

fibres. The longitudinal fibres are the most external and abundant. Under the microscope numerous connective-tissue corpuscles may be seen filling cell-spaces, similar to those in the cornea but not so abundant, and containing pigment-granules. The inner surface of the sclerotic is of a dark brownish colour, due to the presence of a thin layer of connective tissue, *lamina fusca*, in which are found pigment-cells. This surface of the sclerotic is grooved for the passage of the ciliary nerves, which run forward in a sort of lymph-space; and it is, moreover, connected by filamentous tissue with the subjacent choroid coat.

Cornea.

The *cornea* is the brilliant translucent coat which forms about the anterior one-sixth of the globe. It is nearly circular in shape, its diameter being nearly half an inch, or accurately (11.5 mm.), and its thickness about $\frac{1}{5}$ th of an inch (1.12 mm.) The curve of the cornea forms part of a smaller circle than that of the sclerotic, so that it projects further forwards, varying in this respect in different eyes, and at different ages of life. It is firmly connected at its margin to the sclerotic, with the fibres of which it is continuous. The margin of the sclerotic is bevelled on the inside; that of the cornea on the outside, so that the former overlaps the latter (Fig. 292).



FIG. 291.—INSERTION OF THE RECTI MUSCLES WITH ANTERIOR CILIARY ARTERIES.

To examine the cornea, it should be removed with the sclerotic coat. This should be done under water, by making a circular cut with the scissors, about a quarter of an inch (6 mm.) from the margin of the cornea. With a little care it will be easy to remove the outer coat of the eye without injuring the dark choroid coat, the ciliary muscle, or the iris. In the loose brown-coloured connective tissue between the sclerotic and the choroid are the ciliary nerves passing forwards to the iris; their white colour makes them very conspicuous on the dark ground.

Structure. The cornea consists of four layers, which are not all composed of the same kind of tissue; they are, from without inwards, the conjunctiva, the substantia propria or cornea proper, the posterior elastic lamina, and the epithelial lining.

The *conjunctiva* is the most superficial layer, and consists of several strata of epithelial cells; the deeper ones are columnar and

placed vertically, the next consist of several layers of polygonal cells, and the most superficial ones are flattened scaly epithelium cells, with well-marked nuclei.

The *cornea proper* or *substantia propria* consists of translucent connective tissue, upon which the thickness and strength of the cornea mainly depend. The fibres are arranged in laminae, about sixty in number. Those composing a lamina are arranged in a parallel direction, but the fibres of each layer cross at right angles those of each succeeding layer. The lamellae are connected together by filaments passing from one to another, so that they are not perfectly separate from each other. The cornea proper in the recent subject presents no trace of structure, but it is only after

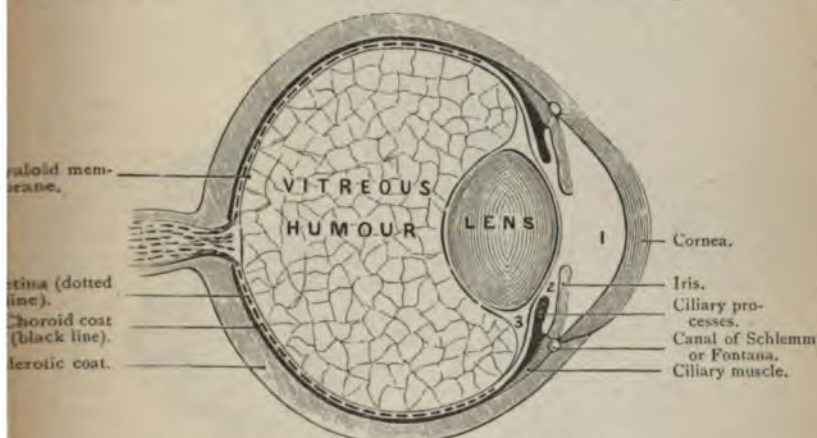


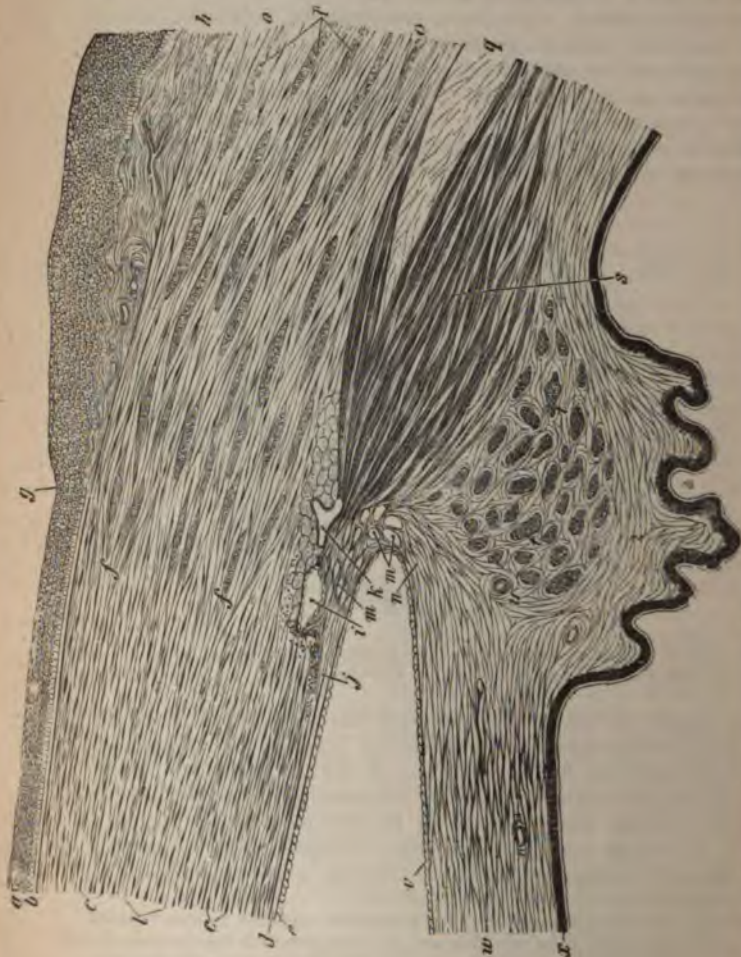
FIG. 292.—DIAGRAM OF A VERTICAL SECTION OF THE EYE.

1. Anterior chamber filled with aqueous humour. 2. Posterior chamber. 3. Canal of Petit.

death by means of lenses and reagents that these lamellae can be satisfactorily demonstrated. Between the lamellae are irregularly branched spaces, called the *cell-spaces of the cornea*, in which are lodged the *corneal corpuscles*, having outstanding processes, which communicate freely with each other in their own plane, and also with those of the planes on either side. These corpuscles correspond in shape to the spaces within which they lie.* In inflamma-

* If fluid be injected very gently into the cornea proper, there may be demonstrated a system of canals, called *Recklinghausen's canals*, which are the communications between the corneal corpuscles; but if the fluid be injected more forcibly, it passes in the course of the fibres composing the various laminae of the cornea, which gives the appearance of a number of varicose and enlarged tubes crossing each other at right angles; these are termed *Bowman's corneal tubes*.

tion of the cornea they undergo considerable changes. Immediately below the conjunctiva, the cornea proper presents a different appearance to that of the main thickness of this layer, so that it has been described by some anatomists under the name



anterior elastic lamina of Bowman. It presents, however, a different fibrillar structure, similar to that of the cornea proper,

destitute of the corneal corpuscles and cells. The greatest thickness of the cornea proper is about $\frac{1}{32}$ th of an inch (1.12 mm).

The *posterior elastic lamina*, called also the *membrane of Descemet* or *Demours*, is translucent, elastic, and brittle, and may be easily separated from the preceding lamina. It consists of a perfectly structureless lamina, which, when peeled off, has a remarkable tendency to curl with the attached surface innermost. At the junction of this lamina with the sclerotic on its inner surface, it spreads out into a number of radiating tooth-like processes, the *ligamentum pectinatum iridis*, which are attached to the front of the circumference of the iris and to the sclerotic and choroid coats. The processes alone are covered with epithelial cells, and the intervals between the processes form small spaces, the *spaces of Fontana*, which communicate freely with the fluid of the aqueous chamber. In the sclerotic coat, close to its junction with the cornea, is situated a small oval canal, lined with epithelium, termed the *sinus circularis iridis* or *canal of Schlemm* (Fig. 293). Although, by some, it is considered a lymph-space, it is probably a venous sinus, for it can be injected from the arteries; but it has probably some free communication with the fluid of the anterior chamber, as this fluid passes rapidly from the chamber into this sinus.*

The *epithelial lining* consists of a single layer of polygonal nucleated cells, and lines the inner surface of the posterior elastic lamina. They resemble those which line serous membranes generally.

Arteries and nerves.—In the healthy condition the cornea contains no blood-vessels, except at its circumference, where they form loops. Nor have any *lymphatics* been demonstrated in it. Its *nerves*, which are numerous—forty to forty-five in number—are derived from the ciliary nerves, and may be traced forwards to the fibrous portion of the cornea, where they lose their dark outline and become transparent, forming a fine plexus—the *primary plexus*. This gives off minute filaments which ramify beneath the epithelium, constituting the *secondary* or *sub-epithelial plexus*. From this very minute varicose fibres run between the epithelial cells, forming the *intra-epithelial plexus*. Besides these plexuses, filaments are given off from the primary plexus to supply the cornea proper, and the filaments are said by some to be continuous with the anastomosing processes of the cell-spaces.

Choroid Coat. After the removal of the sclerotic coat and the cornea, which constitute the first tunic, we expose the second tunic, consisting of the choroid, the iris, and

* For further information on this point consult Leber, *Archiv f. Ophth.* 1878; Heisrath, *Archiv f. Ophth.* xxvi.; and Schwalbe, Graefe, and Saemisch's *Hand-book*, 1874.

ciliary processes in front, and of the ciliary ligament and the ciliary muscle.

The *choroid* is the soft and flocculent tunic of the eye, recognised by its dark brown colour and great vascularity. It covers the posterior five-sixths of the globe, and is thickest posteriorly, where there is a circular aperture in it for the passage of the optic nerve. In front, the choroid passes beneath the ciliary muscle and ligament with which it is connected, and then extends forwards, terminating in a series of plaited folds, called the *ciliary processes*. It is connected with the sclerotic by delicate connective tissue, the *lamina fusca*, through which the ciliary vessels and nerves pass forwards (Fig. 294) to the iris. Its inner surface is smooth, and is in contact with the retina, and when detached from it presents a layer of hexagonal pigmented cells, which are now recognised as forming a part of the retinal coat and as part of which it is originally developed.

Structure.

Under the microscope the choroid is seen to consist of two layers, an external and an internal. The choroid is covered externally by a connective tissue layer, similar to the lamina fusca of the sclerotic, and known as the *lamina supra-choroidea*; it consists of connective tissue intermingled with elastic tissue, and embedded in the meshwork are pigment cells and lymphoid cells. The contiguous surfaces of the lamina fusca and the lamina supra-choroidea are lined with squamous epithelium, having between them a more or less complete lymph-space, which is continuous with that of Tenon's capsule through the apertures in the sclerotic, through which the ciliary vessels and nerves pass.

The *external layer* consists of the larger branches of the blood-vessels; the arteries (short ciliary) running forwards between the veins, previous to dipping down to form the internal layer. The veins are arranged with great regularity in drooping branches (*vena vorticosa*) like the weeping willow (Fig. 294), and converge to four or five nearly equidistant trunks, which, after running backwards for a short distance, perforate the sclerotic not far from the entrance of the optic nerve, and empty themselves into the ophthalmic vein. Between the veins there are interspersed numerous stellate pigment-cells which anastomose with neighbouring cells; on the inner side of this layer the cells are absent.

The *internal layer* is formed by the capillaries of the ciliary arteries and is called the *tunica Ruyschiana*, after the Dutch anatomist Ruysch. The capillaries branch off from the choroid vessels in a radiating manner, and form the most delicate vascular network found in any tissue. It extends forwards as far as the retina, where the intervals become larger and the vessels freely communicate with

those of the ciliary processes. This tissue has on its inner surface a transparent membrane, the *membrane of Bruch*, which rests on the pigmentary layer of the retina.

Ciliary Processes. The *ciliary processes* are the plaited folds formed by the anterior part of the choroid, and may be best seen when the globe has been divided by a transverse vertical section into an anterior and a posterior half, the vitreous humour being left undisturbed. They are black, and consist of from sixty to seventy radiating folds arranged in a circle. These processes consist of longer and shorter folds, the former being the more numerous, and in the proportion of three to one of the latter. The processes fit into corresponding folds of the suspensory ligament of

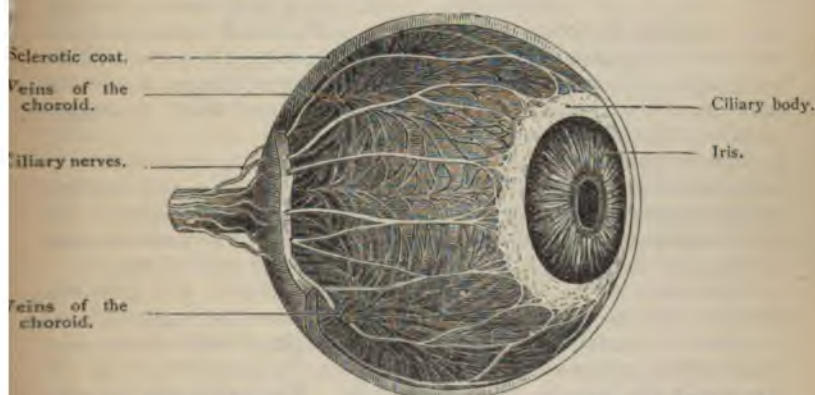


FIG. 394.—SCLEROTIC COAT REMOVED TO SHOW THE CHOROID, CILIARY MUSCLE, AND NERVES.

the lens, and their free ends project for a short distance into the posterior chamber. The circumference of the processes are attached to the ciliary ligament; their inner ends are free and rest upon the circumference of the lens.

Structure.

The vascular supply of the ciliary processes is most abundant and resembles in the main that of the choroid, except that the plexus is coarser, with its meshes arranged longitudinally. The *arteries* come chiefly from the anterior ciliary, and from the front vessels of the choroid; and after breaking up into a fine plexus, they form loops which arch backwards, to end in the smaller veins. Their dark color is due to several layers of pigmented cells, which disappear, however, at the free ends of the processes.

Ciliary Muscle.

The *ciliary muscle* consists of unstripped muscular fibres, and forms a muscular zone at the front of the choroid (Fig. 293), close to the junction of the sclerotic with the cornea. It arises by a thin tendon from the sclerotic close to the cornea, and near the spaces of Fontana. Thence some of its fibres radiate backwards, forming the *meridional* or *radiating fibres*, and are lost in the choroid behind the ciliary processes: some of the fibres form a circular muscle around the outer circumference of the iris, the *circular ciliary muscle*, which was formerly described as the ciliary ligament. Its action is to accommodate the eye to objects at various distances by compressing the lens and increasing the convexity of its anterior surface.*

Iris.

The *iris* is the contractile and coloured curtain suspended in the clear fluid which fills the space between the cornea and the lens. The iris divides this space into two unequal parts, called the *anterior* and *posterior chambers* (Fig. 292); these communicate with each other through a circular aperture in the centre of the iris, called the *pupil*, which is situated a little to the inner side of the iris.†

The circumference of the iris is nearly circular, and is immovably connected with the choroid, the ciliary muscle, and through the ligamentum pectinatum with the cornea. The diameter of the iris is about half an inch (13 mm.), and that of the pupil in man varies from the $\frac{1}{10}$ th (1.2 mm.), to the $\frac{1}{8}$ rd of an inch (8 mm.).

The colour of the iris varies in different subjects, and gives the peculiar tint and brilliancy to the eye. The colouring matter or pigment is contained in minute cells, *pigment cells*, lining the anterior and posterior surfaces of the iris, the posterior taking the name of *uvea*, from its grape-like colour. Pigmented cells are also found in the substance of the iris.

The use of the iris is to regulate the amount of light which shall be admitted into the eye; for this purpose its inner circumference is capable of dilating and contracting according to circumstances, while its outer circumference is immovably attached.

Structure.

When the iris is laid under water, and viewed with a low magnifying power, it is seen to be composed of fine fibres converging from all sides towards the pupil; many of them unite and form arches, leaving elongated interspaces, which are most marked towards the middle of the iris.

* Sir P. Crampton has noticed that this muscle is well developed in birds. In them, its muscles are of the striped variety, as are the circular fibres of the iris.

† The size and shape of the pupil vary in different animals. In the bullock, sheep, horse, &c., it is oblong; in carnivorous quadrupeds it is often a mere vertical slit during the day, but dilates into a large circle at night.

In front of the iris is a thin layer of polyhedral cells, which is continuous with that covering the membrane of Descemet, but the cells are smaller and more granular.

The *stroma* consists of connective tissue and cells. The fibres of the connective tissue are arranged longitudinally and circularly; the longitudinal fibres radiate from the circumference towards the pupil, and between them are contained the blood-vessels and nerves; the circular fibres are found at the circumference of the iris. Intermingled in the meshes of this connective tissue and throughout its whole thickness are numerous and various-shaped pigment cells having anastomosing processes, like those of the choroid. They are chiefly found in the uvea, which is continuous with the pigmented layer of the retina. Upon the disposition of these pigment-cells depends the colour of the iris: in dark eyes, the pigment-cells are scattered throughout the thickness of the stroma; in light eyes, only on its posterior surface.

The *muscular tissue* is of the unstriped kind, and is arranged partly in a radiating, partly in a circular manner. The circular fibres, the *sphincter*, well marked, are collected on the posterior aspect of the pupillary margin, where they form a ring about $\frac{1}{40}$ th of an inch (.5 mm.) in width; at the free margin of the iris they form a thick bundle, but become more frayed out towards the circumference.* The radiating fibres, the *dilatator*, converge towards the pupil, where they form arches and blend with the circular fibres.

The *pigment*, as before described, is found in varying thickness and position, differing according to the colour of the iris.

The *arteries* of the iris are derived from the two long and the anterior ciliary arteries. The *long ciliary arteries* (Fig. 295) perforate the sclerotic coat on each side of the optic nerve, and then run forwards between this tunic and the choroid to the ciliary muscle at the outer circumference of the iris. Each artery divides into an upper and a lower branch, which form with each other and the anterior ciliary arteries a vascular circle (*circulus major*); from this circle numerous small branches pass inwards and form another circle (*circulus minor*) of anastomosis, which terminates in the veins of the iris. The *anterior ciliary arteries*, five or six in number, are derived from the muscular and lachrymal branches of the ophthalmic artery, and ramify on the tendons of the recti muscles (p. 722), where they pierce the sclerotic about the $\frac{1}{2}$ th of an inch (2 mm.) behind the margin of the cornea. These vessels supply the ciliary processes and iris, and join the *circulus major*: it is from

* The circular fibres of the iris in the bird are of the striped variety, and discernible without difficulty.

their enlargement that the red zone round the cornea is produced in inflammation of the iris.

The *veins* follow the same arrangement as the arteries, and communicate as stated (p. 725) with the canal of Schlemm.

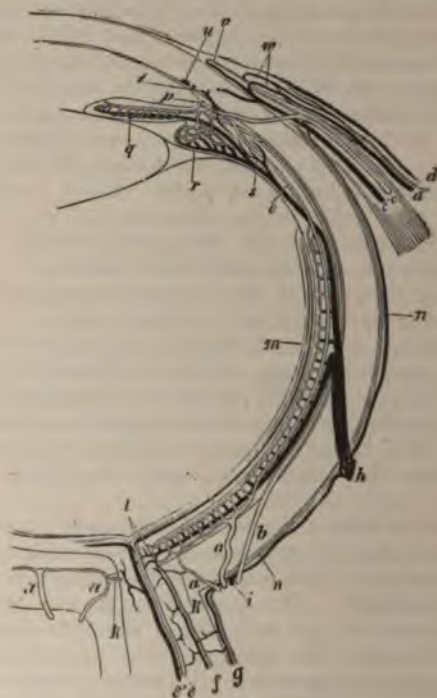


FIG. 295.—HORIZONTAL SECTION OF EYE SHOWING THE BLOOD-VESSELS.

a, a, Short posterior ciliary. *b*, Long posterior ciliary. *c, c'*, Anterior ciliary artery and vein. *d, d'*, Artery and vein of conjunctiva. *e, e'*, Central artery and vein of retina. *f*, Blood-vessels of the inner, and *g*, of the outer optic sheath. *h*, Vorticoses vein. *i*, Posterior short ciliary vein confined to the sclerotic. *k*, Branch of the posterior short ciliary artery to the optic nerve. *l*, Anastomosis of the choroidal vessels with those of the optic. *m*, Chorio-capillaris. *n*, Episcleral branches. *o*, Recurrent choroidal artery. *p*, Great circular artery of iris (transverse section). *q*, Blood-vessels of the iris. *r*, Ciliary process. *s*, Branch of a vorticoses vein from the ciliary muscle. *t*, Branch of the anterior ciliary vein to the ciliary muscle. *u*, Circular vein. *v*, Marginal loops of vessels on the cornea. *w*, Anterior artery and vein of the conjunctiva.

The *nerves of the iris* come from the nasal branch of the ophthalmic nerve, and by twelve to fifteen branches from the lenticular ganglion. They pierce the sclerotic around the entrance of the

optic nerve, and run forwards between the sclerotic and the choroid as far as the ciliary muscle. On the choroid they form a gangliated plexus which lies in connection with and among the blood-vessels. In the ciliary muscle the nerves form another plexus, from which numerous non-medullated fibrils are given off to terminate in the muscular tissue of the iris. The sphincter iridis is supplied through the motor root of the lenticular ganglion which is derived from the third nerve; the dilatator iridis is supplied by the sympathetic system.

Membrana Pupillaris.

Until the seventh or eighth month of foetal life, the pupil is closed by a transparent, vascular membrane, the *membrana pupillaris*, so that the anterior and posterior chambers are divided from each other by this membrane. Its vessels, derived from those of the iris and capsule of the lens, are arranged in loops which converge towards the centre of the membrane without joining each other. About the eighth month this membrane becomes gradually absorbed, so that at birth it is completely lost.

Retina.

To obtain a view of the *retina*, the choroid coat must be carefully removed while the eye is under water; this should be done with the forceps and scissors on a fresh eye. When the choroid is thus removed, there will be seen on its inner surface a layer of pigmented cells, which has been already referred to as really the external layer of the retina, and not in any way part of the choroid coat. The optic nerve, having entered the interior of the globe through the sclerotic and the choroid, expands into the delicate nerve layer, called the retina, which forms the third tunic of the globe. The retina is in contact, externally, with the choroid; internally, with the hyaloid membrane, which separates it from the vitreous; and it extends forwards nearly to the posterior margin of the ciliary processes, where it terminates in a thin serrated border—the *ora serrata*; from this border a thin membrane—*pars ciliaris retinae*—destitute of nerve fibres, is continued forwards to the tips of the ciliary processes, and thence to the posterior surface of the iris.

In passing through the coats of the eye, the optic nerve becomes gradually constricted and reduced to one-half of its diameter; here it presents a round disc, called the *porus opticus*, in the centre of which may be seen the *arteria centralis retinae*. At this point, too, the nerve-substance projects slightly into the interior of the globe, forming a little prominence, to which the term *colliculus nervi optici* has been applied. This prominence is remarkable, in that it is insensible to the rays of light, and is hence called the 'blind spot.'

The retina when fresh is nearly transparent, but soon it becomes

of a pink milky tint. Precisely opposite the pupil, in the centre of the axis of vision, there is an oval yellow spot, *macula lutea*, in the retina, about $\frac{1}{20}$ th of an inch (*1.2 mm.*) in diameter, having a depression, *fovea centralis*, in the centre, and fading off gradually at the edges.

Here vision is most perfect, so that it might be called the "spot of light." This central spot was believed by its discoverer, Sömmerring, to be a perforation; but it is now ascertained to be due to the pigmentary layer of the retina showing through it. These appearances are lost soon after death, and are replaced by a minute fold, into which the retina gathers itself, reaching from the centre of the spot to the prominence of the optic nerve.*

Structure.

Although to the naked eye the retina appears a simple, soft, semi-transparent membrane, yet when examined under the microscope it is found to be most minutely and elaborately organized. It varies in thickness from the $\frac{1}{20}$ th to the $\frac{1}{100}$ th of an inch (*.45 to .14 mm.*), being thickest behind, and gradually diminishes towards the front. It consists of eight layers, through which may be traced a considerable amount of extremely delicate connective tissue (*fibres of Müller*), which constitutes a sustentacular tissue for the various strata, and is said to form for them two more or less continuous boundary layers, termed *membranæ limitantes*, *interna* and *externa*, and which are classed by some anatomists as two additional layers. The layers of the retina are as follows, beginning from within:—

1. The layer of nerve-fibres.
2. The ganglionic layer.
3. The inner molecular layer.
4. The inner nuclear layer.
5. The outer molecular layer.
6. The outer nuclear layer.
7. The layer of rods and cones.
8. The pigmentary layer.

The *membranæ limitantes* are situated as follows: the internal stratum lies on the inner surface of the layer of nerve-fibres; the external, between the outer nuclear layer and the layer of rods and cones.

1. The *layer of nerve-fibres* (Fig. 296, 1) is composed of the spreading out of the optic nerve fibres, and of connective tissue cells. The nerve-fibres, consisting only of the axis-cylinders, run forwards as a continuous layer to the *ora serrata*, partly arranged in bundles and partly in plexuses, and become connected with the nerve-cells of the next layer. The fibres are almost absent on the yellow spot.

* In birds the retina has throughout the yellowish colour seen only at one part in the human eye.

2. The *ganglionic layer* (Fig. 296, 2) is a stratum of spheroidal nerve-cells; from the deeper part of each cell there is given off a single elongated process, which passes obliquely into the nerve-fibre layer, with which it becomes continuous; from the outer side of the cell two or more processes are given off, which branch dichotomously and become at first embedded and then lost in the inner molecular layer. The ganglionic cells, which in the greater part of the stratum form a single layer, are at the yellow spot arranged eight or ten deep, and in its neighbourhood two or three deep.

3. The *inner molecular layer* (Fig. 296, 3) is a granular stratum of considerable thickness which exhibits, under high powers, a reticular structure, having small interstices filled probably with lymph. In it are found, the processes of the nerve cells of the preceding layer, which pass outwards for a considerable distance; some varicose filaments which pass inwards from the next layer; and some Müllerian fibres which pass through this layer. Other cells, like those found in the nerve-fibre and ganglionic layers, are also found in this stratum, chiefly on its surfaces.

4. The *inner nuclear layer* (Fig. 296, 4) contains three kinds of cells, and some fibres which belong to the Müllerian or connective tissue fibres of the retina. The first kind consists of oval bipolar cells placed longitudinally, and having a distinct nucleus and nucleolus; from the inner extremities of these cells there extend long varicose, thin processes which pass vertically downwards, without division, into the inner molecular layer, and are presumably connected with the processes of the ganglionic layer and thence with the nerve-fibres; from the outer extremities of the cells pass processes, thicker than the ones just described and not varicose, which pass to the next layer and there break up into numerous filamentous processes. The second kind of cells are small, granular, protoplasmic cells, which are confined to the deeper part of this layer; and the third kind, similar in their appearance, are disposed here and there in the most external stratum of the inner nuclear layer. The course which the Müllerian fibres take through this layer will be described later on.

5. The *outer molecular or internuclear layer* (Fig. 296, 5) resembles in most respects the inner molecular layer, but is much thinner. It contains, however,

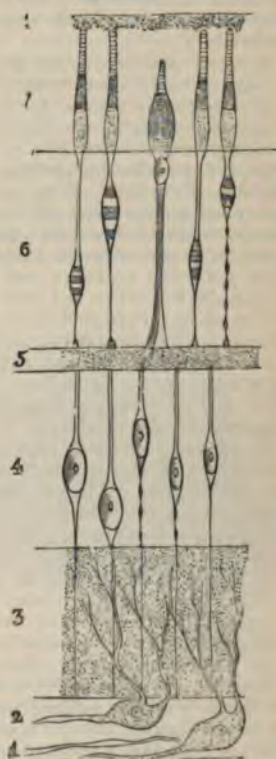


FIG. 296.—DIAGRAM OF THE VARIOUS LAYERS OF THE RETINA. (After Schwalbe.)

1. Layer of nerve-fibres. Membrana limitans interna.
2. Layer of nerve-cells.
3. Inner molecular layer.
4. Inner nuclear layer.
5. Outer molecular layer.
6. Outer nuclear layer.
7. Layer of rods and cones. (Membrana Jacobi.) Membrana limitans ext.
8. Layer of pigment cells.

numerous flattened, branched cells, having well-marked nuclei and nucleoli, and whose fine branching processes exhibit varicosities in their course, resembling nerve-fibrils. Whether these are nerve-fibres or only the fibres of the sustentacular tissue is at present not determined; but this layer, as well as those already described, is developed in the same manner as those of the brain, so that probably these fibres are nerve-fibrils.

6. The *outer nuclear layer* (Fig. 296, 6) consists of a thick stratum of nucleated cells, having outward and inward prolongations, which may be recognised as connected respectively with the rods and cones of the next layer. The *rod-granules* are the most numerous, and each presents an oval cell, which has a well-marked transverse striation, due to the highly refracting substance being crossed by discs of a less refracting medium. There are usually two, one on each side of the middle of the cell. From this enlargement one varicose filament passes inwards and becomes connected with the outer molecular layer by a dilatation, from which numerous filaments pass inwards; the other extremity is thicker, not varicose, and passes outwards towards the *membrana limitans externa*, where it becomes somewhat expanded, and then becomes continuous with a rod. The *cone-granules* are fewer, and each has an oval nucleated cell, which presents no transverse striation characteristic of the rod-granule. The cell is situated close to the *membrana limitans externa*, and rests upon a thick cone-fibre, much thicker than a rod fibre, which enlarges as it approaches the outer molecular layer, upon which it rests by a pyramidal base. From this base numerous fine processes are given off into the molecular layer: the outer extremity is very short and broad, and supports the base of a cone.

7. The *layer of rods and cones, bacillary layer or Jacob's membrane* (Fig. 296, 7) is composed of minute cylindrical elements, arranged at right angles to the surface of the retina. The *rods*, the more numerous, are tapering processes running through the whole thickness of this layer, and, externally, are embedded to a greater or less depth in the pigmented layer, so that when viewed from without they have the appearance of a mosaic pavement made up of round segments. Among the rods are intermingled numerous shorter, flask-shaped bodies called *cones*, which do not extend through more than half the thickness of this layer. Their outer extremities taper off towards the choroid; their inner or broad ends, like the rods, rest upon the *membrana limitans externa*, and thence are connected with the outer nuclear layer. Each rod and cone consists of two segments of equal lengths: the inner, in the case of the cones, very broad and bottle-shaped, of the rods only slightly bulged; the outer, fine and tapering off. The two segments vary in their microscopic appearance and in relations to reagents; the outer segments of both have a transverse striation, and break up in the direction of this striation; the inner segments are composed externally of longitudinal fibrillæ, internally of finely granular homogeneous substance continuous with the rod or cone fibre. The inner segments are deeply stained by carmine, iodine, &c., the outer segments not by the same reagents, but are by osmic acid. The rods are absent at the yellow spot.

8. The *pigmentary layer* (Fig. 296, 8) is usually described as forming part of the choroid coat, but it should both developmentally and physiologically be included as one of the layers of the retina. It consists of a single layer of hexagonal nucleated cells filled with pigment-granules, which are most numerous towards the margins of the cells. The surface of the cells which looks towards the choroid is smooth and destitute of pigment-granules, and it is here that the nucleus is situated; the surface towards Jacob's membrane is filled with pigment, which is not well defined, but runs down among the rods, so that their outer part is embedded among the pigment-cells. The use of the pigment is to absorb the rays of light which pass through the retina, and thus prevent their being reflected.

It serves the same purpose as the black point with which the inside of optical instruments is darkened. Albinos, in whom this layer has little or no pigment, are, consequently, dazzled by daylight and see better in the dusk.*

The *sustentacular tissue* (*Müllerian fibres*) is a tissue which runs through the greater thickness of the retina, beginning at the so-called *membrana limitans interna*, and ending at the *membrana limitans externa*; but in neither of these two situations does it form a continuous layer, so that it cannot be classed under the layers forming the retina. These fibres are probably of the nature of a delicate connective tissue, which serves to sustain the various layers and their constituent elements. Each fibre begins by a broad conical base, on the deeper aspect of the layer of nerve-fibres (the bases of these fibres being more or less in connection with each other); it then passes through the layers of nerve-fibres and ganglionic cells, and, consequently the inner molecular layer, gradually diminishing in thickness; on reaching the inner nuclear layer it gives off thin filamentous processes which support the structures of this stratum, presenting here a lateral bulge with a well-marked nucleus. After passing through the outer molecular layer it reaches the

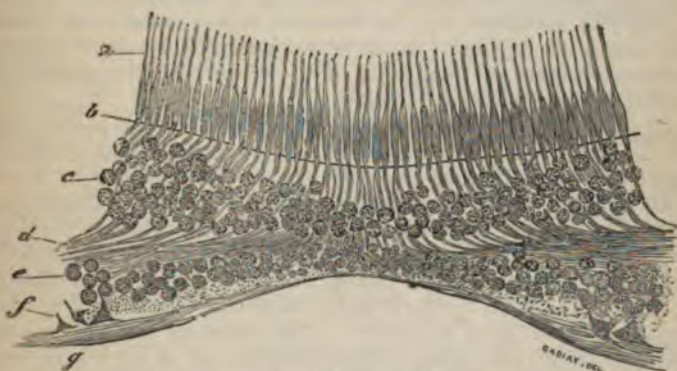


FIG. 297.—SECTION OF THE FOVEA CENTRALIS.

a. Cones. b, and g. Internal and external limiting membrane. c, External and e, Internal nuclear layer. d. Fibres. f. Nerve-cells.

outer nuclear layer, and then breaks up into filaments which join with fibrils from other Müllerian fibres, thus enclosing and supporting the cells and their prolongations of this layer. These filamentous offsets reach as far as the bases of the rods and cones, forming a bed on which they rest; this is described as the *membrana limitans externa*.

The structure of the *macula lutea* and *fovea centralis* (Fig. 297).—In the *macula lutea*, the nerve-fibres do not form a continuous layer; the ganglionic layer consists of cells six to eight deep; there are no rods; the cones are longer

* In many of the nocturnal carnivorous quadrupeds, the inner surface of the choroid at the bottom of the eye presents a brilliant colour and metallic lustre. It is called the *tapetum*. By reflecting the rays of light a second time through the retina, it probably enables the animal to see better in the dusk. It is the cause of the well-known glare of the eyes of cats and other animals; and the great breadth of the luminous appearance arises from the dilatation of the pupil.

and narrower than elsewhere; and the outer nuclear layer has only cone-fibres. In the *fovea centralis* there are no rods, and the cones are longer than in the macula; and all the other layers are much thinned. At the margin of the fovea most of the layers are thicker than elsewhere.

The structure of the *ora serrata* is much less complex than the other parts of the retina; the layer of rods and cones disappear, the former first of all; the ganglionic and nerve fibre layers become thin and then cease; the inner molecular layer loses much of its granular appearance, and is largely formed of sustentacular tissue, and then abruptly ceases; the inner and outer nuclear layers become thinner, and then gradually merge into a single layer, which is continued on to the *pars ciliaris* as a single stratum of columnar epithelial cells.

The *arteria centralis retinae*, after emerging through the porus opticus, divides into two branches—an *upper* and a *lower*—which then form a delicate network of blood-vessels throughout the nerve-fibre layer, penetrating as far as the inner nuclear layer, beyond which no capillaries can be traced. After maceration in water, the nervous substance can be removed with a camel's-hair brush, and then in an injected eye the network formed by the vessels can be distinctly seen. The arteries of the retina do not communicate directly with the choroidal vessels.

Aqueous Humour. The *aqueous humour* consists of a few drops of an alkaline clear watery fluid, which fills the space between the cornea and the lens.* The iris lies in it, and divides the space into two chambers of unequal size—an anterior and a posterior. The *posterior* is much the smaller of the two: indeed, the iris rests on the capsule of the lens, so that, strictly speaking, there is no interval between the opposed surfaces, except a triangular interval bounded by the attachment of the iris, the ciliary processes, and the zone of Zinn. This accounts for the frequent adhesions which take place during inflammation of the iris, between the iris and the capsule of the crystalline lens.† A delicate layer of epithelium covers the posterior surface of the cornea, but nothing like a continuous membrane can be demonstrated on the iris or the capsule of the lens. The *anterior* chamber is remarkable for the rapidity with which it absorbs and secretes; as is proved, in the one case, by the speedy removal of extravasated blood; in the other, by the rapid reappearance of the aqueous humour after the extraction of a cataract.

The Vitreous Body and the Hyaloid Membrane. The vitreous body is a transparent, gelatinous-looking substance, which fills up nearly four-fifths of the interior of the globe (Fig. 292). It can be easily separated from the retina, except at the optic disc; in front it presents a deep depression, in

*The solid constituent is mainly composed of chloride of sodium.

† Some anatomists describe the anterior chamber as lined by a serous membrane called the membrane of the aqueous humour.

which the crystalline lens is embedded. It is surrounded, except in front, by a delicate transparent membrane—the *hyaloid membrane*—which forms a capsule for the vitreous body, and is sufficiently strong to keep it in shape after the stronger tunics of the eye have been removed.

When the vitreous humour has been hardened in chromic acid it is rendered somewhat opaque, and presents, especially at its outer part, a lamellar appearance. It consists of a fluid contained in the meshes of a cellular structure, which communicate freely with each other; for if any part of it be punctured, the humour gradually drains away.* If examined carefully, the lamellation is seen to be arranged concentrically, the layers, as they approach the centre, becoming less firm in consistence. The vitreous, moreover, on a transverse section, shows a radial striation, but whether this exists naturally, or is the result of post-mortem changes, or from chemical reagents, is not known. Running through the middle from before backwards is a small canal—*canal of Stilling*—about a line in diameter, which contains fluid, and is broader behind than in front; this in the fetus lodges a small branch of the retinal artery, which ramifies on the back of the capsule of the lens.



FIG. 298.—ARTERIES OF THE RETINA.

Canal of Petit (inflated). Zone of Zinn (exaggerated).

The hyaloid membrane surrounds the vitreous body, except in front, and passes from the anterior border of that body to the margin of the lens, forming the *suspensory ligament of the lens*, and known as the *zone of Zinn*. This is best exposed by removing the ciliary processes. It appears as a dark, radiating disc, and the surface is marked by prominent ridges, which correspond with the intervals between the ciliary processes (Fig. 298). These intervals are in life filled with fluid, and perhaps with the vitreous. The hyaloid membrane, with the exception of the suspensory ligament, is a structureless membrane, but the ligament presents a structure consisting in part of longitudinal elastic fibres. Beneath the membrane, on its inner surface, are numerous granular nucleated cells, which exhibit amoeboid movements. The ligament assists in maintaining the lens in its proper position, and is firmly connected with its capsule.

Canal of Petit.

If the transparent membrane between the zone of Zinn and the margin of the lens be carefully punctured, and the point of a small blowpipe gently introduced, and air or fluid injected, we may succeed in inflating a canal which encircles the lens: this is the *canal of Petit* (Fig. 298). It is triangular in section, and bounded in front by the suspensory ligament of the lens; behind, by the vitreous body; and its base, by

* This is composed mainly of water, with albuminate of soda and mucin.

the capsule of the lens. When inflated, it becomes sacculated, as in Fig. 298, owing to the foldings on the front surface of the lens.

Crystalline Lens. The *crystalline lens* (Fig. 292) is a perfectly translucent solid body, situated immediately behind the pupil, partly embedded in the vitreous body, and completely surrounded by a capsule equally translucent. It is convex on both sides, but more so behind. In early life it is nearly spherical and soft, but it becomes more flattened, firmer, and amber-coloured with advancing age. In the adult its transverse diameter is about one-third of an inch (9 mm.); its antero-posterior, one-seventh of an inch (3.7 mm.).

The *capsule of the lens* is a transparent, elastic, and brittle membrane. It resembles in structure the elastic layer of the cornea, and is much thicker in front than behind; in front, it is in contact with the posterior surface of the iris; behind, it rests in the depression of the vitreous body. The capsule in front is separated from the lens by a layer of polygonal nucleated cells, and, after death, a layer of fluid is interposed between the capsule and the lens, constituting the *liquor Morgagni*; behind, no such layer of epithelium exists. No vascular connection whatever exists between the lens and its capsule.* The lens protrudes directly the capsule is sufficiently opened.

Structure of the Lens.

The minute structures of the lens can only be made out after being hardened. It is soft, almost gelatinous in consistence outside, but each successive concentric layer becomes more dense, so that the central part is hard, and constitutes the *nucleus*. It is seen to be divided into three equal parts, by three lines, which radiate from the centre to within one-third of the circumference. Each of these portions is composed of numerous concentric layers, arranged one within the other, like the coats of an onion. If any single layer be examined with the microscope, it is seen to be composed of fibres, running in a curved direction, and connected together by finely serrated edges. On a transverse section the lens-fibres are found to be hexagonal prisms, with very little connecting substance. Between the front of the lens and its capsule is a layer of flattened cells with well-marked excentric nuclei. The beautiful dove-tailing of the fibres of the lens was first pointed out by Sir David Brewster; and to see it in perfection, one ought to examine the lens of the cod-fish.

The function of the lens is to bring the rays of light to a focus upon the retina.†

* The vessel of the capsule of the lens is derived from the *arteria centralis retinae*, and in mammalia can only be injected in the foetal state. In the reptilia, however, the posterior layer of the capsule is permanently vascular. This small artery passes forwards through the canal of Stilling to the posterior part of the capsule of the lens, on which it radiates into numerous small branches, communicating with branches in the iris and pupillary membrane.

† The lens contains about 60 per cent. of water, and 30 per cent. of albuminoids.

DISSECTION OF THE ORGAN OF HEARING.

The parts constituting the organ of hearing should be examined in the following order: (1) the outer cartilage or pinna; (2) the meatus auditorius externus; which leads to (3) the tympanum or middle ear; and (4) the labyrinth or internal ear, comprising the vestibule, cochlea, and semicircular canals, which contain the distribution of the auditory nerve.

Pinna.

The *pinna* or *auricle* consists of yellow fibro-cartilage covered with integument, and is irregularly concave to receive the undulations of sound. It is unevenly oval, and presents on its external aspect numerous eminences and hollows, which have received the following names:—The circumferential folded border is called the *helix*; the ridge within it, the *antihelix*; between these is a curved groove, called the *fossa of the helix*. The antihelix bifurcates towards the front and encloses the *fossa of the antihelix* (*fossa scaphoidea*). The conical eminence in front of the meatus is termed the *tragus*, on which some hairs are usually found. Behind the *tragus*, and separated from it by a deep notch (*incisura intertragica*), is the *antitragus*. The *lobule* is the soft pendulous part placed below the *concha*, and consists of fat and fibrous tissue. The deep hollow, which collects the vibrations of sound, and conveys them into the external meatus, is termed the *concha*.

Structure.

The pinna is composed of yellow fibro-cartilage, with some fat and connective tissue, covered with integument, and attached to neighbouring parts, partly by fibrous tissue and partly by muscles.

The *skin* is very thin, intimately adherent to the subjacent cartilage, and provided with numerous sebaceous glands, found chiefly in the scaphoid fossa and the *concha*.

The *cartilage* is a single, uneven plate of fibro-cartilage, which presents all the irregularities of the external ear. The cartilage is incomplete, for there is a deficiency behind the *tragus* at the bottom of the *concha*, which is filled up with fibrous tissue. It has a tubular prolongation inwards, which forms the external part of the meatus auditorius externus. The cartilage presents several fissures (*fissures of Santorini*) at the anterior part of the tubular prolongation, which are completed by fibrous tissue. In the front part of the

pinna, where the helix makes its first bend, is a conical projection of cartilage, termed the *process of the helix*. The lobule, attached to the lower part of the pinna, is a rounded projection formed of fat and connective tissue; it is this which enlarges with age and obesity of the subject.

Ligaments. The ligaments are: the *anterior ligament*, broad and strong, which passes from the process of the helix to the root of the zygoma; the *posterior ligament*, which extends from the cranial surface of the concha to the mastoid process of the temporal bone. There are also *intrinsic ligaments* which bridge over and fill up the deficiencies in the pinna.

Muscles of the Pinna.

The muscles which move the cartilage of the ear as a whole, have been described (page 27). Other small muscles extend from one part of the cartilage to another; but they are so indistinct that, unless the subject be very muscular, it is difficult to make them out. The following six—four on the front of the auricle and two behind it—are usually described:—

- (a) The *musculus major helicis* runs vertically along the front margin of the helix: it arises below from the process of the helix, and is inserted into the curve of the helix as it passes backwards.
- (b) The *musculus minor helicis*, an oblique muscle, lies over that part of the helix which is connected with the concha.
- (c) The *musculus tragicus* lies vertically over the outer surface of the tragus.
- (d) The *musculus antitragicus* passes transversely from the anti-tragus to the lower part of the tail-like process of the helix behind the lobule.
- (e) The *transversus auricula* is on the cranial aspect of the pinna; it passes nearly transversely from the back of the concha to the prominence corresponding to the fossa of the helix.
- (f) The *obliquus auris* extends vertically from the cranial aspect of the concha to the convexity below it.

The *arteries* of the pinna are derived from the posterior auricular, and from the auricular branches of the temporal and occipital. The *veins* empty themselves into the temporal vein. The *nerves* are furnished by the great auricular branch of the superficial cervical plexus, the auriculo-temporal branch of the inferior maxillary, the posterior auricular branch of the facial, and the auricular branch of the pneumogastric.

Meatus Auditorius Externus.

This oval passage leads down to the membrana tympani, and conveys the vibrations of sound to the tympanum. It is about an inch and a quarter (*.3.1 cm.*) in length; its external opening is longest in its vertical direction: its termination is broadest in its transverse. The canal inclines at first upwards and forwards, and then curves a little downwards.* Its floor, owing to the oblique direction of the

* To obtain a correct knowledge of the length and dimensions of the meatus, sections should be made through it in different directions, or a cast be taken of it in plaster of Paris.

membrani tympani, is a little longer than the roof. It is not of equal calibre throughout, the narrowest part being about the middle; hence the difficulty of extracting foreign bodies which have passed to the bottom of the canal. It is formed, partly by a tubular continuation of the cartilage of the pinna, partly by an osseous canal in the temporal bone.

The *cartilaginous portion* is about half an inch (13 mm.) long,

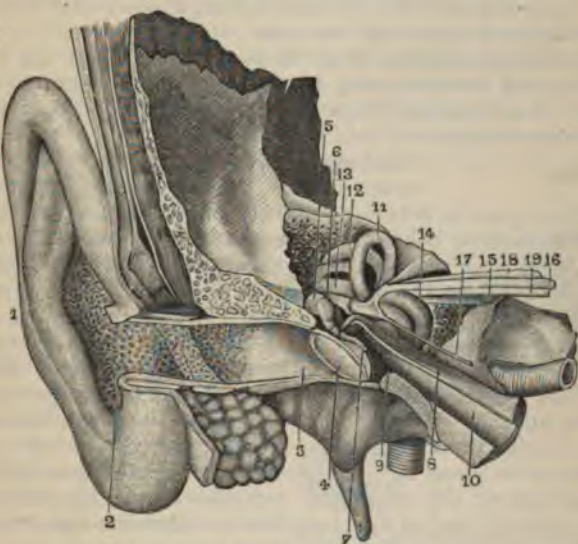


FIG. 299.—VERTICAL SECTION OF EAR.

1. Pinna or Auricle. 2. Concha with orifices of sebaceous and ceruminous glands. 3. Osseous portion of external auditory canal. 4. External surface of the membrani tympani. 5. Anterior part of the incus. 6. Head of the malleus. 7. Handle of the malleus lodged between the internal and middle layers of the membrani tympani. 8. Tensor tympani m. with its tendon at a right-angle to be attached at the inner margin of the base of the handle of the malleus. 9. Cavity of the tympanum. 10. Expanded portion of the Eustachian tube. 11. Superior semicircular canal. 12. Posterior semicircular canal. 13. External semicircular canal. 14. Cochlea. 15. The internal auditory canal where the wall has been taken away to show the nerves which it transmits. 16. Facial nerve. 17. The great superficial petrosal nerve passing from the geniculate ganglion of the facial to reach its destination. 18. Vestibular branch of the auditory nerve. 19. Cochlear branch of the auditory nerve.

and is firmly connected to the osseous portion. The cartilage is incomplete at the upper and back part, and the interval is filled in with fibrous tissue.

The *osseous portion*, about three-quarters of an inch (19 mm.) in length, is narrower than the cartilaginous portion, and is curved forwards and inwards. Its outer extremity is rough for the attach-

ment of the cartilage; its inner presents a narrow groove, except at the upper part, for the insertion of the membrana tympani. The lower and anterior wall of the osseous portion is formed by a semi-circular plate of bone, the *tympanic plate*, the outer border of which is thickened and is termed the *external auditory process*.

The *skin* and the cuticle are continued down the passage, and becoming gradually thinner, form a cul-de-sac over the membrana tympani. The outer portion is furnished with hairs and ceruminous glands, which secrete the cerumen or wax, and are only found over the cartilaginous portion of the canal.

Its *arteries* are derived from the posterior auricular, the internal maxillary and the temporal, all branches of the external carotid artery. Its *nerves* come from the auriculo-temporal branch of the inferior maxillary nerve.

Tympanum.

The *tympanum*, or middle ear, is an irregular cavity in the petrous part of the temporal bone: having on its outer side the membrana tympani; on its inner side the labyrinth; behind, the mastoid cells; in front, the carotid canal; and below, the wall of the jugular fossa. It is rather less than half an inch (13 mm.) in its long diameter; from $\frac{1}{8}$ to $\frac{1}{12}$ of an inch ($\frac{1}{4}$ to 2 mm.) between its outer and inner boundaries; and a quarter of an inch (6 mm.) in its vertical direction. It is lined with mucous membrane and filled with air, which is freely admitted through the Eustachian tube; so that atmospheric pressure is equal on both sides of the membrane. A chain of small bones, the *ossicles*, retained in their position by ligaments and acted upon by muscles, passes across it. The use of these bones is to communicate the vibrations of the membrana tympani to the labyrinth. For this purpose one end of the chain is attached to the membrane, the other to the fenestra ovalis. The tympanum is bounded by a floor, a roof, an outer, an inner, an anterior, and a posterior wall.

Its *roof* is formed by a thin plate of bone corresponding with the anterior surface of the pars petrosa, which separates the tympanum from the cranial cavity.

The *floor*, which is narrow, is formed by a thin plate, corresponding to the jugular fossa beneath: it is perforated in front by a small aperture for Jacobson's nerve.

Its *outer wall* is formed mainly by the membrana tympani, and by a ring of bone which affords attachment to it; the latter is pierced by the fissura Glaseri (which gives passage to the processus gracilis of the malleus, the laxator tympani, and the tympanic branch of the internal maxillary artery), by the foramen chordæ posterius, through which the chorda tympani enters the tympanum, and by the foramen chordæ anterius, which is the commencement of the canal of Huguier, for the exit of the chorda tympani nerve.

The *inner wall* is vertical and uneven, and presents the following objects, beginning from above: 1. A horizontal *ridge*, indicating the line of the aquæductus Fallopii; 2. The *fenestra ovalis*, a reniform opening, nearly horizontal, which leads into the vestibule, but is closed in the recent state by a membrane, to which is attached the base of the stapes; 3. Below and in front of the fenestra ovalis is a convex bony prominence, the *promontory*; it is occasioned by the first turn of the cochlea, and is marked by vertical grooves, in which lie the branches of the tympanic plexus of nerves; 4. Below and behind this is the *fenestra rotunda*, which lies at the bottom of a conical depression and is overhung by a projection of bone, so that it cannot be seen, except when viewed obliquely; it leads to the scala tympani of the cochlea, but is closed in the recent state by membrane; 5. Immediately behind the fenestra ovalis is a small conical eminence, named the *pyramid*, in the summit of which is a small aperture, from which the tendon of the stapedius emerges; within the pyramid at its base is a small aperture which leads to the aquæductus Fallopii, and transmits a special filament from the facial nerve to the stapedius.

The *posterior wall* presents three or four openings, one of them large, which lead to the mastoid cells, and convey air into them from the tympanum. The mucous membrane of the tympanum is continued into the mastoid cells through these openings.

The *anterior wall* is pierced by an aperture for the transmission of a small artery from the internal carotid. Into this wall open the *Eustachian tube*, and (in the dry bone) the canal for the *tensor tympani*, which are separated from each other by a bony septum, the *processus cochleariformis*. The *Eustachian tube* is partly osseous, partly cartilaginous; the *cartilaginous portion* has been described, p. 237; the *osseous portion*, about half an inch (13 mm.) in length, opens into the lowest part of the anterior wall, and is lined with mucous membrane continuous behind with that of the tympanum and in front with that of the pharynx. The *canal for the tensor tympani* terminates in the anterior wall above the Eustachian tube as a conical projection, in the apex of which is a small aperture for the tensor muscle; this projection is frequently called the *anterior pyramid*.

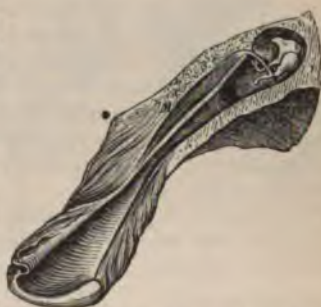

FIG. 300.—TENSOR TYMPANI MUSCLE. (M)
The Eustachian tube (left) opened and showing the processus cochleariformis.

Lastly, a nerve called the chorda tympani (a branch of the facial) runs in an arched direction from the back to the front of the tympanum, and is covered with mucous membrane.

Membrana Tympani. The *membrana tympani* is a thin semi-transparent oval disc, which completely closes the bottom of the meatus auditorius externus. Its transverse diameter slightly exceeds its vertical, and its circumference is set in a bony groove, so that it is stretched, somewhat like the parchment of a drum, on the outer wall of the tympanum.* Its plane is not vertical, but slants from above downwards, forming, with the floor of the meatus, an angle of 40 to 55°. It is slightly conical, the apex being directed inwards towards the tympanum, and between its layers is inserted the handle of the malleus which runs downwards and forwards to a little below the centre.

Structure. It is composed of three layers; an outer, formed by an extremely thin layer of true skin; an inner, by the mucous membrane of the tympanum; and a middle fibrous layer; most of the fibres radiate from the attachment of the tip of the handle of the malleus in a bowed direction, so that the membrane is not a strict cone; other fibres are annular, forming a circumferential ring close to the osseous ring; these stretch over a notch in the upper part of the ring (*notch of Rivini*) so that the membrane is here flaccid and takes the name of the *membrana flaccida*.

The *arteries* to the membrane are supplied from the tympanic branch of the internal maxillary, the stylo-mastoid branch of the posterior auricular, the Vidian, and the internal carotid.

Ossicula Auditus. The three small bones in the tympanum are named after their fancied resemblance to certain implements, the *malleus*, *incus*, and *stapes*. They are articulated to each other by perfect joints, and are so placed that the chain somewhat resembles the letter Z. Their use is to transmit the vibrations of the *membrana tympani* to the membrane of the fenestra ovalis, and, through it, to the fluid contained within the vestibule. But they have another use, which would be incompatible with a single bone—namely, to permit the tightening and relaxation of the membrane, and thus adapt it either to resist the impulse of a very loud sound, or to favour a more gentle one.

The *malleus* (Fig. 302) or hammer bone, consists of an upper part or *head* (*c. m.*), which is suspended from the roof of the tympanum by the suspensory ligament, and articulates posteriorly with the *incus*. Below the head is a narrow constriction, the *neck* (*c.*),

* The transverse diameter of the membrane is 0.37 inch (9 mm.); its vertical diameter 0.33 inch (8 mm.).

which is continued on into a long, somewhat curved, tapering process, the *manubrium* or *handle* (*m*): it is nearly vertical, and is attached along its whole length to the upper half of the *membrana tympani*, passing between its inner and middle layers. The *processus gracilis* (*Pbl*) projects at a right angle below the neck, runs into the Glaserian fissure, and receives the insertion of the *laxator tympani*. The *processus brevis* (*Pbr*) is a stunted projection, situated at the junction of the *processus gracilis* and *manubrium*, and touches the *membrana tympani*; it receives the insertion of the *tensor tympani*.

The *incus*, or *anvil* bone (Fig. 302), is shaped like a tooth, with

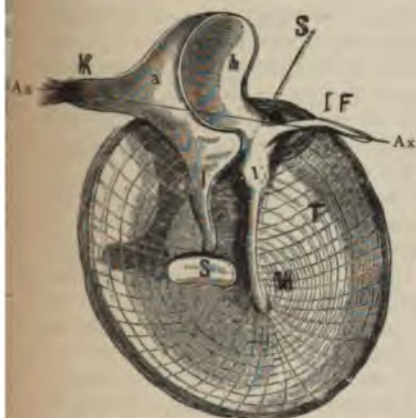


FIG. 301.—TYMPANIC MEMBRANE AND AUDITORY OSSICLES (LEFT) SEEN FROM WITHIN, (*i. e.*) FROM THE TYMPANIC CAVITY.

M. Manubrium or handle of the malleus. T. Insertion of the tensor tympani. h. Head. IF. Long process of the malleus. a. Incus with the short (*k*) and the long (*l*) process. S. Plate of the stapes. Ax. Ax. is the common axis of rotation of the auditory ossicles. S. Pinion wheel arrangement between the malleus and incus.

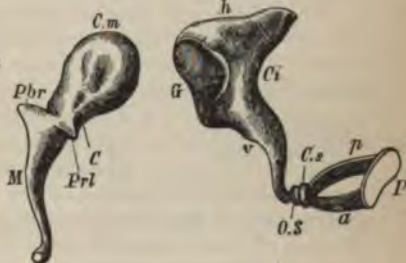

FIG. 302.—AUDITORY OSSICLES (RIGHT).

Cm. Head of the malleus. C. Neck. Pbr. Short process. Pbl. Long process. M. Manubrium or handle. Ci. Body of the incus. G. Articular surface. h. Short and v long processes. O. S. So-called lenticular ossicle. Cs. Head of the stapes. a. Anterior. p. Posterior limb or crus. P. Plate of the stapes.

two unequal, widely separated fangs. Its broad part or *body* (*ci*), presents a concavo-convex articulation in front for the head of the malleus; its *long process* (*v*) runs nearly parallel with the handle of the malleus, and articulates with the stapes through the intervention of a small bone, the *os orbiculare*, which forms part of the long process; its *short process* (*h*) is directed horizontally backwards, and its point is fixed in a small hollow at the commencement of the mastoid cells.

The *stapes*, or stirrup bone (Fig. 302), lies horizontally. Its *head (cs)* articulates with the long process of the incus. Below the head is a constriction, the *neck*, which receives at its posterior part the insertion of the stapedius. Two *diverging crura (a. p.)* pass from the head to an oval plate of bone, the *base*, which is attached to the membrane covering the fenestra ovalis.

The tympanic bones are maintained in their positions by various ligaments. The *anterior ligament of the malleus* passes from the head of this bone to the anterior wall of the tympanum; the *suspensory ligament* descends from the roof of the tympanum outwards to the head of the malleus, and the *posterior ligament of the incus* passes from the short process to the posterior wall near the mastoid cells. The ossicles are connected by an imperfect *capsular ligament*, which passes from the long process of the incus to the head of the stapes; and by another which passes from the head of the malleus to the incus. The base of the stapes is attached to the margin of the fenestra ovalis by an *annular ligament*. The surfaces of the bones forming these two little joints are covered with cartilage. The joints have also synovial membranes.

Muscles of the Tympanum.

The muscles, by moving the tympanic bones, tighten or relax the membrana tympani.

The *tensor tympani* (Fig. 300, p. 743) runs in a canal above and parallel to the Eustachian tube, from the cartilaginous part of which it *arises*, as well as from the apex of the petrous portion of the temporal bone. It passes backwards, and terminates in a round tendon, which enters the front wall of the tympanum through a special bony canal, and, making a sharp bend outwards, is *inserted* into the root of the handle of the malleus. Its nerve comes from the otic ganglion. Its action is to draw inwards the head of the malleus, and thus render the membrane tense.

The *laxator tympani* *arises* from the spinous process of the sphenoid, and the cartilaginous portion of the Eustachian tube, and is *inserted* into the neck of the malleus close to the root of the processus gracilis. It is supplied by a branch of the facial nerve.* Its action is to relax the membrana tympani.

The *stapedius* *arises* from the hollow of the pyramid, and its tendon, emerging through the aperture in the apex, runs forwards to be *inserted* into the neck of the stapes.† Its nerve is derived from the facial. By its action it increases the tension upon the fluid in the vestibule.

* This is usually regarded as a muscle, and is described here as such; no muscular fibres, however, can be traced in it, so that it is probably only ligamentous in structure—a fact borne out in the lower animals.

† There is a little sheath, lined with synovial membrane, to facilitate the play of the tendon in the pyramid.

The *mucous membrane* of the tympanum is continuous with that of the pharynx. It covers the ossicles, muscles, and nerves, and is prolonged into the mastoid cells. The membrane is pale and thin, and lined with columnar ciliated epithelium, except on the promontory, the *membrana tympani*, and the ossicles, where there is only a single layer of flattened cells.

A branch (*chorda tympani*) of the facial nerve enters the tympanum through a foramen, *foramen chordæ posterius*, at the base of the pyramid; it then crosses the tympanum beneath the handle of the malleus and the long process of the incus, leaves the tympanum through a foramen, *foramen chordæ anterius*, and then traverses a canal (*canal of Huguier*), which runs close to the Glaserian fissure. It eventually joins the submaxillary ganglion (p. 154).



FIG. 303.—RIGHT-STAPEDIUS MUSCLE EMERGING FROM THE PYRAMID.

The *arteries* supplying the *tympanum* are:

(1) the *tympanic* branch of the internal maxillary, which enters through the *fissura Glaseri*; (2) the *stylo-mastoid* branch of the posterior auricular; (3) small branches from the ascending pharyngeal, which enter with the Eustachian tube; (4) branches from the internal carotid artery; and (5) the petrosal branch of the *arteria meningea media*.

The *veins* open into the middle meningeal and the pharyngeal veins.

The mucous membrane is supplied with branches from the tympanic plexus, which is formed by filaments from the tympanic branch of the glosso-pharyngeal nerve, from the carotid sympathetic plexus, and from the large and small superficial petrosal nerves.

Internal Ear.

This, in consequence of its complexity, is called the *labyrinth*. It consists of cavities excavated in the most compact part of the temporal bone, and it is divided into three parts: a middle one, called the *vestibule*, being the common cavity in which all communicate; an anterior, named, from its resemblance to a snail's shell, the *cochlea*; and a posterior, consisting of *three semicircular canals*; it communicates externally with the tympanum by means of the *fenestra ovalis* and *rotunda*, and internally with the *meatus auditorius internus*. These cavities are filled with a clear fluid, called the *endolymph* and contain a membranous expansion, the *membranous labyrinth*, upon which the filaments of the auditory nerve are expanded.

Vestibule.

The *vestibule*, or central chamber, is an irregular oblong cavity, about one-fifth of an inch (5 mm.) in its widest part, which is at its antero-posterior and at its vertical diameters. On its *outer wall* is the *fenestra ovalis*, which

is closed in the recent state by the base of the stapes; on its *inner wall*, at the front part, is a shallow round depression, the *fovea hemispherica*, which is perforated

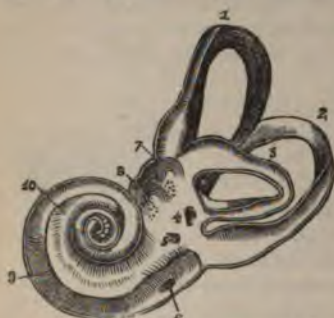

FIG. 304.—OSSEOUS LABYRINTH OF THE RIGHT SIDE (Opened) (Sämmering). (Two and a half times its natural size).

1. The superior semicircular canal. 2. The posterior semicircular canal. 3. The external semicircular canal. 4. Common opening of the superior and posterior semicircular canals. 5. Aquæductus vestibuli. 6. Aquæductus cochleæ. 7. Fovea hemispherica. 8. Fovea hemispherica. 9. Scala tympani. 10. Scala vestibuli.

at its lower by numerous foramina, *macula cribrosa*, for the transmission of the filaments of the auditory nerve. Posteriorly, this pit is bounded by a ridge, the *crista vestibuli*, and in some subjects there is behind this eminence the opening of a small canal, called the *aquæductus vestibuli*. It leads to the posterior surface of the pars petrosa, and transmits a small vein. In the *roof* is a transverse oval depression, the *fovea hemi-elliptica*, which lodges the utricle; *posteriorly*, the five openings of the semicircular canals open into it; and, *in front*, is a large opening through which it communicates with the scala vestibuli of the cochlea.

Semicircular Canals.

The *semicircular canals*, three bony canals, are situated above and rather behind the vestibule. Each canal forms about two-thirds of a circle, is compressed laterally, and is about $\frac{1}{10}$ th of an inch (*1.2 mm.*) in diameter. The canals are not of equal diameter throughout; each presents at one end a dilatation termed the *ampulla*, about $\frac{1}{5}$ th of an inch (*2.4 mm.*) in diameter. This dilatation corresponds to a similar dilatation of the membranous sac, upon which the auditory nerve expands. The canals open at each extremity into the vestibule by five openings, since one of the apertures is common to the extremities of two canals. Each canal differs in its direction; they are named accordingly superior, posterior, and external.

The *superior semicircular canal* (Fig. 304, 1) is the most anterior of the three; its direction is vertical, and runs across the petrous bone. It rises up higher than any other portion of the labyrinth, and its ampulla is at the outer and anterior extremity, and opens into the upper part of the vestibule; its non-ampullated extremity opens by a common orifice with the posterior semicircular canal into the back part of the vestibule.

The *posterior semicircular canal* (Fig. 304, 2) is also vertical, and runs parallel to the posterior surface of the petrous bone, consequently at right angles to the preceding. It is the longest of the

three canals, and its ampullated extremity is at the lower end, opening into the lower and back part of the vestibule. Its upper non-dilated end joins with that of the superior semicircular canal.

The *external semicircular canal* (Fig. 304, 3), is the shortest of the three, is horizontal in position, with the convexity of the arch diverted backwards; it opens by its extremities directly into the back of the vestibule; the ampulla is at the outer end and opens into the vestibule just above the fenestra ovalis.

Cochlea.

The *cochlea* is the most anterior part of the osseous labyrinth; it very closely resembles a common snail's shell, and is placed nearly horizontally, so that its first coil is directed forwards and outwards, and corresponds with the promontory; while its base corresponds to the bottom of the meatus auditorius internus, and is perforated by apertures for the transmission of the cochlear branches of the auditory nerve. The diameter of its base, and also of its height, is about the same, namely, a quarter of an inch (6 mm.). It consists of a gradually tapering spiral tube, which winds round a central pillar, called the *modiolus* or *columella*. The spiral canal is divided into two parallel tubes, *scalæ*, by a delicate lamina, partly bony, partly membranous, which is called the *lamina spiralis*. In the dry condition this partition is only partial; but in the recent state it is completed by a membrane.

The *spiral canal* (Fig. 304, 9, 10) is about an inch and a half (3.8 cm.) long, and about the $\frac{1}{10}$ th of an inch (2.4 mm.) in diameter, lessening as it approaches the summit. After making two turns and a half it terminates at the apex of the cochlea in a rounded dome—the *cupola*. The coil at the base is the widest, the second being a very small one. The canal has in it three openings; thus it communicates with the vestibule by an oval opening; with the tympanum by the fenestra rotunda, but which in the recent state is closed by the *membrana secundaria*; and, lastly, there is the aperture of the *aquæductus cochleæ*, which transmits a small vein from the cochlea to the internal jugular vein.

The *modiolus* or *columella* (Fig.

305, 4) is the central pillar of the cochlea around which the spiral canal coils, and it passes from the base to the apex. It is of considerable thickness at its base, but gradually tapers towards the apex, where at the last half coil it terminates in a half funnel-shaped



FIG. 305.—THE OSSEOUS COCHLEA. (MAGNIFIED FIVE TIMES.)

1. Scala tympani. 2. Scala vestibuli. 3. Lamina spiralis ossea. 4. Modiolus, or central pillar.

curved lamella, called the *infundibulum*. Here the pears, and is called the *helicotrema*, so that the scala cochleæ communicate with each other in this situation of the modiolus is composed of cancellous bone, by numerous canals, which transmit small vessels to the lamina spiralis. One of these canals, larger than the others, runs up the centre of the modiolus nearly to the apex, and is called the *arteria centralis modioli*.

On making a vertical section through the cochlea, it is seen that the spiral canal is divided into three tubes, termed the *scala tympani* (Fig. 306, 1) the lower and largest is the *scala tympani* (Fig. 306, 1) the *scala vestibuli* (Fig. 306, 2), which is subdivided

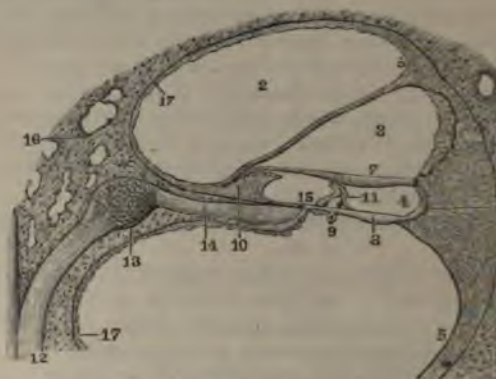


FIG. 306.—SECTION OF THE COCHLEA.

1. Scala tympani. 2. Scala vestibuli. 3. Scala media. 4. Canal of Corti. 5. Membrane of Corti. 6. External spiral groove. 7. Membrane of Corti. 8. Membrane of Corti. 9. Rods of Corti. 10. A branch of the cochlear nerve which after having traversed the spiral ganglion, makes its way to the lamina of the osseous lamina spiralis. 11. One of the foramina by which the canal of Corti penetrates the organ which it forms the margin of the lamina. 12. Periostracum or inner wall of the cochlea. 13. Periostracum or inner wall of the cochlea.

membrane to form an outer or third tube—the *scala media* (Fig. 306, 3).

The *lamina spiralis* (Fig. 305, 3), is the projecting part which divides the spiral canal into two tubes or *scalae*: it is divided into the inner half, of bone—*lamina spiralis ossea*—and the outer half, of membrane—*membrana basilaris* (Fig. 306, 8). The *lamina spiralis ossea* ends at the cupola in a hook-like process—*cupola*. Winding round the modiolus, close to the attachment of the *lamina spiralis ossea*, is a small canal—the *canalis spiralis osseus*—is filled by the gangliform swelling of the cochlear nerve.

ganglion spirale, 13. The osseous lamina spiralis is seen, on a vertical section, to be composed of two plates, between which the structure is spongy; and presents a number of small canals for the passage of the small filaments of the cochlear division of the auditory nerve, in their course to the membranous part of the lamina.

On examining the membranous continuation of the lamina spiralis, it is seen, not far from its attachment to the osseous zone, to be thickened into an elongated crest—the *limbus laminae spiralis* (Fig. 306, 7)—which overhangs a groove, called the *sulcus spiralis* (Fig. 306, 10); the upper horn of the groove is called the *labium vestibulare*; the lower, the *labium tympanicum*. From the labium tympanicum, the *basilar membrane* is continued outwards to be attached to the outer wall of the canal, and thus completes the septum. At the point of attachment of the basilar membrane with the outer wall of the cochlea may be seen a triangular projection, which, formerly described as a muscle (*cochlearis muscle*), is now recognised to be a collection of connective-tissue cells, and called the *ligamentum spirale* (Fig. 306, 5). The structure of the limbus consists of firm connective tissue, on the under part of which are found numerous cells. Close to the junction of the limbus with the basilar membrane are a series of regularly arranged apertures, looking upwards to the sulcus spiralis: these are ovoid apertures for the exit of branches of the cochlear nerve.

The *basilar membrane* forms, at the base of the cochlea, but a small breadth of the septum, the broadest part being composed of bone; but it gradually increases in breadth towards the cupola, where it constitutes nearly the entire septum. It consists of a firm, fibrillated tissue, which is probably formed, at any rate on its upper surface, of a structure closely resembling the organ of Corti.

It has been stated that in the bony cochlea there is a partial septum dividing the spiral tube into two incomplete *scalæ*. In the recent condition the basilar membrane completes the septum dividing the upper tube into an upper canal—the *scala vestibuli*, and a lower, the *scala tympani*. The upper *scala* is subdivided by an oblique membrane, *membrane of Reissner*, into two canals—an inner, the *scala vestibuli*, and an outer, the *canalis cochleæ*, the *scala media* or the *ductus cochlearis* (Fig. 306, 3). The *canalis cochleæ* terminates at the helicotrema in a cul-de-sac; inferiorly, it is connected with the saccule by a long narrow duct called the *canalis reuniens*.

The *membrane of Reissner*, is the oblique membrane which separates the *scala vestibuli* and the *canalis cochleæ*. It is a delicate, almost structureless layer, composed of connective tissue, continuous with the periosteum lining the upper surface of the lamina spiralis. It is smooth on its vestibular surface, and is lined with flattened con-

nective-tissue cells; on its cochlear surface it is covered with squamous epithelium.

The *inner wall* of the canalis cochleæ is formed by the membrane of Reissner covered with pavement epithelium. The *outer wall*, the periosteum, is thickened by a quantity of retiform connective-tissue lined with columnar epithelial cells. An increase of this tissue is seen a little above the ligamentum spirale as a conical eminence, in which runs a small vessel, the *vas spirale*; midway between the vas and the attachment of Reissner's membrane is another thickening, consisting also of numerous blood-vessels, *stria vascularis*, which form anastomosing loops. The lower wall is formed by the limbus spiralis and the basilar membrane; upon the latter is placed the complex structure, called the organ of Corti.

The *organ of Corti*, placed upon the upper surface of the membrana basilaris, presents a slight triangular elevation outside the limbus, and winds spirally throughout the cochlea from its base to its summit. The central part of the organ (Fig. 306, 11) consists of two sets, an inner and an outer, of slanting rods—*rods of Corti*—which rest against each other at their upper extremities, thus forming a triangular tunnel, called the *tunnel of Corti*, filled in the recent state with endolymph. The inner and the outer rods are similar in structure, but differ in shape—the inner are shorter, less oblique, and have the shape of the human ulna, the outer resemble the swan's head, the head being received into the concavity of the inner rod, the part resembling the bill looking horizontally outwards. Both have a broad nucleated base, and present a fibrillar appearance. The inner rods are more numerous than the outer.*

On the inner side of the inner rods is a single row of broad epithelial cells tipped with stiff ciliated processes, called the *inner hair cells*; and on the outer side of the outer rods, resting on cells which are placed on the basilar membrane, are four to six rows of similar cells, termed the *outer hair cells* (307, 0 c). The bases of the outer hair cells present on one side a rounded bulge, while from the other are long processes which pass downwards to be attached to the membrana basilaris. The outer rods are placed upon numerous fusiform nucleated cells, *cells of Deiters*, whose bases rest upon the basilar membrane, and whose summits taper off into fine long cubicular processes, *phalangeal*, which pass between the outer hair cells to be connected to the phalanges of the reticular lamina.

The *lamina reticularis* is the net-like membrane surmounting the summits of the outer hair cells. It is an open network, of a fiddle-shape pattern, consisting of four rows of fiddle-shaped cells termed

* According to Waldeyer, in the proportion of 6,000 of the inner to 4,500 of the outer rods.

phalanges, through which the ciliated processes of the hair cells project. To these phalanges, as before stated, are attached the phalangeal processes of the cells of Deiters.

The *tectorial membrane* (Fig. 307, M T) is the only remaining membrane to be described, and lies above and parallel to the basilar membrane, but does not extend more than half-way over it. It is connected on its inner side with the *limbus spiralis*, and is then

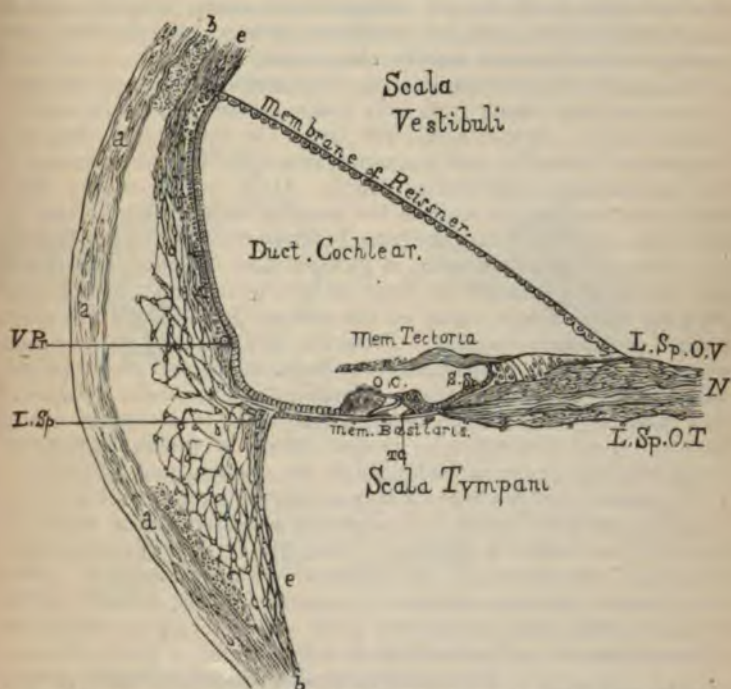


FIG. 307.—VERTICAL SECTION OF THE FIRST TURN OF THE COCHLEA, SHOWING THE MEMBRANOUS COCHLEA AND THE POSITION OF THE ORGAN OF CORTI. (After Waldeyer and Quin.)

continued outwards, overlying and resting upon the rods of Corti; at its origin it is thin, subsequently it thickens, and then gradually tapers off to end in a free extremity. It is a strong, elastic membrane, distinctly fibrous, especially upon its inner and thicker part.

Membranous
Labyrinth.

If the bony labyrinth just described be properly understood, there will not be much difficulty in comprehending the shape of the

membranous labyrinth in its interior—a structure supporting the ultimate ramifications of the auditory nerve. It has the general form and shape of the vestibule and the semicircular canals, although smaller, and it is separated from the osseous labyrinth by a quantity of fluid called *perilymph* or *liquor Cotunnii*, which is secreted by the delicate serous membrane lying in the bony labyrinth.

The membranous labyrinth is a sac, contained partly in the vestibule and partly in the semicircular canals: that situated in the vestibule is termed the *vestibular portion*; that in the bony canals, the *membranous semicircular canals*.

The sac in the vestibule is so constricted as to form two sacs of unequal size, which indirectly communicate with each other.* The *utricle* or *common sinus*, the larger of the two, is oval and compressed laterally, and communicates with the five openings of the membranous semicircular canals. It is lodged in the fovea hemi-elliptica, and its wall is thickest (*macula acustica*) close to the crista vestibuli, where the branches from the auditory nerve enter it. The *sacculæ*, the smaller, is globular and flattened, and lies in the fovea hemispherica, in front of the utricle. It is connected with the membranous canal of the cochlea by a small short duct, termed the *canalis reuniens*. From the sacculæ there passes downwards, along the aquæductus vestibuli, a narrow prolongation, which terminates in a pyriform dilatation, *saccus endolymphaticus*; this canal is joined, at an acute angle, by a short narrow canal from the front of the utricle, so that there is a communication existing throughout the entire length of the membranous labyrinth.

The utricle and the sacculæ contain on their inner wall a minute mass of calcareous matter in connection with nerve-ends, called by Breschet the *otoliths* or *otoconia*. They are crystals of carbonate of lime, and are present in the labyrinth of all mammalia. From their greater hardness and size in aquatic animals, there is reason to believe that they perform the office of rendering the vibrations of sound sharper and more distinct.†

Membranous Semicircular Canals.

The membranous semicircular canals present the same dilatations or ampullæ as the bony ones at one end, and at this part they nearly

* From the utricle there proceeds a small canal, which lies in the aquæductus vestibuli; this is joined close to its commencement by a similar canal from the sacculæ; thus forming the indirect communication above alluded to.

† For a detailed description of the relation of the otoliths with the hair-like processes of the nerve-filaments, the student is referred to an article by Dr. Urean Pritchard in the *Quarterly Journal of Microscopic Science*, October 1876, entitled "The Termination of the Nerves in the Vestibule, and Semicircular Canals of Mammals."

fill their bony cases; but in the rest of their extent the diameter of the membranous canal is not more than one-third to one-fifth that of the bony. At the ampullated extremity the sac is connected on its outer aspect by blood-vessels and nerves to the periosteum, forming on section a transverse projection, called the *septum transversum* or *crista acustica*, which forms a partial septum.

The membranous semicircular canals consist of three layers, an outer or *fibrous layer*, which is connected with the periosteum by blood-vessels, and contains irregular pigment-cells; a middle or *tunica propria*, clear and structureless; and an inner or *epithelial layer*, which lines the inner space of the tunica propria. At the ampullæ the epithelial layer is composed of the columnar variety,

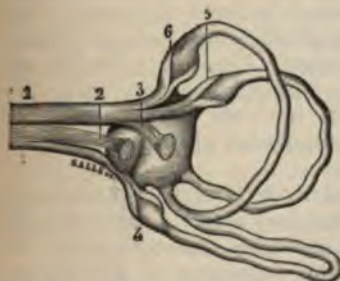


FIG. 308.—DISTRIBUTION OF THE VESTIBULAR BRANCH IN THE MEMBRANOUS LABYRINTH.

1. Vestibular branch of the nerve. 2. Its branch to the saccule. 3. Its branch to the utricle. 4. Utricular branch to the ampulla of the posterior semicircular membrane. 5. Branch to the external semicircular membrane from the vestibular n. 6. Branch from the same to superior membrane.

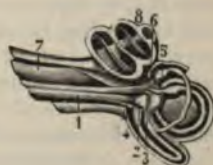

FIG. 309.—THE TWO BRANCHES OF THE AUDITORY NERVE.

1. Vestibular branch. 2. Sacculus branch. 3. Utricular branch. 4. Branch to ampulla of posterior membranous canal. 5. Branch to ampulla of external membrane. 6. Branch to superior membrane. 7. Cochlear branch. 8. Cochlea opened to show the distribution of cochlear nerve.

upon which are arranged cells of a spindle shape, having delicate ciliated processes (*auditory hairs*) projecting into the endolymph.

The membranous labyrinth is protected, inside and out, by fluid. The fluid in the interior is termed the *endolymph* or *liquor Scarpa*, and the thin layer between it and the bone, the *perilymph* or *liquor Cotunnii*; thus the delicate nervous membrane is placed between two layers of fluid.

Distribution of the Auditory Nerve.

The *auditory nerve*, or the eighth cranial nerve, passes down the meatus auditorius internus, and, at the bottom of it, divides into an anterior and posterior branch, which, after breaking up into numerous fasciculi, are distributed to the cochlea and to the vestibule.

The *vestibular nerve* divides into five branches, which proceed to the utricle, the saccule, and the three ampullæ of the semicircular canals, respectively; those for the utricle, and the superior and external semicircular canals enter the vestibule along the crista vestibuli; that for the saccule enters through the fovea hemispherica, and that for the posterior semicircular canal is continued along a bony canal to its termination. The nerves to the semicircular canals enter the ampullæ by a forked swelling which corresponds to each septum transversum.

The *cochlear division* of the auditory nerve is a short, thick branch, which breaks up into numerous filaments at the bottom of the meatus auditorius internus. These enter the canals in the base of the modiolus, and then arch outwards between the plates of the lamina ossea. In their course outwards between the plates, they pass through the spirally arranged ganglionic cord, *ganglion spirale*, beyond which they form a wide plexus. They are collected together close to the free border of the osseous zone, forming a very minute nerve-plexus, whose filaments interlace freely; they then enter the membranous zone to be connected with the inner hair-cells of the organ of Corti.*

The vessels which supply the cochlea are from ten to twelve in number, and are derived from the auditory artery; they, like the nerves, enter the bony canals of the modiolus, and then turn outwards to ramify upon the osseous zone, supplying its periosteum. The plexus formed by these branches communicates with a vessel known as the *vas spirale*, which runs longitudinally in the ligamentum spirale to the outer attachment of the membrana basilaris. The veins from the cochlea terminate in the superior petrosal sinus, having previously joined those of the vestibule and semicircular canals.

* Some anatomists describe filaments as passing between the rods of Corti to end in the outer hair-cells.

DISSECTION OF THE MAMMARY GLAND.

The form, size, position, and other external characters of the mammary gland in the female vary more or less in different persons. The longest diameter of the gland is in a direction upwards and outwards towards the axilla; its thickest part is at the centre, and the fulness and roundness of the gland depend upon the amount of fat about it. Its deep surface is flattened in adaptation to the pectoral muscle, to which it is firmly connected by an abundance of areolar tissue. In its vertical direction the breast corresponds to the space between the third and sixth or seventh ribs; in its lateral direction, to the space between the side of the sternum and the axilla, while the nipple corresponds to the fourth rib, or a little below it.

It is inclosed by a fascia, which not only supports it as a whole, but penetrates into its interior, so as to form a framework for its several lobes; hence, it is that, in cases of mammary abscess, the matter is apt to be circumscribed, not diffused.

The *nipple (mamilla)* projects a little below the centre; it is surrounded by a coloured circle, termed the *areola*; this circle is of a rose-pink colour in virgins, but in those who have borne children of a dark brown. It begins to enlarge and grow darker about the second or third month of pregnancy, and these changes continue till parturition. The areola is abundantly provided with papillæ, and with subcutaneous sebaceous glands, to lubricate the surface during laceration; the areolar, as well as the nipple, is destitute of fat.

Structure.

The gland itself consists of distinct lobes held together by firm connective tissue, and provided with separate lactiferous ducts. Each lobe divides and subdivides into lobules, and the duct branches out accordingly.* Traced to their origin, we find that the ducts commence in clusters of minute cells, and that the blood-vessels ramify minutely upon these cells; altogether, then, a single lobe might be compared to a bunch of grapes, of which the stalk represents the main duct. The main ducts (*galactophorous ducts*) from the several lobes, from fifteen to

* It is observed, in some cases, that one or more lobules run off to a considerable distance from the main body of the gland, and lie embedded in the subcutaneous tissue. This should be remembered when it is necessary to remove the entire gland.

twenty in number, converge towards the nipple, and, just before they reach it, become dilated into small sacs or *ampullae*, two or three lines wide; after this they run up to the apex of the nipple, and, running parallel, terminate in separate orifices.

The vesicles and the galactophorous ducts are lined with columnar epithelium, except at their orifices, where it becomes squamous.

The *arteries* of the gland are derived from the long thoracic, the internal mammary, and the intercostals; the *nerves* come from the anterior and lateral cutaneous branches of the intercostal nerves, and from the descending branches of the cervical plexus. The *veins* diverge from the nipple, and terminate in the axillary and internal mammary veins.

The *lymphatics* run chiefly to the axillary glands, but some pierce the front of the intercostal spaces to join the anterior mediastinal glands.

DISSECTION OF THE SCROTUM AND TESTIS.

The *scrotum* is a pouch of skin for the lodgment of the two testes.

They are originally developed in the abdomen, and descend into the scrotum about the eighth month of intra-uterine life. In their descent they push before them certain coverings derived from the strata of the abdominal walls, through which they pass, and which constitute, with the layers of the scrotum, the coverings of the testes. The scrotum presents in the middle a ridge, the *raphé*, on each side of which it is corrugated into transverse folds or *rugæ*. It is divided by a distinct septum into two lateral halves, of which the left is the longer. The scrotum consists of two layers, the integument and the dartos.

The *integument* is of dark colour, thrown into transverse *rugæ*, and provided with sebaceous glands and hairs.

The *dartos* is a thin layer, consisting of muscular fibres of the involuntary kind, like those of the bladder and intestines. It serves to corrugate the loose and extensible skin of the scrotum, and in a measure to support and brace the testes. It is more abundant in the anterior than in the posterior part of the scrotum. Beneath the dartos, and partly intermingling with it, is a large quantity of loose connective tissue, remarkable for the total absence of fat. Together with the dartos, it forms a vertical partition between the testes, termed the *septum scroti*, which passes from the raphé to the under aspect of the penis, as far as its root. It is not a complete partition, since air or fluid will pass from one side to the other. The great abundance and looseness of this tissue explains the enormous swelling of the scrotum in cases of anasarca, and in cases where urine is extravasated into it in consequence of rupture or ulceration of the urethra.

The coverings of the testes, in addition to these *two layers of the scrotum*, are the *intercolumnar* or *spermatic fascia*, derived from the pillars of the external abdominal ring, the *cremasteric fascia*, derived from the lower border of the internal oblique of the abdomen, the *infundibuliform fascia*, derived from the fascia transversalis, and, lastly, the *tunica vaginalis*, derived from the parietal layer of the peritoneum.

The spermatic fascia, cremaster muscle, and the infundibuliform fascia have been described (pp. 403, 406, 411).

Each of these coverings cannot be demonstrated under ordinary circumstances, because they are so blended together: but they can be shown when hypertrophied in the case of old and large herniæ.

The *arteries* supplying the tissues of the testis are the cremasteric branch of the deep epigastric artery, the superficial and deep external pudic branches of the common femoral artery, and the superficial perineal branch of the internal pudic artery.

The *nerves* are derived from the ilio-inguinal, the genital branch of the genito-crural, the superficial perineal nerves, and the inferior pudendal branch of the lesser sciatic nerve.

The *lymphatics* pass to the inguinal glands.

Testis. The *testis* is a gland of an oval shape with flattened sides, suspended obliquely in the scrotum by the spermatic cord, so that its upper end is directed

forwards and outwards, its lower end in the reverse direction. The left is generally a little lower of the two. Each testis is from an inch and a half to two inches (3.8 to 5 cm.) in length, an inch in breadth (25 mm.), and an inch and a quarter (3.1 cm.) from behind forwards. Its weight is from six to seven drachms (23.2 to 27 gm.), but few organs present greater variations in size and weight, even in men of the same age; generally speaking, the left is the larger. The front and sides of the testis are convex and smooth, and are covered with the visceral layer of the tunica vaginalis; but the posterior surface is only partially invested, as there is here placed a long narrow body, termed the epididymis; this is not a part of the testis, but an appendage to it, formed by the convolutions of its long excretory duct.

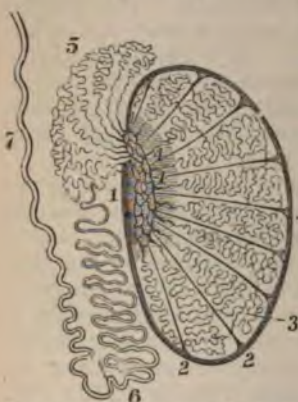

FIG. 310.—DIAGRAM OF A VERTICAL SECTION THROUGH THE TESTICLE.

1. Mediastinum testis, containing the rete testis. 2,2. Trabeculae. 3. One of the lobules. 4,4. Vasa recta. 5. Coni vasculosi, forming the "globus major" of the epididymis. 6. Globus minor, or lower end of the epididymis. 7. Vas deferens.

The *epididymis* consists of a larger upper end called the *globus major* (Fig. 310, 5) and of a lower smaller end, the *globus minor* (Fig. 310, 6), the two being connected together by the *body*. The *globus major* is connected with the testicle by radiating efferent ducts; the *globus minor* is only connected with the organ by connective tissue and the tunica vaginalis. The upper and lower ends and the outer surface of the epididymis are covered with serous membrane, as is also the body, except at its anterior border, where the vessels enter and emerge. Situated between the *globus major* and

the body of the testis are one or two small pedunculated bodies, called the *hydatids of Morgagni*; they are formed by pouchings of the tunica vaginalis, and are filled with blood-vessels bound together by connective tissue.*

A considerable quantity of unstriped muscular tissue exists at the posterior part of the epididymis and testis beneath the infundibuliform fascia, and has been described by Kölliker as the *inner muscular tissue*.

Coverings of the Testicle.

The testicle is invested by three coverings, which are—1. A serous membrane, called the *tunica vaginalis*, to facilitate its movements.

2. A strong fibrous membrane, called the *tunica albuginea*, to support the glandular structure within. 3. A delicate vascular stratum, termed the *tunica vasculosa*, which consists of a layer of minute blood-vessels.

The *tunica vaginalis* is a closed serous sac, one part of which, *tunica vaginalis propria*, adheres closely to the testis; the other, *tunica vaginalis reflexa*, is the reflected portion, adherent to the inner surface of the infundibuliform fascia, and loosely surrounds the testicle. On opening the sac, it will be seen that the *visceral layer* completely covers the testicle, except behind, where the vessels and duct are situated (Fig. 311); and that it covers the outer part of the epididymis in front and behind, forming here a pouch called the *digital fossa*. The *parietal layer* extends upwards for a variable distance upon the cord and below the testicle. The interior of the sac is smooth and polished like all other serous membranes, and lubricated by a little fluid. An excess of this fluid gives rise to the disease termed *hydrocele*.

The portion of the process of peritoneum between the internal abdominal ring and the upper part of the tunica vaginalis testis (the spermatic portion of the tunica vaginalis) becomes, in the process of development, converted into a fibrous cord, which may usually be recognised, but which is sometimes so atrophied as not to be recognised.

The tunica vaginalis testis was originally derived from the peritoneum. In some subjects it still communicates with that cavity by a narrow canal, and is therefore liable to become the sac of a hernia (Fig. 155, p. 418). Such herniæ are called *congenital*—a misleading term, since they do not necessarily take place at birth, but may occur at any period of life, even in very old age.† Sometimes

* The largest which lies upon the top of the testis, is stated to be the vestige of the Müllerian duct.

† It would be a better term to call this lesion a *hernia in the tunica vaginalis*, denoting thereby its anatomical position; at the same time implying a congenital arrest in development, and without limiting its occurrence to any age of life.

the communication continues through a very contracted canal, open to the passage of fluid alone; or the communication may be only partially obliterated, and then one or more isolated serous sacs are left along the cord. Such a one, when distended with fluid, gives rise to *hydrocele of the cord*.

The *tunica albuginea* is a dense, white, inelastic membrane, composed of white fibrous tissue, interlacing in every direction; analogous to the sclerotic coat of the eye. It completely invests the testis, but not the epididymis. It is covered by the visceral layer of the *tunica vaginalis*, except behind and at the attachments of the epididymis. At the posterior part of the gland it penetrates into its substance for a short distance, and forms an incomplete vertical septum, termed after the anatomist who first discovered it, *corpus Highmorianum*, and subsequently by Sir A. Cooper, *mediastinum testis* (Fig. 311, 5).

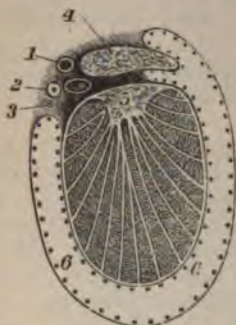

FIG. 311.—TRANSVERSE SECTION THROUGH THE LEFT TESTICLE. (The dots show the reflections of the tunica vaginalis.)

1. Spermatic artery. 2. Vas deferens. 3. Deferential artery. 4. Epididymis. 5. Mediastinum testis. 6. Cavity of tunica vaginalis.

The mediastinum testis transmits the blood-vessels of the organ, and contains also the network of seminal ducts, called the *rete testis*, shown in the diagram (Fig. 310). This septum gives off from its front and sides a number of diverging slender fibrous cords, *trabeculae testis*,* which traverse the interior of the gland, and are attached to the inside of the tunica albuginea.

They serve to maintain the general shape of the testicle, to support the numerous lobules of which its glandular substance is composed, and to convey the blood-vessels into it. These septa, as well as the mediastinum from which they proceed, are readily seen on making a transverse section through the gland (Fig. 311).

The *tunica vasculosa* (*pia mater testis*) consists of a multitude of minute blood-vessels, formed by the ramifications of the spermatic artery, and held together by delicate areolar tissue. It covers the inner surface of the tunica albuginea, and gives off branches, which run with the fibrous septa into the interior of the gland.

Minute structure.—When the testis is cut into, its surfaces become convex, and present a dirty fawn colour. The section is soft and pulpy, and is seen to consist of numerous *lobules*, between

* Kölliker has demonstrated unstriped muscular fibres upon the septa as well as the mediastinum.

two hundred and fifty and four hundred in number,* of various sizes, the central being the larger, and contained in the compartments formed by the fibrous septa proceeding from the mediastinum testis. A few only of these lobules are shown in the diagram. These lobules are conical in shape, their bases being anterior and their apices at the mediastinum, and are bounded by the septa which pass from the mediastinum. They contain two or more minute convoluted tubes, *tubuli seminiferi*, which may be easily unravelled, in consequence of their tough walls. Their number has been estimated to be between 800 and 900, and each has a length of about 18 inches (35 cm.) and a diameter averaging $\frac{1}{140}$ th of an inch ($.3$ mm.). They commence either by communications with other tubes or by cæcal extremities, and they frequently exhibit small bulgings in their course backwards. The walls of the tubuli consist of a *membrana propria*, composed of several layers of flattened cells, and the walls are lined with several irregular layers of cells, between which may, under the microscope, be distinguished seminal filaments in various stages of development. The tubuli seminiferi are connected together by a delicate interstitial tissue, the laminae of which are surrounded by flattened epithelioid cells, and between them are lymph-spaces in direct communication with the lymphatics of the testicle. In this intertubular tissue ramify the minute branches of the spermatic artery which surround the tubules.

After pursuing a convoluted course, the tubules unite in front of the mediastinum into from thirty to fifty straight vessels, *vasa recta*, which penetrate the mediastinum testis, and these form an anastomosing plexus of seminal tubes, called the *rete testis* (Fig. 310). This lies along the back of the gland. From the upper part of the rete, its tubes converge to form twelve to fifteen tubes, termed *vasa efferentia*, which perforate the tunica albuginea, and convey the seminal secretion to the upper part of the epididymis. The *vasa efferentia* are at first straight, but ultimately form a number of coils termed *coni vasculosi*, which collectively constitute the *globus major* of the epididymis. The *coni vasculosi* are about $\frac{1}{50}$ th of an inch (5 mm.) in diameter, and about $\frac{1}{2}$ to $\frac{2}{3}$ of an inch (13 to 17 mm.) long; when unravelled they obtain a length of six to eight inches (15 to 20 cm.).

At the *globus major* the smaller tubes terminate in a single duct, the *canal of the epididymis*, which in its descent describes an extremely tortuous coil, constituting the body and *globus minor* of the epididymis. The length of the canal of the epididymis, is in its natural condition, about three inches (7.5 cm.), but when un-

* The larger estimate is that by Krause; the smaller, that by Berres.

ravelled it is nearly twenty feet (6 m.) in length. The diameter of the canal is about $\frac{1}{10}$ th of an inch (.4 mm.). It is lined with columnar ciliated epithelium.

Vas Deferens. The *vas deferens* begins at the lower part of the globus minor; at first it is somewhat convoluted, but, as it ascends behind the epididymis, it becomes subsequently straight, and joins the other component parts of the cord. After passing through the inguinal canal, it enters the abdomen through the internal ring. It then winds round the outer side of the deep epigastric artery, and, after crossing over the external iliac artery and vein, it enters the pelvis, curves round the side and lower part of the bladder, and empties itself into the prostatic part of the urethra, after running a course of about two feet. Its course in the abdomen has been previously described (p. 491). Its length is two feet (60 cm.) and its diameter $\frac{1}{10}$ th of an inch (2.5 mm.).

In connection with the anterior aspect of the cord, just above the epididymis, are two or three small masses of convoluted tubes, which are known as the *organ of Giraldès*, or the *parepididymis*. They are lined with squamous epithelium, and are probably the remains of part of the Wolffian body.

The *vas aberrans* is a small convoluted tubule, with a cæcal extremity, found between the epididymis and the cord, and communicating usually with the canal of the epididymis. It is about an inch (2.5 cm.) in length, but, when frayed out, varies from two to twelve inches (5 to 30 cm.) in length. It, like the organ of Giraldès, is connected with a fetal structure—the Wolffian body.

The *vas deferens* consists of an external or connective-tissue coat; a middle or muscular coat, composed of longitudinal and circular fibres intermingled with elastic tissue; and an internal or mucous coat, arranged in longitudinal folds, and lined with columnar epithelium. It can always be recognised from the other constituents of the spermatic cord by its hard whipcord-like feel.

Spermatic Cord. The *spermatic cord* begins at the internal ring, traverses the inguinal canal, and extends to the testis, where its component parts pass to their respective destinations. It is composed of the spermatic vessels, nerves, and lymphatics; of the *vas deferens*, with the deferential artery, a branch of the superior vesical; of the cremaster muscle, and the cremasteric artery, a branch of the deep epigastric. The coverings of the cord have been described, with the anatomy of the parts concerned, in inguinal hernia (p. 413).

The *spermatic artery* in its course along the cord becomes remarkably tortuous; it enters the back part of the testicle, and breaks up into a number of fine ramifications, which spread out on the inner surface of the tunica albuginea.

The *spermatic veins* leave the testis at its back part, and, as they ascend along the cord, become extremely tortuous and form a plexus, termed the *pampiniform plexus*. They lie in front of the *vas deferens* and unite to form a single vein, which on the right side opens into the inferior vena cava, and on the left side into the left renal vein. It is usually stated that these veins are destitute of valves; and this fact is adduced as one of the reasons for the occurrence of varicocele. It is, however, certain that the larger veins do contain valves.

The *lymphatics* of the testis pass through the lumbar glands; hence these glands, and not the inguinal, become affected in malignant diseases of the testis.

The *nerves* of the testicle are derived from the sympathetic. They descend from the abdomen with the spermatic arteries, and come from the aortic and renal plexuses, with a few filaments from the hypogastric plexus, which surround the deferential artery (p. 495). This accounts for the ready sympathy of the stomach and intestines with the testicle, and for the constitutional effects of an injury to it.

Descent of the Testis.

The testicle is originally developed in the lumbar region, immediately below the kidney, and is loosely attached to the back of the abdomen by a fold of peritoneum, termed the *mesorchium*, along which its vessels and nerves run up to it, as to any other abdominal viscus. From the lower end of the gland a fibrous cord, termed the *gubernaculum testis*,* proceeds to the bottom of the scrotum. There is no evidence to warrant the assumption that the gradual contraction of the gubernaculum effects the descent of the testis. The organ begins to descend from the lumbar region about the fifth month of foetal life, reaches the internal ring about the seventh, and about the ninth has entered the scrotum. Its original peritoneal coat is retained throughout; but as it enters the inguinal canal the peritoneal lining of the abdomen is pouched out before it, and eventually becomes the *tunica vaginalis reflexa*. Immediately after the descent of the testis its serous bag communicates with the abdomen, and in the lower animals continues to do so throughout life.† But in the human subject the canal of communication soon begins to

* Mr. Curling considers the gubernaculum testis to be a muscular cord. See his "Observations on the Structure of the Gubernaculum, and on the Descent of the Testis in the Fœtus," *Medical Gazette*, April 10, 1841. This is denied by Cleland. See "Mechanism of the Gubernaculum Testis," 1856.

† According to Professor Owen, the African orang outang (*Simia troglodytes*) is the only exception to this rule. In this animal it is interesting to observe that the lower extremities are more fully developed as organs of support, and there is a ligamentum teres in the hip-joint.

close. It closes at the upper extremity first,* and the closure is generally complete in a child born at its full time.† This provides against the occurrence of rupture, to which man, owing to his erect position, is more exposed than animals. At the end of the first month after birth the canal is entirely obliterated from the internal ring to the testis. Sometimes, however, this obliteration fails, or is only partial; hence may arise congenital hernia, or hydrocele. The possible existence of a communication between the tunica vaginalis and the peritoneal cavity of the abdomen is one reason, among many, why caution should be observed in treating hydroceles in children with stimulating injections.

* The frequency of hernia in the funicular portion of the vaginal process of the peritoneum hardly bears this out.

† Camper has shown that the canal on the right side is nearly always open at birth, whereas that on the left is usually closed. This explains the greater frequency of hernia on the right side in children under one year old. Thus out of 3,014 cases of inguinal hernia seen at the City of London Truss Society under one year 2,269 occurred on the right side and 745 on the left; or in the proportion of 3 to 1.





Bones.

Muscles.

Arteries.

Veins.

Nerves.

Viscera.

Peritoneum.

Pericardium.

Pleura.

I have examined the above specimen and report it correct.



EXPLANATION OF BLANK.

The blank on opposite page has been used by the editor with so much success that it is given here as a suggestion to other teachers who do not keep any record of anomalies.

The object of this blank is twofold : first, to obtain a verified record of anomalies ; second, as an educator in preparing the student to put into words what he sees. What is not so well expressed by description may be thoroughly done by a drawing. In recording the number of the table I can inquire of other students on the same body whether any anomalies were present.

A. B. After this is placed the number given to the body by the Anatomical Board, by means of which any history may be traced.

The other points in the blank need no illumination.

The reason Morris's Anatomy is referred to is because the "Variations" are so specifically marked and are more easily found by the student than in any other work.

The rigid examination held after each part has been dissected, has done much to stimulate the student to work carefully and note what he finds.

INDEX.

A.

- Abdomen, dissection of, 395
 parts exposed on opening, 421
 regions of, 395
 superficial fascia of, 397
 surface marking of, 395
 Abdominal muscles, functions of, 409
 ring, external, 403
 internal, 411
 walls, arteries of, 411
 nerves of, 409
 Abducens, nerve, 41, 78, 683
 Accelerator urinæ, 472
 Acervulus cerebri, 699
 Achilles, tendo, 620
 Adami, pomum, 240
 Adductor brevis, 576
 longus, 575, 577
 magnus, 577
 Ala cinerea, 702
 Alimentary canal, anastomoses on, 555
 arterial supply of, 555
 length of, 426
 Ampulla, 424
 Ampulla of semicircular canals, 748
 of rectum, 488
 Amygdala cerebelli, 705
 tonsilli, 235
 Anal glands, 468
 fascia, 486
 Anastomoses, alimentary canal, 555
 Angular artery, 60
 vein, 61
 Ani, sphincter, 469
 levator, 493
 Ankle-joint, ligaments of, 648
 movements of, 650
 Annular ligament of hand, 343
 posterior ligament of forearm, 368
 ligament of ankle, 590
 Annulus ovalis, 205
 Ansa hypoglossi, 102, 125
 Antitragus, 739
 Antihelix, 739
 fossa of, 739
 Aorta, abdominal, 184, 434, 449
 arch, course of, 184
 descending thoracic, 184, 190
 great sinus of, 186
 relations of, 184
 to sternum, 184
 ascending part of, 185
 descending part of, 186
 transverse part of, 186
 Aponeurosis, epicranial, 26
 gluteal, 563
 lumbar, 355
 pharyngeal, 226, 229
 supra-hyoid, 109
 vertebral, 271, 355
 Apparatus ligamentosus colli, 287
 Appendix vermiformis, 423
 Aquæductus cochleæ, 749
 Fallopîi, 64, 263
 Sylvii, 700
 vestibuli, 748
 Arachnoid membrane of brain, 655
 cavity of, 31
 of spinal cord, 711
 Arantius, corpus of, 209
 nodules of, 209
 Arbor vitæ of cerebellum, 706
 uterus, 518
 Arch, crural, 402, 569
 parts passing under, 570
 deep, 414
 Arm, upper, cutaneous nerves of, 294,
 311
 musculo-cutaneous nerve of, 321
 surface marking of, 293, 310
 Arnold's ganglion, 159, 259
 nerve, 30, 160
 Arterial inosculations, 585
 Arteries :—
 acromial thoracic, 297, 304
 alar thoracic, 301, 304
 alveolar, 148

Arteries:—

- anastomotica magna of brachial, 319
femoral, 584
- angular, 60
- anterior cerebral, 657
 - ciliary, 729
 - communicating, 657
 - perforating, of foot, 651
 - peroneal, 625
 - spinal, 659
 - superior cerebellar, 659
 - tibial, 593
- aorta, 184
 - abdominal, 184, 434, 449
 - branches of, 431
 - arch of, 184
 - ascending, 185
 - descending, 186
 - transverse, 186
 - descending thoracic, 190
- articular, of knee, 611
 - of shoulder, 136
- attachment to ventricles, 214
- auditory, 659, 756
- auricular anterior, 141
 - posterior, 27, 123, 141
- axillary, 302
- azygos, 611
- back, 280
- basilar, 658
 - transverse of, 658
- bicipital, 305
- brachial, 317
- brachio-cephalic, 187
- of brain, 657
- bronchial, 200, 224
- buccal, 149
- bulb, 478
- calcanean internal, 626, 631
- capsular, 449, 528
- carotid, common, 96, 98, 188
 - difference between left and right, 100
 - external, 111, 114
 - internal, 44, 157, 264, 657
- carpal of radial, anterior, 332
 - posterior, 332, 377
 - ulnar, anterior, 335
 - posterior, 335, 377
- centralis modiolii, 750
 - retinae, 76, 736
- cerebellar, anterior superior, 659
 - posterior inferior, 659
 - superior, 659

Arteries:—

- cerebral anterior, 264, 657
 - middle, 264, 657
 - posterior, 659
- cervical ascending, 135
 - superficial, 136, 357
 - transverse, 136
- cervicis princeps, 123, 282
 - profunda, 137
- choroid anterior, 264, 657
 - posterior, 659
- ciliary anterior, 76
 - long, 76
 - short, 76
- circle of Willis, 657, 659
- circulus major, 76, 729
 - minor, 76, 729
- circumflex of arm, anterior, 305
 - posterior, 305, 361
 - thigh, external, 584
 - internal, 584
- circumflexa ilii, deep, 412, 457
 - superficial, 398, 557
- coccygeal, 607
- coeliac axis, 435, 436
- colica dextra, 441
 - media, 441
 - sinistra, 441
- comes nervi ischiatici, 607
 - mediani, 338
 - phrenici, 170
- communicating anterior of tibial, 626, 657
 - posterior of tibial, 626
- coronaria ventriculi, 436
- coronary, 187, 212
 - of lip, inferior, 59
 - superior, 59
- corpus cavernosum, 478, 511
- cranial, 123
- cremasteric, 412
- crico-thyroid, 112
- cystic, 437
- deep cervical, 137, 282
 - external pudic, 560
 - palmar arch, 349
 - temporal, 148
- deferential, 495
- dental anterior, 149
 - inferior, 148
 - superior, 149
- digital, of hand, 342
 - toes, 595, 631
- dorsalis hallucis, 595

Arteries:—

- dorsalis indicis, 377
 - linguae, 122
 - pedis, 594
 - pollicis, 377
 - scapulæ, 365
- dorsal interosseous of hand, 377
 - of foot, 594, 595
- dorsal, of penis, 478
- epigastric, deep, 409, 412
 - superficial, 307, 558
- ethmoidal anterior, 76
 - posterior, 76
- external maxillary, 59
- facial, 59, 115
- femoral, 576
 - superficial, 576
 - deep, 583
- frontal, 27, 68, 77
- gastric, 434
- gastro-duodenalis, 436
- gastro-epiploica dextra, 436
 - sinistra, 437
- glandular, 115
- gluteal, 495, 602
 - inferior, 607
- groin, 559
- helicine, 511
- hæmorrhoidal external, 469
 - middle, 496
 - superior, 442
- hepatic, 436, 528
- hyoid inferior, 112
 - superior, 122
- hypogastric, 218, 495
- ileo-colic, 441
- iliac, common, 456
 - external, 457
 - internal, 494
- ilio-lumbar, 494
- inferior coronary, 59
- inferior labial, 59
- infraorbital, 67, 149
- infraspinous, 136, 357
- innominate, 187
- intercostal, 197, 411
 - anterior, 170
 - collateral, 198
 - dorsal of, 198
 - superior, 134, 136
- interlobular, 543
- interosseous, anterior, 338
 - common, of forearm, 335
 - of hand, 338

Arteries:—

- interosseous, posterior, 376
 - recurrent, 376
- intestini tenuis, 441
- labial inferior, 59
 - superior, 59
- lachrymal, 69, 76
- laryngeal, superior, 112
- lateral, of nose, 59
 - sacral, 494
 - spinal, 659
- lingual, 115, 121
- long ciliary, 729
- lumbar, 412, 435
- malleolar, 594
- mammary, internal, 136, 170, 412
- masseteric, 148
- mastoid, 123, 124
- maxillary, external, 59
 - internal, 147
- mediastinal, 170
 - posterior, 200
- meningeal media, 148
 - parva, 38, 148
- meningeal, 38
 - anterior, 38, 264
 - middle, 38, 148
 - posterior, 38, 123, 659
- mental, 68
- mesenteric, inferior, 435, 441
 - superior, 435, 440
- metatarsal, 595
- middle cerebral, 657
 - hemorrhoidal, 496
 - sacral, 452
 - temporal, 141
 - vesical, 495, 503
- muscular to eye, 77
- musculo-phrenic, 171, 412
- mylo-hyoid, 148
- nasal, 77, 150, 270
- nutrient, of femur, 584
 - humerus, 319
 - to tibia, 626
- obturator, 496, 587
 - pubic branch of, 496
- occipital, 27, 122, 282
- oesophageal, 200
 - of gastric, 434
- omental, 438
- ophthalmic, 76, 264
- ovarian, 435, 451, 523
- palatine, ascending, 115, 156
 - descending, 149

Arteries:—

- palmar arch, deep, 349
 - superficial, 340
 - interosseous, 349
- palmaris profunda, 349
- palpebral, inferior, 77
 - superior, 77
- pancreatic, 437
- pancreatico-duodenal, inferior, 441
 - superior, 437, 441
- perforating, of hand, 349
 - foot, 631
 - thigh, 584
 - intercostal, 171
- pericardiac, 170
- perineal, superficial, 469, 470
 - transverse, 471
- plantar, external, 631
 - internal, 630
- peroneal, 625
 - anterior, 625
- petrosal, 38, 148
- pharyngeal, ascending, 124, 158
 - meningeal of, 124
 - pharyngeal branches of, 158
- phrenic, 435, 449
- popliteal, 611, 621
 - articular branches of, 621
 - branches of, 621
- posterior communicating, 657
 - auricular, 27
- profunda inferior, 318
 - superior, 318, 367
- princeps pollicis, 348
- pterygoid, 149
- pterygo-palatine, 149
- pubic, of deep epigastric, 412
 - obturator, 496
- pudic, internal, 478, 497, 607
 - deep external, 500
 - superficial external, 397, 558
- pulmonary, 200, 218
- pyloric, 436
- radial, 331
 - in palm, 348
 - at back of wrist, 377
 - recurrent, 332
- radialis indicis, 348
- ranine, 122
- receptaculi, 44, 264
- rectum of, 489
- renal, 451, 542
 - branches of, 543
- sacral, lateral, 495

Arteries:—

- sacral, middle, 435, 497
- scalp, of, 27
- scapulæ dorsalis, 305
- scapula, posterior, 136, 357
 - supra-, 135, 364
- sciatic, 497, 607
- septum of the, 59, 150
- sigmoid, 442
- spermatic, 435, 451, 765
- spheno-palatine, 150
- spinal anterior, 659
 - lateral, 135
 - posterior, 658, 659
- splenic, 437, 535
- sternal, 170
- sterno-mastoid, inferior, 136, 357
 - middle, 112
 - superior, 123
- stylo-mastoid, 124, 747
- subclavian, left, 130, 188
 - right, 128
 - branches of, 133
- sublingual, 122
- submental, 115
- subscapular, 304, 357
- superficialis volæ, 332
 - colli, 136
- supra-acromial, 136, 364
- supra-orbital, 27, 76
- supra-renal, 449
- supra-scapular, 135, 364
 - subscapular of, 136
- sural, 622
- tarsal, 595
- temporal, 27, 141
 - deep, 148
 - superficial, 27
- testis, of, 763
- thoracica-acromialis, 297, 304
 - alaris, 301, 304
 - longa, 304
 - superior, 297, 304
- thymic, 170
- thyroid axis, 135
 - inferior, 135, 252
 - superior, 112, 252
- tibial, anterior, 593
 - posterior, 625
 - recurrent, 593
- tonsillar, 115
- transverse cervical, 136
 - colli, 136
 - facial, 61

Arteries :—

- transversalis perinei, 471
 - tympanic, 148
 - tympanum, of, 747
 - ulnar, 334
 - anterior recurrent, 334
 - posterior recurrent, 334
 - ulnaris, profunda, 342
 - uterine, 516
 - vaginal, 516, 528
 - vasa brevia, 438
 - vertebral, 134, 282, 657
 - lateral, spinal of, 135, 659
 - posterior meningeal of, 659
 - vesical, inferior, 495, 503
 - middle, 495, 503
 - superior, 495, 503
 - Vidian, 149
- Articulations, acromio-clavicular, 382
- ankle, 648
 - astragalo-calcanean, 650
 - astragalo-scapoid, 650
 - atlo axoid, 288
 - calcaneo-cuboid, 652
 - calcaneo-scapoid, 651
 - carpal, 390
 - carpo metacarpal, 392
 - costo-sternal, 290
 - vertebral, 289
 - elbow, 386
 - hip, 638
 - inter-phalangeal, 393, 394, 654
 - lower-jaw, 291
 - metacarpal, 392
 - metacarpo-phalangeal, 393
 - metatarsal, 653
 - metatarso-phalangeal, 654
 - occipito-atlantal, 287
 - phalangeal, 654
 - pubic, 638
 - radio-carpal, 389
 - radio-ulnar, inferior, 388
 - superior, 387
 - sacro-coccygeal, 636
 - sacro-iliac, 636
 - sacro-vertebral, 635
 - scapulo-clavicular, 382
 - shoulder, 383
 - sterno-clavicular, 380
 - tarsal, 652
 - tarsometatarsal, 653
 - temporo-maxillary, 291
 - tibio-fibular, inferior, 648
 - superior, 647

Arteries :—

- trapezium and thumb, 391
- wrist, 389
- Aryteno-epiglottideus, 249
 - inferior, 252
 - superior, 252
- Aryteno-epiglottidean folds, 243, 244
- Arytenoid cartilages, 242
- Arytenoideus, 249
- Atrium of auricle, 211
- Auditory meatus, external, 740
 - nerve, 41, 684, 755
- Auerbach's plexus, 551
- Aurem attollens, 27
 - atrahens, 27
 - retrahens, 27
- Auricle of ear, 739
- Auricle of heart, right, 205
 - left, 211
 - muscular fibres of, 214
- Auricular appendix, 205, 211
 - artery, anterior, 141
 - posterior, 123
 - great, nerve, 84
- Auricular nerve, 160
 - posterior, 30, 124
 - nerve of pneumogastric, 30
 - vein, 28, 124
- Auriculo-temporal nerve, 30, 142, 153
- Axilla, dissection of, 298
 - boundaries of, 300
- Axillary artery, 302
 - ligature of, 298
 - fascia, 299
 - plexus of nerves, 306
 - vein, 305
- Axis coeliac, 436
 - thyroid, 135
- Azygos artery, 611
 - veins, 191, 192

B.

- Back, arteries of, 280
 - cutaneous nerves of, 349
 - muscles, of, 271, 349
 - nerves of, 279, 349
- Band, ilio-tibial, 563
 - ventricular, 245
 - vocal, 246
- Bartholin, duct of, 120
 - glands of, 481
- Basilic vein, 313
- Bell, nerve of, 310

- Bertini, columns of, 537
 Bichat, fissure of, 693
 Biliary ducts, 529
 Biceps of arm, 314, 384
 thigh, 612
 Bladder, 489
 arteries of, 503
 female, 513
 ligaments of, 465, 483, 486
 nerves of, 504
 position of, 489
 sphincter of, 502
 structure of, 500
 trigone of, 502
 uvula of, 502
 veins of, 504
 Bochdalek, ganglion of, 257
 Brachial artery, 317
 plexus of nerves, 138, 306
 Brachialis anticus, 316
 Brachio cephalic artery, 187
 veins, 182
 Brain, 655
 annectent gyri, 673, 674
 arteries of, 657
 central fissure of, 670
 cornua of, 688
 membranes of, 31, 655
 removal of, 35
 division of, 660
 fissures of, 669, 670
 peculiarities of circulation in, 660
 weight of, 660
 Breasts, 757
 Bronchi, 219
 Bronchial arteries, 200, 224
 lymphatic glands, 201
 Bruch, membrane of, 727
 Brunner's glands, 550
 Buccal fascia, 57
 glands, 58
 Buccinator, 57
 Bucco-pharyngeal fascia, 58
 Burns' ligament, 564
 Bursæ, biceps, near tendon of, 388
 of carpus, 367, 378,
 over knuckles, 367
 olecranon, 367,
 patella, 581
 under coraco-acromial ligament,
 361
 coraco-brachialis, 316
 deltoid, 361
 gastrocnemius, 619
 Bursæ, under gluteus maximus, 599
 medius, 600
 gracilis, 573
 latissimus dorsi, 354
 ligamentum patellæ, 643
 obturator internus, 604
 popliteus, 623
 Sartorius, 572
 semi-membranosus, 615
 subscapularis, 364
 subcutaneous, 366
 teres major, 363
 triceps, 366
 tuberosity of ischium, 469
 C.
 Cæcum, 423
 meso-cæcum, 433
 Calamus scriptorius, 702
 Canal, crural, 569
 femoral, 569
 of Huguier, 154, 747
 Hunter, 582
 inguinal, 413
 of Nück, 466
 Petit, 737
 Schlemm, 725
 Stilling, 37
 Wirsung, 443
 Canaliculus, 50, 53
 Canalis reuniens, 754
 spiralis modioli, 750
 Canals, semicircular, 748
 Canthi, 50
 Capsule, Glisson's, 438
 of Tenon, 69, 79, 720
 Capsules, supra-renal, 429, 543
 Caput gallinaginis, 504
 Cardiac nerves, of pneumogastric, 160,
 195
 sympathetic, 163
 plexus, deep, 201
 superficial, 202
 Carotid artery, common, 96, 98, 188
 ligature of, 100
 difference of left, 100
 external, 111
 branches of, 112
 internal, 44, 157, 264, 657
 curves of, 44
 plexus, 44, 164
 triangles, 93
 Carpal arteries, 377

- Carpus, bursal sac of, 347
 Cartilages, arytenoid, 242
 cornicula laryngis, 243
 cricoid, 241
 cuneiform, 243
 epiglottis, 243
 of larynx, 240
 of nose, 265
 of pinna, 739
 sesamoideæ, 265
 of trachea, 219
 of Wrisberg, 243
 tarsal, 53
 thyroid, 240
 Cartilago triticea, 240
 Caruncula lachrymalis, 50
 Carunculæ myrtiformes, 481
 Cava, vena, inferior, 205
 superior, 184
 Cavernous plexus, 44, 164
 sinus, 36, 41
 structures passing through, 41
 Centrum ovale majus, 686
 Cephalic vein, 298, 313
 Cerebelli, falx, 33
 tentorium, 33
 Cerebellum, 703
 inferior peduncles of, 702
 middle peduncles of, 705
 superior peduncles of, 700
 structure of, 706
 inferior vermiform process, 704
 superior vermiform process, 704
 Cerebral circulation, peculiarities of, 660
 Cerebri, falx, 32
 Cerebro-spinal fluid, 655
 of cord, 711
 Cerebrum, 668
 base of, 676
 crura of, 679
 development of, 707
 hemispheres of, 668
 labium of, 676
 longitudinal fibres of, 668, 705
 peduncular fibres of, 703
 structure of, 702
 transverse fibres of, 703
 ventricles of, 688, 691, 696, 701
 Cervicalis ascendens artery, 135
 profunda, 137
 superficialis, 136
 Cervical fascia, 86
 deep, 86
 Cervical glands, 103
 plexus of nerves, 125
 deep, 125
 superficial, 84
 Cervicis princeps artery, 123
 Cervico-facial nerve, 64
 Chambers of the eye, 736
 Check ligaments, 287
 Chest, surface marking of, 293
 Chorda tympani nerve, 154
 Chordæ tendineæ of ventricles, 207
 vocales, 246
 Willisii, 35
 Choroid arteries, 657
 coat of eye, 725
 plexus, 637, 688, 695
 Chyli receptaculum, 192
 Cilia, 51
 Ciliary arteries, anterior, 76
 long, 76
 short, 76
 muscle, 728
 nerves, long, 75
 processes, 727
 Circular sinus, 37
 Circulation, foetal, 216
 Circulus major and minor, 729
 Circumflex artery, anterior, 305
 posterior, 305, 361
 external, 584
 iliac artery, deep, 412
 superficial, 557
 internal, 584
 nerve, 308, 359
 Clitoris, 480
 erector of, 480
 glans of, 480
 prepuce of, 480
 Coccygeal gland, 452
 Coccygeus, 494
 Cochlea, 749
 canal of, 749
 columella of, 749
 modiolus, 749
 spiral canal, 749
 Collateral circulation after ligature of
 axillary artery, 305
 carotid, 98
 iliac, external, 457
 common, 457
 innominate, 188
 femoral, common, 585
 superficial, 585
 subclavian, 137

- Colon, ascending, 424
 descending, 424
 transverse, 424
 Columns of Bertini, 537
 Columnæ, carneæ, 207
 rugarum, 514
 Complexus, 276
 Communicantes noni nerves, 101, 125
 Commissure, anterior, 698
 great transverse, 686
 middle, 697
 of cord, 713
 of labium, 480
 optic, 682
 posterior, 480, 698
 simplex, 704
 Coni vasculosi testis, 763
 Concha of ear, 739
 Conjunctiva, 51, 719
 Constrictors of pharynx, 227
 Conus arteriosus, 207
 medullaris, 713
 Convolutions, dentate, 677
 frontal, 672
 occipital, 673
 parietal, 672
 temporo-sphenoidal, 674
 uncinate or hippocampal, 677
 Cord, spermatic, 413, 764
 Cornea, 722
 Cornicula laryngis, 243
 Coronary arteries of heart, 212
 inferior, 59
 superior, 59
 plexuses, 203
 Coronary sinus, 212, 213
 Corpora albicantia, 679
 quadrigenina, 699
 Corpus, Arantii, 209
 callosum, 686, 688
 ventricle of, 686
 cavernosum penis, 510
 dentatum cerebelli, 706
 fimbriatum, 688
 geniculatum, 696
 Highmorianum, 762
 luteum of ovary, 522
 spongiosum, 512
 striatum, 688, 693
 Corti, organ of, 752
 rods of, 752
 tunnel of, 752
 Costo-coracoid membrane, 296
 Cotunnii liquor, 754
 Cotunnus, nerve of, 259
 Cotyloid ligament, 640
 Cowper's glands, 477
 structure of, 506
 Cranial nerves, dissection to expose, 38
 exit of, 38
 origin of, 680
 Cremaster muscle, 406
 Cribriform fascia, 558, 565
 Cricoid cartilage, 241
 ligaments of, 241
 Crista, acustica, 755
 galli, 32
 vestibuli, 747
 Crucial anastomosis, 584
 ligaments, 645
 Crural arch, 566
 deep, 569
 canal, 569
 nerve, anterior, 461, 587
 Crusta of crus cerebri, 679
 Crystalline lens, 738
 Cuneiform cartilages, 243
 Cuneus, 675
 Cupola of cochlea, 749
 Cuvier, duct of, 181
 Cystic duct, 439, 531
- D.
- Dartos scroti, 759
 Deglutition, mechanism of, 238
 Deiters, cells of, 752
 Deltoid muscle, 359
 parts covered by, 360
 Demours, membrane of, 725
 Dental artery, inferior, 148
 superior, 149
 nerve, inferior, 153
 Descemet, membrane of, 725
 Descent of testis, 765
 Diaphragm, 445
 arteries of, 447
 central tendon of, 446
 crura of, 445
 functions of, 447
 nerves of, 447
 openings in, 446
 Digastric muscle, 108
 triangle and contents, 108
 Diogenes, cup of, 339
 Dissection of the:
 abdomen, 395
 abdominal viscera, 524

Dissection of the:—

- axilla, 298
 - back, 271
 - muscles of, connected with arm, 349
 - brain, 655
 - to remove, 35
 - cavernous sinus, 41
 - cranial cavity, 31
 - digastric triangle, 108
 - epicranial region, 25
 - eye, 719
 - extremity, lower, 557
 - upper, 293
 - face, 45
 - femoral hernia, 565
 - foot, sole of, 626
 - forearm, back, 367
 - front, 325
 - gluteal region, 598
 - hand, 338
 - hearing, organ of, 739
 - heart, 203
 - inguinal hernia, 414
 - larynx, 239
 - leg, back of, 617
 - front of, 588
 - ligaments, 635
 - mammary gland, 757
 - maxillary nerve, superior, 256
 - neck, 81
 - nose, 265
 - orbit, 67
 - pelvis, side view of, 483
 - viscera of, 461
 - female, 512
 - perineum, male, 465
 - female, 479
 - pharynx, 225
 - pterygoid region, 145
 - scrotum, 759
 - shoulder muscles, 359
 - spinal cord, 708
 - submaxillary triangle, 108
 - supra-clavicular region, 91
 - temporal region, 144
 - testis, 760
 - thorax, 167
 - tongue, 253
- Dorsal nerves, 198
- Douglas, semilunar fold of, 405
 - pouch of, 431
- Ducts, or duct of—
- Bartholin, 120

Ducts, or duct of—

- biliary, 529
 - common bile, 439
 - hepatic, 530
 - Cowper's gland, 477
 - Cuvier, 181
 - cystic, 439, 531
 - galactophorous, 757
 - hepatic, 439
 - nasal, 267
 - pancreatic, 443, 533
 - parotid gland, 63
 - prostate, 504
 - Rivinus, 120
 - Steno's, 63
 - sublingual gland, 120
 - thigh, back of, 611
 - thoracic, 192
 - Wharton's, 154
 - Wirsung, 533
- Ductus arteriosus, 201, 218
- communis, choledochus, 439, 531
 - ejaculatorius, 491
 - venosus, 218,
 - fissure of, 525
- Duodenum, course of, 422
- relations of, 442
- Dura mater, 31
- nerves of, 31
 - partitions of, 32
 - processes of, 31
 - sinuses of, 33
 - spinal cord, 710
- Duverney's glands, 481

E.

- Ear, 739
- muscles, 27
 - intrinsic, 740
- Eighth pair of nerves, 41, 684, 755
- Ejaculatory ducts, 491
- Elbow-joint, 386
- synovial membrane of, 387
 - triangle, 327
 - veins in front of, 312
- Eleventh nerve, 41, 261, 685
- Eminence, hypothernar, 338
- thenar, 338
- Eminentia, cinerea, 702
- collateralis, 689
- Endocardium, 205, 214
- Endolymph of labyrinth, 747, 755
- Ependyma ventriculorum, 688

Epicardium, 214
 Epicranial aponeurosis, 26
 Epididymis, 760
 Epiglottis, 243
 cushion of, 245
 ligaments of, 249
 mucous folds of, 244
 Eustachian tube, 237, 743
 valve, 206
 Eye, 719
 lashes, 51
 lids, 50
 muscles of, 52
 Exit of the cranial nerves, 38

F.

Face, dissection of, 45
 motor nerves of, 45
 sensory nerves of, 48, 66
 Facial artery, 59, 115
 nerve, 41, 86, 262, 683
 on face, 64
 transverse artery, 61
 vein, 61, 111
 Fallopian tubes, 465, 520
 fimbriæ of, 465, 520
 Fallopii aqueductus, 64
 Falx cerebelli, 33
 cerebri, 32
 Fascia, abdominal, 397
 anal, 486
 arm, 295
 forearm, 326
 back of forearm, 368
 axillary, 299
 buccal, 57
 bucco-pharyngeal, 58
 cervical, deep, 86
 costo coracoid, 296
 cremasteric, 406
 cribriform, 558, 565
 iliac, 453
 infundibuliform, 411
 intercolumnar, 403
 intermuscular of arm, 295
 ischio-rectal, 486
 lata of thigh, 562
 lumbar, 272
 metacarpus, 369
 muscular of arm, 314
 obturator, 486
 orbit, 69
 palmar, 339
 pelvic, 484
 perineal, deep, 470
 superficial, 470
 pharyngeal, 226
 plantar, 627
 prevertebral, 87
 psoas, 453
 recto-vesical, 486
 semilunar of biceps, 313
 spermatic, 403
 temporal, 143
 transversalis, 410
 Fasciculi graciles, 664
 teres, 702
 Faucium isthmus, 232
 Femoral artery, 576
 in canal, 582
 sheath of, 568
 ring, 567, 569
 Fenestra ovalis, 743
 rotunda, 743
 Ferrein, pyramids of, 539
 Fibro-cartilages, interarticular, lower
 jaw, 292
 intervertebral, 284
 scapulo-clavicular, 382
 semilunar of knee, 645
 sterno-clavicular, 380
 wrist, 388
 Fifth cranial nerve, 39, 151, 256, 682
 Filium terminale, 712, 713
 Fimbriæ of Fallopian tube, 520
 Fissures, Bichat, 693
 calcarine of brain, 674
 calloso-marginal of brain, 674
 horizontal, 704
 longitudinal, 685
 palpebral, 50
 parieto-occipital, 671
 præcentral, 670
 primary of brain, 669
 Rolando, 670
 Santorini, 739
 sphenoidal, nerves in, 42
 Sylvius, 669
 triradiate, 672
 Flocculus, 705
 Foetal circulation, 216
 changes at birth, 217
 Folds, ary-epiglottic, 244
 glosso-epiglottic, 254
 Houston's, 554
 hepato-renal, 431
 rectal, 554

- Follicles, Graafian, 522
 Fontana, spaces of, 725
 Foot, cutaneous nerve of sole, 632
 Forearm, cutaneous nerve of, 325
 back of, 367
 deep fascia of, 326
 fascia on back of, 368
 Foramen chordæ arterius, 747
 posterius, 747
 cæcum of medulla, 661
 Magendie, 656, 701
 Monro, 692
 ovale of heart, 205, 218
 quadratum, 447
 Thebesius, 206
 Winslow, 432
 Fornix, 691
 conjunctivæ, 51, 719
 crura of, 692
 Fossa, ischio-rectal, 468, 479
 Mohrenheim's, 81
 nasal, 236
 navicularis of labia, 480
 of urethra, 508
 ovalis, 205
 scaphoidea of ear, 739
 Fouchette, 480
 Fourth cranial nerve, 39, 69, 71, 682
 ventricle, 701
 Fovea centralis, of eye, 732
 hemi-elliptica, 748
 hemispherica, 748
 inferior, 702
 superior, 702
 Frænulum, 700
 labiorum, 480
 Frontal artery, 27, 68, 77
 nerve, 70
- G.
- Galactophorous ducts, 757
 Galen, veins of, 695
 Gall-bladder, 530
 duct of, 531
 fissure for, 525
 relations of, 427
 structure of, 530
 Ganglion of Andersch, 157
 Arnold, 159, 259
 Bochdalek, 257
 cardiac, 201
 cervical inferior, 166
 middle, 166
 superior, 164
 Ganglion, diaphragmatic, 447, 459
 Gasserian, 39
 geniculate of facial, 44, 262
 impar, 163, 500
 jugular, 167, 261
 lenticular, 75, 77
 Meckel's, 257
 ophthalmic, 77
 otic, 259
 petrous, 157, 261, 262
 pneumogastric, root of, 159
 160
 trunk, 159, 160, 262
 Ribes, 163
 semilunar, 445, 458
 spheno-palatine, 257
 spirale, 751, 756
 submaxillary, 121
 Wrisberg, 202
 Gasserian ganglion, 39
 Gastrocnemius, 619
 Genito-crural nerve, 460
 Gimbernat's ligament, 403, 566
 Giraldès, organ of, 764
 Glands, agminate, 550
 anal, 468
 Bartholin, 481
 Brunner's, 550
 buccal, 58
 coccygeal, 452
 Cowper's, 477, 506
 Duverney's, 481
 Havers', 641
 lachrymal, 71
 Lieberkühn, 550
 lingual, 254
 Littre, 509
 Luschka, 452
 Meibomian, 51-53
 molar, 58
 muciparous, 232
 parotid, 61
 Peyer, 550
 pineal, 690
 pituitary, 678
 prostate, 492
 sublingual, 120
 submaxillary, 110
 thyroid, 103
 tracheal, 220
 Tyson, 509
 uterine, 520
 lymphatic axillary, 301
 bronchial, 201

- Glands, at elbow, 313
 of heart, 213
 inguinal, 558
 intercostal, 200
 lumbar, 448
 mediastinal, anterior, 171
 neck, deep, 105
 superficial, 84
 popliteal, 611
 submaxillary, 115
 Glandula socia parotidis, 63
 Glandulæ concatenatæ, 105
 Pacchioni, 33
 palatinæ, 238
 Glans clitoridis, 480
 penis, 509
 Glisson's capsule, 526
 Globus major, 760
 minor, 760
 Glosso-epiglottic folds, 243, 244, 254
 Glosso-pharyngeal nerve, 41, 156, 261, 684
 Glottidis rima, 245
 Glottis, 245
 muscles acting on, 250
 Gluteal region, 598
 Gluteus maximus, parts seen under, 599
 nerve, inferior, 602, 607
 superior, 602
 Graafian follicles, 522
 Groin, dissection of, 558
 Gubernaculum testis, 765
 Gyri operi, 670
 Gyrus fornicatus, 675
- H.
- Hamstring muscles, 612-616
 Hamulus of cochlea, 750
 Hand, dissection of palm, 338
 surface marking, 338
 Hasner, valve of, 267
 Havers, gland of, 641
 Heart auricle, left, 211
 right, 205
 cavities, thickness of, 215
 chordæ tendinæ, 207
 endocardium, 205
 fibrous rings of, 213
 lymphatics of, 213
 muscular fibers of, 215
 musculi papillares, 207
 nerves of, 201
 openings, size of, 212
- Heart, position of, 177, 181, 203
 valves of, 208
 veins of, 213
 ventricles, left, 211
 right, 207
 weight of, 204
 Helicotrema, 750
 Helix, 739
 Henle, looped tubes of, in kidney, 539
 Hepatic artery, 436
 duct, 439
 Hernia, congenital, 418
 encysted, 419
 femoral, 565
 coverings of, 570
 seat of stricture, 570
 funicular, 419
 infantile, 419
 inguinal, anatomy of, 414
 changes in old, 419
 direct, 417
 oblique, 416
 position of cord in, 419
 seat of stricture, 419
 tunica vaginalis, 419
 lumbar, 420
 of ovary, 480
 umbilical, 420
 ventral, 420
 Herophili, torcular, 34, 660
 Hesselbach's triangle, 417
 Hey's ligament, 564
 Highmorianum, corpus, 762
 Hilton's muscle, 247
 Hip-joint, movements at, 641
 Hippocampus, major, 690, 694
 minor, 689, 695
 Houston, valves of, 554
 Huguier, canal of, 747
 Humour, aqueous, 736
 vitreous, 736
 Hunter's canal, 582
 Hyaloid membrane, 736
 Hydatids of Morgagni, 761
 Hymen, 480
 varieties of, 480
 Hypogastric plexus, 459
 Hypoglossi ansa, 102, 125
 Hypoglossal nerve, 41, 111, 119, 163, 685
 Hypothena, 338
 Hyoides os, 239
 basi-hyal, 239
 cerato-hyals, 239

- Hyoides, ligaments of, 240**
 thyro-hyals, 239
 I.
- Ileo-cæcal valve, 553**
 artery, 441
- Ileum, course of, 423**
- Iliac artery,**
 common, 456
 external, 457
 internal, 494
 ligature of, 457
 fascia, 453
 veins, 497
- Iliacus, 455**
- Ilio costalis, 275**
 lumbar artery, 412, 435
 tibial band, 563
- Impressio colica, 526**
 renalis, 526
- Incisura cerebelli anterior, 704**
 posterior, 704
- Incus, 745**
- Infra clavicular triangle, 296**
- Infra orbital artery, 67, 149**
 nerve, 67
- Infundibuliform fascia, 411**
- Infundibulum of brain, 703**
 cochlea, 750
 heart, 207
- Inguinal region, 413**
 glands, 558
 hernia, 415
 nerves, 400
- Inion, 25**
- Innominate artery, 187**
 veins, 182
- Interarticular fibro-cartilages (See**
 Fibro-cartilages)
- Intercarotic ganglion, 452**
- Intercolumnar fascia, 403**
- Intercostal arteries, 197, 411**
 anterior, 170
 collateral, 198
 dorsal, 198
 superior, 134, 136
 glands, 200
 muscles, 197
 nerves, 199
- Intercosto-humeral nerves, 299**
- Internal ear, 747**
- Interpleural space, 173**
- Intervertebral fibro-cartilages, 284**
- Intestine, large, course of, 423, 552**
- Intestine, large, relations of, 426**
 structure of, 552
 small, course of, 423, 548
 structure of, 549
- Intumescencia gangliiformis, 262**
- Iris, 728**
 arteries of, 729
 nerves of, 730
 structure of, 728
- Ischio-rectal-fascia, 486**
 fossa, 467
 boundaries of, 479
- Isthmus faucium, 232**
- Iter a tertio ad quartum ventriculum, 697, 700**
 ad infundibulum, 699
- J.
- Jacob's membrane, 734**
- Jacobson, nerve of, 261**
- Jaw, lower, ligaments of, 155**
- Jejunum, course of, 423**
- Joints (See Articulations)**
- Jugular ganglion, 157, 261**
 vein, anterior, 84
 external, 82
 internal, 101
 posterior external, 83
- K.
- Kerkring, valves of, 549**
- Kidneys, 536**
 arteries of, 451, 542
 capsule of, 537
 cortical structure of, 537
 lymphatics of, 543
 medullary structure of, 537
 nerves of, 543
 pyramids of, 537
 situation of, 428, 444
 tubuli uriniferi, 537
 veins of, 452, 544
- Knee-joint, arteries of, 621**
 ligaments of, 642
 movements of, 647
 nerves of, 589
- L.
- Labia majora, 479**
 minora, 480
- Labial arteries, 59**
 nerves, 67, 153

- Labium cerebri**, 676
 tympanicum, 751
 vestibulare, 751
Labyrinth of ear, 747
Lachrymal gland, 71
 nerve, 69, 71
 sac, 53, 267
Lacunæ of urethra, 509
Lacus lachrymalis, 50
Lamina, anterior, of cornea, 724
 posterior, of cornea, 725
 cinerea, 678
 cribrosa, 722
 fusca, 722
 spiralis, 750
 ossea, 750
 supra-choroidea, 726
Laminated tubercle of cerebellum, 704
Lancisi, nerves of, 687
Larynx, 239
 arteries, 252
 cartilages, 240
 cavity, 245
 male and female, 253
 mucous membrane of, 244
 muscles, 248
 nerves, 252
 situation of, 239
 upper opening of, 245
 ventricle of, 247
Laryngotomy, 107
Lateral sinuses, 36
 ventricles, 688
Latissimus dorsi, 308, 354
Lawrence on femoral hernia, 510
Leg, dissection of, back, 617
 front, 588
Lens, crystalline, 738
 capsule of, 738
 structure of, 738
 suspensory ligament of, 738
Lenticular ganglion, 77
Lieberkühn's glands, 550
Ligamenta alaria, 646
 annularia, 346
 vaginalia, 346
Ligaments of:
 accessory of shoulder, 384
 acromio-clavicular, inferior, 382
 superior, 382
 ankle, anterior, 648
 lateral external, 649
 internal, 648
 annular anterior of ankle, 590
 Ligaments of:
 annular external of ankle, 590
 internal of ankle, 590
 carpus anterior, 343
 radius, 388
 posterior of wrist, 368
 anterior carpal, 392
 common, 284
 elbow, 388
 wrist, 393
 arcuate, external, 445
 internal, 445
 calcanean, 650
 astragalo-scapoid, 650
 atlo-axoid, anterior, 288
 posterior, 288
 between occipital bone and
 atlas, 287
 bladder, false, 465, 483
 true, 486
 Burns, 564
 calcaneo-scapoid, 651
 interosseous, 653
 posterior, 651
 calcaneo-cuboid, long, 652
 short, 652
 internal, 652
 superior, 652
 capsular, 286, 289
 carpo-metacarpal, 392
 dorsal, 392
 palmar, 392
 interosseous, 392
 carpus, 390
 central of cord, 712
 check, 287
 ciliary of eye, 728
 Colles', 403
 common, anterior vertebral, 284
 posterior vertebral, 284
 conoid, 383
 coraco-acromial, 383
 clavicular, 383
 humeral, 384
 coracoid, 383
 coronary of knees, 646
 liver, 526
 costo-colic, 431
 clavicular, 381
 sternal, 290
 transverse, 290
 vertebral, 289
 cotyloid, 640
 crico-arytenoid, 242

Ligaments of:

crico-thyroid, 241
 crucial of knee, 645
 cruciata, 346
 cruciform, 288
 deltoid of ankle, 648
 dissection of, 380
 elbow, anterior and posterior, 386
 lateral external, 387
 internal, 387
 falciform of Burns, 564
 liver, 427
 sacro-sciatic, 636
 femoral (Hey's), 564
 gastro-phrenic, 431
 Gimbernat's, 403, 566
 glenoid, 385
 of fingers, 394
 Hey's, 564
 hip, 638
 capsular of, 638
 hyo-epiglottic, 243
 hyoid bone, 239
 ilio-femoral, 639
 lumbar, 635
 incus, 746
 interarticular of ribs, 289
 intercarpal, 391
 interclavicular, 380
 intermetatarsal, 653
 interosseous of cuneiform bones,
 653
 interosseous of forearm, 387
 leg, 648
 tarsus, 650
 interspinous, 284
 intertransverse, 286
 ischio-capsular, 639
 jaw, 291
 internal lateral of, 155
 knee, 642
 latum pulmonis, 171
 long calcaneo-cuboid, 652
 lumbo-sacral, 635
 metacarpal, 392
 metacarpo-phalangeal, 393
 metatarsal, 653
 metatarso-phalangeal, 654
 mucosum of knee, 646
 malleus, 744
 nuchæ, 286
 oblique of radius, 388
 sacro-iliac, 636
 occipito-atloid, 287

Ligaments of:

occipito-axial, 287
 odontoid, 287
 orbicular of radius, 387
 ovary, 465, 521
 palpebral, 52
 palmar, 347, 390
 patella, 580, 642
 phalangeal of hand, 394
 plantar, long, 651
 posterior, common, 284
 of Winslow, 645
 Poupart's, 402, 566
 pterygo-maxillary, 57
 pubic, 638
 sub-pubic, 638
 pubo-femoral, 639
 radio-carpal, 390
 ulnar, 388
 rhomboid, 381
 round of hip, 639
 liver, 427
 radius, 388
 uterus, 414, 465
 sacro coccygeal, 635
 sacro-iliac anterior, 636
 posterior, 636
 oblique, 636
 sacro-sciatic, great, 636
 lesser, 637
 sacro-vertebral, 635
 scapulo clavicular, 382
 shoulder-joint, 384
 spinal, 284
 stellate, 289
 sterno-clavicular, 380
 stylo-hyoid, 156
 stylo-maxillary, 87, 117
 subpubic, 638
 subflava, 284
 supraspinous, 284
 suspensory, of lens, 738
 liver, 426
 penis, 509
 tarso-metatarsal, 653
 tarsus, 650
 temporo-maxillary, 291
 teres of hip, 639
 thyro-arytenoid inferior, 246
 superior, 246
 thyro-epiglottic, 243
 thyro-hyoid, 240
 tibio-fibular inferior, 648
 superior, 647

- Ligaments of:
 transverse, of fingers, 340
 hip, 640
 knee, 646
 metacarpal, 378
 metatarsal, 654
 trapezoid, 383
 triangular of abdomen, 403
 perineum, 470
 urethra, 475
 uterus, 465
 Winslow, 615, 643
 wrist, 389
 Zinn, 52, 79
- Ligamenta subflava, 284
- Ligamentum denticulatum, 713
 mucosum, 646
 nuchæ, 286
 patellæ, 642
 pectinatum iridis, 725
 posticum Winslowii, 643
 spirale, 749
 suspensorium, 287
- Ligula, 702
- Limbus spiralis, 751
- Linea alba, 402, 408
 semilunaris, 405, 408
 splendens, 712
 transverse of fourth ventricle, 687
 rectus, 408
- Linguæ frænum, 253
 dorsalis artery, 122
- Lingual artery, 115, 121
 glands, 254
 nerve, 121
- Lithotomy, parts divided in, 476
 parts to be avoided in, 476
- Littre, glands of, 509
- Liver, situation of, 426, 524
 arteries of, 528
 cells of, 528
 coats of, 526
 ducts of, 529
 fissures of, 524
 functions of, 530
 ligaments of, 526
 lobes of, 526
 lobules of, 526
 lymphatics of, 530
 nerves of, 530
 plexus of, 530
 structure of, 526
 veins of, 527
- Lobule of the ear, 739
- Lobule, paracentral, 672
- Lobulus caudatus, 526
 centralis, 704
 quadratus, 526
 Spigellii, 432
- Locus cæruleus, 702
 niger, 679
 perforatus anticus, 678
 posticus, 679
- Longitudinal sinus, inferior, 36
 superior, 34
- Lower, tubercle of, 207
- Lumbar aponeurosis, 355
 arteries, 435
 fascia, 272
 hernia, 420
 plexus of nerves, 460
- Lumbricales of hand, 348
 foot, 630
- Lungs, 221
 air-cells of, 223
 arteries of, 224
 contractibility, 221
 infundibula of, 223
 lobes of, 176
 lymphatics of, 225
 nerves of, 225
 position and form of, 168, 176
 root of, constituents, 203
 shape of, 221
 structure of, 218, 222
 veins of, 224
- Lunulæ of valves, 210
- Luschka, gland of, 452
- Lymphatics, heart, 213
 intestine, 551
 kidney, 543
 liver, 530
 lung, 225
 pancreas, 533
 parotid gland, 64
 scalp, 30
 spleen, 536
 testis, 765
 uterus, 516
- Lymphatic glands, cervical, deep, 105
 superficial, 84
- Lyra of fornix, 693
- M.
- Macula acustica, 754
 cribrosa, 748

- Macula lutea**, 732
Magendie, foramen of, 656, 701
Malleus, 744
 ligaments of, 746
Malpighi, pyramids of, 537
Malpighian bodies of kidney, 543
 spleen, 536
Mammary gland, 757
 arteries of, 758
 lymphatics of, 756
 internal artery, 136, 170
Mammilla, 757
Marginal convolution, 676
Marshall, vestigial fold of, 213
Maxillary artery, external, 59
 internal, 147
 nerve, inferior, 40, 151
 superior, 40, 256
 vein, 150
Meatus auditorius, externus, 740
 of the nose, 266
 urinarius, female, 480
Meckel's ganglion, 257
Median nerve, 320
 in palm, 345
 vein, 325
Mediastinum, 173
 anterior, 173
 middle, 173
 posterior, 173, 190
 superior, 174
 testis, 762
Medulla oblongata, 661
 anterior pyramid, 662, 664
 fissures of, 661
 grey matter, 666
 lateral tracts of, 662, 665
 nuclei of, 666
 olivary bodies, 662, 665
 fasciculus, 666
 posterior pyramids, 664, 666
 restiform bodies, 663, 665
 structure, 664
 septum of, 666
Medullary-spinal veins, 709
Meibomian glands, 51, 53
Meissner's plexus of nerves, 552
Membrana basilaris, 750
 fusca, 722
 limitans of retina, 734
 nictitans, 50
 papillaris, 731
 sacciformis, 389
 tectoria, 753
Membrana tympani, 744
 arteries of, 744
 flaccida, 744
 secundaria, 749
Membrane, of aqueous humour, 736
 arachnoid of brain, 655
 spinal cord, 711
 Bruch, 727
 choroid, 725
 Corti, 752
 costo-coracoid, 296
 crico-thyroid, 241
 Demours, 725
 Descemet, 725
 hyaloid, 736
 interosseous of forearm, 388
 leg, 648
 Jacob's, 734
 Reissner, 751
 thyro-hyoid, 240
 Schneiderian, 268
Membranes of brain, 31, 655
 spinal cord, 711
Membranous labyrinth, 753
 semicircular canals, 754
Meningeal arteries, 38
 anterior, 38
 middle, 38, 148
 parva, 38
 posterior, 38, 123
 small, 148
Mesenteric artery, inferior, 435, 441
 superior, 435, 440
 veins, inferior, 442
 superior, 441
Mesentery, 433
Meso-colon, ascending, 433
 descending, 433
 transverse, 430, 433
 sigmoid, 433
 rectum, 433, 488
Metencephalon, 706
Mitral valves, 212
Modiolus of cochlea, 749
Mohrenheim's fossa, 81
Molar glands, 58
Monro, foramen of, 692
Mons Veneris, 479
Monticulus cerebelli, 704
Morgagni, sinus of, 228
 hydatids of, 761
Morsus diaboli, 520
Motor oculi nerve, 39, 78
Mouth, muscles of, 46

Movements of spine, 286

Müller, fibres of, 732

Multifidus spinæ, 277

Muscles :—

- abdominal functions of, 409
 - nerves of, 409
- abductor hallucis, 628
 - indicus, 378
- minimi digiti manus, 344
 - pedis, 629
 - pollicis, 343
- accelerator urinæ, 472
- accessorius ad sacro-lumbalem, 275
 - flexor, 630
- adductor brevis femoris, 576
 - hallucis, 633
 - longus, 575, 577
 - magnus, 577
 - pollicis, 344
- anconeus, 373
- antitragicus, 740
- aryteno-epiglottideus, 249
 - inferior, 248, 252
 - superior, 252
- arytenoideus, 249
- attollens aurem, 27
- atrahens aurem, 27
- azygos uvulæ, 232, 235
- back of, 271, 349
- biceps of arm, 314
 - thigh, 613
- biventer cervicis, 276
- brachialis anticus, 316
- brachio-radialis, 331
- buccinator, 57
- cervicalis ascendens, 275
- ciliary, 728
- circumflexus, 233
- coccygeus, 494
- cochlearis, 749
- complexus, 276
- compressor naris, 56
 - sacculi laryngis, 247
 - urethræ, 476
 - in the female, 482
- coraco-brachialis, 316
- corrugator supercilii, 50
- cremaster, 406
- crico-arytenoideus lateralis, 250
 - posticus, 249
- crico-thyroideus, 248
- crureus, 580
- cutaneous, 82
- dartos, 759

Muscles :—

- deltoid, 359
- depressor alæ nasi, 56
 - anguli oris, 46
 - labii inferioris, 47
- diaphragm, 445
- digastricus, 108
- dilatator naris anterior, 56
 - posterior, 56
- ejaculator urinæ, 472
- erector clitorides, 480
 - penis, 473
 - spinæ, 274
- external sphincter ani, 469
- extensor brevis digitorum, 594
 - carpi radialis brevior, 371
 - longior, 371
 - carpi ulnaris, 372
 - communis digitorum, 371
 - indicus, 374
 - longus digitorum pedis, 592
 - minimi digiti, 372
 - ossis met. pollicis, 373
 - primi internodii pollicis, 374
 - secundi internodii pollicis, 374
 - proprius hallucis, 593
 - flexor accessorius, 630
 - brevis digitorum, 629
 - hallucis, 632
 - minimi digiti manus, 344
 - pedis, 634
 - pollicis, 343
 - carpi radialis, 327
 - ulnaris, 329
 - longus digitorum pedis, 623
 - hallucis, 624
 - pollicis, 336
 - profundus digitorum, 336
 - proprius hallucis, 624
 - sublimis digitorum, 329
 - gastrocnemius, 619
 - gemellus inferior, 604
 - superior, 604
 - genio-hyoglossus, 119
 - hyoideus, 118
 - gluteus maximus, 599
 - medius, 600
 - minimus, 601
 - gracilis, 573
 - helicis major, 740
 - minor, 740
 - hyoglossus, 118
 - hyoid region, 97
 - iliacus, 455

Muscles:—

- ilio-costalis, 275
- indicator, 374
- inferior constrictor of pharynx, 224
- infra-hyoid region, 97
- infra spinatus, 363
- intercostal, external, 197
 - internal, 197
- interosseous of foot, 634
 - of hand, 378
 - palmar, 379
- interspinales, 278
- intertransversales, 277
- ischio-cavernosus, 473
- latissimus dorsi, 308, 354
- laxator tympani, 746
- levator anguli oris, 57
 - scapulæ, 356
- ani, 493
 - female, 513
- glandular thyroides, 104
- labii inferioris, 48
 - superioris alæque nasi, 56
 - proprius, 56
- menti, 48
- palati, 233
- palpebræ, 51, 70, 75
- prostatæ, 493
- uvulæ, 235
- levatores costarum, 277
- lingualis, inferior, 255
 - superficial, 255
- longissimus dorsi, 275
- longus colli, 282
- lumbricales manus, 348
 - pedis, 630
- masseter, 143
- of mastication, 143
- middle constrictor of pharynx, 227
- mouth, 46
- multifidus spinæ, 277
- mylo-hyoideus, 115
- nose, of the, 54
- obliquus auris, 740
 - externus abdominis, 400
 - inferior oculi, 70, 80
 - capitis, 278
 - internus abdominis, 404
 - superior oculi, 70, 73
 - capitis, 278
- obturator externus, 605
 - internus, 604
- occipito-frontalis, 26
- opponens digiti minimi, 345

Muscles:—

- opponens pollicis, 343
- orbicularis oris, 46
 - palpebrarum, 48
- omo-hyoid, 90, 94, 356
 - relations of, 95
- palato-glossus, 235
 - pharyngeus, 235
- palmaris brevis, 339
 - longus, 329
- pectineus, 575
- pectoralis major, 295
 - minor, 302
- peroneus brevis, 595
 - longus, 595, 635
 - tertius, 592
- plantaris, 619
- platysma myoides, 81, 82, 294
- popliteus, 622
- prevertebral, 282
- pronator quadratus, 338
 - radii teres, 327
- psaos magnus, 453
 - parvus, 455
- pterygoideus externus, 145
 - internus, 146
- pyramidalis, 408
 - nasi, 55
- pyriformis, 602
- quadratus femoris, 605
 - lumborum, 456
 - menti, 47
- quadriceps femoris, 579
- recti of the eye, 70
- rectus abdominis, 407
 - capitis anticus major, 283
 - minor, 283
 - lateralis, 279
 - posticus major, 278
 - minor, 278
 - externus oculi, 79
 - femoris, 579
 - internus oculi, 79
 - inferior oculi, 79
 - sternalis, 295
 - superior oculi, 74
- retrahens aurem, 27
- rhomboideus major, 356
 - minor, 356
- risorius, 46
- rotatores spinæ, 277
- sacro-lumbalis, 275
 - of Santorini, 46
- sartorius, 572

Muscles :—

- scalenus anticus, 126
- medius, 126
- posticus, 126
- semi-membranosus, 615
- semi spinalis colli, 277
- dorsi, 277
- semi-tendinosus, 613
- serratus magnus, 310, 358
- posticus inferior, 271
- superior, 271
- soleus, 620
- sphincter ani internus, 553
- iris, 729
- vaginæ, 482
- vesicæ, 500
- spinalis dorsi, 276
- splenius capitis, 272
- colli, 272, 276
- stapedius, 746
- sterno-cleido mastoideus, 88
- hyoid, 94
- thyroid, 94
- stylo-glossus, 119, 155
- hyoideus, 109
- pharyngeus, 155
- subanconeus, 366
- subclavius, 297
- subcostal, 197
- subcrureus, 580
- sublimis digitorum, 329
- subscapularis, 310, 364
- superior constrictor of pharynx, 227
- supinator radii brevis, 375
- longus, 331
- supraspinales, 278
- supraspinatus, 364
- temporal, 145
- tensor fasciæ femoris, 577
- palati, 233
- tarsi, 54
- tympani, 746
- teres major, 308, 363
- minor, 363
- thyro-arytenoideus, 250
- epiglottideus, 252
- hyoid, 95
- tibialis anticus, 591
- posticus, 624, 635
- trachelo-mastoid, 275
- tragicus of ear, 740
- transversalis abdominis, 406
- colli, 275

Muscles :—

- transversalis pedis, 634
- transverso-spinalis, 277
- transversus auriculæ, 740
- perinei, 474
- deep, 475
- trapezius, 352
- triangularis sterni, 170
- triceps extensor cubiti, 324, 366
- femoris, 581
- of ureters, 503
- uvulæ azygos, 232, 235
- vastus externus, 580
- internus, 580
- zygomatikus major, 48
- minor, 48
- Musculi papillares, 207, 212
- pectinati, 205, 207
- Musculo-spiral nerve, 324
- musculus ciliaris, 49
- Mylo-hyoid artery, 148
- nerve, 115, 153

N.

- Nabothi ovula, 518
- Nasal fosse, posterior openings, 231
- boundaries, 266
- duct, 267
- muscles, 54
- Nasion, 25
- Naso-lobular nerve, 56, 67, 75
- Nates of brain, 699
- Neck, central line of, 96, 106
- cutaneous nerves of, 84
- dissection of, 81
- lymphatics of, 84
- surface marking of, 81
- triangles of, 90
- anterior, 93
- carotid inferior, 93
- superior, 93
- digastric, 93
- posterior, 91
- submaxillary, 93
- supra-clavicular, 91

Nerves :

- abducens, 41
- abducens oculi, 78, 683
- accessory obturator, 461, 587
- acromial, 86, 294
- anterior crural, 461, 586
- cutaneous of abdomen, 399
- tibial, 597

Nerves:—

- Arnold's, 30, 160
- auditory, 41, 684, 755
- auriculo-parotidean, 85
 - temporal, 29, 142, 153
- auricular branch of pneumogastric, 160
 - posterior, 30, 124
 - great, 84
- axillary, plexus of, 306
- back, cutaneous of, 279, 349
- Bell, nerve of, 310
- brachial plexus, 138, 306
- buccal branch of facial, 66
 - inferior maxillary, 152
- calcaneo-plantar, 626
- cardiac branch of pneumogastric, 160, 195
 - inferior, 166
 - middle, 166,
 - superior, 166
- carotid of glosso-pharyngeal, 157, 259
 - spheno-palatine ganglion, 259
- cauda equinae, 713
- cervical, acromial branch of, 86, 294
 - posterior branches of, 350
 - superficial, 86
 - plexus, deep, 125
- cervico-facial, 64, 66
- chorda tympani, 154, 263, 747
- ciliary, long, 75
 - short, 77
- circumflex, 308, 359, 361
- clavicular, 86, 294
- cochlear, 756
- coccygeal, 280, 498
 - posterior branch of, 350
- communicans noni, 95, 101, 125
- communicans peronei, 597, 609
- cornea, nerves of, 725
- coronary, anterior, 203
 - posterior, 203
- cranial, exit of, 38
 - at base of skull, 261
 - origin of, 680
- crural branch of genito-crural, 461, 562
- cutaneous of chest, 294
 - forearm, 313, 325, 368
 - neck, 84
 - thigh, 461, 588
 - external, 561, 562
 - internal, 562

Nerves:

- cutaneous thigh, middle, 562
- dental, anterior, 256
 - inferior, 153
 - posterior, 256
- descendens noni, 95, 101, 120
- dorsal, 198, 280, 350, 499
- penis, 512
- dura mater, 31
- eighth cranial, 41
 - origin of, 684
- eleventh cranial, 41, 261, 685
- external cutaneous, of musculo-spiral, 365
 - of peroneal, 589
 - of thigh, 416, 561
- laryngeal, 113
- plantar, 632
- popliteal, 597
- respiratory, of Bell, 310
- saphenous, 610, 617
- superficial petrosal, 45, 263
 - facial, 28, 45, 64
 - cervical branch of, 86
 - in skull, 262
 - origin of, 683
- fifth cranial, 39
 - origin of, 682
 - sacral, 497
- first cranial, 38, 264, 680
 - origin of, 680
 - lumbar, 460
- fourth cranial, 39, 69, 71
 - pair, origin of, 682
 - sacral, 469, 497
- frontal, 68, 70
- genital branch of genito-crural, 460, 562
- genito-crural, 460
 - crural branch of, 461, 562
- glosso-pharyngeal, 41, 156, 261
 - carotid branches of, 157, 259
 - lingual branches of, 157
 - origin of, 684
 - pharyngeal branches of, 157
 - tonsillar, 157, 499
- gluteal, inferior, 602, 606
 - superficial, 602
- superior, 499, 602
- great sciatic, 499, 606, 609, 616
 - occipital, 30, 279
- gustatory, 121, 154
- hypoglossal, 41, 119, 163
 - origin of, 685

Nerves:

- ilio-hypogastric, 399, 410, 460
- ilio-inguinal, 400, 410, 460
 - inguinal branch of, 562
- incisor, 153
- inferior dental, 153
 - hæmorrhoidal, 479
 - laryngeal or recurrent, 194
- maxillary, 40, 151
 - puddental, 470
- infra-maxillary of facial, 66
 - orbital of facial, 66
 - of superior maxillary, 67
 - trochlear, 66, 74, 75
- intercostal, 199, 409
 - abdominal, 200
 - anterior cutaneous branches, 294
- intercosto-humeral, 299
 - lateral, cutaneous of, 294
 - pectoral, 199
- internal cutaneous, of arm, 294, 311
 - thigh, 562
 - plantar, 632
 - popliteal, 609
 - branches of, 610
- interosseous anterior, 336
 - posterior, 376
- iris, 730
- Jacobson's or tympanic, 261
- labial, 67, 153
- lacrimal, 69, 71
- Lancisi, 687
- kidney, 543
- laryngeal, external, 113, 160
 - inferior, 162, 195, 251
 - inferior or recurrent, 162
 - internal, 113, 160
 - recurrent, 162, 295, 252
 - superior, 113, 160, 252
- lateral cutaneous, of abdomen, 399
- lesser cutaneous, of arm, 311
- lingual 121, 154
 - of glosso-pharyngeal, 157
- long or inferior pudental, 470, 607
 - saphenous, 587
- longus colli, 140
- liver, 582
- lumbar, 280
 - plexus of, 460
 - posterior branches of, 350
- sympathetic, 458
- lumbo-sacral, 497

Nerves:

- malar branch of superior maxillary, 68, 80
- malar, of facial, 65
- maxillary inferior, 151, 683
 - superior, 256, 683
- median, 320, 335
 - cutaneous branch of, 336
 - digital branches of, 345
 - in the palm, 345
- mental, 68, 153
- masseteric, 151
- motor oculi, 39, 78
 - origin of, 682
- musculo-cutaneous, of arm, 321
 - foot, 597
 - spiral, 324, 325
- mylo-hyoid, 153
 - hyoidean, 115
- nasal, 67, 74
 - septal branch of, 74
 - superior, 259
 - upper, 259
- naso-lobular, 56, 67, 75
 - palatine, 259
- neck, cutaneous of, 84
- nervi molles, 60
- ninth cranial, 41, 261
 - origin of, 684
- noni communicantes, 101, 125
- obturator, 461, 587
 - accessory, 461
 - internus, 498
- occipital, great, 30, 279
 - small, 30, 85
- olfactory, 38, 270
 - origin of, 680
- ophthalmic, 39, 70, 683
- optic, 39, 75
 - origin of, 682
- orbital branch of superior maxillary, 67, 80
 - malar branch of, 63, 80
- ovarian, 523
- palatine, anterior, 258
 - external, 259
 - nasal branches of, 259
 - naso-, 259
 - posterior, 259
- palpebral, 67
- palmar branch of median, 336, 339
 - of ulnar, 336, 339
- pancreas, 533
- pars intermedia, 683

Nerves :

- perineal, 469
- peroneal, 589, 597, 609
 - external cutaneous, branch of, 589
- pes anserinus, 45, 64
- petrosal, external, 263
 - great, 259
 - small, superficial, 44, 261
- pharyngeal, 259
 - of glosso-pharyngeal, 157
 - of pneumogastric, 160
- phrenic, 125, 127
 - in chest, 189
- plantar, external, 632
 - internal, 632
- pneumogastric, 41, 194, 159, 262
 - auricular branch of, 30
 - in the chest, 194
 - course of, 194
 - origin of, 684
- popliteal, external, 589, 597
 - internal, 609
- portio dura, 45, 64, 683
- posterior auricular, 30, 64
 - branches of spinal, 279
 - interosseous, 376
 - scapular, 356
 - tibial, 626
 - thoracic, 310
- pterygoid, 151
- puddendal, inferior or long, 470, 607
- puvic, 479, 499
- pulmonary branches of pneumogastric, 195, 225
- radial, 333, 368
- recurrent or inferior laryngeal, 162, 195
- rhomboid, 140
- sacral, 280, 497
 - fourth, 469
 - plexus, branches of, 498
 - posterior branches of, 350
- saphenous, long, 587, 589
 - short, 610, 617
- scaleni, 140
- scalp, of, 28
- second cranial, 39, 75
 - origin of, 682
 - cervical, 265, 280
- seventh cranial, 41, 64, 262
 - origin of, 683
- shoulder, cutaneous of, 359
- sixth cranial, 41, 78

Nerves :

- sixth cranial, origin of, 683
- small occipital, 30, 85
- sciatic, 499, 606
- superficial petrosal, 44, 261
- in sphenoidal fissure, 42
- spheno-ethmoidal, 76
- spinal accessory, 91, 162, 355
 - origin of, 685
- spinal, posterior branches of, 350
- splanchnic, great, 196
 - lesser, 196
 - smallest, 196
- spleen, 536
- sternal, 86, 294
- subclavius, 139
- suboccipital, 264, 279
 - cutaneous branch of, 30
- subscapular, 307
- superior gluteal, 499, 602
 - maxillary, 40, 256
- supra clavicular, 86, 294
 - maxillary branch of facial, 66
 - orbital, 29, 66, 70
 - scapular, 140, 357, 364
 - trochlear, 29, 66, 70
- sympathetic, abdomen, 458
 - cervical, 163
 - in the chest, 195
 - in the pelvis, 500
- temporal branch of superior maxillary, 30, 68, 81
 - deep anterior, 151
 - posterior, 151
 - branches of facial, 29, 65
 - middle, 151
- temporo-facial, 30, 64
 - malar, 30, 68
- tenth cranial nerve, 41, 159, 194, 261
 - origin of, 684
- testis, 765
- third cranial nerve, 39, 78
 - origin of, 682
- thoracic anterior, 298
 - posterior, 140, 310
- tonsillar of glosso-pharyngeal, 157
- trigeminal, origin of, 682
- trochlear, of orbit, 70, 74, 682
- trochlearis, 39
- tympanic, 261
- twelfth cranial, 41, 119, 163
 - origin of, 685
- ulnar, 323, 335

Nerves:

- ulnar, deep palmar branch of, 349
- dorsal, cutaneous of, 368
- in the palm, 342
- deep, 349
- uterus, 516
- vestibular, 756
- Vidian, 259
- Wrisberg, 300, 311, 366
- Nervi molles, 60
- Nodule of cerebellum, 704
- Nose, arteries of, 59, 265, 270
 - cartilages of, 265
 - dissection of, 265
 - interior of, 266
 - meatus of, 266
 - mucous membrane of, 268
 - muscles of, 54
 - nerves of, 265, 270
 - septum of, 265
 - veins of, 270
- Nück, canal of, 466
- Nymphæ, 480

O.

- Obex, 702
- Obturator artery, 496, 587
 - abnormal, 496
 - externus, 605
 - fascia, 486
 - internus, 604
 - nerve, 461, 587
 - accessory, 461, 587
- Obliquus externus, 400
 - inferior, 70, 80, 278
 - internus, 404
 - superior, 70, 278
- Occipital artery, 27, 122
 - sinus, 38
 - nerve, great, 30, 279
 - small, 30, 85
 - vein, 27, 123
- Occipito-atloid ligaments, 287
 - axial ligaments, 287
 - frontalis, 26
- Odontoid ligaments, 287
- Oculi tendo, 48
 - tutamina, 50
- Esophageal arteries, 200
 - glands, 194
 - plexus, 195
- Esophagus, 193
 - structure of, 194
- Olfactory bulb, 38

- Olfactory cells, 270
 - origin of, 680
 - nerves, 270
- Omentum, gastro-colic, 430, 434
 - hepatic, 430, 434
 - splenic, 431
 - great, 430, 434
 - cavity of, 431
 - lesser, 430
- Openings for aorta in diaphragm, 446
 - vena cava in diaphragm, 447
 - oesophageal in diaphragm, 447
 - of heart, 212
 - upper, of thorax, 169
- Operculum, 670
- Ophthalmic artery, 76
 - ganglion, 77
 - nerve, 39, 70
 - veins, 77
- Optic nerve, 39, 75, 682
- Ora serrata, 731
 - structure of, 736
- Orbicularis oris, 46
 - palpebrarum, 48
- Orbit, dissection of, 67
 - contents of, 70
 - fascia of, 69
 - nerves at back of, 44
 - periosteum of, 68
- Organ of Corti, 752
 - Giraldès, 764
 - Rosenmüller, 523
- Os hyoides, 239
- Ossicula auditus, 744
 - ligaments of, 746
- Ostium abdominale, 520
 - externum of uterus, 520
 - internum of uterus, 520
 - internum of Fallopian tube, 520
- Otic ganglion, 259
 - branches of, 259
- Otoliths, 754
- Ovaries, 521
 - arteries of, 435-451
 - position of, 521
 - structure of, 521
- Oviducts, 521
- Ovula of Naboth, 518
- Ovum, 523

P.

- Pacchionian bodies, 33
- Palate, glands of, 238
 - hard, 238

- Palate**, pillars of, 233
 soft, 232
 muscles of, 233
- Palati circumflexus**, 233
 levator, 233
 tensor, 233
 velum pendulum, 232
- Palatine artery**, ascending, 115
 descending, 149
- Palmar arch**, deep, 349
 superficial, 340
 profunda artery, 349
- Palpebræ**, 51
 cartilages of, 53
 conjunctiva of, 51
- Pampiniform plexus**, 765
- Pancreas**, 532
 duct of, 533
 functions of, 533
 lesser, 533
 lymphatics of, 533
 position of, 428
 relations of, 443
 structure of, 533
 vessels of, 533
- Papilla lachrymalis**, 50
- Papillæ circumvallatæ**, 254
 filiformes, 254
 fungiformes, 254
- Parepididymis**, 764
- Parotid gland**, 61
 duct, 57, 63
 relations of, 62
 structure of, 62
 structures in, 63
- Parotidis glandula socia**, 63
- Parovarium**, 523
- Pars ciliaris retinæ**, 731
- Pecquet**, cistern of, 192
- Pectiniforme**, septum, 511
- Pedis dorsal artery**, 594
- Pelvic fascia**, 484
 female viscera, 512
 male viscera, 486
- Pelvis**, contents of female, 465
 male, 462
 side view of female, 512
 male, 484
- Penis**, 509
 bulb of, 510
 artery of, 511
 cervix of, 509
 corona glandis, 509
 corpus cavernosum, 510
- Penis**, corpus cavernosum, artery of,
 511
 spongiosum, 510, 512
 crus, 510
 dorsal artery of, 511
 erector, 473
 glans, 509
 glandulæ Tysonii, 509
 helicine arteries of, 511
 lymphatics of, 512
 nerves of, 512, 479
 vessels of, 512
- Perforating arteries of thigh**, 584
- Pericardium**, 178
 objects seen on opening, 181
 structure of, 179
 vestigial fold of, 181
- Perilymph**, 754
- Perineum**, female, 479
 male, 465
 boundaries of, 467
 cutaneous nerves of, 469
 raphé of, 467
 tendinous centre of, 470
 triangular ligament of, 475
 parts between, 476
 surgery of, 475
- Perineal arteries**, superficial, 470
 fascia, deep, 470
 superficial, 470
 transverse muscle, 474
 deep muscle, 475
- Peritoneum**, 429
 course of, 430
 lesser cavity of, 431
 parts covered by, 431
 partially by, 431
 uncovered by, 431
 reflections of, 466
- Peroneal artery**, 625
 anterior, 625
 nerve, 589, 597
- Pes anserinus**, 45, 64
- Petit**, canal of, 737
- Petrosal ganglion**, 261
 nerve, lesser, 44, 259
 superficial external, 45
 small, 261
 great, 44, 259
 sinuses, inferior, 37
 superior, 37
- Peyer's glands**, 550
- Pharyngeal aponeurosis**, 226, 229
 artery, ascending, 124, 158

- Pharyngeal fascia, 226
 veins, 124
 venous plexus, 227
 Pharynx, 225
 constrictors of, 227
 mucous membrane of, 230
 openings into, 230
 Phrenic nerve, 125, 127
 in chest, 189
 differences of, 189
 Pia mater of brain, 656
 spinal cord, 712
 Pineal body, 699
 peduncles of, 699
 Pinna of ear, 739
 ligaments of, 740
 structure of, 739
 muscles of, 740
 Pisiform bone, 390
 Pituitary body, 678
 Plantar artery, external, 631
 internal, 630
 nerve, external, 632
 internal, 632
 fascia, 627
 Plantaris, 619
 Platysma myoides, 82
 Plexus of nerves, Auerbach's, 551
 brachial, 138, 306
 cardiac, deep, 201
 superficial, 202
 carotid, 44, 164
 cavernous, 44, 164
 cervical, superficial, 84
 deep, 125
 coeliac, 459
 coronary, anterior, 203
 posterior, 203
 diaphragmatic, 459
 gastric, 459
 gulae, 194
 haemorrhoidal, 500
 hepatic, 459
 hypogastric, 459
 infra-orbital, 66
 lumbar, 460
 Meissner's, 552
 mesenteric, 551
 inferior, 459
 superior, 459
 oesophageal, 159, 194
 ovarian, 459
 pampiniform, 451, 523, 765
 patellar, 589
 pelvic, 500
 pharyngeal, 227
 prostatic, 500
 pterygoid, 150
 pulmonary, 225
 renal, 459
 sacral, 498
 solar, 458
 spermatic, 459
 splenic, 459
 superficial cardiac, 202
 supra-renal, 459
 sympathetic of abdomen, 201
 uterine, 500
 vaginal, 500, 513
 of veins, interlobular, 527
 vesical, 500
 vesico-prostatic, 486
 Pleura, 171
 outlines of, 176
 cavity of, 171
 Plica semilunaris, 50, 719
 Pneumogastric nerve, 41, 159, 262,
 684
 in chest, 194
 ganglia of, 262
 auricular branch of, 30
 Pomum Adami, 240
 Pons hepatis, 525
 Tarini, 679
 Varolii, 667
 Popliteal artery, 611, 621
 nerve, external, 587, 589
 internal, 609
 space, 608
 vein, 611, 622
 Popliteus, 622
 Porus opticus, 722, 731
 Portal fissure, 525
 Portio dura, 45, 64, 683
 mollis, 683
 Pouch of Douglas, 431
 recto-vaginal, 431
 vesical, 463
 Pouches, laryngeal, 247
 Poupart's ligament, 402, 566
 Precordial region, 177
 Prepuce, 510
 Prevertebral muscles, 282
 fascia, 87
 Processus cochleariformis, 743
 Promontory of tympanum, 743
 Proencephalon, 706
 Prostate, 492

- Prostate**, arteries of, 506
 lobes of, 504
 lymphatics of, 506
 nerves of, 506
 position of, 492
 relations of, 492
 sinus of, 504
 structure of, 505
 veins of, 506
Psoas fascia, 453
 magnus, 453
 parvus, 455
Pterygo-palatine artery, 149
 maxillary ligament, 57
 region, 141, 145
Pudendal, inferior, nerve, 470, 607
Pudenda, 479
Pudic artery, internal, 478, 497, 607
 nerve, 479, 499
Pulmonary artery, 200, 218
 nerves of pneumogastric, 195, 225
 valves, 208
Pulmonis hilum, 176
Puncta lachrymalia, 50, 53
Pupil, 728
Pylorus, 545
Pyramid, anterior, of tympanum, 743
 posterior, of tympanum, 743
 cerebellum, 664
- Q.**
- Quadratus lumborum**, 456
- R.**
- Radial artery**, 331
 at back of wrist, 377
 in palm of hand, 348
 nerve, 333, 368
 vein, 313, 325
Ranine artery, 122
 vein, 122
Ranula, 155
Receptaculum chyli, 192, 448
Recess, lateral of fourth ventricle, 701
Recto-vaginal pouch, 466
Recto-vesical fascia, 486
 pouch, 463
Rectum, 425, 553
 ampulla of, 488
 arteries of, 489
 course of, 463
 digital examination of, 488
- Rectum**, folds in, 554
 relations of, 487
Rectus femoris, 579
Region, precordial, 177
Regions of abdomen, 395
Reil, fillet of, 665
 island of, 670
Reissner, membrane of, 751
Restiform bodies, 663, 665
Rete testis, 763
Retina, 731
 arteria centralis of, 76
 cones and rods of, 734
 structure of, 732
Ribs, movements of, 291
Rima glottidis, 245
Ring, abdominal external, 403
 internal, 411
 femoral, 567, 569
 fibrous, of heart, 213
Rivini, notch of, 744
Rivinus, ducts of, 120
Rolando, arciform fibres of, 662, 664
 fissure of, 670
 funiculus of, 663
 tubercle of, 663
Rosenmüller, organ of, 523
Rugæ of vagina, 514
Ruyschiana tunica, 726
- S.**
- Sac, lachrymal**, 53, 267
 of omentum, 434
Sacculæ of vestibule, 754
Sacculus laryngis, 247
Sacro-lumbalis, 275
 iliac articulation, 636
Santorini, cartilages of, 242
 fissures of, 739
 muscle of, 46
Saphena, external vein, 617
 internal vein, 560
Saphenous, external nerve, 610
 opening, 564
 posterior vein, 617
Scala media, 750
 tympani, 750
 vestibuli, 750
Scalp, dissection of, 25
 arteries of, 27
 lymphatics of, 30
 nerves of, 28
 veins of, 28

- Scaleri muscles, 126
 Scapulæ artery, dorsalis, 305
 Scapular artery, posterior, 136, 357
 supra, 135, 364
 vein, posterior, 136
 Scarpa, liquor of, 755
 triangle of, 572
 Schlemm, canal of, 725
 Schneiderian membrane, 268
 Sciatic artery, 497, 607
 nerve, great, 499, 606, 609, 616
 small, 499, 606
 Sclerotic coat of eye, 721
 structure of, 721
 Scrotum, 759
 dartos of, 759
 lymphatics of, 760
 septum of, 759
 vessels of, 760
 Semicircular canals, 748
 Semilunar cartilages of knee, 644
 ganglia, 445, 458
 valves, 208
 Semimembranosus, 615
 Semispinalis colli, 277
 dorsi, 277
 Semitendinosus, 613
 Sensory nerves of face, 66
 Septum, artery of nasal, 59
 auricularum, 205
 lucidum, 691
 narium, 266
 pectiniforme, 511
 scroti, 759
 tongue, 255
 transversum, 755
 ventriculorum, 207
 Serratus magnus, 310, 358
 posticus inferior, 271
 superior, 271
 Seventh cranial nerve, 41, 64, 683
 Sheath, axillary vessels, 297
 femoral vessels, 568
 rectus muscle, 408
 Sheaths for extensor tendons of hand,
 369
 Sheaths for flexor tendons of hand, 346
 Shoulder, cutaneous nerves of, 359
 joint, 384
 movements of, 385
 muscles in relation with, 385
 synovial membrane of, 385
 Sigmoid flexure of colon, 424
 Sinus circularis iridis, 725
 Sinus coronary, 212, 213
 Morgagni, 228
 pocularis, 504
 prostaticus, 504
 venous, cavernous, 36, 41
 circular, 37
 coronary of heart, 212
 dura mater, 33
 lateral, 36
 longitudinal, inferior, 36
 superior, 34
 occipital, 38
 petrosal, inferior, 37
 superior, 37
 straight, 36
 transverse, 37
 venous, 205
 Sinuses, great, of aorta, 186
 Valsalva, 186, 210
 Sixth cranial nerve, 41, 78, 683
 Small intestines, 549
 Socia parotidis, glandula, 63
 Sœmmering, foramen of, 732
 Solar plexus, 458
 Soleus, 620
 Space, interpleural, 173
 popliteal, 608
 subdural, 31
 Spaces of Fontana, 725
 subarachnoid, 655
 Spermatic cord, 413, 764
 arteries of, 413, 764
 lymphatics of, 414
 nerves of, 414
 veins of, 413
 Sphenoidal fissure, structures passing
 through, 42
 Spheno-palatine artery, 150
 ganglion, 257
 branches of, 258
 Spigelii lobulus, 526
 Spinæ rotatores, 277
 Spinal-accessory nerve, 41, 91, 162, 355,
 684
 cord, 708, 713
 arteries of, 718
 central canal of, 716
 fissures of, 714
 functions of, 718
 membranes of, 711
 structure of, 715
 lateral artery from vertebral, 135
 nerves, origin of, 716
 Spine, ligaments of, 284

- Spine, movements of, 286**
Splanchnic nerves, 196
 great, 196
 lesser, 196
 smallest, 196
Spleen, 534
 artery of, 437, 535
 functions of, 536
 lymphatics of, 536
 Malpighian corpuscles of, 536
 nerves of, 536
 omenta of, 534
 pulp of, 535
 relations of, 428
 tunics of, 534
 veins of, 438, 536
Splenium of corpus callosum, 687
Splenius capitis, 272
 colli, 272
Stapedius, 746
Stapes, 746
Stenon's duct, 63
Sterno-mastoid muscle, 88
 artery, middle, 112
 superior, 123
 parts beneath, 97
Stilling, canal of, 757
Stomach, 544
 relations of, 422
 structure of, 545
Straight sinus, 36
Striæ acusticæ, 702
 laterales, 687
 longitudinales, 687
 medullares, 702
Stylo-glossus, 119, 155
 pharyngeus, 155
Stylo-hyoid ligament, 156
 muscle, 109
Stylo-maxillary ligament, 87, 117
Subarachnoid fluid of brain, 655
 of spinal cord, 711
 spaces of, 655
Subclavian artery, left, 130, 188
 right, 128
 ligature of, 131
 triangle, 91
 vein, 138
Subdural space, 31
Sublingual artery, 122
 gland, 120
Suboccipital nerve, 264, 279
 triangle, 278
Submaxillary ganglion, 121
Submaxillary gland, 110
 triangle, 108
Subperitoneal fat, 412
Subscapular artery, 304
 nerves, 307
Subscapularis, 310, 364
Sulci of brain, 669
Sulcus spiralis, 751
Supra clavicular nerves, 91
 triangle, 91
Supra-hyoid aponeurosis, 109
Supra-renal capsules, 543
 arteries of, 544
 nerves, 544
 relations of, 429
 structure of, 544
Supra-orbital artery, 27, 76
 nerve, 29, 66, 70
Supra-scapular artery, 135, 364
 nerve, 140, 364
 vein, 136
Supra-trochlear nerve, 29, 66, 70
Supra-spinales, 278
Supra-spinous ligament, 284
Sylvius, aqueduct of, 700
 fissure of, 669
Sympathetic nerves :
 cervical, 163
 cranial, 164
 lumbar, 458
 nervi molles, 60
 pelvic, 500
 thoracic, 195
Symphysis pubis, 636, 637
 sacro-iliac, 636
- T.**
- Tænia, fourth ventricle, 702**
 hippocampi, 693
Tænia semicircularis, 688, 693
Tarsal cartilages and ligaments, 52
Tarsi, tensor, 54
Tarsus, synovial membranes of, 653
Tectorial membrane, 753
Tegmentum, 679
Tela choroidea, inferior, 657
Temporal artery, 141
 superficial, 27
 deep, 148
 fascia, 143
 muscle, 145
 nerves, deep, 151
 veins, 141

- Temporal veins, superficial, 27
 Temporo-facial nerve, 64
 Temporo-maxillary ligaments, 291
 Tendo Achillis, 620
 palpebrarum, 48
 Tenon, capsule of, 69, 79, 720
 Tenth cranial nerve, 41, 159, 194, 684
 Tentorium cerebelli, 33
 Teres major, 308, 363
 minor, 363
 Testes cerebri, 700
 muliebres, 521
 Testis, 760
 arteries of, 760
 coverings of, 761
 descent of, 765
 gubernaculum, 765
 lymphatics of, 765
 mediastinum, 762
 nerves of, 765
 structure of, 762
 Thalamencephalon, 796
 Thalami optici, 696
 Thebesii foramina, 206
 valve, 206, 213
 veins of, 206, 213
 Theca vertebralis, 713
 Thena, 338
 Third cranial nerve, 39, 78, 682
 Thoracic aorta, 184
 Thoracic artery, alar, 301, 304
 long, 304
 superior, 297, 304
 nerves, anterior, 298
 posterior, 140, 310
 Thoracic duct, 192
 Thoracico-acromialis artery, 297, 304
 Thorax, base of, 169
 dissection of, 167
 osseous measurements, 167
 upper openings of, 169
 Thymus gland, 169
 Thyro-arytenoideus, 250
 Thyro epiglottideus, 252
 Thyro-hyoid, 95
 Thyroid artery, superior, 112
 body, 103
 inferior, 135
 vein, 112
 cartilage, 240
 gland, 103
 isthmus, 103
 arteries of, 104
 lymphatics of, 104
 Thyroid, nerves of, 104
 structure of, 105
 veins of, 104
 Tibial artery, anterior, 593
 posterior, 625
 nerve, anterior, 597
 posterior, 626
 Tibialis anticus, 591
 posticus, 624, 635
 Tomentum cerebri, 656
 Tongue, 118, 253
 arteries of, 255
 dorsum, 253
 foramen cæcum of, 253
 glands beneath, 255
 mucous membrane of, 253
 muscular fibres of, 255
 nerves of, 256
 papillæ of, 253
 raphe of, 253
 septum of, 255
 Tonsillar artery, 115
 Tonsils, 235
 Torcular Herophili, 34, 660
 Trachea, 218
 cartilages of, 219
 elastic tissue, 220
 glands of, 220
 mucous membrane of, 220
 muscular fibres of, 220
 relations of, 218
 Tragus, 739
 Transverse sinus, 37
 Transversalis fascia, 410
 abdominis, 406
 Trapezium of pons Varolii, 667
 Trapezius, 352
 Triangle, carotid inferior, 93
 superior, 93
 digastric, 108
 elbow, 327
 Hesselbach's, 417
 infraclavicular, 296
 neck, anterior, 93
 posterior, 91
 occipital, 91
 Scarpa's, 572
 subclavian, 91
 submaxillary, 93, 108
 suboccipital, 278
 supraclavicular, 91
 Triangular ligament of abdomen, 403
 perineum, 470
 Triangularis sterni, 170

- Triceps extensor cubiti**, 324, 366
 femoris, 581
Tricuspid valves, 208
Trifacial nerve, 39, 682
Trigonum vesicæ, 502
Trochlea of orbit, 70
Trochlearis nerve, 39, 682
Tube, Eustachian, 237, 743
 Fallopian, 465, 520
Tuber annulare, 667
 cinereum, 678
Tubercula quadrigemina, 699
Tuberculum acusticum, 702
Tubes, bronchial, 219
Tunica albuginea, 761
 Ruyschiana, 726
 vaginalis, 761
 vasculosa, 762
Tutamina oculi, 50
Twelfth cranial nerve, 41, 119, 163
Tympani laxator, 746
 membrana, 742
 tensor, 746
Tympanic nerve of facial, 261
 glosso-pharyngeal, 261
Timpanum, 742
 arteries of, 744
Tyson's glands, 509
- U.**
- Ulnar artery**, 334
 nerve, 323, 335
 in palm, 342
 deep, in hand, 349
 veins, 313, 325
Umbilical hernia, 420
Umbilicus, 408
Urachus, 421
Ureter, 491
 course of, 491
 muscles of, 503
 orifices of, 503
 relation of, 444
Urethra. female, 481
 male, 506
 bulbous portion of, 508
 fossa navicularis of, 508
 lacunæ of, 509
 male, membranous part of, 493,
 507
 prostatic portion, 507
 spongy part of, 507
 structure of, 509
- Uterus**, 515
 arbor vitæ of, 518
 arteries of, 516
 cervix of, 515
 glands of, 520
 lymphatics of, 516
 masculinus, 504
 nerves of, 516
 os of, 515
 position of, 465
 round ligament of, 414, 465
 structure of, 516
 veins of, 516
Utricle of vestibule, 754
Utriculus, 504
Uvea, 728
Uvula of bladder, 512
 cerebellum, 704
 palate, 232
Uvulae azygos, 235
- V.**
- Vagina**, 482, 513
 arteries of, 516, 528
 bulb of, 483
 structure of, 514
 venous plexus of, 513
Vagus nerve, 41, 159, 194, 684
Vallecula of cerebellum, 704
 Sylvii, 669
Vallum of tongue, 254
Valsalva, sinuses of, 186, 210
Valve, coronary, 206
 Eustachian, 206
 Hasner, 269
 ilio-cæcal, 553
 Kerkring, 549
 Thebesius, 213
 Vieussens, 700
Valves, cardiac, position of, 181
 aortic, 213
 mitral, 212
 pulmonary, 208
 semilunar, 208
 tricuspid, 208
Valvulae conniventes, 549
Varolii pons, 667
Vas aberrans, 764
 deferens, 414, 491, 764
 spirale, 756
Vastus externus, 580
 internus, 580

Veins :

angular, 61
 auricular, 124
 axillary, 305
 azygos, left upper, 192
 major, 191
 minor, 191
 basilic, 313
 median, 313, 325
 basi-vertebral, 708
 brachial, 320
 brachio-cephalic, 182
 bronchial, 224
 capsular, 449, 528
 cardiac, anterior, 213
 great, 213
 posterior, 213
 cava, inferior, 205, 452
 superior, 184, 205
 cephalic, 298, 313
 median, 313, 325
 circumflex iliac, 413
 coronary, of heart, 213
 of stomach, 438
 dorsal of penis, 478
 dorsi-spinal, 708
 elbow, in front of, 312
 epigastric, 412
 facial, 61, 111
 femoral, 572
 frontal, 27
 of Galen, 37, 695
 gastric, 536
 hæmorrhoidal, 442
 hepatic, 438, 527
 iliac, common, 456
 external, 458
 internal, 497
 inferior cava, 452
 innominate, 182
 intercostal, superior, 136, 189
 interlobular, 527
 intralobular, 527
 jugular anterior, 84
 external, 82
 internal, 101
 posterior external, 83
 kidney, of, 452, 544
 lumbar, 452
 mammary internal, 171
 maxillary internal, 150
 median, 325
 deep, 325
 medullii-spinal, 709

Veins :

meningeal, 38
 meningo-rachidian, 708
 mesenteric inferior, 442
 superior, 441
 nasal, 270
 oblique, of Marshall, 213
 occipital, 123
 ophthalmic, 77
 pharyngeal, 124
 phrenic, 449
 popliteal, 611, 622
 portal, 438
 profunda femoris, 584
 pudic, external, 560
 internal, 497
 radial, 313, 325
 ranine, 122
 rectum, 489
 renal, 451, 543
 sacra media, 452
 saphenous external, 617
 internal, 560
 posterior, 617
 scalp of, 28
 scapular posterior, 136
 supra, 136
 spermatic, 451, 765
 spinal longitudinal anterior, 708
 posterior, 708
 posterior external, 708
 splenic, 438, 536
 subclavian, 138
 sublobular, 527
 supra-orbital, 27
 renal, 449
 scapular, 136
 temporal, 141
 superficial, 27
 Thebesii, 206, 213
 thyroid superior, 112
 tibial posterior, 626
 tympanum of, 747
 ulnar anterior, 313, 325
 posterior, 313, 325
 umbilical, 217
 uterine, 516
 vaginal, 528
 of liver, 528
 vertebral, 135
 Velum interpositum, 657, 695
 medullary anterior, 700
 medullary posterior, 700
 pendulum palati, 232

- Venæ vorticosæ, 726
 Ventral hernia, 420
 Ventricle of brain, fifth, 691
 fourth, 701
 lateral, 688
 third, 696
 Ventricle of heart, left, 211
 right, 207
 muscular fibres of, 215
 Ventricle of larynx, 247
 Ventricular bands, 245
 Vermiform process, inferior, 704
 superior, 704
 Vertebral aponeurosis, 271, 355
 artery, 134, 659
 Vincula tendinum, 347
 Verumontanum, 504
 Vesico-prostatic plexus, 486
 structure of, 506
 vessels of, 506
 Vestibule of ear, 747
 vagina, 480
 Vestigial fold of pericardium, 181
 Vibrissæ, 269
 Vidian artery, 149
 nerve, 259
- Vieussens, valve of, 700
 Villi, 549
 Vocal cords, inferior or true, 246
 superior or false, 246
 bands, 246
- W.
- Wharton's duct, 154
 Willis, circle of, 657, 659
 cords of, 35
 Winslow, foramen of, 432
 posterior ligament of, 643
 Wirsung, canal of, 443
 Wrisberg, cartilages of, 243
 ganglion of, 202
 nerve of, 300, 311
 Wrist-joint, synovial membranes of, 393
 triangular fibro-cartilage of, 388
- Z.
- Zinn, ligament of, 52
 zone of, 737
 Zygomaticus major, 48
 minor, 48



.

BOOKS
FOR
STUDENTS,
INCLUDING THE
? QUIZ-COMPENDS ?

CONTENTS.

	PAGE		PAGE
New Series of Manuals, 2,3,4,5	6	Obstetrics,	10
Anatomy,	6	Pathology, Histology,	11
Biology,	11	Pharmacy,	12
Chemistry,	6	Physical Diagnosis,	11
Children's Diseases,	7	Physiology,	11
Dentistry,	8	Practice of Medicine,	11, 12
Dictionaries,	8, 16	Prescription Books,	12
Eye Diseases,	8	? Quiz-Compend?	14, 15
Electricity,	9	Skin Diseases,	12
Gynæcology,	10	Surgery and Bandaging,	13
Hygiene,	9	Therapeutics,	9
Materia Medica,	9	Urine and Urinary Organs,	13
Medical Jurisprudence,	10	Veneral Diseases,	13
Nervous Diseases,	10		

PUBLISHED BY

P. BLAKISTON, SON & CO.,

Medical Booksellers, Importers and Publishers.

LARGE STOCK OF ALL STUDENTS' BOOKS, AT
THE LOWEST PRICES.

1012 Walnut Street, Philadelphia.

. For sale by all Booksellers, or any book will be sent by mail, postpaid, upon receipt of price. Catalogues of books on all branches of Medicine, Dentistry, Pharmacy, etc., supplied upon application.

GOULD'S }
DICTIONARIES } See Page 16.

"An excellent Series of Manuals."—*Archives of Gynecology.*

A NEW SERIES OF STUDENTS' MANUALS

On the various Branches of Medicine and Surgery.

Can be used by Students of any College.

Price of each, Handsome Cloth, \$3.00. Full Leather, \$3.50

The object of this series is to furnish good manuals for the medical student, that will strike the medium between the compend on one hand and the prolix textbook on the other—to contain all that is necessary for the student, without embarrassing him with a flood of theory and involved statements. They have been prepared by well-known men, who have had large experience as teachers and writers, and who are, therefore, well informed as to the needs of the student.

Their mechanical execution is of the best—good type and paper, handsomely illustrated whenever illustrations are of use, and strongly bound in uniform style.

Each book is sold separately at a remarkably low price, and the immediate success of several of the volumes shows that the series has met with popular favor.

No. 1. SURGERY. 318 Illustrations.

Third Edition.

A Manual of the Practice of Surgery. By WM. J. WALSHAM, M.D., Asst. Surg. to, and Demonstrator of Surg. in, St. Bartholomew's Hospital, London, etc. 318 Illustrations.

Presents the introductory facts in Surgery in clear, precise language, and contains all the latest advances in Pathology, Antiseptics, etc.

"It aims to occupy a position midway between the pretentious manual and the cumbersome System of Surgery, and its general character may be summed up in one word—practical."—*The Medical Bulletin.*

"Walsham, besides being an excellent surgeon, is a teacher in its best sense, and having had very great experience in the preparation of candidates for examination, and their subsequent professional career, may be relied upon to have carried out his work successfully. Without following out in detail his arrangement, which is excellent, we can at once say that his book is an embodiment of modern ideas neatly strung together, with an amount of careful organization well suited to the candidate, and, indeed, to the practitioner."—*British Medical Journal.*

Price of each Book, Cloth, \$3.00; Leather, \$3.50.

No. 2. DISEASES OF WOMEN. 150 Illus.
SECOND EDITION.

The Diseases of Women. Including Diseases of the Bladder and Urethra. By DR. F. WINCKEL, Professor of Gynæcology and Director of the Royal University Clinic for Women, in Munich. Second Edition. Revised and Edited by Theophilus Parvin, M.D., Professor of Obstetrics and Diseases of Women and Children in Jefferson Medical College. 150 Engravings, most of which are original.

"The book will be a valuable one to physicians, and a safe and satisfactory one to put into the hands of students. It is issued in a neat and attractive form, and at a very reasonable price."—*Boston Medical and Surgical Journal*.

No. 3. ANATOMY. Sixth Edition.

311 ILLUSTRATIONS.

HOLDEN'S ANATOMY. A Manual of the Dissections of the Human Body. By JOHN LANGTON, F.R.C.S., Surgeon to, and Lecturer on Anatomy at, St. Bartholomew's Hospital. Carefully Revised by A. HEWSON, M.D., Demonstrator of Anatomy, Jefferson Medical College; Chief of Surgical Clinic, Jefferson Hospital; Mem. Assoc. Amer. Anatomists, etc. 311 Illustrations. This book comes bound in oil-cloth—price \$3.00—as well as in the regular cloth and leather styles.

"The work before us is a brilliant example of the new order of text-books. * * * We would call special attention to the character of the illustrations with which the volume is bountifully furnished."—*American Journal of Medical Sciences*.

No. 4. PHYSIOLOGY. Sixth Edition.

254 ILLUSTRATIONS AND A GLOSSARY.

A Manual of Physiology. By GERALD F. YEO, M.D., F.R.C.S., Professor of Physiology in King's College, London. 254 Illustrations and a Glossary of Terms. Sixth American from last English Edition, revised and improved.

This volume was specially prepared to furnish students with a new text-book of Physiology, elementary so far as to avoid theories which have not borne the test of time and such details of methods as are unnecessary for students in our medical colleges.

"The brief examination I have given it was so favorable that I placed it in the list of text-books recommended in the circular of the University Medical College."—*Prof. Lewis A. Stimson, M.D., 37 East 33d Street, New York.*

Price of each Book, Cloth, \$3.00; Leather, \$3.50.

No. 5. DISEASES OF CHILDREN.

SECOND EDITION.

A Manual. By J. F. GOODHART, M.D., Phys. to the Evelina Hospital for Children; Ass't Phys. to Guy's Hospital, London. Second American Edition. Edited and Rearranged by LOUIS STARR, M.D., Clinical Prof. of Dis. of Children in the Hospital of the Univ. of Pennsylvania, and Physician to the Children's Hospital, Phila. Containing many new Prescriptions, a list of over 50 Formulæ, conforming to the U. S. Pharmacopœia, and Directions for making Artificial Human Milk, for the Artificial Digestion of Milk, etc. Illus.

"A safe and reliable guide, and in many ways admirably adapted to the wants of the student and practitioner."—*American Journal of Medical Science.*

No. 6. MATERIA MEDICA, PHARMACY, PHARMACOLOGY, AND THERAPEUTICS. SECOND EDITION.

A Handbook for Students. By WM. HALE WHITE, M.D., F.R.C.P., etc., Physician to, and Lecturer on Materia Medica, Guy's Hospital; Examiner in Materia Medica, Royal College of Physicians, London, etc. Second Edition. Revised and Enlarged by REYNOLD W. WILCOX, M.A., M.D., Prof. of Clinical Medicine and Therapeutics, New York Post-Graduate Medical School; Ass't Visiting Physician Bellevue Hospital. 661 pages.

"This is a well-arranged, concise, and handy work on materia medica, excellent as a reference manual or as a text-book for students attending lectures on the subject."—*New York Medical Record.*

No. 7. MEDICAL JURISPRUDENCE AND TOXICOLOGY. THIRD EDITION.

By JOHN J. REESE, M.D., Professor of Medical Jurisprudence and Toxicology in the University of Pennsylvania; President of the Medical Jurisprudence Society of Phila.; Third Edition, Revised and Enlarged.

"This admirable text-book."—*Amer. Jour. of Med. Sciences.*

"We lay this volume aside, after a careful perusal of its pages, with the profound impression that it should be in the hands of every doctor and lawyer. It fully meets the wants of all students. . . . He has succeeded in admirably condensing into a handy volume all the essential points."—*Cincinnati Lancet and Clinic.*

Price of each Book, Cloth, \$3.00; Leather, \$3.50.

**No. 8. DISEASES OF THE EYE. 164 Illus.
FOURTH EDITION.**

Diseases of the Eye and their Treatment. A Handbook for Physicians and Students. By HENRY R. SWANZY, A.M., M.B., F.R.C.S.I., Surgeon to the National Eye and Ear Infirmary; Ophthalmic Surgeon to the Adelaide Hospital, Dublin; Examiner in Ophthalmic Surgery in the Royal University of Ireland. Fourth Edition, Thoroughly Revised. 164 Illustrations and a Zephyr Plate for Testing Color Blindness. 518 pages.

"Mr. Swanzy has succeeded in producing the most intellectually conceived and thoroughly executed *résumé* of the science within the limits he has assigned himself. As a 'students' handbook,' small in size and moderate in price, it can hardly be equalled."—*Medical News*.

"A full, clear, and comprehensive statement of Eye Diseases and their treatment, practical and thorough, and we feel fully justified in commending it to our readers. It is written in a clear and forcible style, presenting in a condensed yet comprehensive form current and modern information that will prove alike beneficial to the student and general practitioner."—*Southern Practitioner*.

**No. 9. MENTAL DISEASES.
WITH ILLUSTRATIONS.**

Lectures on Mental Diseases, designed for Medical Students and General Practitioners. By HENRY PUTNAM STEARNS, A.M., M.D., Physician Superintendent at the Hartford Retreat, Lecturer on Mental Diseases in Yale University, New Haven, Conn., Hon. Mem. British Psycho. Asso'n, etc. With Illustrations and a Digest of the Laws of the various States relating to the Commitment and Care of the Insane. 636 pages.

**No. 10. MEDICAL CHEMISTRY.
THIRD EDITION. ILLUSTRATED.**

A Text-Book of Medical and Pharmaceutical Chemistry. By E. H. BARTLEY, M.D., Professor of Chemistry and Toxicology at Long Island College Hospital, Chief Chemist Board of Health, Brooklyn, N. Y., etc. With Glossary and Illustrations. 684 pages.

"It is with pleasure that we notice what is probably the best chemistry for medical students—for its size—now in the market. Prof. Bartley has written the book because he had something to say; and he has said it well."—*The Journal of the American Medical Association, Chicago, Ill.*

Price of each Book, Cloth, \$3.00; Leather, \$3.50.

ANATOMY.

Morris' New Text-Book on Anatomy. *Now Ready.* By ten leading Surgeons and Anatomists, and Edited by Henry Morris, F.R.C.S. 791 Specially Engraved Illustrations, 214 of which are printed in colors. Octavo. 1280 pages.

Price in Cloth, 7.50; Sheep, 8.50; Half Russia, 9.50

*^s Send for Descriptive Circular and Sample Pages.

Macalister's Human Anatomy. 816 Illustrations. A new Text-book for Students and Practitioners, Systematic and Topographical, including the Embryology, Histology, and Morphology of Man. With special reference to the requirements of Practical Surgery and Medicine. With 816 Illustrations, 400 of which are original. Octavo. Cloth, 7.50; Leather, 8.50

Ballou's Veterinary Anatomy and Physiology. Illustrated. By Wm. R. Ballou, M.D., Professor of Equine Anatomy at New York College of Veterinary Surgeons. 29 graphic Illustrations. 12mo. Cloth, 1.00; Interleaved for notes, 1.25

Holden's Dissector. A manual of Dissection of the Human Body. Sixth Edition. Edited by A. Hewson, M.D., Demonstrator of Anatomy at Jefferson Medical College. 311 Illustrations, many of which are new. Oil-cloth, 3.00; Sheep, 3.50

Holden's Human Osteology. Comprising a Description of the Bones, with Colored Delineations of the Attachments of the Muscles. The General and Microscopical Structure of Bone and its Development. With Lithographic Plates and Numerous Illustrations. Seventh Edition. 8vo. Cloth, 6.00

Holden's Landmarks, Medical and Surgical. 4th Ed. Clo., 1.25

Potter's Compend of Anatomy. Fifth Edition. Enlarged. 16 Lithographic Plates. 117 Illustrations. *See page 14.*

Cloth, 1.00; Interleaved for Notes, 1.25

CHEMISTRY.

Barley's Medical and Pharmaceutical Chemistry. Third Edition. Prepared specially for Medical, Pharmaceutical, and Dental Students. 60 Illustrations, Plate of Absorption Spectra, and Glossary. Revised and Enlarged. Cloth, 3.00

Trimble. Practical and Analytical Chemistry. A Course in Chemical Analysis, by Henry Trimble, Prof. of Analytical Chemistry in the Phila. College of Pharmacy. Illustrated. Fourth Edition, Enlarged. 8vo. Cloth, 1.50

Bloxam's Chemistry, Inorganic and Organic, with Experiments. Seventh Edition. 281 Illustrations. Cloth, 4.50; Leather, 5.50

See pages 2 to 5 for list of Students' Manuals.

Chemistry.—Continued.

- Richter's Inorganic Chemistry.** Fourth American, from Sixth German Edition. Translated by Prof. Edgar F. Smith, PH.D. 89 Wood Engravings and Colored Plate of Spectra. Cloth, 2.00
- Richter's Organic Chemistry, or Chemistry of the Carbon Compounds.** Illustrated. Second Edition. Cloth, 4.50
- Symonds. Manual of Chemistry,** for the special use of Medical Students. By BRANDRETH SYMONDS, A.M., M.D., Asst. Physician Roosevelt Hospital, Out-Patient Department; Attending Physician Northwestern Dispensary, New York. Cloth, 2.00
- Leffmann's Compend of Medical Chemistry.** Including Urinary Analysis. Third Edition. Revised.
See page 15. Cloth, 1.00; Interleaved for Notes, 1.25
- Mûter. Practical and Analytical Chemistry.** Fourth Edition. Revised, to meet the requirements of American Medical Colleges, by Prof. C. C. Hamilton. Illustrated. Cloth, 1.25
- Holland. The Urine, Common Poisons, and Milk Analysis, Chemical and Microscopical.** For Laboratory Use. Fourth Edition, Enlarged. Illustrated. Cloth, 1.00
- Woody. Essentials of Chemistry for the Medical Student.** Third Edition. Cloth, 1.25

CHILDREN.

- Goodhart and Starr. The Diseases of Children.** Second Edition. By J. F. Goodhart, M.D., Physician to the Evelina Hospital for Children; Assistant Physician to Guy's Hospital, London. Revised and Edited by Louis Starr, M.D., Clinical Professor of Diseases of Children in the Hospital of the University of Pennsylvania; Physician to the Children's Hospital, Philadelphia. Containing many Prescriptions and Formulæ, conforming to the U. S. Pharmacopœia, Directions for making Artificial Human Milk, for the Artificial Digestion of Milk, etc. Illustrated. Cloth, 3.00; Leather, 3.50
- Hatfield. Diseases of Children.** By M. P. Hatfield, M.D., Professor of Diseases of Children, Chicago Medical College. Colored Plate. 12mo. Cloth, 1.00; Interleaved, 1.25
- Starr. Diseases of the Digestive Organs in Infancy and Childhood.** With chapters on the Investigation of Disease, and on the General Management of Children. By Louis Starr, M.D., Clinical Professor of Diseases of Children in the University of Pennsylvania. Illus. Second Edition. Cloth, 2.25

See pages 14 and 15 for list of Quiz-Compend!

DENTISTRY.

- Fillebrown. *Operative Dentistry*. 330 Illus. Cloth, 2.50
 Flagg's *Plastics and Plastic Filling*. 4th Ed. Cloth, 4.00
 Gorgas. *Dental Medicine*. Fourth Edition. Cloth, 3.50
 Harris. *Principles and Practice of Dentistry*. Including Anatomy, Physiology, Pathology, Therapeutics, Dental Surgery and Mechanism Twelfth Edition. Revised and enlarged by Professor Gorgas. 1028 Illustrations. Cloth, 7.00; Leather, 8.00
 Richardson's *Mechanical Dentistry*. Sixth Edition. By Warren. 600 Illustrations. 8vo. Cloth, 4.50; Leather, 5.50
 Sewill. *Dental Surgery*. 200 Illustrations. 3d Ed. Clo., 3.00
 Taft's *Operative Dentistry*. *Dental Students and Practitioners*. Fourth Edition. 100 Illustrations. Cloth, 4.25; Leather, 5.00
 Talbot. *Irregularities of the Teeth, and their Treatment*. Illustrated. 8vo. Second Edition. Cloth, 3.00
 Tomes' *Dental Anatomy*. Fourth Ed. 235 Illus. Cloth, 4.00
 Tomes' *Dental Surgery*. 3d Edition. 292 Illus. Cloth, 5.00
 Warren. *Compend of Dental Pathology and Dental Medicine*. Illustrated. 2d Ed. Cloth, 1.00; Interleaved, 1.25

DICTIONARIES.

- Gould's *Student's Medical Dictionary*. Containing the Definition and Pronunciation of all words in Medicine, with many useful Tables, etc.
 ½ Dark Leather, 3.25; ½ Mor., Thumb Index, 4.25
 Gould's *Pocket Dictionary*. 12,000 Medical Words Pronounced and Defined. Containing many Tables and an Elaborate Dose List. Thin 64mo.
 Leather, gilt edges, 1.00; with Thumb Index, 1.25
 Harris' *Dictionary of Dentistry*. Fifth Edition. Completely revised by Prof. Gorgas. Cloth, 5.00; Leather, 6.00
 Cleaveland's *Pronouncing Pocket Medical Lexicon*. Small pocket size. Cloth, red edges .75 pocket-book style, 1.00
 Longley's *Pocket Dictionary*. The Student's Medical Lexicon, giving Definition and Pronunciation, with an Appendix giving Abbreviations used in Prescriptions, Metric Scale of Doses, etc. 24mo.
 Cloth, 1.00; pocket-book style, 1.25

EYE.

- Hartridge on *Refraction*. 5th Edition. Illus. Cloth, 2.00
 Swanzy. *Diseases of the Eye and their Treatment*. 176 Illustrations. Fourth Edition. Cloth, 3.00; Leather, 3.50
 Fox and Gould. *Compend of Diseases of the Eye and Refraction*. 2d Ed. Enlarged. 71 Illus. 39 Formulæ.
 Cloth, 1.00; Interleaved for Notes, 1.25

See pages 2 to 5 for list of Students' Manuals.

ELECTRICITY.

- Bigelow. Plain Talks on Medical Electricity. Cloth, 1.00
 Mason's Compend of Medical Electricity. Cloth, 1.00
 Steavenson and Jones. Medical Electricity. A Practical Handbook. Just Ready. Illustrated. 12mo. Cloth, 2.50

HYGIENE.

- Coplin and Bevan. Practical Hygiene. By W. M. L. Coplin, Adjunct Professor of Hygiene, Jefferson Medical College, Philadelphia, and Dr. D. Bevan. Illustrated. Cloth, 4.00
 Parkes' (Ed. A.) Practical Hygiene. Seventh Edition, enlarged. Illustrated. 8vo. Cloth, 4.50
 Parkes' (L. C.) Manual of Hygiene and Public Health. Second Edition. 12mo. Cloth, 2.50
 Wilson's Handbook of Hygiene and Sanitary Science. Seventh Edition. Revised and Illustrated. Cloth, 3.25

MATERIA MEDICA AND THERAPEUTICS.

- Potter's Compend of Materia Medica, Therapeutics, and Prescription Writing. Fifth Edition, revised and improved. See page 15. Cloth, 1.00; Interleaved for Notes, 1.25
 Davis. Essentials of Materia Medica and Prescription Writing. By J. Aubrey Davis, M.D., Demonstrator of Obstetrics and Quiz-Master on Materia Medica, University of Pennsylvania. 12mo. Interleaved. Net, 1.50
 Biddle's Materia Medica. Twelfth Edition. By the late John B. Biddle, M.D. Revised by Clement Biddle, M.D. 8vo. Illustrated. Cloth, 4.25; Leather, 5.00
 Potter. Handbook of Materia Medica, Pharmacy, and Therapeutics. Including Action of Medicines, Special Therapeutics, Pharmacology, etc. By Saml. O. L. Potter, M.D., M.R.C.P. (Lond.), Professor of the Practice of Medicine in Cooper Medical College, San Francisco. Fifth Revised and Enlarged Edition. 800 pages. 8vo. Cloth, 4.00; Leather, 5.00
 Sayre. Organic Materia Medica and Pharmacognosy. A Handbook of Pharmacy and Medicine. By L. E. Sayre, Ph.D., Professor of Pharmacy and Materia Medica, University of Kansas; Member Committee of Revision of U. S. P. 400 Illustrations. 8vo. Nearly Ready.

See pages 14 and 15 for list of Quiz-Compendis

Practice:—Continued.

Hughes. Compend of the Practice of Medicine. 5th Edition, Enlarged.

Two parts, each, Cloth, 1.00; Interleaved for Notes, 1.25

PART I.—Continued, Eruptive and Periodical Fevers, Diseases of the Stomach, Intestines, Peritoneum, Biliary Passages, Liver, Kidneys, etc., and General Diseases, etc.

PART II.—Diseases of the Respiratory System, Circulatory System, and Nervous System; Diseases of the Blood, etc.

Physicians' Edition. Fifth Edition. Including a Section on Skin Diseases. With Index. 2 vol. Full Morocco, Gilt, 2.50

From John A. Robinson, M.D., Assistant to Chair of Clinical Medicine, now Lecturer on Materia Medica, Rush Medical College, Chicago.

"Meets with my hearty approbation as a substitute for the ordinary note books almost universally used by medical students. It is concise, accurate, well arranged, and lucid, . . . just the thing for students to use while studying physical diagnosis and the more practical departments of medicine."

Wythe's Dose and Symptom Book. Containing the Doses and Uses of all the principal Articles of the Materia Medica, etc. Seventeenth Edition. Completely Revised and Rewritten. 32mo. Cloth, 1.00; Pocket-book style, 1.25

PHARMACY.

Bartley. Medical and Pharmaceutical Chemistry. Third Edition. Cloth, 3.00; Leather, 3.50

Coblentz. Manual of Pharmacy. Illustrated. By Virgil Coblentz, PH.D., Professor of Theory and Practice of Pharmacy, College of Pharmacy of City of New York. Octavo. 500 pages. Cloth, 4.00

U. S. Pharmacopœia, 1890, 7th Revision. Cloth, net, 2.50; Sheep, net, 3.00. (Add 27 cents if to go by mail.)

Sayre. Organic Materia Medica and Pharmacognosy. 400 Illustrations. See page 0. *Nearly Ready.*

Stewart's Compend of Pharmacy. Based upon Remington's Text-book of Pharmacy. Fourth Edition, Revised in accordance with new U. S. P., 1890. Cloth, 1.00; Interleaved for Notes, 1.25

Robinson. Latin Grammar of Pharmacy and Medicine. By H. D. Robinson, PH.D., Professor of Latin Language and Literature, University of Kansas, Lawrence. With an Introduction by L. E. Sayre, PH.G., Professor of Pharmacy in, and Dean of, the Dept. of Pharmacy, University of Kansas. 12mo. Second Edition. Cloth, 2.00

SKIN DISEASES.

Crocker. Diseases of the Skin, their Description, Pathology, Diagnosis, and Treatment, with Special Reference to the Skin Eruptions of Children. By H. Radcliffe Crocker, F.R.C.P., Physician for Diseases of the Skin in University College Hospital. Second Edition. Revised and Enlarged, with 92 Wood-cuts. Cloth, 5.00

Van Harlingen on Skin Diseases. Third Edition. Enlarged and Illustrated. 12mo. *In Press.*

☞ See pages 2 to 5 for list of New Manuals.

SURGERY AND BANDAGING.

Moullin's Surgery, by Hamilton. 600 Illustrations (some colored), 200 of which are original. Second Edition.

Cloth, net, 7.00; Leather, net, 8.00; Half Russia, net, 9.00

. Complete circulars, with sample pages and Illustrations, free upon application.

Jacobson. Operations in Surgery. A Systematic Handbook for Physicians, Students, and Hospital Surgeons. By W. H. A. Jacobson, B.A. Oxon., F.R.C.S. Eng.; Ass't Surgeon Guy's Hospital; Surgeon at Royal Hospital for Children and Women, etc. 199 Illustrations. 1006 pages. 8vo. Cloth, 5.00; Leather, 6.00

Heath's Minor Surgery, and Bandaging. Tenth Edition. 158 Illustrations. 62 Formulæ, and Diet Lists. Cloth, 2.00

Horwitz's Compend of Surgery, Minor Surgery and Bandaging, Amputations, Fractures, Dislocations, Surgical Diseases, and the Latest Antiseptic Rules, etc., with Differential Diagnosis and Treatment. By ORVILLE HORWITZ, B.S., M.D., Demonstrator of Surgery, Jefferson Medical College. 5th Edition, Enlarged and Rearranged. Many new Illustrations and Formulæ. 12mo. Cloth, 1.00; Interleaved for the addition of Notes, 1.25

. The new Section on Bandaging and Surgical Dressings consists of 32 Pages and 41 Illustrations. Every Bandage of any importance is figured. This, with the Section on Ligation of Arteries, forms an ample Text-book for the Surgical Laboratory.

Walsham. Manual of Practical Surgery. Third Edition. By WM. J. WALSHAM, M.D., F.R.C.S., Asst. Surg. to, and Dem- of Practical Surg. in, St. Bartholomew's Hospital; Surgeon to Metropolitan Free Hospital, London. With 318 Engravings. See page 2. Cloth, 3.00; Leather, 3.50

URINE, URINARY ORGANS, ETC.

Holland. The Urine, and Common Poisons and The Milk. Chemical and Microscopical, for Laboratory Use. Illustrated. Fourth Edition. 12mo. Interleaved. Cloth, 1.00

Ralfe. Kidney Diseases and Urinary Derangements. 42 Illustrations. 12mo. 572 pages. Cloth, 2.75

Marshall and Smith. On the Urine. The Chemical Analysis of the Urine. Colored Plates. 12mo. Cloth, 1.00

Memminger. Diagnosis by the Urine. Illus. Cloth, 1.00

Tyson. On the Urine. A Practical Guide to the Examination of Urine. With Colored Plates and Wood Engravings. Eighth Edition, Enlarged. 12mo. Cloth, 1.50

Van Nüys, Urine Analysis. Illus. Cloth, 1.00

VENEREAL DISEASES.

Hill and Cooper. Student's Manual of Venereal Diseases, with Formulæ. Fourth Edition. 12mo. Cloth, 1.00

. See pages 14 and 15 for list of ? Quis-Compendis ?

? QUIZ-COMPENDS?

The Best Compendes for Students' Use
in the Quiz Class, and when Pre-
paring for Examinations.

Compiled in accordance with the latest teachings of prominent Lecturers and the most popular Text-books.

They form a most complete, practical, and exhaustive set of manuals, containing information nowhere else collected in such a condensed, practical shape. Thoroughly up to the times in every respect, containing many new prescriptions and formulæ, and over six hundred illustrations, many of which have been drawn and engraved specially for this series. The authors have had large experience as quiz-masters and attachés of colleges, with exceptional opportunities for noting the most recent advances and methods.

Cloth, each \$1.00. Interleaved for Notes, \$1.25.

No. 1. HUMAN ANATOMY, "Based upon Gray." Fifth Enlarged Edition, including Visceral Anatomy, formerly published separately. 16 Lithograph Plates, New Tables, and 117 other Illustrations. By SAMUEL O. L. POTTER, M.A., M.D., M.R.C.P. (Lond.), late A. A. Surgeon U. S. Army, Professor of Practice, Cooper Medical College, San Francisco.

Nos. 2 and 3. PRACTICE OF MEDICINE. Fifth Edition. By DANIEL E. HUGHES, M.D., Demonstrator of Clinical Medicine in Jefferson Medical College, Philadelphia. In two parts.

PART I.—Continued, Eruptive, and Periodical Fevers, Diseases of the Stomach, Intestines, Peritoneum, Biliary Passages, Liver, Kidneys, etc. (including Tests for Urine), General Diseases, etc.

PART II.—Diseases of the Respiratory System (including Physical Diagnosis), Circulatory System, and Nervous System; Diseases of the Blood, etc.

*These little books can be regarded as a full set of notes upon the Practice of Medicine, containing the Synonyms, Definitions, Causes, Symptoms, Prognosis, Diagnosis, Treatment, etc., of each disease, and including a number of prescriptions hitherto unpublished.

No. 4. PHYSIOLOGY, including Embryology. Seventh Edition. By ALBERT P. BRUBAKER, M.D., Prof. of Physiology, Penn'a College of Dental Surgery; Demonstrator of Physiology in Jefferson Medical College, Philadelphia. Revised, Enlarged, with new Illustrations.

No. 5. OBSTETRICS. Illustrated. Fifth Edition. By HENRY G. LANDIS, M.D. Edited by WILLIAM H. WELLS, M.D., Assistant Demonstrator of Clinical Obstetrics, Jefferson College, Philadelphia. New Illustrations.

BLAKISTON'S ? QUIZ-COMPENDS ?

- No. 6. MATERIA MEDICA, THERAPEUTICS, AND PRESCRIPTION WRITING.** Fifth Revised Edition. With especial Reference to the Physiological Action of Drugs, and a complete article on Prescription Writing, including many unofficinal remedies. By SAMUEL O. L. POTTER, M.A., M.D., M.R.C.P. (Lond.), late A. A. Surg. U. S. Army; Prof. of Practice, Cooper Medical College, San Francisco. Improved and Enlarged, with Index.
- No. 7. GYNÆCOLOGY.** A Compend of Diseases of Women. By WM. H. WELLS, M.D., Ass't Demonstrator of Obstetrics, Jefferson Medical College, Philadelphia. Illustrated.
- No. 8. DISEASES OF THE EYE AND REFRACTION,** including Treatment and Surgery. By L. WEBSTER FOX, M.D., Chief Clinical Assistant Ophthalmological Dept., Jefferson Medical College, etc., and GEO. M. GOULD, M.D. 71 Illustrations, 39 Formulæ. Second Enlarged and Improved Edition. Index.
- No. 9. SURGERY, Minor Surgery and Bandaging.** Illustrated. Fifth Edition. Including Fractures, Wounds, Dislocations, Sprains, Amputations, and other operations; Inflammation, Suppuration, Ulcers, Syphilis, Tumors, Shock, etc. Diseases of the Spine, Ear, Bladder, Testicles, Anus, and other Surgical Diseases. By ORVILLE HORWITZ, A.M., M.D., Demonstrator of Surgery, Jefferson Medical College. Revised and Enlarged. 98 Formulæ and 167 Illustrations.
- No. 10. CHEMISTRY.** Inorganic and Organic. For Medical and Dental Students. Including Urinary Analysis and Medical Chemistry. By HENRY LEFFMANN, M.D., Prof. of Chemistry in Penn'a College of Dental Surgery, Phila. Third Edition, Revised and Rewritten, with Index.
- No. 11. PHARMACY.** Based upon "Remington's Text-book of Pharmacy." By F. E. STEWART, M.D., PH.G., Quiz-Master at Philadelphia College of Pharmacy. Fourth Edition, Revised.
- No. 12. VETERINARY ANATOMY AND PHYSIOLOGY.** 29 Illustrations. By WM. R. BALLOU, M.D., Prof. of Equine Anatomy at N. Y. College of Veterinary Surgeons.
- No. 13. DENTAL PATHOLOGY AND DENTAL MEDICINE.** Containing all the most noteworthy points of interest to the Dental student. Second Edition. By GEO. W. WARREN, D.D.S., Clinical Chief, Penn'a College of Dental Surgery, Philadelphia. Second Edition, Enlarged and Illustrated.
- No. 14. DISEASES OF CHILDREN.** By DR. MARCUS P. HATFIELD, Prof. of Diseases of Children, Chicago Medical College. Colored Plate.
- No. 15. GENERAL PATHOLOGY AND MORBID ANATOMY.** By H. NEWBERRY HALL, M.D., Professor of Pathology and Medical Chemistry Post-Graduate School; Surgeon Emergency Hospital, Chicago, etc. 91 Illustrations.

Bound in Cloth, \$1. Interleaved, for the Addition of Notes, \$1.25.

No series of books are so complete in detail, concise in language, or so well printed and bound. Each one forms a complete set of notes upon the subject under consideration.

Illustrated Descriptive Circular Free.

25,000 COPIES
Of These Books Have Already Been Sold.
GOULD'S STUDENT'S
MEDICAL DICTIONARY.

Based on Recent Medical Literature.



Small 8vo, Half Morocco, as above, with Thumb Index, . . \$4.25
Plain Dark Leather, without Thumb Index, 3.25

A compact, concise Vocabulary, including all the Words and Phrases used in medicine, with their proper Pronunciation and Definitions.

"One pleasing feature of the book is that the reader can almost invariably find the definition under the word he looks for, without being referred from one place to another, as is too commonly the case in medical dictionaries. The tables of the bacilli, micrococci, leucomaines and ptomaines are excellent, and contain a large amount of information in a limited space. The anatomical tables are also concise and clear. . . . We should unhesitatingly recommend this dictionary to our readers, feeling sure that it will prove of much value to them."—*American Journal of Medical Science.*

JUST PUBLISHED.
GOULD'S POCKET DICTIONARY. 12,000
Medical Words Pronounced and Defined.
Leather, gilt edges, \$1.00; with Thumb Index, \$1.25



ant, curat m.
Zanulesi vena
cava,
Portul m

LANE MEDICAL LIBRARY

To avoid fine, this book should be returned on
or before the date last stamped below.

ilio-

ilio-

ilio-

ilio-

8 5 0 8 0 2

E34 Holden, L.

H726 Holden's anatomy.

1894

59431

NAME

DATE DUE

Robert H. Munscheing

